



Contents lists available at ScienceDirect

## International Journal of Surgery Case Reports

journal homepage: [www.casereports.com](http://www.casereports.com)

# Spontaneous dissociation of bipolar hip hemiarthroplasty in a patient with nerve palsy: A case report and review of the literature



Varah Yuenyongviwat<sup>a,\*</sup>, Khanin lamthanaporn<sup>a</sup>, Theerawit Hongnaparak<sup>a</sup>

<sup>a</sup> Department of Orthopaedic Surgery and Physical Medicine, Faculty of Medicine, Prince of Songkla University, Hat Yai, Songkhla, 90110 Thailand

## ARTICLE INFO

### Article history:

Received 9 June 2015

Received in revised form 21 August 2015

Accepted 21 August 2015

Available online 29 August 2015

### Keywords:

Bipolar  
Hemiarthroplasty  
Dislocation  
Dissociation

## ABSTRACT

**INTRODUCTION:** Dislocation after bipolar hemiarthroplasty is a common complication but dissociation of the prosthesis is rare. There are some reports of bipolar hemiarthroplasty dissociation at the inner head and outer shell. However, there are limited reports on acute spontaneous dissociation of the head and neck at the taper interface in bipolar hemiarthroplasty.

**PRESENTATION OF CASE:** A 65-year-old female had cemented bipolar hip replacement after fixation failure of a dynamic hip screw. She had left lower limb weakness for ten years after previous spinal surgery. At the sixth week of postoperation, the patient had dissociation of the components of the bipolar hemiarthroplasty at the femoral head and neck junction. The patient had open reduction and femoral head revision. There was no re-dislocation at one-year follow-up.

**DISCUSSION:** Dissociation of bipolar hemiarthroplasty is a complex complication that can happen from the modularity of the implant. This condition requires operative treatment. The mechanism and cause of failure should be identified before the operation.

**CONCLUSION:** To prevent this condition, preoperative planning and proper techniques should be done as an index procedure. In the case of marked shortening of the limb after an operation in patients with lower limb muscle weakness, we hypothesize that early full weight bearing with immediate use of a shoe lift might help prevent this condition.

© 2015 The Authors. Published by Elsevier Ltd. on behalf of Surgical Associates Ltd. This is an open access article under the CC BY-NC-ND license (<http://creativecommons.org/licenses/by-nc-nd/4.0/>).

## 1. Introduction

Bipolar hemiarthroplasty is one of the treatment options for unstable femoral neck fracture in the elderly [1]. Hip dislocation after hip replacement is a common complication but dissociation of a bipolar prosthesis is rare. There are some reports of bipolar hemiarthroplasty dissociation at the inner head and outer shell [2–5]. However, there are limited reports on acute spontaneous dissociation of head and neck at the taper junction in bipolar hemiarthroplasty. A previous case reported inner femoral head disassembly from the stem-neck taper junction which occurred after revision of the head of a bipolar hip prosthesis [6]. The present study reports an acute disassembly of a primary bipolar hemiarthroplasty at the femoral head and stem-neck taper junction in a patient with nerve palsy. This case report is rare and will be beneficial for surgeons who perform hip arthroplasty in a patient with limb shortening and weakness. Written informed consent was obtained from the patient for publication of this case report.

\* Corresponding author. Fax: +66 74451603.

E-mail addresses: [varahortho@gmail.com](mailto:varahortho@gmail.com) (V. Yuenyongviwat), [iamnat0212@gmail.com](mailto:iamnato212@gmail.com) (K. lamthanaporn), [theerawit.h@gmail.com](mailto:theerawit.h@gmail.com) (T. Hongnaparak).

<http://dx.doi.org/10.1016/j.ijscr.2015.08.034>

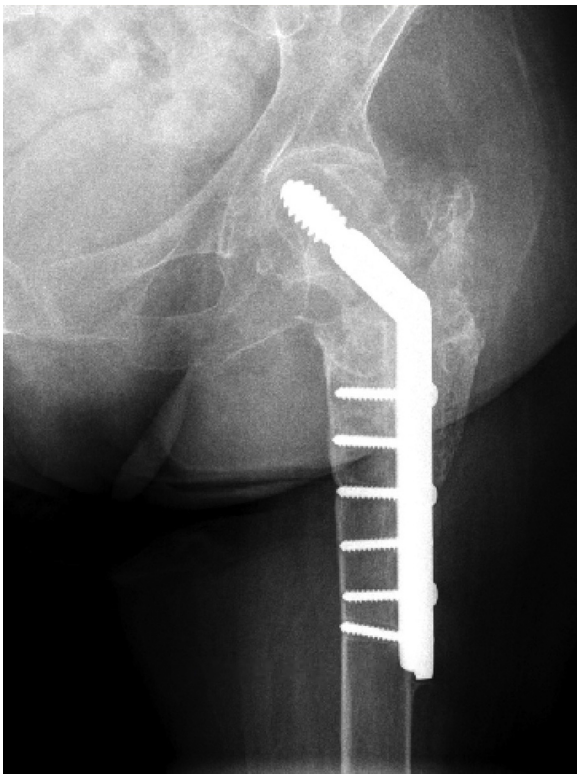2210-2612/© 2015 The Authors. Published by Elsevier Ltd. on behalf of Surgical Associates Ltd. This is an open access article under the CC BY-NC-ND license (<http://creativecommons.org/licenses/by-nc-nd/4.0/>).

## 2. Presentation of case

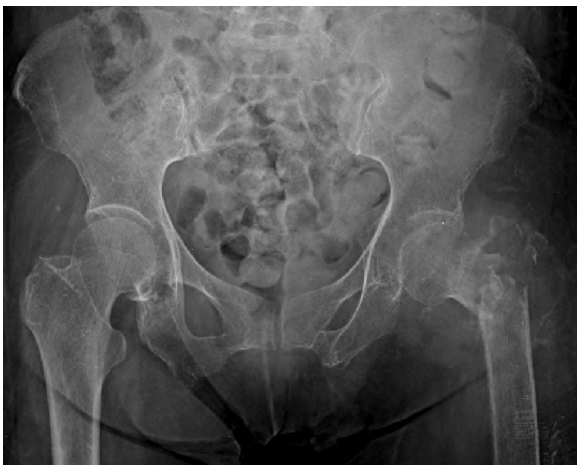A 65-year-old female patient presented with failure of dynamic hip screw fixation for treatment of pathological intertrochanteric fracture of her left hip (Fig. 1). Three years prior to the visit at the clinic, she had pathological intertrochanteric fracture at her left hip from osteomyelitis while she was changing posture from standing to sitting (Fig. 2). She was treated by antibiotic cement spacer and systemic antibiotics. After the infection cleared, she had an operation for dynamic hip screw and bone grafting. At the fifth month of the postoperative period, there were signs of fixation failure. However, the patient refused to have hip replacement after early fixation failure but finally she considered having hip replacement 2 years later. She also had surgery 10 years earlier for spinal stenosis at the lower lumbar spine. After the spine surgery, she developed weakness of her left lower limb. She had no other medical history.

At the clinical visit, the physical examination showed a 6 cm shortening of her left leg compared with the right side. She had left ankle dorsiflexion and toe dorsiflexion motor power grade II and quadriceps motor power grade III. She had decreased sensation over the dorsum of her left foot. A plain radiograph showed loosening of the dynamic hip screw and bone loss in the femoral head.

In this case, the patient chose bipolar hemiarthroplasty for treatment because she was a household ambulator and had a high risk



**Fig. 1.** Plain radiograph shows failure of dynamic hip screw fixation.

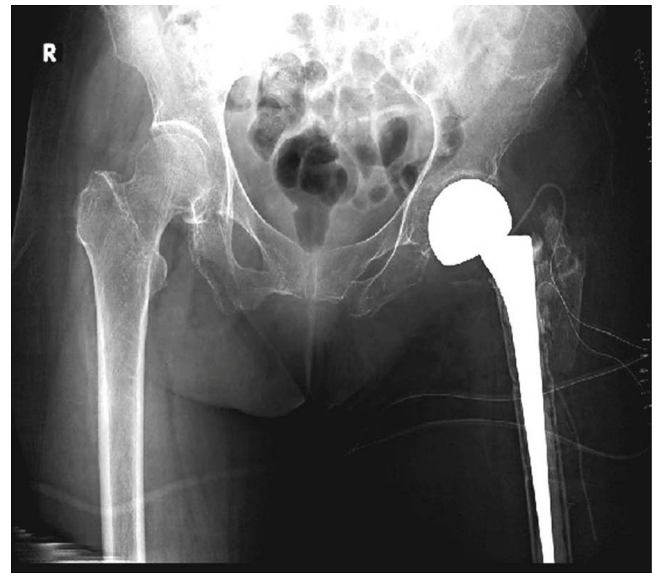

**Fig. 2.** Initial plain radiograph of fracture.

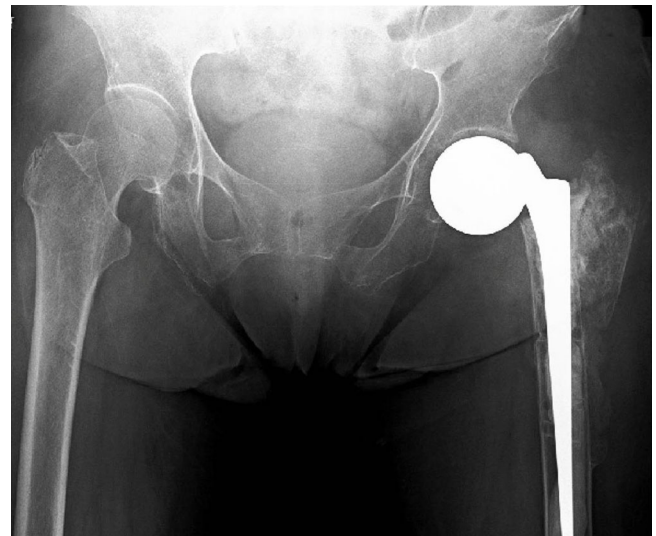
for hip dislocation following total hip replacement due to her poor muscle condition. An operation for long-stem cemented bipolar hemiarthroplasty was done (CPT, Zimmer, Inc., Warsaw, IN, USA). The operation was done by the posterior approach. After the stem was placed in the femoral canal, the femoral head component was coupled with one stroke of a hammer after the stem neck was cleaned and dried. After insertion of the femoral head, the surgeon inspected the coupling again by trying to pull the head out of the stem neck gently by finger to confirm a perfect coupling.

The postoperative examination found that the patient still had a shortened left leg of 5 cm compared with the right side (Fig. 3). The patient was allowed to ambulate with a walker by full weight bearing after the operation.

At the sixth week of the postoperative period, the patient felt clicking in her left hip while walking and was unable to move her



**Fig. 3.** Immediate postoperative plain radiograph.



**Fig. 4.** Six-week follow-up plain radiograph.

hip as usual. She said she didn't use her orthopedic shoe lift and didn't step with full weight on her left foot because she was familiar with non-weight bearing without the shoe lift for a long time. The hip radiographs demonstrated dissociation of the components of the bipolar hemiarthroplasty at the femoral head and neck junction (Fig. 4).

Open reduction was performed through the old surgical scar using the posterior approach. The femoral head component was found intraoperatively in the acetabulum and was covered with a well healed capsule. The tapered part at the inner head and stem neck didn't show any scratch marks or defects. A new femoral head with a longer offset was assembled to the old femoral stem (Fig. 5).

Postoperatively, the patient received an orthopedic shoe lift to correct the limb length discrepancy and she was encouraged to apply full weight during ambulation. At one-year follow-up, there were no complications. She was able to ambulate with a walker and the Harris hip score was 69.

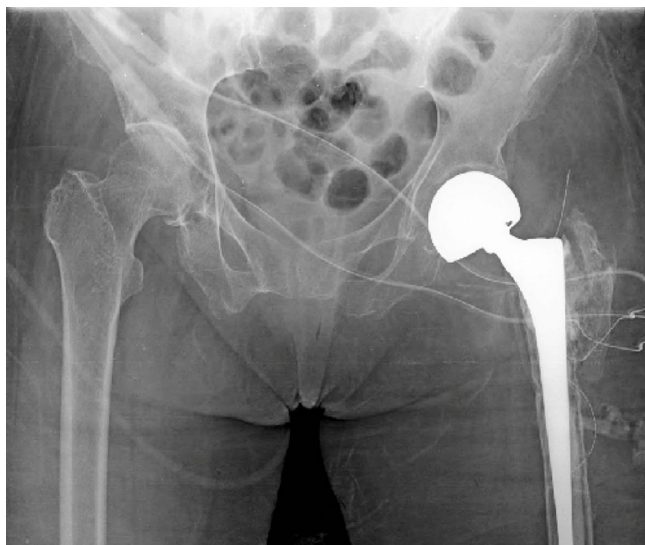

Fig. 5. Immediate postrevision operative plain radiograph.

### 3. Discussion

The modular system of hip arthroplasty is an option to restore good hip biomechanics and function. However, there are also problems that can happen from the modularity of this implant. The concerns are corrosion, fretting at the modular junction, and implant dissociation [7,8]. Cases of dissociation of bipolar hemiarthroplasty were reported. Most of the cases were disassembly of the polyethylene cup and the inner femoral head [2–5]. There are few case reports of disassembly of the inner femoral head and stem neck at the taper junction [5,6].

Bipolar hemiarthroplasty dissociation can occur from many causes. The most common cause in the reports was dissociation after manipulation for closed reduction under general anesthesia. The mechanism was called “bottle-opener mechanism”. When the surgeon applied traction force to reduce the dislocated hip, the outer bipolar shell locked with the acetabular rim but the inner head continued traction until dissociation occurred [2,3,5]. The other cause was failure of the polyethylene locking ring [2,4]. This failure usually presented with intra-acetabular dislocation with the bipolar shell still in the acetabulum but the inner head was dislocated out of the acetabulum [4]. Failure of the locking ring might be from an improper technique of installing the locking ring [9].

Failures of disassembly at the inner head and neck stem in bipolar hip prosthesis were also reported [5,6]. Toshiki Shiga et al. suspected that the reason of disassembly was impingement of the stem neck and outer shell when the hip was in extreme flexion and abduction and internal rotation [6]. However, Fukuda et al. stated that failure of the taper lock mechanism might happen from an inner head revision operation [10].

The prosthesis in the present case report was dissociated without a history of trauma or extreme movement and the dissociation occurred in primary bipolar hemi replacement which is different from the previous report which had a femoral head revision procedure before dissociation occurred. The suspected cause of dissociation in this case was repeated dynamic traction force because this patient had weakness of the left lower limb muscle and marked shortening of the limb. The authors hypothesize that the femoral head component was trapped in the acetabulum and hip capsule but the femoral stem had repeated traction force by the lower limb weight because the patient ambulated without foot contact to the ground and the patient also had loss of muscle power to hold the lower limb with the pelvis.

The other factor might be the pumping phenomenon caused by sealed air trapped in the inner femoral head [6]. However, the index hip replacement procedure in the present case was done to avoid this phenomenon by cleaning and drying the stem neck and coupling the femoral head and neck with one stroke of a hammer.

Treatment of bipolar hemiarthroplasty with failure of the taper lock mechanism in the previous report was full revision by change of the stem and femoral head component due to a tapered defect at the upper part of the stem neck [6]. In the present case, the stem neck was inspected and the tapered part was intact. So, head revision was done without stem revision. After the operation, the patient received an orthopedic shoe lift and was encouraged to apply full weight bearing when ambulating to prevent a distraction force from the unsupported limb. With this approach, this case had a successful outcome at one-year follow-up.

### 4. Conclusion

Dissociation of bipolar hemiarthroplasty is a complex complication that requires operative treatment. The mechanism and cause of failure should be identified before the operation. To prevent this condition, preoperative planning and proper techniques should be done as an index procedure. In the case of marked shortening of the limb after an operation in patients with lower limb muscle weakness, we hypothesize that early full weight bearing with immediate use of a shoe lift might help prevent this condition.

### Conflicts of interest

No conflict of interest.

### Funding

No source of funding.

### Ethical approval

The present study was approved by the Prince of Songkla university Institutional Review Board, Faculty of Medicine, Songklanagarind Hospital, Prince of Songkla University (IRB number REC 58-127-11-1).

### Consent

Written informed consent was obtained from the patient for publication of this case report and accompanying images. A copy of the written consent is available for review by the Editor-in-Chief of this journal on request.

### Author contribution

Varah Yuenyongviwat—Preparation of case report, Literature review, Writing the paper.

Khanin Iamthanaporn—Preparation of case report. Literature review.

Theerawit Hongnarak—Literature review, Editing the paper.

All co-authors have seen and agree with the contents of the manuscript.

### Guarantor

Varah Yuenyongviwat accepts full responsibility for the work and controlled the decision to publish.

## Acknowledgement

The authors would like to thank Glenn Shingledecker for proof-reading the English of this report.

## References

- [1] P.L. Broos, Prosthetic replacement in the management of unstable femoral neck fractures in the elderly. Analysis of the mechanical complications noted in 778 fractures, *Acta Chir. Belg.* 99 (1999) 190–194.
- [2] G. Georgiou, A. Siapkara, A. Dimitrakopoulou, S. Provelengios, E. Dounis, Dissociation of bipolar hemiarthroplasty of the hip after dislocation. A report of five different cases and review of literature, *Injury* 372 (2006) 162–168.
- [3] F. Loubignac, F. Boissier, Cup dissociation after reduction of a dislocated hip hemiarthroplasty, *Rev. Chir. Orthop. Reparatrice Appar. Mot.* 835 (1997) 469–472.
- [4] J. Tabutin, A. Damotte, Progressive intra-acetabular dislocation of bipolar hip prostheses: four cases, *Rev. Chir. Orthop. Reparatrice Appar. Mot.* 90 (2004) 79–82.
- [5] M.J. Star, C.W.J. Colwell, D. r, W.F. onaldson 3, W. rd, R.H. alker, Dissociation of modular hip arthroplasty components after dislocation. A report of three cases at differing dissociation levels, *Clin. Orthop. Relat. Res.* 278 (1992) 111–115.
- [6] T. Shiga, M. Mori, T. Hayashida, Y. Fujiwara, T. Ogura, Disassembly of a modular femoral component after femoral head prosthetic replacement, *J. Arthroplasty* 25 (2010) 659.
- [7] J.D. Boby, M. Tanzer, J.J. Krygier, A.R. Dujovne, C.E. Brooks, Concerns with modularity in total hip arthroplasty, *Clin. Orthop. Relat. Res.* 298 (1994) 27–36.
- [8] A.M. Kop, E. Swarts, Corrosion of a hip stem with a modular neck taper junction: a retrieval study of 16 cases, *J. Arthroplasty* 24 (2009) 1019–1023.
- [9] L.C. Lin, J.J. Chang, R.Y. Pan, Dissociation of bipolar prostheses with hip subluxation: A case report and literature review, *J. Med. Sci.* 34 (2014) 214.
- [10] S. Fukuda, A. Kuge, H. Nakamura, Separation between inner head and stem after bipolar hemiarthroplasty of the hip: a case report, *SeikeiGeka* 53 (2002) 554.

## Open Access

This article is published Open Access at [sciedirect.com](http://sciedirect.com). It is distributed under the [IJSCR Supplemental terms and conditions](#), which permits unrestricted non commercial use, distribution, and reproduction in any medium, provided the original authors and source are credited.