

Disseminated intravascular coagulation from disseminated histoplasmosis in uncontrolled HIV – Case report



Jared L. Cooper^{a,*}, Aaron M. Spring^{a,b}, David J. Low^a

^a Department of Internal Medicine, Faculty of Medicine, University of Calgary, Calgary, AB, Canada

^b Department of Paediatrics, Faculty of Medicine, University of Toronto, Toronto, ON, Canada

ARTICLE INFO

Article history:

Received 6 July 2021

Received in revised form 7 August 2021

Accepted 30 August 2021

Available online xxxx

Keywords:

Disseminated Intravascular Coagulation (DIC)

Disseminated Histoplasmosis

Human Immunodeficiency Virus (HIV)

Histoplasma Capsulatum

Case Report

ABSTRACT

This case report describes an atypical presentation of a relatively common opportunistic infection, without documented exposure to areas known at the time to be endemic, resulting in catastrophic complications. The patient presented with a two month progressive history of vomiting, diarrhea, productive cough, and shortness of breath, on the background of poorly-controlled HIV. There was a low index of suspicion for infection with histoplasmosis, particularly given the large differential diagnosis and the lack of travel or endemic precedence. The case was complicated by the development of disseminated intravascular coagulation (DIC) prior to identification of the pathogen. Ultimately, the patient's goals of care transitioned to palliation, and treatments were discontinued. It is our hope that in the future, such outcomes might be prevented by considering disseminated histoplasmosis in systemically unwell patients with HIV, regardless of endemic exposure or specific presentation.

© 2021 Published by Elsevier Ltd.
CC_BY_NC_ND_4.0

Introduction

Disseminated histoplasmosis is a granulomatous disease that has commonly been associated with travel to the endemic regions of its causative organism (*Histoplasma capsulatum*), and immunodeficient states [1]. Traditionally, the endemic areas of *H. capsulatum* within North America have been widespread, but have not included western Canada. Few cases of *H. capsulatum* have been described in western Canada, most closely in central Alberta [2,3], and only recently has it been proposed to expand the endemic area to include Alberta [3]. The present work reports the first confirmed infection with *H. capsulatum* in southern Alberta and the first reported mortality attributable to *H. capsulatum* in western Canada.

Case description

A 49-year-old male residing in southern Alberta presented with a two month progressive history of vomiting, diarrhea, productive cough, and shortness of breath. His history was remarkable for a 20 year history of HIV not actively on antiretroviral treatment (CD4 count of 3); housing insecurity; and lack of social supports. Travel history and infectious exposures were negative.

At presentation he was tachypneic (24/min), tachycardic (112/min), hypertensive (140/94 mmHg), and febrile (Tmax 38.4 °C) but saturating well on room air (SpO2 98%). Physical examination was remarkable for cachexia including temporal wasting; bronchial breath sounds at the right lower lung base; and a diffusely tender non-peritonitic abdomen.

Timeline

Fig. 1 illustrates the timeline from the patient's admission.

Diagnostic assessment and therapeutic intervention

Initial laboratory investigations including blood chemistry (Table 1), complete blood count (Table 2), blood gas (Table 3), and coagulation panel (Table 4) were notable for anemia and neutropenia. Computed tomography of the thorax revealed peripheral nodularity bilaterally in the lower lung fields with some tree-in-bud patterning. Empiric treatment for *Pneumocystis jiroveci* pneumonia (PJP) and atypical community acquired pneumonia were initiated. Antiretrovirals were not initiated on admission. Initial bacterial blood cultures returned negative with no improvement of symptoms. Subsequent bronchoalveolar lavage (BAL), urine virology, serology, and respiratory viral panel were obtained, including studies for: cryptococcus, cytomegalovirus, legionella, acid fast bacilli,

* Corresponding author.

E-mail address: Jared.cooper@albertahealthservices.ca (J.L. Cooper).

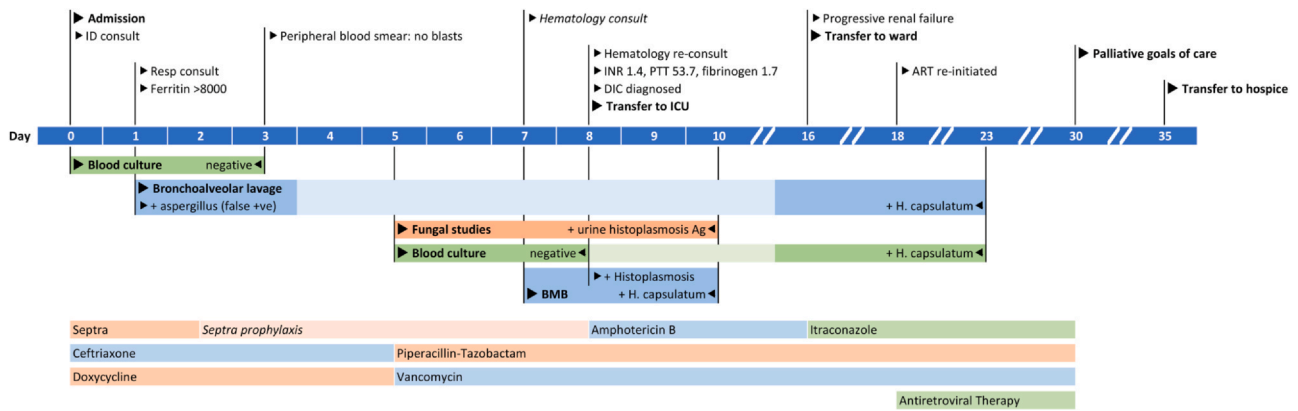


Fig. 1. Admission timeline, including significant events; date of significant investigations and corresponding results; and relevant treatments. Investigations are marked on the date of collection, with interim and final results noted on the date(s) resulted.

Table 1
Blood chemistry.

Test	Units	Range	Day 1	Day 8
Na	mmol/L	133–145	125 _↓	
K	mmol/L	3.5–5	3.4 _↓	
Cl	mmol/L	98–111	92 _↓	
CO2	mmol/L	21–31	19 _↓	
Cr	mmol/L	50–120	146 [†]	250 [†]
Ca	mmol/L	2.1–2.6	1.99 _↓	
Alb	g/L	33–48	25 _↓	
Phos	mmol/L	0.8–1.5	1.3	
Mg	mmol/L	0.65–1.05	0.85	
ALP	U/L	30–130	122	
ALT	unit/L	1–60	34	
GGT	U/L	11–63	64	
Bili	μmol/L	0–24	10	
Lipase	U/L	0–80	102	
LDH	unit/L	100–235	>2500 [†]	>2500
Ferritin*	μg/L	30–400	>8000 [†]	

Blood chemistry, including comprehensive initial investigations from Day 1 (except as otherwise noted), and relevant investigations from Day 8. SI units and normal range for laboratory are noted for each test. *- Ferritin collected Day 2. Abnormal values noted in red, with (↓) indicating values below normal range and (†) indicating values above normal range. Abbreviations: Chem (chemistry), Na (sodium), K (potassium), Cl (chloride), CO2 (bicarbonate), Cr (creatinine), Ca (total calcium; uncorrected); Alb (albumin), Phos (phosphate), Mg (magnesium), ALP (alkaline phosphatase), ALT (alanine transaminase), GGT (gamma-glutamyl transferase), Bili (total bilirubin), LDH (lactate dehydrogenase), U (units), mmol (millimole), μmol (micromole), L (litre), g (gram), μg (microgram).

Table 2
Complete blood count.

Test	Units	Range	Day 1	Day 8
Hgb	g/L	137–180	84 _↓	55 _↓
MCV	fL	82–100	80 _↓	82
Platelets	x10 ⁹ /L	150–400	199	117 _↓
WBC	x10 ⁹ /L	4–11	1.0 _↓	1.4 _↓
Neut	x10 ⁹ /L	2–8	0.7 _↓	0.9 _↓
Lymph	x10 ⁹ /L	0.7–3.5	0.3 _↓	0.4 _↓

Complete blood count from Day 1 and Day 8. SI units and normal ranges are noted for each test. Values below normal range are noted in red and marked with downward arrow (↓). Abbreviations: Hgb (hemoglobin), MCV (mean corpuscular volume), WBC (white blood cells), Neut (neutrophils), Lymph (lymphocytes), L (litre), fL (femtolitre), g (gram).

and PJP. Due to persistent febrile neutropenia he was broadened to coverage with piperacillin-tazobactam.

Eight days into admission, a bone marrow biopsy was performed to investigate the persistent bicytopenia. Post-procedure, significant bleeding began, including simultaneous large-volume epistaxis, hematuria, and local hemorrhage from the biopsy site. Investigations revealed declining platelets (Table 2), presence of schistocytes,

Table 3
Blood gas.

Test	Units	Range	Day 1
pH	—	7.30–7.40	7.46 [†]
pCO2	mmHg	36–46	30 _↓
HCO3	mmol/L	20–24	21
Lactate	mmol/L	0–2	1.4

Blood gas from Day 1. SI units and normal range for laboratory are noted for each test. *- Ferritin collected Day 2. Abnormal values noted in red, with (↓) indicating values below normal range and (†) indicating values above normal range. Abbreviations: pCO2 (partial pressure of carbon dioxide), HCO3 (bicarbonate), mmHg (millimetres of mercury), mmol (millimole), L (litre).

Table 4
Coagulation panels.

Test	Units	Range	Day 3	Day 8
INR		0.9–1.1	1.2 [†]	1.4 [†]
PTT	seconds	26–36	—	53.7 [†]
Fibrinogen	g/L	1.6–4.1	1.1 _↓	1.7*

Coagulation panels from Days 3 and 8. SI units and normal range for laboratory are noted for each test. *- Ferritin collected Day 2. Abnormal values noted in red, with (↓) indicating values below normal range and (†) indicating values above normal range. Abbreviations: INR (International Normalized Ratio), PTT (partial thromboplastin time), g (gram), L (litre).

elevated international normalized ratio, prolonged partial thromboplastin time, and falsely normal fibrinogen (Table 4). Given his clear coagulopathy and profuse bleeding phenotype he was diagnosed with disseminated intravascular coagulation (DIC). He received tranexamic acid, as well as transfusions of packed red blood cells, fresh frozen plasma, and cryoprecipitate. A preliminary pathology report returned three days later showing histocytes filled with microorganisms morphologically in keeping with *Histoplasma* spp. – which was ultimately speciated as *H. capsulatum* on blood culture – and empiric Amphotericin B intravenous therapy was initiated. Additionally, testing revealed positive urine histoplasma antigen, and later showed BAL fungal cultures with *H. capsulatum* and falsely positive BAL aspergillus galactomannan antigen.

The patient developed multisystem organ failure and was transferred to the intensive care unit (ICU) for intubation and vasopressor support. While stabilized from a cardiopulmonary perspective, he continued to exhibit progressive renal failure, which was attributed to the Amphotericin B treatment. It was determined that he was not a candidate for hemodialysis, and was transferred back to the general internal medicine ward for ongoing management of his bleeding, infection, and renal failure. His progressive renal failure persisted despite transitioning from Amphotericin B to itraconazole to minimize renal toxicity.

Antiretroviral therapy was initiated on day 18. On day 30, the patient advocated for a transition to palliative care; he was subsequently transferred to hospice where he ultimately passed away.

Discussion

Traditionally, the endemic areas of *H. capsulatum* within North America have been widespread, but have not included western Canada. At the time of this patient's presentation, one case series of immunocompetent patients described a cluster of three confirmed cases of acute histoplasmosis thought to have been acquired in northern Alberta [2], which to our knowledge reflected the closest reported *H. capsulatum* infection of any sort. No reports yet existed of locally acquired disseminated histoplasmosis. Subsequently, an epidemiologic study undertaken in Alberta identified a total of five proven and six probable cases of locally acquired *Histoplasma* spp. in central and northern Alberta, including disseminated histoplasmosis [3]. The present case further expands the geographic locations in which *H. capsulatum* has been acquired, and provides further evidence supporting the expansion of its endemic area.

The diagnosis of *H. capsulatum* in immunocompromised individuals is challenging to complete in an expedient manner. A comprehensive review described these challenges, noting that: growth and identification of *H. capsulatum* can take 1–6 weeks; blood cultures have lower sensitivity than bone marrow aspirates; and that alternative methods such as antibody detection are substantially less sensitive in immunocompromised patients with HIV [4]. Conversely, a retrospective cohort study found that cultures were more sensitive in patients with HIV than those without [1]. In the present case the blood cultures did eventually grow *H. capsulatum*, but the diagnosis was made from the bone marrow aspirates drawn on the eighth day of admission. A prospective study of a cohort of 31 HIV positive patients with pancytopenia found a probable diagnosis in 38.7% of patients using bone marrow microscopy, suggesting early bone marrow biopsy and microscopy plays an important clinical role in such cases [5]. The bone marrow biopsy in the present case was performed due to febrile neutropenia and anemia, preceding the development of pancytopenia. Whether the diagnostic yield justifies the risk of performing a bone marrow biopsy routinely for bicytopenia in patients with HIV remains to be elucidated.

Despite the low geographical probability of *H. capsulatum* infection and the initially negative blood cultures, the patient's HIV positive status and poor compliance to antiretroviral therapy placed him at increased risk for opportunistic infection, and at a high risk of morbidity and mortality. A retrospective cohort study found patients with acquired immunodeficiency syndrome in particular to be at greater risk for morbidity and mortality than those without HIV, and that this finding was largely driven by the significantly higher mortality within the subset of HIV positive patients not receiving highly active antiretroviral therapy (HAART) at the time of infection [1]. Indeed, seven of the 10 patients with HIV not receiving HAART died, while none showed major improvement with antifungal therapy [1].

In the present case, the patient developed a clear coagulopathy and profuse bleeding phenotype. Despite a normal fibrinogen level, he was diagnosed with disseminated intravascular coagulation (DIC). The fibrinogen level was disregarded in this diagnosis due to its established poor sensitivity, potentially due to its dual role as an acute phase reactant [6]. Indeed, higher fibrinogen levels (such as in the present case) have been linked to poorer outcomes in DIC [7]. To date, DIC has been described as a complication of disseminated histoplasmosis in only two case reports, both in immunocompromised patients. In the first, the patient had a new diagnosis of HIV in an area endemic to *H. capsulatum*, and was started on empiric Amphotericin B prior to diagnosis due to the high index of suspicion for disseminated histoplasmosis [8]. The patient made a full recovery. In the second, the patient was on immunosuppressants, and passed away prior to the

diagnosis of disseminated histoplasmosis or the initiation of treatment [9]. Unfortunately, the conditions in the present case were unfavourable, due in part to the underlying uncontrolled HIV and the delayed diagnosis of disseminated histoplasmosis. Furthermore, the patient developed progressive renal failure, likely related to Amphotericin B nephrotoxicity in the context of DIC. This triggered a change in therapy to a less nephrotoxic but less effective antifungal. Finally, the patient was not a candidate for reduction of immunosuppression or hemodialysis, both of which have been associated with positive outcomes in patients with thrombotic microangiopathy (TMA) secondary to disseminated histoplasmosis [10].

The morbidity and mortality of disseminated histoplasmosis is high, particularly so in patients with underlying HIV not controlled with HAART. The presence of extensive diagnostic uncertainty delayed treatment in the present case, potentially increasing the probability of mortality. The initial low index of suspicion – due to the broad differential diagnosis, lack of endemic precedence, and slow-growing cultures – delayed initiation of appropriate treatment.

Disseminated histoplasmosis is an opportunistic infection that is particularly detrimental to patients with HIV not adequately controlled with HAART. Early treatment with aggressive antifungals and appropriate adjuncts is essential to achieve positive outcomes. Infections without identifiable causative organisms in such patients should be strongly considered to be disseminated histoplasmosis in areas endemic to *H. capsulatum*, but should not be overlooked elsewhere. Local infection is possible in areas not previously considered endemic, and may be especially dangerous given the low index of suspicion and ensuing delayed diagnosis.

Funding

This research did not receive any specific grant from funding agencies in the public, commercial, or not-for-profit sectors.

CRedit authorship contribution statement

Jared L Cooper: Investigation, Writing – original draft, Writing – review & editing. **Aaron M Spring:** Investigation, Writing – original draft, Writing – review & editing. **David J Low:** Supervision, Writing – review & editing.

Disclosures

None.

Declaration of Competing Interest

The authors have no conflicts of interest to declare.

Ethics approval

As a case report, the present article is exempt from ethics approval from the Conjoint Health Research Ethics Board at the University of Calgary.

Consent

Written informed consent for this case report was obtained from the patient.

References

- [1] Tobón AM, Agudelo CA, Rosero DS, Ochoa JE, De Bedout C, Zuluaga A, et al. Disseminated histoplasmosis: a comparative study between patients with acquired immunodeficiency syndrome and non-human immunodeficiency virus-infected individuals. *Am J Trop Med Hyg* 2005;73(3):576–82.
- [2] Anderson H, Honish L, Taylor G, Johnson M, Tovstiuk C, Fanning A, et al. Histoplasmosis cluster, golf course, Canada. *Emerg Infect Dis* 2006;12(1):163–5.

- [3] Dingle TC, Croxen MA, Fathima S, Shokoples S, Sonpar A, Saxinger L, et al. Histoplasmosis acquired in Alberta, Canada: an epidemiological and genomic study. *Lancet Microbe* 2021;2:e191–7.
- [4] Adenis AA, Aznar C, Couppie P. Histoplasmosis in HIV-infected patients: a review of new developments and remaining Gaps. *Curr Trop Med Rep* 2014;1:119–28.
- [5] Madrigal-Jimenez HM, Hernandez-Rivera G. [Usefulness of bone marrow microscopic examination in HIV-infected patients with pancytopenia]. *Gac Med Mex* 2006;142(1):13–7.
- [6] Kim HK, Lee DS, Kang S-H, Kim JQ, Park S, Cho HI. Utility of the fibrinogen/C-reactive protein ratio for the diagnosis of disseminated intravascular coagulation. *Acta Haematol* 2007;117(1):34–9.
- [7] Wada H, Mori Y, Okabayashi K, Gabazza EC, Kushiya F, Watanabe M, et al. High plasma fibrinogen level is associated with poor clinical outcome in DIC patients. *Am J Hematol* 2003;72(1):1–7.
- [8] Nieto JF, Gomez SM, Moncada DC, Serna LM, Hidron AI. Successful treatment of hemophagocytic lymphohistiocytosis and disseminated intravascular coagulation secondary to histoplasmosis in a patient with HIV/AIDS. *Biomedica* 2016;36(0):9–14.
- [9] Mirza AS, Rodriguez VV. Cave diving for a diagnosis: disseminated histoplasmosis in the immunocompromised. *IDCases* 2018;12:92–4.
- [10] Dwyre DM, Bell AM, Siechen K, Sethi S, Raife TJ. Disseminated histoplasmosis presenting as thrombotic microangiopathy. *Transfusion* 2006;46(7):1221–5.