

CASE REPORT

Case Report of Ethanol and Cyanoacrylate Embolisation of a Recurrent Uncontrollable Torrentially Bleeding Arteriovenous Malformation of the Finger

Darius K.L. Aw^a, Hao-Yun Yap^a, Luke H.T. Tay^a, Kiang-Hiong Tay^b, Tze-Tec Chong^{a,*}

^aDepartment of Vascular Surgery, Singapore General Hospital, Singapore

^bDepartment of Vascular and Interventional Radiology, Singapore General Hospital, Singapore

Introduction: In general, arteriovenous malformations (AVMs) are extremely rare, with an incidence of only 1 in 100,000. They are rarer still in the hands and present variably with bleeding, heaviness, a pulsatile mass, pain, ulceration, or necrosis.

Report: The case of a 25 year old man with a rapidly bleeding right thumb AVM is presented. Bleeding was torrential and life threatening within a matter of seconds. He had previously undergone surgical ligation and embolisation twice at another centre, without success. At presentation, he had no thumb function and the bones of the thumb were exposed. An angio-embolisation was performed with ethanol and cyanoacrylate as the embolic agent. This was done using direct puncture into the AVM and also with a transarterial approach with microcatheters inserted into various unnamed branches feeding the AVM. Non-target embolisation and reflux was prevented by deploying a pneumatic tourniquet and mechanical elastic bands to confine the flow of the embolic agents within the AVM. Re-aspiration of the embolic agent post-embolisation was also performed to prevent local/systemic ethanol toxicity. Haemostasis was achieved without the need for further compression. A right thumb disarticulation was subsequently performed and the patient expressed great satisfaction with the outcome.

Discussion: AVMs in the hand are particularly challenging to treat owing to the need to preserve function of the myriad tissues and structural units that enable the many hand movements involved in activities of daily living. Even a partial loss of function may be disabling or poorly tolerated. The mainstays of treatment are embolisation, sclerotherapy, and surgical ligation/resection, all of which carry the potential for ischaemic injury to muscle and soft tissue. A holistic approach to management is desirable prior to selecting the appropriate management plan.

© 2018 The Authors. Published by Elsevier Ltd on behalf of European Society for Vascular Surgery. This is an open access article under the CC BY-NC-ND license (<http://creativecommons.org/licenses/by-nc-nd/4.0/>).

Article history: Received 15 January 2018, Revised 1 April 2018, Accepted 5 May 2018,

Keywords: Arteriovenous malformation, Cyanoacrylate glue, Endovascular, Ethanol embolisation, Hand

INTRODUCTION

Arteriovenous malformations (AVMs) are usually present at birth; however, not all of them are easily detectable clinically and can be affected by trauma, surgery, or hormonal alterations. They can occur on any part of the body, including the hand, which is the second most commonly affected site.¹

The treatment of hand AVMs includes conservative treatment, embolisation/sclerotherapy, surgical ligation, excision, and amputation. However, there is currently no consensus on treatment.

A case of a young man who was diagnosed with a congenital thumb AVM who failed initial treatment is reported. He subsequently underwent a repeat angio-embolisation, which successfully stopped the torrential AVM bleed.

CASE REPORT

A 25 year old man suffered swelling and bleeding from his right thumb. He lost the use of his thumb as he constantly required a heavy compression dressing to arrest the torrential haemorrhage (Fig. 1a). Despite previous ligation of his radial artery and multiple rounds of embolisation therapy, the bleeding was still not controlled.

At presentation, there was torrential, life threatening arterial bleeding, necrosis with exposed bone, and macerated skin from prolonged bandaging (Fig. 1b), as well as symptomatic anaemia. Given his late stage presentation, hand surgeons were insistent on a hand amputation.

* Corresponding author. Department of Vascular Surgery, Singapore General Hospital, Outram Road, 169608, Singapore.

E-mail address: chong.tze.tec@singhealth.com.sg (Tze-Tec Chong).

2405-6553/© 2018 The Authors. Published by Elsevier Ltd on behalf of European Society for Vascular Surgery. This is an open access article under the CC BY-NC-ND license (<http://creativecommons.org/licenses/by-nc-nd/4.0/>).

<https://doi.org/10.1016/j.ejvssr.2018.05.003>

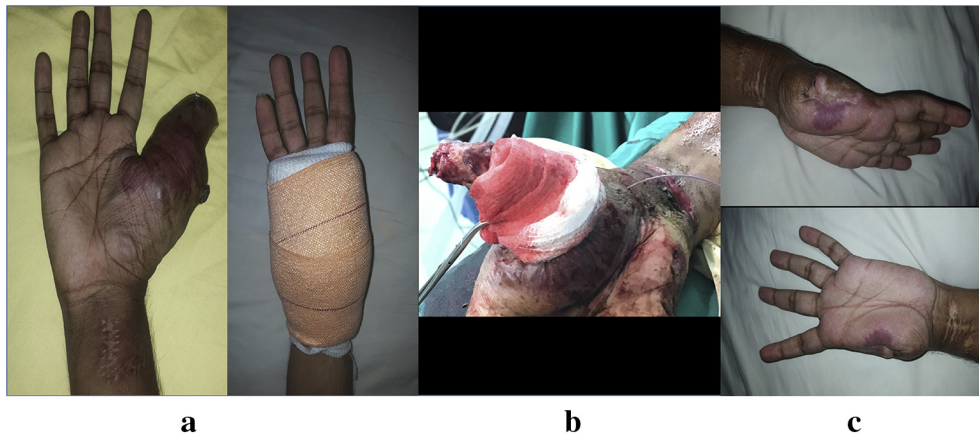


Figure 1. **a.** First presentation of AVM in 2014. The patient had open ligation of his radial artery and as well as embolization performed. Despite surgical and embolization therapy, bleeding was poorly controlled, requiring prolonged bandage over the right thumb as seen in the above picture. **b.** Subsequent presentation of AVM in 2017. Severe skin necrosis with bone exposure and torrential bleed were noted. **c.** 6 months post surgery with good wound healing and cessation of bleeding.

However, in view of the clinical urgency and the patient's social circumstances, further angio-embolisation was selected with the aim of securing definitive haemostasis, digit preservation, and the hope of preventing further recurrence.

The procedure was performed under general anaesthesia with a flat panel system (Artis Zeego, Siemens AG, Forchheim, Germany). The right brachial artery was cannulated in an antegrade manner under ultrasound guidance and a 4 Fr sheath was inserted. Baseline angiography was obtained for evaluation of the AVM and for selection of access route, transarterial, direct puncture, or both. A transarterial approach via the ulnar artery was performed using a 0.018 inch Terumo wire (Terumo, Somerset, NJ, USA) and a Berll catheter (Cordis, Miami Lakes, FL, USA). Diagnostic angiography revealed a previously ligated radial artery, feeding branches from the ulnar artery and palmar arches (Fig. 2a), as well as large draining veins (Fig. 2b).

Using the direct puncture method, a 21 G needle was directed into the prominent draining veins, checking back-flow of blood by gentle aspiration (Fig. 3a). To determine the volume and injection rates of ethanol, test injections of contrast media were used to fill the AVM without opacifying normal vessels. With a tourniquet (A.T.S 2000; Zimmer, Warsaw, IN, USA) inflated at 250 mmHg and mechanical elastic constrictors around the proximal phalanges to achieve vascular stasis (Fig. 2c), ethanol was injected with Lipiodol (Guerbet, Villepinte, France) into the AVM (Fig. 3b). Five minutes after ethanol injection, an angiogram was performed to evaluate the response to embolisation. However, a post-embolisation angiogram revealed suboptimal results with persistent contrast filling of the AVM (Fig. 3c).

The decision was made to repeat the embolisation with 20% cyanoacrylate glue (B. Braun, Melsungen, Germany) by mixing 2 mL lipiodol and 0.5 mL glue together with ethanol (Fig. 3d). A 2.7 Fr microcatheter (Terumo) was then super-selectively advanced via the digital artery of the index finger

to be within close proximity of the new nidus. Multiple runs of glue and ethanol were performed to achieve best results, with careful manipulation and repeat aspiration of remnant ethanol post-embolisation (Fig. 3e). A significant reduction in bleeding was achieved following these manoeuvres. In total, 10 mL ethanol and 0.5 mL cyanoacrylate glue was used.

A completion angiogram revealed no further collaterals to the AVM (Fig. 3f). The brachial artery sheath was removed and haemostasis was achieved by manual compression of the brachial artery puncture site.

Thereafter, the patient underwent a right thumb disarticulation 3 days later. He had recovered well 8 months post-surgery (Fig. 1c). He was able to regain good hand function, for example in driving and performing activities of daily living. His quality of life has significantly improved and the team is most happy with the outcome. Written informed consent was obtained from the patient for publication of this case report and accompanying images.

DISCUSSION

AVMs are congenital vascular malformations that can occur in any part of the body and may not be apparent in the early stages, especially on the digits. They are typically staged based on the Schobinger staging system and classified accordingly to the classification by the International Society for The Study of Vascular Anomalies.^{2,3}

Management of hand AVMs has been exceptionally challenging because of the functional complexity strictly related to the anatomy where many different tissues of high functional value are located in a small space. In digital AVMs, treatment is often indicated, especially so when the AVM involves the thumb, arguably the most important digit for finger opposition and hand function.

Endovascular techniques have been used in an attempt to maintain function without permanent disability or recurrence from reconstituted arterial flow from the nidus.

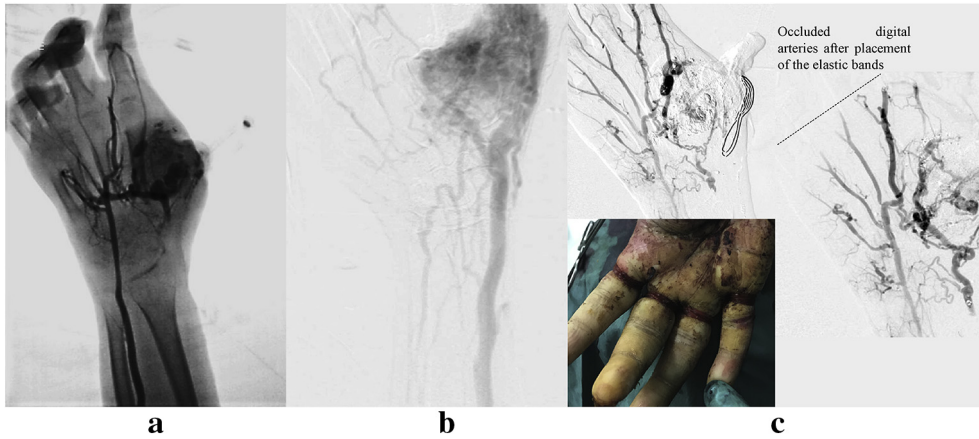


Figure 2. **a.** Baseline angiography was obtained for evaluation. An angiogram was obtained, revealing a previously ligated radial artery, feeding branches from the ulnar artery and palmar arches. **b.** Large draining veins. **c.** With a pneumatic tourniquet and elastic bands at the base of the phalanges as mechanical constrictors, vascular stasis was achieved to reduce reflux and non target embolization of the digital arteries.

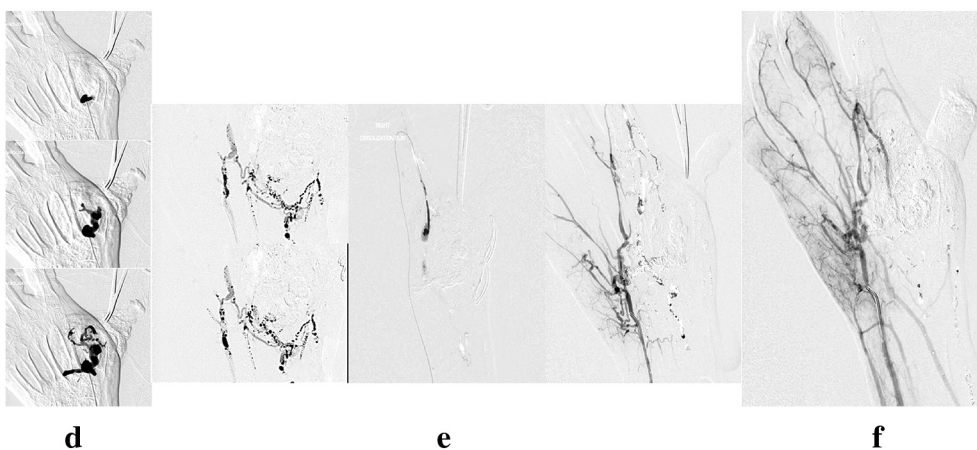
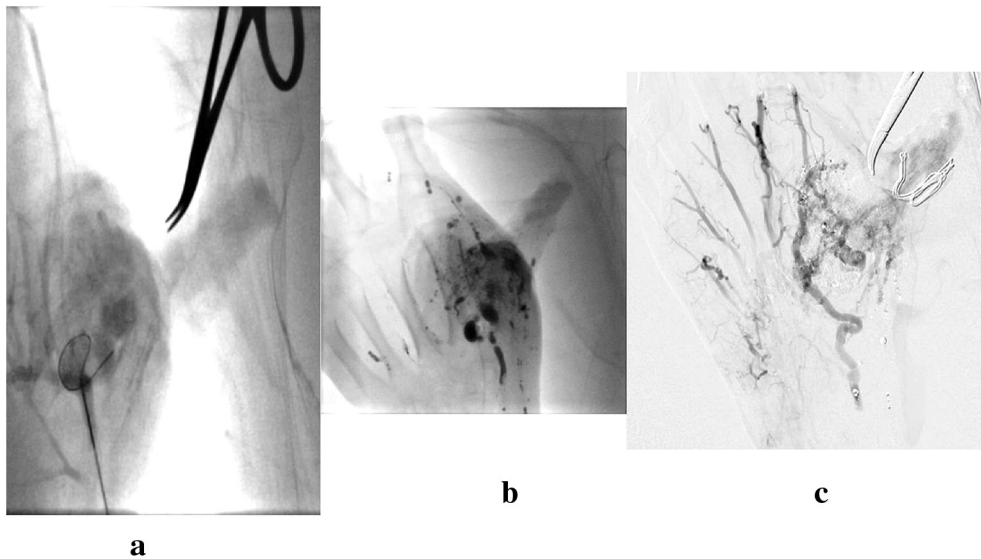


Figure 3. **a.** The prominent draining veins were punctured with a 21G needle. A 4Fr microcatheter guidewire was advanced to cannulate the nidus. **b.** Absolute ethanol with lipiodol in 1:1 ratio was injected and incubated in the AVM for 3–5mins. **c.** Post ethanol embolization angiogram revealed suboptimal results with persistent contrast filling of the AVM. **d.** Direct puncture and embolization with 20% cyanoacrylate glue and ethanol was repeated. **e.** Multiple runs of glue and ethanol embolization were performed via different approaches, i.e inferior approach with cannulation via ulnar artery/palmar arch, superior approach with placement of embolization catheter via the digital artery of the index finger. **f.** Post embolization check angiogram revealed no further feeding arteries or contrast enhancement.

Endovascular treatment options include embolisation, thermal ablation, and sclerotherapy. These have been advocated as an independent therapeutic modality or as an adjunctive therapy to surgery.⁴

Given the often complex nature of AVMs, it is sometimes difficult to achieve complete obliteration of the AVM, and multiple sessions may be required. Consequently, the choice of embolisation method is an important consideration. Use of glue or coils as embolic agents have been extensively described but are rarely curative, and also associated with complications. Glue has been shown to be a non-permanent embolic agent with evidence of recanalization and neovascular recruitment, even after complete occlusion.^{5,6} Coils have been placed in the AVM draining veins in hope of reducing arteriovenous shunting and the amount of ethanol required for obliteration, however results have been less than ideal.⁷ Known complications include pressure necrosis, poor wound healing, and coils being extruded from the wound requiring further surgical removal.⁴

Adding to the difficulties, controlling the level of occlusion with glue, is also challenging as this strategy runs the risk of catheter occlusion by the polymerised glue, resulting in abandonment of the catheter position before achieving complete vessel occlusion. This prevents administration of further treatment or may cause venous hypertension.

Ethanol ablation, however, commonly used in embolotherapy, has shown permanence in the management of AVM of the extremities and is effective for a large nidus in truncal, pelvic, and deep seated AVMs.^{8–10} This therapy is rendered less effective following non-target embolisation.

Non-target embolisation is not well tolerated in hand AVMs. Reflux into, or inevitable embolisation of, normal vessels in the hand will lead to blistering, skin necrosis, adjacent nerve injury, digital ischaemia, and gangrene.

Considering each approach, it was decided to adopt the simultaneous use of dual embolic agents, starting with glue followed by ethanol. Histoacryl consists of n-butyl-2-cyanoacrylate, a free monomer that polymerises when exposed to blood, forming a permanent cast in the blood vessel. The viscous property of cyanoacrylate glue is utilised to slow down the subsequent passage of the ethanol. This strategy helps limit the rapid spread of ethanol without the use of coils, yet allows adequate time for vessel wall damage and fibrosis with protein denaturation, thus reducing collateral tissue damage.

CONCLUSION

Digital AVMs are rare but are one of the most difficult of diseases to treat because the complication rates are high with, at best, acceptable treatment responses. Pre-

operative diagnostic angiography is important to identify the feeding vessels/nidus and to decide on the proper strategy with regard to the access route and choice of embolisation agents. Despite best efforts, many patients may still end up with digital amputations.

ACKNOWLEDGEMENTS

The authors thank the patient for his consent to use his clinical data.

CONFLICT OF INTEREST

None.

FUNDING

None.

REFERENCES

- 1 Moye SJ, Billmire DA. Congenital arteriovenous malformation of the finger resulting in cardiac decompression: a case report. *J Hand Surg Am* 1992;**17**:887–91.
- 2 Kohout MP, Hansen M, Pribaz JJ, Mulliken JB. Arteriovenous malformations of the head and neck: natural history and management. *Plast Reconstr Surg* 1998;**102**:643–54.
- 3 Lee BB, Baumgartner I, Berlien HP, Bianchini G, Burrows P, Do YS, et al. Current concepts on the management of arteriovenous malformations consensus document of the International Union Angiology (IUA) - 2013. *Int Angiol* 2013;**32**:9–36.
- 4 Yakes WF, Rossi P, Odink H. How I do it. Arteriovenous malformation management. *Cardiovasc Intervent Radiol* 1996;**19**:65–71.
- 5 Osuga K, Hori S, Kitayoshi H, Khankan AA, Okada A, Suguira T, et al. Embolization of high flow arteriovenous malformations: experience with use of superabsorbent polymer microspheres. *J Vasc Inter Radiol* 2002;**13**:1125–33.
- 6 Park HS, Do YS, Park KB, Kim DI, Kim YW, Kim MJ, et al. Ethanol embolotherapy of hand arteriovenous malformations. *J Vasc Surg* 2011;**53**:725–31.
- 7 Hashimoto Y, Matsuhiro K, Nagaki M, Tanioka H. Therapeutic embolization for vascular lesions of the head and neck. *Int J Oral Maxillofac Surg* 1988;**18**:47–9.
- 8 Do YS, Yakes WF, Shin SW, Lee BB, Kim DI, Liu WC, et al. Arteriovenous malformations of the body and extremities: analysis of therapeutic outcomes and approaches according to a modified angiographic classification. *J Endovasc Ther* 2006;**13**:527–38.
- 9 Bae S, Do YS, Shin SW, Choo IW. Ethanol embolotherapy of pelvic arteriovenous malformations: an initial experience. *Korean J Radiol* 2008;**9**:148–54.
- 10 Igari K, Kudo T, Toyofuku T, Jibiki M, Inoue Y. Surgical treatment with or without embolotherapy for arteriovenous malformations. *Ann Vasc Dis* 2013;**6**:46–51.