

Acute Pulmonary Embolism after Radiofrequency Catheter Ablation

Lan-Yan Guo, Zhong-Chan Sun, Dian-Xin Zhang, Bing Liu

Department of Cardiology, Xijing Hospital, Fourth Military Medical University, Xi'an, Shaanxi 710032, China

To the Editor: Radiofrequency catheter ablation (RFCA) is the first-line therapy for symptomatic paroxysmal supraventricular tachycardia. However, several life-threatening complications remain underestimated. Herein, we report an atypical case of RFCA complicated by acute pulmonary embolism (PE), an extremely rare but potentially fatal complication. After 3 months of anticoagulation therapy, PE was treated successfully.

A 47-year-old female patient weighing around 74 kg with a body mass index of 29.6 kg/m² suffered from hypertension and hyperlipidemia for several years without family histories of thromboembolic diseases and complained about intermittent palpitation for 2 years. Electrocardiography (ECG) showed a regular narrow QRS tachycardia. In admission, blood pressure (BP) was 180/140 mmHg and physical examination showed a normal heart rate and heart sound without heart murmurs. There were no signs of deep venous thrombosis (DVT). Echocardiography, ECG, and chest X-ray showed no abnormal signs before intracardiac electrophysiologic study (EPS). Aspirin (100 mg once daily) and atorvastatin (20 mg once nightly) were prescribed. With antihypertensive therapy, the patient maintained a stable and normal BP (120/70 mmHg). She received an EPS and orthodromic atrioventricular reentrant tachycardia was induced, with the earliest retrograde atrial activation recorded at the distal coronary sinus electrode, which distributed in an eccentric pattern. After an injection of 3700 units of heparin, RFCA was performed successfully over the anterior aspect of the mitral annulus (2 o' clock) through femoral artery, eliminating the accessory pathway uneventfully. The total procedure lasted for 35 min. The punctured sites in the right inguinal area were manually compressed for 15 min to stop the bleeding, followed by bandaging techniques for 10 h and a 1-kg sandbag compression for 2 h.

One day later, she complained about a chest distress. Her BP was 100/60 mmHg, and neither her ECG nor echocardiogram showed noteworthy abnormalities. Arterial blood gas examination showed a PaO₂ of 65 mmHg and oxygen saturation of 93%. Pneumothorax was ruled out by a normal chest X-ray. In the muscular veins of the right calf, thrombosis was observed by color Doppler ultrasonography. D-dimer was elevated to 4.53 mg/L FEU (reference range, 0–0.6 mg/L FEU). The possibility of acute PE was suspected and chest computed tomography (CT) with contrast medium revealed bilateral filling defects, primarily

located between the left main pulmonary and the left descending pulmonary artery [Figure 1a]. Low-molecular-weight heparin calcium (0.1 U/10 kg, twice daily) was administered for 5 days. Meanwhile, warfarin was also prescribed for 2 weeks. The patient was discharged without any discomfort. During the hospital stay, thrombophilic workup showed negative findings. The patient was put on warfarin for another 2.5 months and was event-free during the follow-up period. Finally, chest CT revealed dissolution of the PE [Figure 1b].

Acute PE, an extremely rare but potentially fatal complication of RFCA, can present atypical clinical signs causing it to be easily misdiagnosed or missed.^[1] Multiple intracardiac catheters through venous sheaths that are inserted into a single femoral vein are often necessary for EPS and RFCA. Chen *et al.*^[2] reported significant incidences (17.6%) of nonocclusive and asymptomatic DVT developments on the next day following EPS or RFCA. However, thrombosis regressed after 1 week for all cases except for one: The patient had persistent nonocclusive DVT while the venous diameter remained the same, showing no signs of thrombus progression at follow-up.

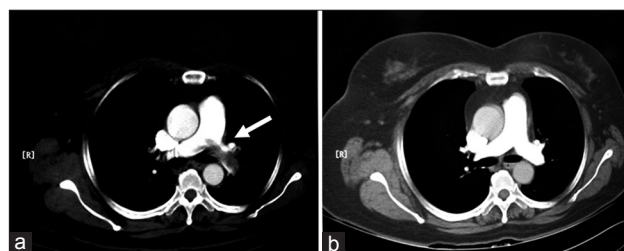


Figure 1: Chest computed tomography with contrast medium: the arrow pointing to the filling defects 1 day later after radiofrequency catheter ablation (a) and the dissolution of pulmonary embolism after 3 months of anticoagulation therapy (b).

Address for correspondence: Dr. Bing Liu,

Department of Cardiology, Xijing Hospital, Fourth Military Medical University, Xi'an, Shaanxi 710032, China
E-Mail: bpwliu@163.com

Access this article online

Quick Response Code:



Website:
www.cmj.org

DOI:
10.4103/0366-6999.204105

This is an open access article distributed under the terms of the Creative Commons Attribution-NonCommercial-ShareAlike 3.0 License, which allows others to remix, tweak, and build upon the work non-commercially, as long as the author is credited and the new creations are licensed under the identical terms.

© 2017 Chinese Medical Journal | Produced by Wolters Kluwer - Medknow

Received: 03-02-2017 **Edited by:** Yuan-Yuan Ji

How to cite this article: Guo LY, Sun ZC, Zhang DX, Liu B. Acute Pulmonary Embolism after Radiofrequency Catheter Ablation. *Chin Med J* 2017;130:1006-7.

In our case, the overweight female suffered from hyperlipidemia and remained immobilized for 10 h after the RFCA procedure. Furthermore, one 6-French sheath was inserted into the right femoral vein, ipsilateral to a 7-French femoral artery sheath. Hemostasis of the femoral artery sheath for 10 h may also compress the femoral vein simultaneously, leading to venous injury and stasis, which may be responsible for the formation of right calf muscular venous and subsequent PE. Since the report of this case, a series of preliminary clinical observations^[3] have been done, and the bandage immobilization time on bed after RFCA has also been shortened to 4 and 2 h through the femoral artery and vein at our center, respectively. To date, no reports of PE have occurred.

The report of this case aimed to increase the awareness of RFCA complicated by PE, especially for patients with absence of typical symptoms and signs. Although PE can be fatal, it is often curable if being recognized promptly. Moreover, the shortened removing time of bandage may help reduce the risk of PE and improve comfort of the patient after the procedure.

Financial support and sponsorship

Nil.

Conflicts of interest

There are no conflicts of interest.

REFERENCES

1. Xu M, Shi CM, Li J, Wang J, Guo XY. Massive pulmonary embolism in recovery period of general anesthesia: Rapid diagnosis and successful rescue by the guidance of transthoracic echocardiography. *Chin Med J* 2017;130:245-46. doi: 10.4103/0366-6999.198020.
2. Chen JY, Chang KC, Lin YC, Chou HT, Hung JS. Safety and outcomes of short-term multiple femoral venous sheath placement in cardiac electrophysiological study and radiofrequency catheter ablation. *Jpn Heart J* 2004;45:257-64. doi: 10.1536/jhj.45.257.
3. Guo L, Zhang D, Cheng H, Shen M, Yi F, Wu F, *et al*. Relationship between complications and the time of the compression bandage on femoral vein after radiofrequency ablation diagnosed as supraventricular tachycardia (in Chinese). *Chin J Card Pacing Electrophysiol* 2016;30:513-6. doi: 10.13333/j.cnki.cjcpe.2016.06.011.