



REVIEW

Donor-Derived Leukemia in a Recipient of Double-Unit Cord Blood Transplantation for Acute Myeloid Leukemia: A Case Study and Literature Review

Adriana Plesa · Isabelle Tigaud · Sandrine Hayette · Christophe Roumier · Xavier Thomas

Received: October 15, 2021 / Accepted: December 2, 2021 / Published online: February 7, 2022
© The Author(s) 2022

ABSTRACT

We report a case of donor-derived leukemia (DDL) occurring 34 months after double-unit cord blood transplantation (CBT). Molecular analysis using short tandem repeat (STR) sequences proved the acute myeloid leukemia (AML) to be of dominant cord blood origin. Karyotype was normal and molecular analysis showed *WT1* and *EVII* overexpression. Cytological and molecular remission were achieved with only induction and consolidation chemotherapy. Relapse occurred after 6 years of

remission from one clone with only *WT1* overexpression. Potential etiologies for donor cell leukemogenesis in the recipient are discussed, including occult leukemia in the donor or genetic predisposition to hematologic malignancies, impaired immune surveillance, induced or inherited stromal abnormalities, transformation of donor cells during engraftment via altered signals of the host tissues, and fusion of donor cells with residual leukemic cells leading to acquisition of oncogenes. Although cases of DDL occurring after umbilical CBT have already been reported, very few cases have been described arising after double-unit CBT. DDL cases following CBT previously described in the literature have been reviewed.

A. Plesa
Laboratoire d'Hématologie Cellulaire-
Immunophénotypage Des Hémapathies, Hospices
Civils de Lyon, Hôpital Lyon-Sud, Lyon, France

I. Tigaud
Laboratoire de Cytogénétique, Hospices Civils de
Lyon, Hôpital Lyon-Sud, Lyon, France

S. Hayette
Laboratoire de Biologie Moléculaire, Hospices Civils
de Lyon, Hôpital Lyon-Sud, Lyon, France

C. Roumier
Laboratoire d'Hématologie, Centre Hospitalier
Régional Universitaire de Lille, Lille, France

X. Thomas (✉)
Service d'Hématologie Clinique, Hematology,
Hospices Civils de Lyon, Lyon-Sud Hospital, Pierre-
Bénite cedex, Bat.1G, 165 chemin du Grand
Revoyet, 69495 Lyon, France
e-mail: xavier.thomas@chu-lyon.fr

Keywords: Acute myeloid leukemia; Donor-derived leukemia; Double-unit cord blood transplantation; Dysmyelopoiesis; Treatment

Key Summary Points

Donor-derived leukemia in a recipient of allogeneic hematopoietic stem cell transplantation is a rare entity.

A few cases were described in recipients after umbilical cord blood transplantation.

We report the first case of donor-derived leukemia occurring after double-unit cord blood transplantation.

Although no clear explanation for this post-transplant complication have been determined, multiple mechanisms have been proposed including donor cell intrinsic factors and host extrinsic factors.

Donor-derived leukemia should provide insights into the process of leukemogenesis.

INTRODUCTION

Allogeneic hematopoietic stem cell transplantation (HSCT) remains an attractive and effective option for the treatment of acute myeloid leukemia (AML). Donor-derived leukemia (DDL) in a recipient of allogeneic hematopoietic stem cell transplantation (HSCT) is a rare entity. Since the first description in 1971 by Fialkow et al. [1], more than 80 cases have been reviewed in the literature [2]. In recent years, cord blood has emerged as a feasible source of hematopoietic progenitor cells for allogeneic HSCT, especially applicable to patients who lack a human leukocyte antigen (HLA)-matched marrow donor. Among reported DDL, a few cases have been described in recipients after umbilical cord blood transplantation (UCBT) (Tables 1 and 2) [2–12].

Here we report one case of DDL in a patient with AML who developed a novel AML after receiving unrelated double-unit CBT (Fig. 1), which allows adults to proceed to allogeneic

SCT with this donor type when a single adequately dosed unit is not available.

CASE PRESENTATION

A previously healthy 38-year-old Turkish woman was diagnosed in April 2007 with French-American-British (FAB) type 4 AML after presenting with pulmonary embolism and blood count disturbances (initial white blood cell count: 8.9 G/L with 27% blast cells; hemoglobin level: 122 g/L; platelet count: 83 G/L). Bone marrow (BM) aspirate showed 60% blasts and dysplastic changes involving the granulocytic and megakaryocytic lineages. Immunophenotypic analysis on BM blasts showed the following profile: CD13⁺ CD33⁺ CD117⁺ MPO⁺/CD34⁻ CD38⁺⁺ HLADR⁺/CD36⁻ CD14⁻ CD11c⁺ CD4⁻ CD15^{+/-} CD65^{+/-} aberrant expression of CD7^{dim} (Fig. 2). Conventional cytogenetics was a failure. Molecular biology analyses showed *NPM1* mutation and *WT1* overexpression. *CBFB*, *FLT3*, *MLL*, *EVI1*, and *IDH1/2* were negative. After giving written informed consent, she was enrolled in the ALFA9802 trial (NCT00880243), which was conducted in accordance with the Declaration of Helsinki [13]. She received induction chemotherapy consisting of a timed-sequential chemotherapy that included a first sequence combining daunorubicin (80 mg/m² per day, intravenously on days 1–3) and cytarabine (500 mg/m² per day, continuous intravenous infusion over the same period). The second sequence, administered after a 4-day free interval, consisted of mitoxantrone (12 mg/m² per day, intravenously on days 8 and 9) and cytarabine (500 mg/m² per 12-h bolus intravenous infusion on days 8–10). Complete remission (CR) was achieved in May 2007. Because of complications such as hepatosplenic candidiasis and the absence of immediate suitable donor availability, she was then assigned to two consolidation courses consisting of high-dose cytarabine (HD-AraC) cycles (3 g/m² per 12 h intravenously on days 1, 3, and 5). BM biopsy performed after the second cycle of HD-AraC confirmed the absence of blast cells but hypoplastic marrow explaining a medullar

Table 1 Review of the literature: characteristics of patients affected by DDL after CBT

Reference	Age at DDL	Primary diagnosis	Donor	GvHD	Time from CBT to DDL (years)
Engel [3]	45	ALL	Haplo	No	1.33
	17	AML	UD	Yes (a G2)	4.54
	35	CML	UD	No	1.44
	21	Fanconi	UD	Yes (a G1)	2.12
Wang [2]	4	AML	UD	No	1.20
	57	CLL/MDS	UD	No	0.50
	23	AML/MDS	UD	Yes	0.41
Fraser [5]	4	LCH	UD	No	3.33
Nagamura-Inoue [10]	33	AML	UD	Yes (a G2)	1.25
	31	Unknown	UD	Yes (a G3)	1.33
Ando [6]	33	AML	UD	Yes (a G3)	0.91
Matsunaga [4]	57	ATL	UD	No	0.58
Mitsui [8]	41	ALL Ph ⁺	UD	No	0.41
Hamaki [9]	32	HL	UD	Yes (a G3)	1.41
Sevilla [7]	5	AML	UD	No	0.25
Kusumoto [11]	59	AML	UD	No	0.83
Cotter [12]	25	ALL	2 UD _s	Yes (a, c)	4.00
Our case	40	AML	2 UD _s	No	2.80

a acute; *ALL* acute lymphoblastic leukemia; *AML* acute myeloid leukemia; *ATL* chronic-type adult T-cell lymphoma; *c* chronic; *CLL* chronic lymphocytic leukemia; *CML* chronic myeloid leukemia; *DDL* donor-derived leukemia; *G* grade; *GvHD* graft-versus-host disease; *Haplo* haploidentical; *HL* Hodgkin lymphoma; *LCH* Langerhans cell histiocytosis; *MDS* myelodysplastic syndrome; *UD* unrelated donor; *Ph⁺* Philadelphia chromosome-positive

origin for persisting cytopenias. The patient finally underwent double HLA loci-mismatched unrelated UCBT [(cord 1: male sex; 3.11×10^7 nucleated cells/kg; 1.33×10^5 CD34 cells/kg) and (cord 2; female sex; 1.91×10^7 nucleated cells/kg; 0.4×10^5 CD34 cells/kg)] in molecular remission in March 2008 after a myeloablative preparative conditioning regimen combining anti-thymocyte globulin (ATG) (2.5 mg/kg/day from day -8 to day -5), cyclophosphamide 60 mg/kg/day on days -6 and -5, and fractionated total body irradiation (TBI) (12 Gy) from day -3 to day -1. Graft-versus-host disease (GvHD) prophylaxis consisted of cyclosporine and steroids. Neutrophil engraftment

was confirmed by short tandem repeat (STR) analysis on day 46 post-transplant, although intermittent granulocyte colony-stimulating factor (G-CSF) therapy was required. Cyclosporine was discontinued 6 months after transplantation with no evidence of GvHD. She however developed non-hemorrhagic cystitis caused by BK virus, resolved under cidofovir therapy. After engraftment, complete donor chimerism was rapidly achieved, minimal residual disease was negative, and hematopoiesis was only mediated by a single dominant unit (cord 2) from month 6 post-transplant (Fig. 3).

Table 2 Review of the literature: DDL characteristics and outcome

Reference	DDL diagnosis	Tests to confirm DDL	DDL treatment	Patient outcome	Survival from DDL (months)
Engel [3]	AML	VNTR/STR	Chemo	Dead	7
	AML	VNTR/STR	HSCT	Dead	13
	AML	HLA/FISH	Unknown	Dead	1
	AML	VNTR/STR	Chemo	Dead	6
Wang [2]	AML	STR/FISH	Chemo	Dead	11
	MDS	STR	No treatment	Alive	28+
	MDS	FISH	No treatment	Alive	9+
Fraser [5]	AML	G-band/VNTR	Chemo	Dead	10
Nagamura-Inoue [10]	AML	FISH	Unknown	Unknown	Unknown
	AML	STR	Unknown	Unknown	Unknown
Ando [6]	AML	STR	Chemo/HSCT	Dead	Unknown
Matsunaga [4]	AML	FISH/STR	No treatment	Dead	8.6
Mitsui [8]	MPD	Karyotype	Unknown	Unknown	Unknown
Hamaki [9]	AML	Karyotype	Chemo	Dead	13
Sevilla [7]	MDS	FISH/STR	No treatment	Alive	24+
Kusumoto [11]	LGLL	STR	No treatment	Dead	0.23
Cotter [12]	MDS	FISH/STR	Azacitidine	Unknown	Unknown
Our case	AML	STR	Chemo	Dead	78

AML acute myeloid leukemia; *Chemo* chemotherapy; *DDL* donor-derived leukemia; *FISH* fluorescence in situ hybridization; *G-band* G-band polymorphism; *HLA* human leukocyte antigen typing; *HSCT* hematopoietic stem cell transplantation; *LGLL* T-cell large granular lymphocyte leukemia; *MDS* myelodysplastic syndrome; *MPD* chronic myeloproliferative disease; *STR* short tandem repeats; *VNTR* variable number of tandem repeats

Thirty-four months after UCBT, the patient presented with cytopenias. BM examination revealed 55% of blasts with morphologic features of monocytic AML with multilineage dysplasia. Immunophenotyping revealed a distinct population from the initial malignant cells within the blast gate: CD13⁺⁺ CD33^{+/-} CD117^{+/-} MPO^{+/-} CD34^{+/-} CD38⁺⁺ HLADR⁺ CD36^{+/-} CD14^{+/-} CD15^{+/-} CD65^{+/-} aberrant expression of CD7 and CD19 (Fig. 2). Cytogenetic and molecular studies were undertaken and showed a normal karyotype and persistence

of *WT1* overexpression, loss of *NPM1* mutation, and acquisition of *EVII* overexpression. STR analysis of the BM cells showed that atypical cells were completely of the donor type (cord 2) (Fig. 3). The patient achieved complete remission following reinduction chemotherapy combining idarubicin 10 mg/m²/day for 3 days with cytarabine 1000 mg/m²/12 h for 6 days [14], but at the cost of tetraparesis following a prolonged stay in the intensive care unit for multi-organ candidiasis. She then received only maintenance therapy with 6 monthly cycles

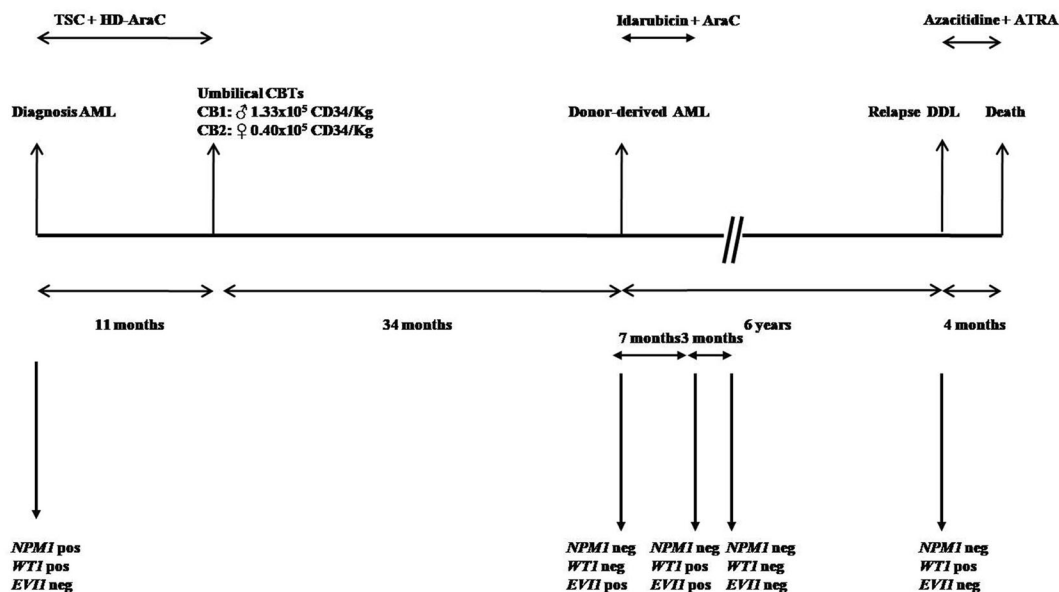


Fig. 1 Timeline of diagnosis, treatment and molecular marker evolution. Abbreviations: AML, acute myeloid leukemia; AraC, cytarabine; ATRA, all-*trans*-retinoic acid; CB1, cord blood 1; CB2, cord blood 2; CBT, cord blood transplantation; DDL, donor-derived leukemia; HD-

AraC, high-dose cytarabine; TSC, timed sequential chemotherapy

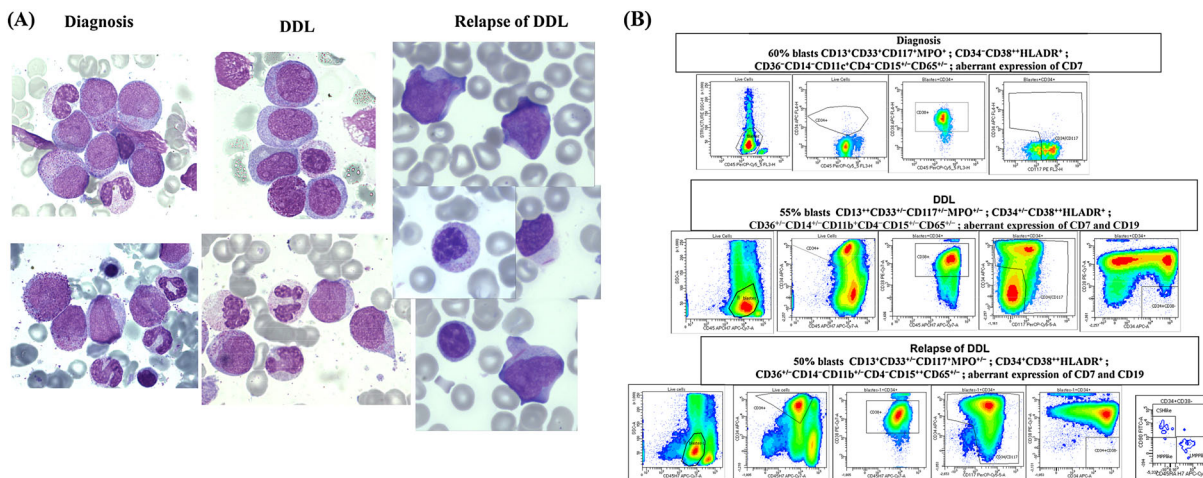
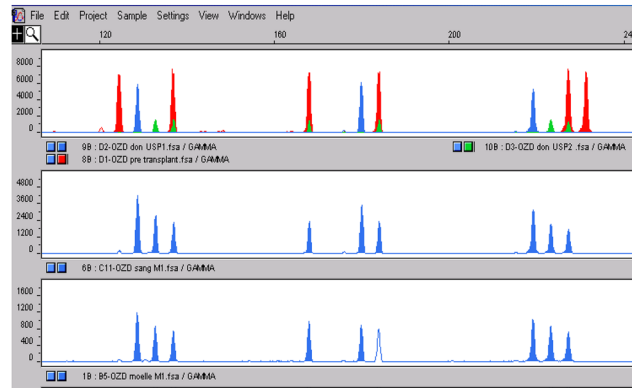


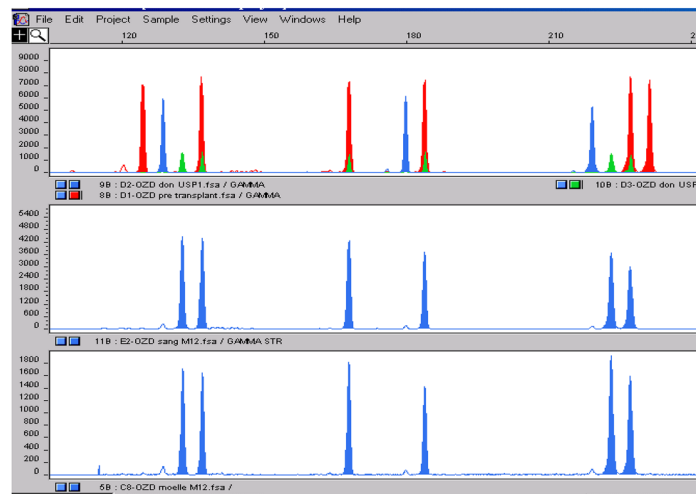
Fig. 2 Morphologic and immunophenotypic features of leukemic cells at time of diagnosis, time of DDL, and time of DDL relapse. (A) Diagnosis: Medium-sized blast cells with fine chromatin, partly nucleated and sometimes with irregular nucleoli. The cytoplasm is moderately abundant, with little or no granulations, and very rare blast with Auer rods. Some of the blasts suggest a monocytic differentiation. DDL: Myeloid blasts with clear monocytic differentiation. Hematopoietic lineages are present with subtle

granulocytic and megakaryocytic abnormalities. Relapse of DDL: Blasts of small to medium size with moderately basophilic cytoplasm, most often containing fine granulations and regularly one or more Auer rods. The nucleus is often irregular, with fine nucleated chromatin. (B) Flow cytometry graphs showing various leukemic stem cell expression at time of diagnosis, DDL and relapse of DDL

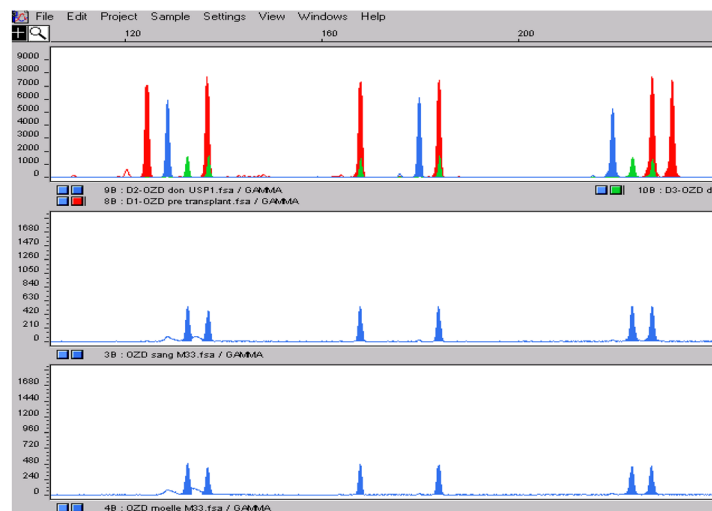
(A) Total donor chimerism: expression of both CB units (CB1 and CB2)



(B) Total donor chimerism: only expression of CB2.



(C) Total donor chimerism: only expression of CB2.



◀**Fig. 3** Assessment of donor chimerism. Profiles of informative STR PCR products (sensitivity threshold 5%) at the time of engraftment (A), month 12 post-transplant (B), and month 34 post-transplant (C). (Top rows show profiles before transplantation: recipient in red, CB1 in blue, and CB2 in green; middle rows show chimerism on blood; bottom rows show chimerism on BM)

combining idarubicin 10 mg/m² on day 1 with cytarabine 100 mg/m²/day, subcutaneously, from days 1 to 5.

Six years after treatment of DDL, she again developed cytopenias. BM examination and immunophenotyping confirmed a relapse of DDL with 50% blasts (Fig. 2). Overexpression of *WT1* persisted, but *EVII* expression was lost. BM cells were predominantly (99%) derived from the unrelated donor (cord 2) as confirmed by STR. Because of a poor physical condition, she was not treated intensively and only received cycles combining azacitidine with all-*trans*-retinoic acid [15]. She died from infectious complications 4 months after relapse.

DISCUSSION

DDL is a rare complication of allogeneic HSCT. However, its real incidence remains unclear. A recent survey from the European Society for Blood and Marrow Transplantation (EBMT) estimated a DDL prevalence of 80.5 cases per 100,000 transplants and a cumulative incidence at 5, 10, and 25 years after HSCT of 0.067%, 0.132%, and 0.363%, respectively [3]. However, this incidence is likely underestimated. The number of described cases has increased over the last decade, suggesting that aggression to BM stroma by peritransplant factors can contribute to leukemia development [16]. A recent observation has even reported multiple DDLs in an individual patient [17]. DDLs have been observed not only after transplantation with progenitor cells from BM and peripheral blood, but also after CBT. About 20% of reported cases were diagnosed in recipients who received umbilical CBT [2]. Overall, the rate of DDL in UCBT recipients seemed to be potentially

higher than that after other stem cell sources [2, 3]. DDLs have mainly been reported after transplantation with a sole umbilical unit. Only one prior case of DDL has been reported following a double-unit CBT [12]. However, ours is the first reported case of a patient with a history of AML who developed DDL after double-unit CBT.

Challenges often remain in confirming the donor origin of malignant cells, especially when the abnormal cells represent only a small fraction of BM cells. If historically the methods used to demonstrate donor origins of leukemia have been based on standard cytogenetics or fluorescence in situ hybridization (FISH) techniques in recipients with sex-mismatched transplants and Southern blot analysis for restriction fragment length polymorphism to test donors and recipients for specific genomic variations, more quantitative methods, including polymerase chain reaction (PCR-based) variable number of tandem repeats (VNTR) and STR analysis, are now currently routinely used [18]. In our case report, molecular analysis using STR proved the de novo leukemia to be of cord 2 origin. The infused CD34⁺ cell dose of the engrafting unit has been shown to determine the speed and success of neutrophil engraftment after double-unit CBT [19]. However, in our case, the percentage of CD34⁺ cells was not associated with unit dominance.

There is currently no clear explanation for this post-transplant complication. However, studying DDL should provide insights into the process of leukemogenesis. Multiple mechanisms have been proposed including donor cell intrinsic factors and host extrinsic factors, but DDL may result from a combination of donor- and recipient-related factors [20]. Occult leukemia in the donor or genetic predisposition to hematologic malignancies are a rare form of DDL but might be favored by the current use of older people as donors. Other described mechanisms include impaired immune surveillance, induced or inherited stromal abnormalities, transformation of donor cells during engraftment via altered signals of the host tissues, and fusion of donor cells with residual leukemic cells leading to acquisition of oncogenes [20, 21]. The Epstein-Barr virus-mediated post-

transplant lymphoproliferative disorder occurring in allogeneic HSCT recipients represents an example of an extrinsic factor able to contribute to an oncogenic transformation arising in HSCT recipients [22]. In the case of DDL following CBT, induced BM stroma abnormalities seem the most likely mechanism of action associated with previous chemotherapy, conditioning regimen with TBI, or post-transplant events [16].

The latency period between transplantation and the occurrence of DDL is an important parameter for the study of its pathogenesis. In CBT, this interval ranged from 0.25 to 4.54 years (median: 1.23 years). A significantly shorter latency has been shown in UCBT recipients in comparison with BM recipients [2]. Because of this shorter latency and the multi-step process of leukemia development, it appears unlikely that undetected potential malignant or pre-leukemic clones were transferred from CB to patient. Furthermore, no cases of leukemia were further reported in donors. A higher proportion of DDL cases with dysplastic features have been described in UCBT recipients compared to BM recipients [2]. Damaged marrow stroma with defective microenvironment, involved in the development of AML/MDS and potentially exacerbated by antigenic or viral stimulation [23], seems more likely in the case of DDL following CBT. In our case report, the fact that the initial diagnosis of AML involved signs of cell dysplasia suggests that this engendered DDL occurrence. Furthermore, our patient received an alkylating agent- and TBI-containing conditioning regimen, which could have influenced an already damaged marrow stroma and a mutagenic microenvironment. Genomic instability related to telomere shortening and early application of growth factors have been observed in recipients after allogeneic HSCT [24]. Although our patient survived 78 months from the diagnosis of DDL, overall survival in most documented cases from the literature remained poor, ranging from 1 month to 28+ months (Table 1). Immunomodulatory dysfunction and immunosuppression could also participate here in DDL development. T lymphocytes in CB are almost exclusively naïve and characterized by

an immature status compared to those derived from BM or mobilized peripheral blood stem cells. They may therefore contribute to the reduced immune tumor surveillance. In the case of double-unit CBT, unit–unit HLA match could influence transplantation outcomes such as GvHD or relapse. Unit dominance is related to immune interactions between the two units [25]. We can hypothesize that less closely HLA-matched units could result in an enhanced unit-versus-unit immune response with potential consequences on cell transformation in a setting of defective microenvironment.

CONCLUSIONS

Although DDL after HSCT is a rare entity, it should be kept in mind that it is a potential and severe side effect of HSCT with progenitor cells from BM and peripheral blood transplantation, but also transplantation with CB units. In our case of DDL arising in a patient with AML after receiving unrelated double-unit CBT, the mechanisms involved are not clearly evident, but probably multifactorial. It seems unlikely that malignant or pre-leukemic clones were transferred from CB to patient. On the other hand, the presence of dysplastic features suggests the involvement of damaged marrow stroma with defective microenvironment, potentially favored by immunomodulatory dysfunction. Further investigations are still needed to better understand the mechanisms in this type of leukemogenesis.

ACKNOWLEDGEMENTS

We thank all physicians who participated to the treatment of our patient. We thank Valérie Dubois from the Etablissement Français du Sang Auvergne Rhône-Alpes, who provided chimerism data.

Funding. No funding or sponsorship was received for publication of this article.

Authorship. All named authors meet the International Committee of Medical Journal

Editors (ICMJE) criteria for authorship for this article, take responsibility for the integrity of the work as a whole, and have given their approval for this version to be published.

Author Contributions. Adriana Plesa: analyzed and interpreted data, and was responsible for coordinating immunophenotyping data. Isabelle Tigaud: was responsible for coordinating cytogenetic data. Sandrine Hayette: was responsible for coordinating molecular biology. Christophe Rournier: interpreted immunophenotypic data. Xavier Thomas: participated to therapy, decision making and patient care, analyzed and interpreted data, and wrote the manuscript.

Disclosures. The authors (Adriana Plesa, Isabelle Tigaud, Sandrine Hayette, Christophe Rournier, Xavier Thomas) have nothing to disclose and declare no competing financial interests.

Compliance with Ethics Guidelines. The patient involved in this trial provided written informed consent, and was enrolled in the ALFA9802 trial (NCT00880243). This study was conducted in accordance with the Declaration of Helsinki.

Data Availability. Data sharing is not applicable to this article as no datasets were generated or analyzed during the current study.

Open Access. This article is licensed under a Creative Commons Attribution-NonCommercial 4.0 International License, which permits any non-commercial use, sharing, adaptation, distribution and reproduction in any medium or format, as long as you give appropriate credit to the original author(s) and the source, provide a link to the Creative Commons licence, and indicate if changes were made. The images or other third party material in this article are included in the article's Creative Commons licence, unless indicated otherwise in a credit line to the material. If material is not included in the article's Creative Commons licence and your intended use is not permitted by statutory regulation or exceeds the permitted use, you

will need to obtain permission directly from the copyright holder. To view a copy of this licence, visit <http://creativecommons.org/licenses/by-nc/4.0/>.

REFERENCES

1. Fialkow PJ, Thomas ED, Bryant JI, Neiman PE. Leukaemic transformation of engrafted human marrow cells in vivo. *Lancet*. 1971;6:251–5.
2. Wang E, Hutchinson CB, Huang Q, Lu CM, Crow J, Wang FF, et al. Donor cell-derived leukemias/myelodysplastic neoplasms in allogeneic hematopoietic stem cell transplant recipients. A clinicopathologic study of 10 cases and a comprehensive review of the literature. *Am J Clin Pathol*. 2011;135:525–540.
3. Engel N, Rovo A, Badoglio M, Labopin M, Basak GW, Beguin Y, et al. European experience and risk factor analysis of donor cell-derived leukaemias/MDS following haematopoietic cell transplantation. *Leukemia*. 2019;33:508–17.
4. Matsunaga T, Murase K, Yoshida M, Fujimi A, Iyama S, Kuribayashi K, et al. Donor cell derived acute myeloid leukemia after allogeneic cord blood transplantation in a patient with adult T-cell lymphoma. *Am J Hematol*. 2005;79:294–8.
5. Fraser CJ, Hirsch BA, Dayton V, Creer MH, Neglia JP, Wagner JE, et al. First report of donor cell-derived acute leukemia after transplantation of umbilical cord blood transplantation. *Blood*. 2005;106:4377–80.
6. Ando T, Yujiri T, Mitani N, Takeuchi H, Nomiya J, Siguchi M, et al. Donor cell-derived acute myeloid leukemia after unrelated umbilical cord blood transplantation. *Leukemia*. 2006;20:744–5.
7. Sevilla J, Querol S, Molines A, Gonzalez-Vicent M, Balas A, Carrio A, et al. Transient donor cell-derived myelodysplastic syndrome with monosomy 7 after unrelated cord blood transplantation. *Eur J Haematol*. 2006;77:259–63.
8. Mitsui H, Nakazawa T, Tanimura A, Karasuno T, Hiraoka A. Donor cell-derived chronic myeloproliferative disease with t(7;11)(p15;p15) after cord blood transplantation in a patient Philadelphia chromosome-positive acute lymphoblastic leukemia. *Int J Hematol*. 2007;86:192–5.
9. Hamaki T, Kajiwara K, Kami M, Murashige N, Funaki M, Harima A, et al. Donor cell-derived acute monoblastic leukemia involving MLL gene

- translocation in an adult patient who received umbilical cord blood transplantation. *Bone Marrow Transplant.* 2008;41:91–2.
10. Nagamura-Inoue T, Kodo H, Takahashi TA, Mugishima H, Tojo A, Asano S. Four cases of donor cell-derived AML following unrelated cord blood transplantation for adult patients: experiences of the Tokyo Cord Blood Bank. *Cytotherapy.* 2007;9:727–728.
 11. Kusumoto S, Mori S, Nosaka K, Morita-Hoshi Y, Onishi Y, Kim SW, et al. T-cell large granular lymphocyte leukemia of donor origin after cord blood transplantation. *Clin Lymphoma Myeloma.* 2007;7:475–9.
 12. Cotter R, Najfeld V, Isola L, Del Toro G, Roman E, Petersen B, et al. An unusual case of donor-derived myelodysplastic syndrome following double-unit umbilical cord blood transplantation in acute lymphoblastic leukemia. *Am J Hematol.* 2012;87:931–3.
 13. Thomas X, Elhamri M, Raffoux E, Renneville A, Pautas C, de Botton S, et al. Comparison of high-dose cytarabine and timed-sequential chemotherapy as consolidation for younger adults with AML in first remission: the ALFA-9802 study. *Blood.* 2011;118:1754–62.
 14. Belhabri A, Thomas X, Wattel E, Chelghoum Y, Anglaret B, Vekhoff A, et al. All trans retinoic acid in combination with intermediate-dose cytarabine and idarubicin in patients with relapsed or refractory non promyelocytic acute myeloid leukemia: a phase II randomized trial. *Hematol J.* 2002;3:49–55.
 15. Paubelle E, Plesa A, Hayette S, Elhamri M, Zylbersztejn F, Hermine O, et al. Efficacy of all-*trans*-retinoic acid in high-risk acute myeloid leukemia with overexpression of *EVII*. *Oncol Ther.* 2019;7:121–30.
 16. Wiseman DH. Donor cell leukemia: a review. *Bio Blood Marrow Transpl.* 2011;17:771–89.
 17. Aldoss I, Song JY, Curtin PT, Forman SJ. Multiple donor-derived leukemias in a recipient of allogeneic hematopoietic cell transplantation for myeloid malignancy. *Blood Adv.* 2020;4:4798–801.
 18. Schichman SA, Suess P, Vertino AM, Gray PS. Comparison of short tandem repeat and variable number tandem repeat genetic markers for quantitative determination of allogeneic bone marrow transplant engraftment. *Bone Marrow Transplant.* 2002;29:243–8.
 19. Avery S, Shi W, Lubin M, Gonzales AM, Heller G, Castro-Malaspina H, et al. Influence of infused cell dose and HLA match on engraftment after double-unit cord blood allografts. *Blood.* 2011;117:3277–85.
 20. Sala Torra O, Loeb KR. Donor cell-derived leukemia and myelodysplastic neoplasm. Unique forms of leukemia. *Am J Hematol.* 2011;135:501–504.
 21. Cooley LD, Sears DA, Udden MM, Harrison WR, Baker KR. Donor cell leukemia: report of a case occurring 11 years after allogeneic bone marrow transplantation and review of the literature. *Am J Hematol.* 2000;63:46–53.
 22. Loren AW, Porter DL, Stadtmauer EA, Tsai DE. Post-transplant lymphoproliferative disorder: a review. *Bone Marrow Transplant.* 2003;31:145–55.
 23. Flores-Figueroa E, Gutierrez-Espindola G, Montesinos JJ, Arana-Trejo RM, Mayani H. In vitro characterization of hematopoietic microenvironment cells from patients with myelodysplastic syndrome. *Leuk Res.* 2002;26:677–686.
 24. Swiggers SJ, Kuijpers MA, de Cort MJ, Beverloo HB, Zijlmans JM. Critically short telomeres in acute myeloid leukemia with loss or gain of parts of chromosomes. *Genes Chromosomes Cancer.* 2006;45:247–56.
 25. Gutman JA, Turtle CJ, Manley TJ, Heimfeld S, Bernstein ID, Riddle SR, et al. Single-unit dominance after double-unit umbilical cord blood transplantation coincides with a specific CD8+ T-cell response against the nonengrafted unit. *Blood.* 2010;115:757–65.