

Far-lateral Vascularized Rib Graft for Cervical and Lumbar Spinal Arthrodesis: Cadaveric Technique Description

Michael A. Bohl, MD
 Randall J. Hlubek, MD
 Jay D. Turner, MD, PhD
 U. Kumar Kakarla, MD
 Mark C. Preul, MD
 Edward M. Reece, MD

Background: Rotational vascularized autografts are ideal for achieving spinal arthrodesis because they maintain bony vascularization while avoiding the morbidity and challenges of free-tissue transfer. Although proximal ribs are ideal candidates for vascularized bone grafts, their use is restricted to the thoracic spine. This study describes a novel technique for harvesting lateral rib grafts on an intercostal pedicle for use in cervical and lumbar posterolateral arthrodesis.

Methods: Six cadaveric dissections were performed (2 included upper and all 6 included lower rib dissections). Measurements included graft width and thickness, distance reached from harvest level to the top of the graft, and ipsilateral and contralateral spine levels reached by the graft.

Results: Overall, 60 lateral rib grafts were harvested. Intercostal vessel pedicles were torn during harvest in 4/48 (8.3%) of the lower rib and 5/12 (41.7%) of the upper rib grafts. Mean measurements of successful upper rib grafts were $1.4 \pm 0.12 \text{ cm} \times 0.5 \pm 0.15 \text{ cm}$ (width \times thickness), $14.1 \pm 2.79 \text{ cm}$ (distance) reached, and C2 (occiput–C4) reached ipsilaterally and C3 (occiput–C5) reached contralaterally. Mean lower rib graft measurements were $1.4 \pm 0.26 \text{ cm} \times 0.4 \pm 0.15 \text{ cm}$ (width \times thickness), $18.0 \pm 6.19 \text{ cm}$ (distance), S1 (L1–S2) reached ipsilaterally, and L4 (L1–S1) reached contralaterally.

Conclusions: It is technically feasible to rotate a far-lateral rib graft on an intercostal pedicle into the posterolateral cervical or lumbar spine for the augmentation of arthrodesis. Upper ribs seem to be more difficult to harvest and rotate while keeping the intercostal pedicle intact than lower ribs. (*Plast Reconstr Surg Glob Open* 2019;7:e2131; doi: 10.1097/GOX.0000000000002131; Published online 25 April 2019.)

INTRODUCTION

Vascularized bone grafts (VBGs) are widely recognized as superior to other graft types, affording patients greater rates of fusion, shorter times to fusion, better biomechanical stability during the critical early phases of healing, and a significantly reduced risk of infection compared with nonvascularized bone grafts.^{1–7} Numerous small case series have been published in the last 3 decades on the use of VBGs in patients with complex spinal pathologies, the results of which are uniformly positive.^{1–3,8–11} All but 2 of these series^{2,8} reported on the use of free fibula or

iliac crest grafts.^{1,3,9–11} An alternative to free-transfer VBG is pedicled VBG. A pedicled VBG comprises a locally harvested piece of bone that is rotated into a fusion bed while maintaining its blood supply via muscle and periosteal feeding vessels. Wilden et al.² and Lewis et al.⁸ reported on their success using pedicled rib grafts in spinal reconstruction. These authors found that the harvest of a vascularized rib graft and mobilization of the vascular pedicle was straightforward, required no anastomosis, afforded high-quality cortical and medullary bone with a natural curve that could be fit to the thoracic kyphosis, and added <60 minutes to the operative time. Lewis et al.⁸ furthermore performed all their pedicled rib grafts through a posterior-only approach, thereby avoiding the increased operative time, anesthesia morbidity, and blood loss associated with combined anterior-posterior approaches. The pedicled rib graft therefore seems to combine all the benefits of VBG while avoiding the prohibitive challenges of

From the Department of Neurosurgery, Barrow Neurological Institute, St. Joseph's Hospital and Medical Center, Phoenix, Ariz.

Received for publication June 22, 2018; accepted December 12, 2018.

Copyright © 2019 The Authors. Published by Wolters Kluwer Health, Inc. on behalf of The American Society of Plastic Surgeons. This is an open-access article distributed under the terms of the Creative Commons Attribution-Non Commercial-No Derivatives License 4.0 (CCBY-NC-ND), where it is permissible to download and share the work provided it is properly cited. The work cannot be changed in any way or used commercially without permission from the journal.

DOI: 10.1097/GOX.0000000000002131

Disclosure: The authors have no financial interest to declare in relation to the content of this article. This study was funded by the Barrow Neurological Foundation and the Newsome Family Endowed Chair of Neurosurgery.

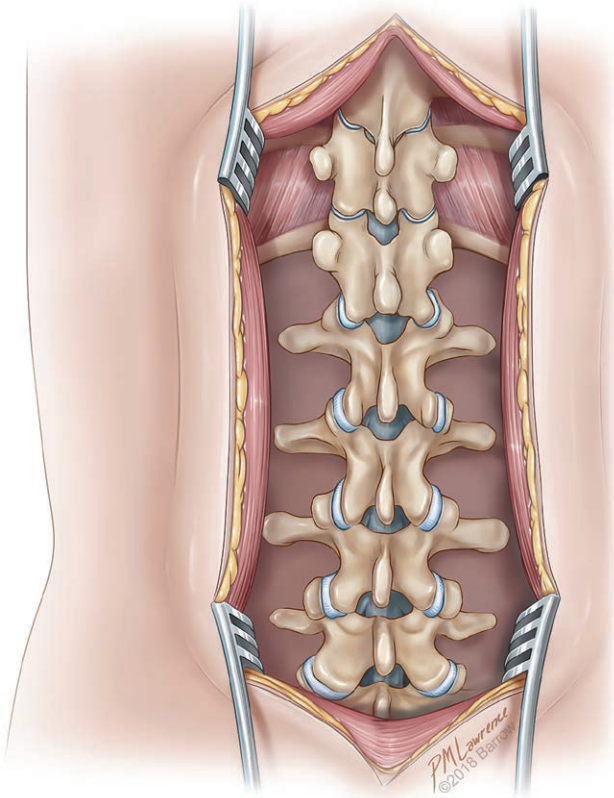


Fig. 1. Illustration demonstrating standard posterior thoracolumbar spine exposure extended laterally to the medial ribs and transverse processes. Used with permission from Barrow Neurological Institute, Phoenix, Ariz.

free-tissue transfer. However, the majority of spine disease treated with posterolateral arthrodesis is in the cervical and lumbar spine, which is unreachable by a harvested proximal rib graft attached to an intercostal pedicle. The objectives of this study were to identify and describe a technique for mobilizing a vascularized rib graft on an intercostal pedicle to the cervical or lumbar spine.

METHODS

A multidisciplinary team of plastic surgeons and neurosurgeons hypothesized that it is feasible to rotate a vascularized rib graft on an intercostal pedicle to the cervical and lumbar spine segments. Six cadaveric torsos were dissected, and a technique was developed to harvest a lateral segment of rib and subsequently rotate this rib segment into the cervical spine (for upper ribs) or lumbar spine (for lower ribs). Graft dimensions were reported as means (SDs) for width by thickness and for the distance reached by the graft from the proximal segment of the intercostal vessel to the most distal point reached by the graft. Graft length measurements were not collected as rib graft length is dependent on the length of rib exposed and harvested by the surgeon. For the sake of consistency in this study, a length of bone graft was harvested in each case for arthrodesis across approximately 2 intervertebral disc spaces. The mean spine levels reached by each graft

type were rounded to the nearest whole level and reported as mean (range) for both the ipsilateral and contralateral spine.

Technique Description

With the cadaver in a prone position, a midline incision was made from occiput to sacrum. A standard midline exposure of the posterior spine was then performed via subperiosteal dissection over the spinous processes, laminae, facet joints, and transverse processes (Fig. 1). Dorsal medial rib exposures were then conducted and extended laterally to the extent allowed by the midline incision. The intercostal neurovascular bundle was then dissected out medially at the rib approximation to the transverse process (Fig. 2). The exiting nerve root at this level can be sacrificed to prevent postoperative neuralgia. A second incision was then made laterally, parallel and directly overlying the rib to be harvested (Fig. 3). The dorsal surface of the rib was exposed by subperiosteal dissection from the midline to the lateral incision, with care taken to preserve the intercostal vessels below the rib (Fig. 4). Care should be taken to only perform the minimal amount of subperiosteal dissection necessary, as the periosteum is an important source of vascular supply to the bone graft. The intercostal muscle attachments were then disconnected from the superior surface of the harvested rib (Fig. 5) and from the superior surface of the rib 1 level inferior to the harvested rib. The mobilized rib with intact intercostal vessels and vessel attachments was then tunneled medially

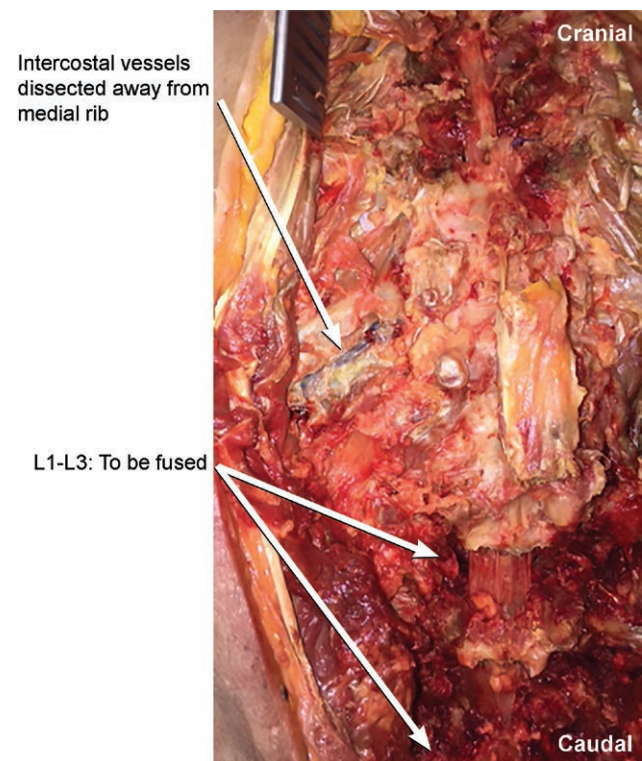


Fig. 2. Cadaver photograph demonstrating how the intercostal neurovascular bundle is dissected off the superior rib. Used with permission from Barrow Neurological Institute, Phoenix, Ariz.

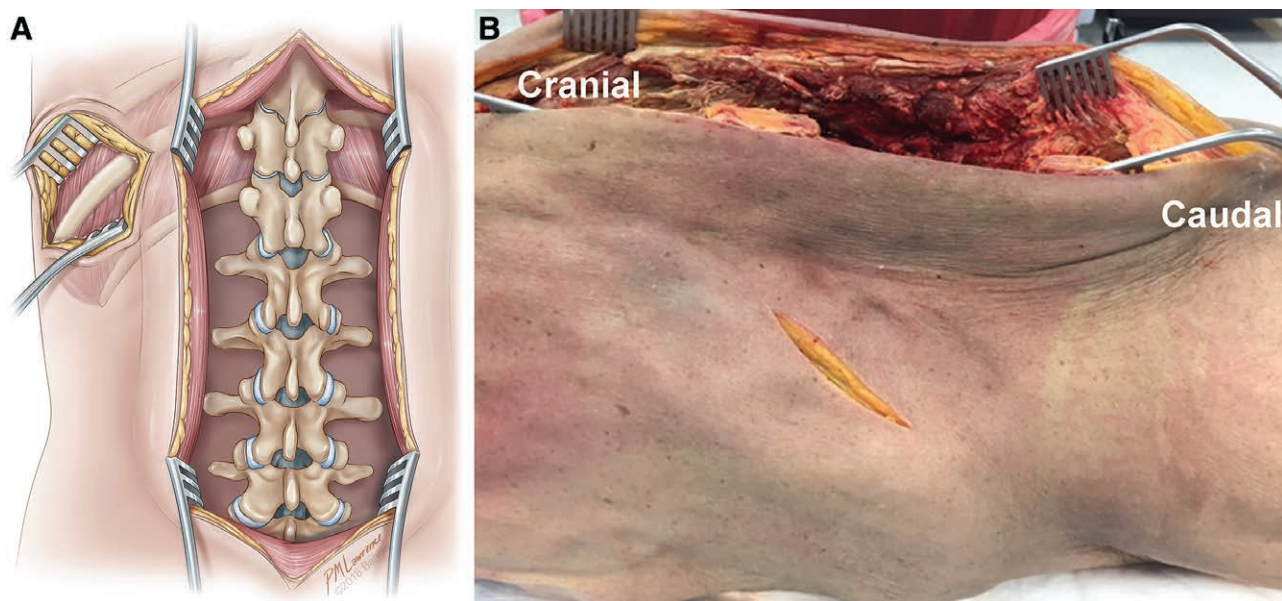


Fig. 3. Lateral incision for harvesting the vascularized rib graft. A, Illustration and (B) cadaver photograph demonstrating how a lateral incision is made overlying the rib to be harvested. Used with permission from Barrow Neurological Institute, Phoenix, Ariz.

while releasing any remaining attachments of the intercostal vessels to the remaining medial rib (Fig. 6) With the rib mobilized to the midline on its extended intercostal vascular pedicle, it could then be positioned either superiorly (in the case of upper rib grafts) into the cervical spine or inferiorly (in the case of lower rib grafts) into the lumbar spine (Fig. 7). The natural convexity of the rib can be used advantageously when positioning the graft into the lordosis of the cervical or lumbar spine (Fig. 8).

RESULTS

Six cadaveric torsos with intact crania were dissected. Lower rib dissections included bilateral levels T9–T12, and upper rib dissections included bilateral T3–T5 (T1 and T2 take a primarily ventral course and were thus found unsuitable for harvesting). Lower rib dissections

were performed in all 6 cadavers, whereas upper rib dissections were performed in 2 of the 6 cadavers (the upper ribs for the other 4 cadavers were used during technique development and were thus unsuitable for measurement). In total, 60 rib grafts were harvested, 48 lower rib and 12 upper rib grafts. Four of the 48 lower rib grafts suffered a torn intercostal pedicle during mobilization of the graft medially (failure rate = 8.3%), and 5 of the 12 upper rib grafts suffered a torn intercostal pedicle, again all of which occurred during mobilization of the graft medially (failure rate = 41.7%). In each of these cases of failed graft harvest, the vascular pedicle was either torn during tunneling to the midline (likely because of inadequate exposure and release of the intercostal vessels along the medial rib segment) or was directly injured during dissection between the lateral and medial incisions.

The upper rib grafts had a mean (SD) width × thickness of 1.4 cm (0.12) × 0.5 cm (0.15), the mean (SD) distance reached was 14.1 cm (2.79), and the mean (range) levels reached were C2 (occiput–C4) ipsilaterally and C3 (occiput–C5) contralaterally. Table 1 shows individual graft measurements of the upper ribs. Lower ribs had a mean (SD) width × thickness of 1.4 cm (0.26) × 0.4 cm (0.15), the mean (SD) distance reached was 18.0 cm (6.19), and the mean (range) levels reached were S1 (L1–S2) ipsilaterally and L4 (L1–S1) contralaterally. Table 2 shows a summary of graft measurements for the lower ribs.

DISCUSSION

Many patients with complex spinal pathologies and numerous risk factors for pseudarthrosis will likely require a surgical strategy for augmenting fusion rates and successful arthrodesis following spinal reconstruction. Studies have shown that despite greatly increased morbidity and mortality, many of these patients have better overall outcomes with surgery compared with patients who have medical management

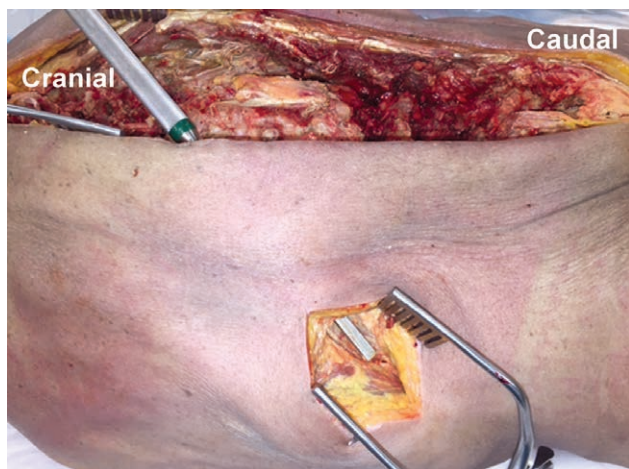


Fig. 4. Cadaver photograph demonstrating the subperiosteal dissection over the harvested rib tunneled from medial to lateral toward the incision. Used with permission from Barrow Neurological Institute, Phoenix, Ariz.

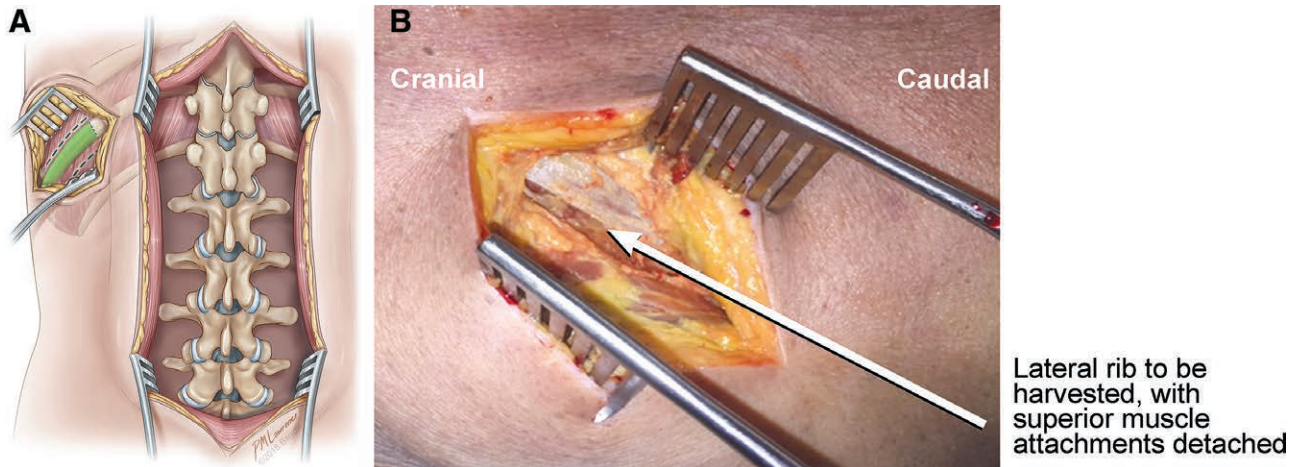


Fig. 5. Lateral rib graft exposure and dissection. A, Illustration and (B) cadaver photograph demonstrating the lateral rib exposure with dissection of the superior muscle attachments from the harvested rib, with inferior muscle attachments and subcostal vessels left intact. Used with permission from Barrow Neurological Institute, Phoenix, Ariz.

only.¹² It is, therefore, imperative for us to continue seeking better methods of spine stabilization for these patients with complex spinal pathologies. The maintenance of the vascular supply of a bone graft is a logical way to augment the probab-

ility of that graft incorporating into the host site, resisting the development of sequestrum, and providing a robust and biomechanically responsive support structure across a previously unstable spine segment.

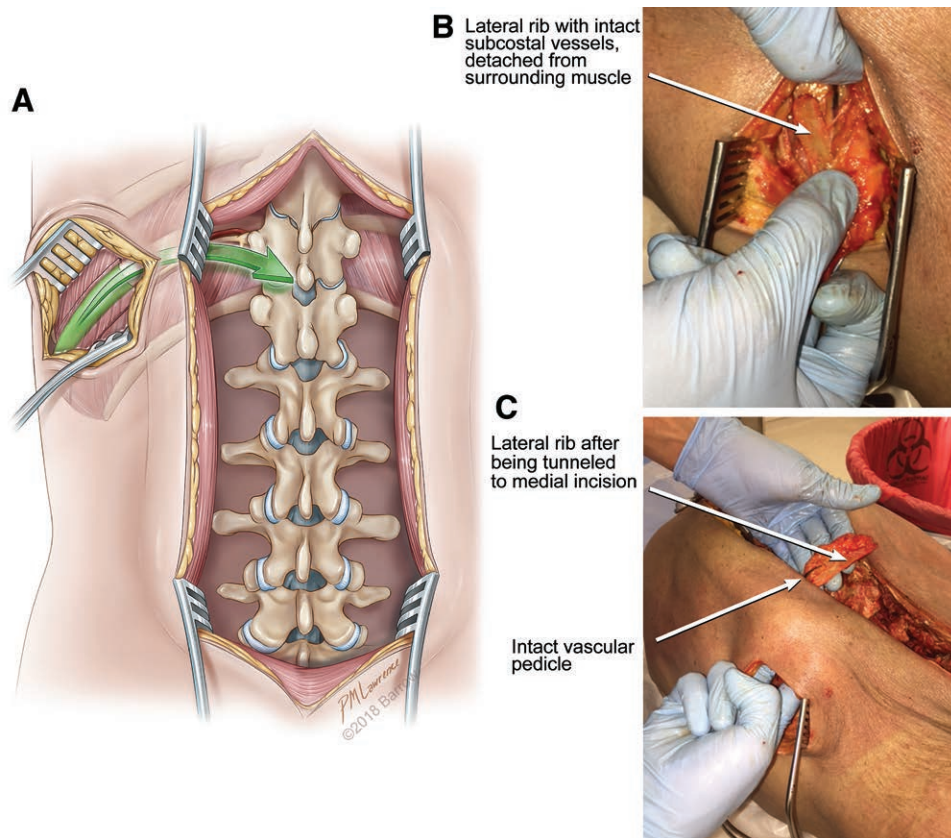


Fig. 6. Mobilization of the vascularized rib graft. A, Illustration demonstrating the mobilization and tunneling of the harvested rib graft medially toward the midline incision. B, Cadaver photograph demonstrating the harvested rib graft with intact subcostal vessels, detached from the surrounding muscle tissue. C, Cadaver photograph demonstrating the medial tunneling of the harvested rib from the lateral incision toward the midline incision while keeping the subcostal vessels intact. Used with permission from Barrow Neurological Institute, Phoenix, Ariz.

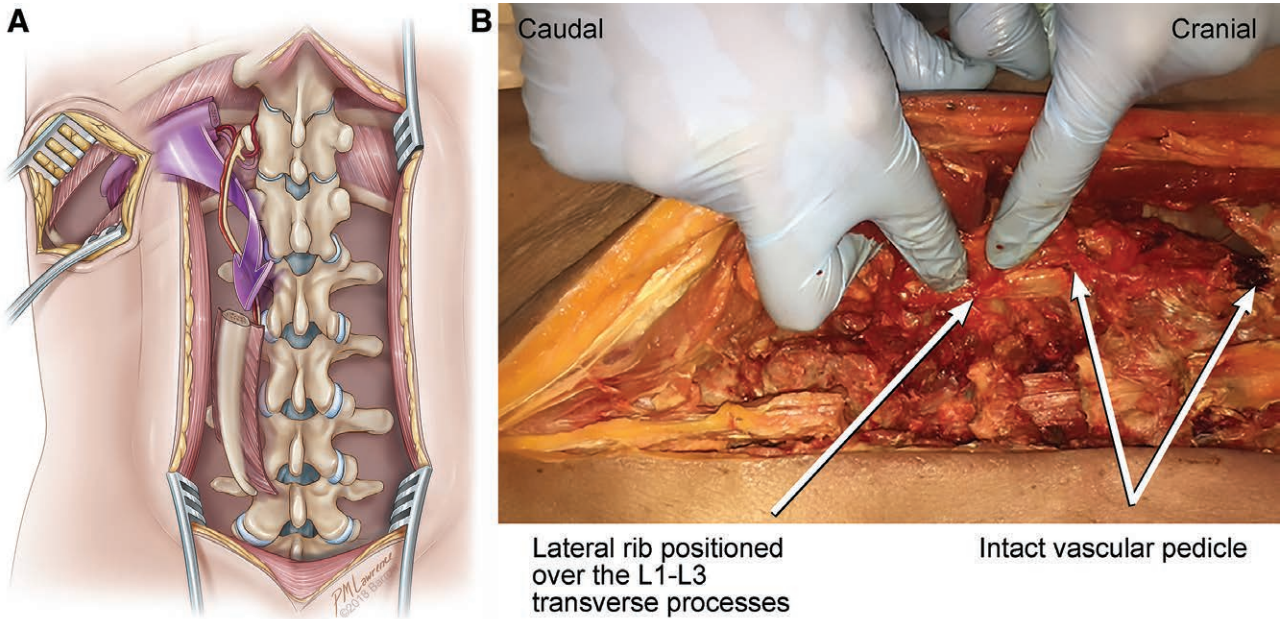


Fig. 7. Placement of the mobilized rib graft. A, Illustration and (B) cadaver photograph demonstrating mobilization of the rib graft down into the posterolateral space of the lumbar spine on its extended vascular pedicle. Used with permission from Barrow Neurological Institute, Phoenix, Ariz.

To the best of our knowledge, this study is the first to describe a technique for mobilizing a vascularized rib graft from a lateral exposure into the posterior cervical or

posterior lumbar spine. The ribs are ideal candidates for a VBG as they contain a robust and relatively easy-to-preserve vascular pedicle, adequate cortical bone to provide biomechanical stability to the graft site, adequate medullary bone to provide biological support to the graft site, and a natural curve that can easily be matched to the intended cervical or lumbar lordosis. Although a mean rib width of 1.4cm seems appropriate for placement in the posterolateral space, a mean thickness of 0.4cm is a potential drawback of using lower ribs as a harvest site for autograft bone. The added benefit of introducing living bone tissue to the arthrodesis site, with subsequent primary bone healing and bony remodeling, would hopefully compensate for this small graft thickness.

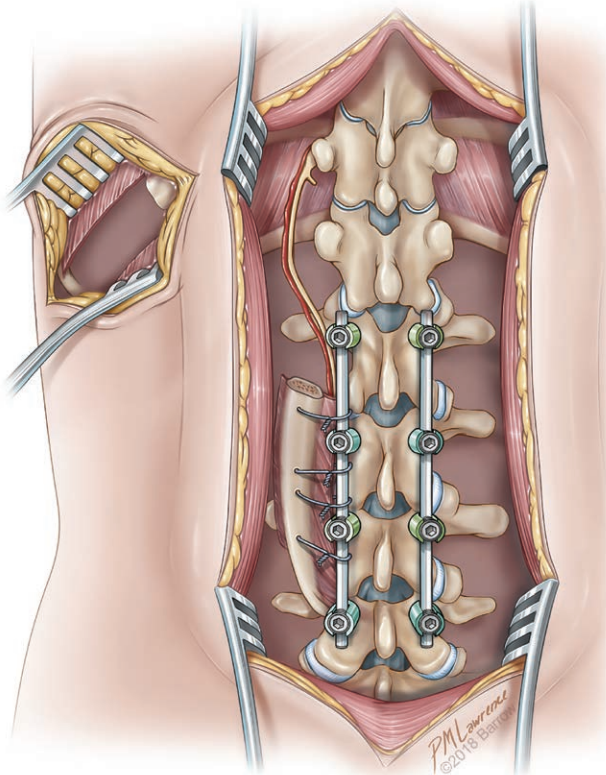


Fig. 8. Illustration demonstrating the pedicled vascular rib graft fixed in the posterolateral space of the lumbar spine where it can augment arthrodesis. Used with permission from Barrow Neurological Institute, Phoenix, Ariz.

The results show that it was somewhat difficult to harvest the upper ribs for mobilization into the cervical spine. A harvest failure rate of nearly 50% is obviously inadequate for performing the technique in patients. However, it is unknown how the cadaveric tissue compares with living tissue, and the effect this difference might have on the success of intercostal pedicle mobilization. Furthermore, not every harvested graft was able to reach above the subaxial cervical spine; thus, on the basis of our results, we recommend the use of this technique for the augmentation of posterior cervical arthrodesis of the subaxial cervical spine only. The high harvest failure rate for the cervical ribs should also be seriously considered before attempting this technique in a living patient. The lower ribs, however, seemed to more easily cover all lumbar segments to the first sacral level and had a much lower harvest failure rate. The T12 rib harvests showed high variability in bone graft dimensions, consistent with known variability in the size of the T12 rib. However, the T10 and T11 ribs were often able to reach the sacrum, and thus, we support the use of

Table 1. Upper Rib Graft Measurements

Rib	Width (cm)	Thickness (cm)	Distance Reached (cm)	Level Reached (Ipsilateral)	Level Reached (Contralateral)
Cadaver 1					
Right T3	1.4	0.5	12.1	C3	C4
Right T4	1.6	0.7	12.8	C4	C5
Right T5	Torn	—	—	—	—
Left T3	1.4	0.3	12.7	C2	C3
Left T4	1.5	0.5	12.0	C4	C5
Left T5	Torn	—	—	—	—
Cadaver 2					
Right T3	1.4	0.6	13.1	C2	C3
Right T4	1.2	0.7	17.2	Occiput	Occiput
Right T5	Torn	—	—	—	—
Left T3	Torn	—	—	—	—
Left T4	1.4	0.6	19.0	Occiput	Occiput
Left T5	Torn	—	—	—	—

Table 2. Lower Rib Measurement Summary

Rib	Width, Mean (SD), cm	Thickness, Mean (SD), cm	Distance Reached, Mean (SD), cm	Ipsilateral Level Reached, Mean (Range)	Contralateral Level Reached, Mean (Range)
T9	1.6 (0.23)	0.5 (0.14)	22.8 (4.04)	L5 (L3–S1)	L4 (L2–S1)
T10	1.4 (0.22)	0.4 (0.17)	21.5 (3.46)	S1 (L3–S2)	L5 (L2–S1)
T11	1.4 (0.20)	0.4 (0.14)	17.3 (1.97)	L5 (L3–S2)	L4 (L2–S1)
T12	1.2 (0.30)	0.4 (0.09)	9.1 (3.68)	L3 (L1–L5)	L2 (L1–L4)

this technique for all levels of the lumbar spine. Interestingly, the T10 rib more reliably reached the sacrum, and as such is likely a better graft site when lumbosacral fusion is desired. Considering the cause of harvest failure was tearing of the vascular pedicle for both the cervical and lumbar rib grafts, great care should be taken at this stage of the procedure to safely and completely free the intercostal vessels from the costotransverse joint to the medial edge of the harvested rib graft.

Limitations

This study is limited by its use of cadaveric specimens only. Although cadavers provide us with the highest fidelity model of human anatomy currently available, certain procedural challenges that are unrealized when working with cadavers are likely to be present when operating on living patients.

CONCLUSIONS

It is technically feasible to rotate a far-lateral rib graft on an intercostal pedicle into the posterolateral cervical or lumbar spine for the augmentation of arthrodesis. Compared with lower ribs, upper ribs seem to be more difficult to harvest and rotate while keeping the intercostal pedicle intact. Experience using the described technique in living patients is needed before more definitive conclusions can be made regarding the technical feasibility of performing this surgical technique.

U. Kumar Kakarla, MD
 Barrow Neuroscience Publications
 Barrow Neurological Institute
 St. Joseph’s Hospital and Medical Center
 350 W. Thomas Rd.
 Phoenix, AZ 85013
 E-mail: Neuropub@barrowneuro.org

ACKNOWLEDGMENTS

The authors thank the Barrow Neuroscience Publications staff for their assistance with manuscript preparation.

REFERENCES

- Ackerman DB, Rose PS, Moran SL, et al. The results of vascularized-free fibular grafts in complex spinal reconstruction. *J Spinal Disord Tech.* 2011;24:170–176.
- Wilden JA, Moran SL, Dekutoski MB, et al. Results of vascularized rib grafts in complex spinal reconstruction. *J Bone Joint Surg Am.* 2006;88:832–839.
- Yelizarov VG, Minachenko VK, Gerasimov OR, et al. Vascularized bone flaps for thoracolumbar spinal fusion. *Ann Plast Surg.* 1993;31:532–538.
- Davis JB, Taylor AN. Muscle pedicle bone grafts; experimental study. *AMA Arch Surg.* 1952;65:330–336.
- Medgyesi S. Healing of muscle-pedicle bone grafts: an experimental study. *Acta Orthop Scand.* 1965;35:294–299.
- Shaffer JW, Field GA, Goldberg VM, et al. Fate of vascularized and nonvascularized autografts. *Clin Orthop Relat Res.* 1985;197:32–43.
- Goldberg VM, Shaffer JW, Field G, et al. Biology of vascularized bone grafts. *Orthop Clin North Am.* 1987;18:197–205.
- Lewis SJ, Kulkarni AG, Rampersaud YR, et al. Posterior column reconstruction with autologous rib graft after en bloc tumor excision. *Spine (Phila Pa 1976).* 2012;37:346–350.
- Lee MJ, Ondra SL, Mindea SA, et al. Indications and rationale for use of vascularized fibula bone flaps in cervical spine arthrodeses. *Plast Reconstr Surg.* 2005;116:1–7.
- Winters HA, van Engeland AE, Jiya TU, et al. The use of free vascularised bone grafts in spinal reconstruction. *J Plast Reconstr Aesthet Surg.* 2010;63:516–523.
- Aliano KA, Agulnick M, Cohen B, et al. Spinal reconstruction for osteomyelitis with free vascularized fibular grafts using intra-abdominal recipient vessels: a series of three cases. *Microsurgery.* 2013;33:560–566.
- Quiñones-Hinojosa A, Jun P, Jacobs R, et al. General principles in the medical and surgical management of spinal infections: a multidisciplinary approach. *Neurosurg Focus.* 2004;17:E1.