



Since January 2020 Elsevier has created a COVID-19 resource centre with free information in English and Mandarin on the novel coronavirus COVID-19. The COVID-19 resource centre is hosted on Elsevier Connect, the company's public news and information website.

Elsevier hereby grants permission to make all its COVID-19-related research that is available on the COVID-19 resource centre - including this research content - immediately available in PubMed Central and other publicly funded repositories, such as the WHO COVID database with rights for unrestricted research re-use and analyses in any form or by any means with acknowledgement of the original source. These permissions are granted for free by Elsevier for as long as the COVID-19 resource centre remains active.

for weight. Four children had known family exposure to coronavirus disease 2019 (COVID-19). Demographics, clinical findings, imaging findings, treatment, and outcome for this cluster of eight children are shown in the table.

Clinical presentations were similar, with unrelenting fever (38–40°C), variable rash, conjunctivitis, peripheral oedema, and generalised extremity pain with significant gastrointestinal symptoms. All progressed to warm, vasoplegic shock, refractory to volume resuscitation and eventually requiring noradrenaline and milrinone for haemodynamic support. Most of the children had no significant respiratory involvement, although seven of the children required mechanical ventilation for cardiovascular stabilisation. Other notable features (besides persistent fever and rash) included development of small pleural, pericardial, and ascitic effusions, suggestive of a diffuse inflammatory process.

All children tested negative for severe acute respiratory syndrome coronavirus 2 (SARS-CoV-2) on bronchoalveolar lavage or nasopharyngeal aspirates. Despite being critically unwell, with laboratory evidence of infection or inflammation² including elevated concentrations of C-reactive protein, procalcitonin, ferritin, triglycerides, and D-dimers, no pathological organism was identified in seven of the children. Adenovirus and enterovirus were isolated in one child.

Baseline electrocardiograms were non-specific; however, a common echocardiographic finding was echobright coronary vessels (appendix), which progressed to giant coronary aneurysm in one patient within a week of discharge from paediatric intensive care (appendix). One child developed arrhythmia with refractory shock, requiring extracorporeal life support, and died from a large cerebrovascular infarct. The myocardial involvement³ in this syndrome is evidenced by very elevated cardiac enzymes during the course of illness.

All children were given intravenous immunoglobulin (2 g/kg) in the first 24 h, and antibiotic cover including ceftriaxone and clindamycin. Subsequently, six children have been given 50 mg/kg aspirin. All of the children were discharged from the PICU after 4–6 days. Since discharge, two of the children have tested positive for SARS-CoV-2 (including the child who died, in whom SARS-CoV-2 was detected post mortem). All children are receiving ongoing surveillance for coronary abnormalities.

We suggest that this clinical picture represents a new phenomenon affecting previously asymptomatic children with SARS-CoV-2 infection manifesting as a hyperinflammatory syndrome with multiorgan involvement similar to Kawasaki disease shock syndrome. The multifaceted nature of the disease course underlines the need for multispecialty input (intensive care, cardiology, infectious diseases, immunology, and rheumatology).

The intention of this Correspondence is to bring this subset of children to the attention of the wider paediatric community and to optimise early recognition and management. As this Correspondence goes to press, 1 week after the initial submission, the Evelina London Children's Hospital paediatric intensive care unit has managed more than 20 children with similar clinical presentation, the first ten of whom tested positive for antibody (including the original eight children in the cohort described above).

We declare no competing interests.

**Shelley Riphagen, Xabier Gomez, Carmen Gonzalez-Martinez, Nick Wilkinson, Paraskevi Theocharis*
shelley.riphagen@gstt.nhs.uk

South Thames Retrieval Service for Children, Evelina London Children's Hospital Paediatric Intensive Care Unit, London SE1 7EH, UK (SR, XG); and Evelina London Children's Hospital, London, UK (CG-M, NW, PT)

- Zhang M-M, Shi L, Lin Y, Liu Y. Clinical analysis of Kawasaki disease shock syndrome. *Chin Med J (Engl)* 2017; **130**: 2891–92.

- Li Y, Zou L, Wu J, et al. Kawasaki disease shock syndrome: clinical characteristics and possible use of IL-6, IL-10 and IFN- γ as biomarkers for early recognition. *Pediatr Rheumatol Online J* 2019; **17**: 1.
- Liu P, Blet A, Smyth D, Li H. The science underlying COVID-19: implications for the cardiovascular system. *Circulation* 2020; published online April 15. DOI:10.1161/CIRCULATIONAHA.120.047549.

COVID-19: PCR screening of asymptomatic health-care workers at London hospital

The exponential growth in coronavirus disease 2019 (COVID-19) caused by severe acute respiratory syndrome coronavirus 2 (SARS-CoV-2) across the UK has been successfully reversed by social distancing and lockdown.¹ RNA testing for prevalent infection is a key part of the exit strategy, but the role of testing for asymptomatic infection remains unclear.² Understanding the determinants of asymptomatic or pauci-symptomatic infection will provide new opportunities for personalised risk stratification and reveal much-needed correlates of protective immunity, whether induced by vaccination or natural exposure. To address this, we set up COVIDsortium (NCT04318314), a bioresource focusing on asymptomatic health-care workers (HCWs—doctors, nurses, allied health professionals, administrators, and others) at Barts Health NHS Trust, London, UK, to collect data through 16 weekly assessments (unless ill, self-isolating, on holiday, or redeployed) with a health questionnaire, nasal swab, and blood samples and two concluding assessments at 6 months and 12 months. HCWs were self-declared as healthy and fit to work for study visits. Participants were not given swab results, and those with symptoms or in self-isolation resumed study visits on return to work.

Across London, case-doubling time in March, 2020, was approximately 3–4 days. The number of nasal swabs testing positive for SARS-CoV-2



Published Online
May 7, 2020

[https://doi.org/10.1016/S0140-6736\(20\)31100-4](https://doi.org/10.1016/S0140-6736(20)31100-4)

See Online for appendix

Submissions should be made via our electronic submission system at <http://ees.elsevier.com/thelancet/>

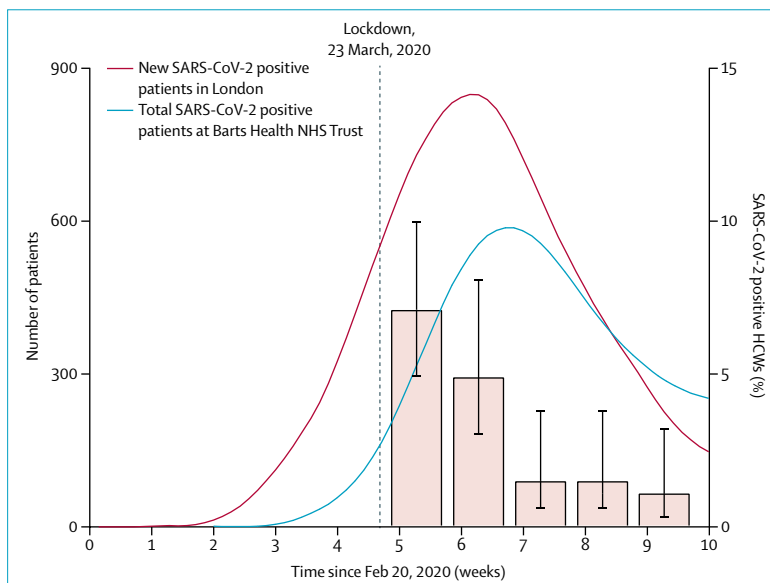


Figure: Number of patients testing positive for SARS-CoV-2 in Greater London and Barts Health NHS Trust and proportion of the HCW study cohort with SARS-CoV-2 positive nasal swab

The left y-axis shows number of daily new SARS-CoV-2 positive patients in the Greater London area, derived from Public Health England data (red curve) and the total number of SARS-CoV-2 positive inpatients at Barts Health NHS Trust (blue curve). Both curves show 7-day averages. The right y-axis shows the percentage (95% CI) of asymptomatic HCWs in this study with SARS-CoV-2 positive swabs in the first 5 weeks of testing. COVID-19=coronavirus disease 2019. SARS-CoV-2=severe acute respiratory syndrome coronavirus 2. HCWs=health-care workers.

peaked on March 30, 2020, suggesting infections peaked on March 23, 2020, the day of UK lockdown. COVIDsortium was established with all national and local permissions in 7 days. Recruitment started on March 23, 2020, and was completed 8 days later.

Here we present the SARS-CoV-2 PCR results from nasal swabs collected at the first five timepoints from the first 400 participants (figure). We show the number and percentage of asymptomatic HCWs who tested positive for SARS-CoV-2 on consecutive weeks from March 23, 2020: 28 (7.1%; 95% CI 4.9–10.0) of 396 HCWs in week 1, 14 (4.9%; 3.0–8.1) of 284 HCWs in week 2, four (1.5%; 0.6–3.8) of 263 HCWs in week 3, four (1.5%; 0.6–3.8) of 267 HCWs in week 4, and three (1.1%, 0.4–3.2) of 269 HCWs in week 5 (figure). Seven HCWs tested positive on two consecutive timepoints, and one HCW tested positive on three consecutive timepoints. During this time, 50 HCWs (not necessarily those who were SARS-CoV-2 positive)

self-isolated for symptoms. Of the 44 HCWs who tested positive for SARS-CoV-2, 12 (27%) had no symptoms in the week before or after positivity.

HCWs have been particularly hard hit by the COVID-19 pandemic, with high reported rates of infection from Italian data,³ raising concerns about the effectiveness of personal protective equipment and of nosocomial transmission.⁴ Public fear of hospitals is also currently high, and many serious and treatable diseases are presenting late with adverse outcomes.⁵ Testing of HCWs has so far been restricted to symptomatic individuals, and no studies have reported serial testing in high-exposure asymptomatic volunteers. If our results are generalisable to the wider HCW population, then asymptomatic infection rates among HCWs tracked the London general population infection curve, peaking at 7.1% and falling six-fold over 4 weeks, despite the persistence of a high burden of COVID-19 patients through this time (representing most inpatients). Taken

together, these data suggest that the rate of asymptomatic infection among HCWs more likely reflects general community transmission than in-hospital exposure. Prospective patients should be reassured that as the overall epidemic wave recedes, asymptomatic infection among HCWs is low and unlikely to be a major source of transmission.

These data reinforce the importance of epidemic multi-timepoint surveillance of HCWs. The data also suggest that a testing strategy should link population-representative epidemiological surveillance to predict prevalence, with adaptive testing for symptomatic individuals at times of low prevalence, and rapidly expanding to include the asymptomatic HCWs during possible new infection waves.

Funding for the work presented in this Correspondence was donated by individuals, charitable Trusts, and corporations including Goldman Sachs, Citadel and Citadel Securities, The GUY Foundation, GW Pharmaceuticals, Kusuma Trust, and Jagclif Charitable Trust. The funders had no role in study design, data collection, or the decision to publish this Correspondence. The corresponding author had full access to all data and final responsibility for the decision to submit for publication. JCM and CM are directly and indirectly supported by the University College London Hospitals (UCLH) and Barts NIHR Biomedical Research Centres and through British Heart Foundation (BHF) Accelerator Award. TAT is funded by a BHF Intermediate Research Fellowship, MB by the Barts NIHR Biomedical Research Centre, and AM by the Rosetrees Trust. JBA received funding from Sanofi. MN is supported by a Wellcome Trust Investigator in Science Award and the NIHR Biomedical Research Centre (UCLH). All other authors declare no competing interests.

*Thomas A Treibel, Charlotte Manisty, Maudrian Burton, Aine McKnight, Jonathan Lambourne, João B Augusto, Xosé Couto-Parada, Teresa Cutino-Moguel, Mahdad Noursadeghi, *James C Moon*
j.moon@ucl.ac.uk

Institute of Cardiovascular Science, University College London, London, UK (TAT, CM, JBA, JCM); Department of Cardiology (TAT, CM, JBA, JCM) and NIHR Cardiovascular Biomedical Research Unit (MB), St Bartholomew's Hospital, London EC1A 7BE, UK; Department of Infection (JL), and Department of Virology (XC-P, TC-M), Barts Health NHS Trust, London, UK; the Blizard Institute, Queen Mary University of London School of Medicine and Dentistry, London, UK (AM); and Division of Infection and Immunity, University College London, London, UK (MN)

- 1 Scientific Advisory Group for Emergencies. SPI-M-O: consensus view on behavioural and social interventions. March 9, 2020. https://assets.publishing.service.gov.uk/government/uploads/system/uploads/attachment_data/file/874290/05-potential-impact-of-behavioural-social-interventions-on-an-epidemic-of-covid-19-in-uk-1.pdf (accessed April 24, 2020).
- 2 Black JRM, Bailey C, Swanton C. COVID-19: the case for health-care worker screening to prevent hospital transmission. *Lancet* 2020; **395**: 1418–20.
- 3 Task force COVID-19 del Dipartimento Malattie Infettive e Servizio di Informatica, Istituto Superiore di Sanità. Epidemia COVID-19, Aggiornamento nazionale: 23 aprile 2020. April 24, 2020. https://www.epicentro.iss.it/coronavirus/bollettino/Bollettino-sorveglianza-integrata-COVID-19_23-aprile-2020.pdf (accessed April 24, 2020).
- 4 Verbeek JH, Rajamaki B, Ijaz S, et al. Personal protective equipment for preventing highly infectious diseases due to exposure to contaminated body fluids in healthcare staff. *Cochrane Database Syst Rev* 2020; **4**: CD011621.
- 5 Lazzarini M, Barbi E, Apicella A, Marchetti F, Cardinale F, Trobia G. Delayed access or provision of care in Italy resulting from fear of COVID-19. *Lancet Child Adolesc Health* 2020; **4**: e10–e11.



Retinal findings in patients with COVID-19

Coronavirus disease 2019 (COVID-19) has been shown to affect different parts of the body, and ophthalmological changes have been associated with ocular external diseases such as conjunctivitis.¹

Optical coherence tomography (OCT) is a non-invasive imaging technique that is useful for demonstrating subclinical retinal changes in systemic conditions such as diabetes, Parkinson's disease, and Alzheimer's disease, as well as many viral infections.² We used OCT to evaluate patients infected by severe acute respiratory syndrome coronavirus 2 (SARS-CoV-2). The protocol was approved by INVIRARE Pesquisa Clínica Auditoria e Consultoria Institutional Review Board Ethics Committee.

Here we report retinal and OCT changes in 12 adults (six men and six women, aged 25–69 years), examined 11–33 days after COVID-19 symptom onset. All patients had fever, asthenia, and dyspnoea, and 11 patients also presented with anosmia. Two patients were admitted to hospital but none required intensive care. Nine patients were physicians, and two were health-care workers. All patients had normal blood parameters at the time of ophthalmological evaluation. Nine patients tested positive for SARS-CoV-2 by PCR (using nasal and oral swabs), and two patients tested positive in antibody tests for COVID-19. Two different OCT devices were used: DRI-OCT Triton Swept Source (Topcon,

Tokyo, Japan) and XR Avanti SD-OCT (Optovue, Fremont, CA, USA).

All patients showed hyper-reflective lesions at the level of ganglion cell and inner plexiform layers more prominently at the papillomacular bundle in both eyes (figure). Results of OCT-angiography and ganglion cells complex analysis appeared normal. Furthermore, four patients presented subtle cotton wool spots and microhaemorrhages along the retinal arcade, observed on fundus examination, color fundus photography, and red-free imaging. Visual acuity and pupillary reflexes were normal in all eyes, and we detected no symptoms or signs of intraocular inflammation.

Although animal models suggest ocular lesions could include retinitis and optic neuritis,^{3,4} this is, to the best of our knowledge, the first report of retinal findings possibly associated with COVID-19 infection in humans. Ganglion cell and plexiform layer findings could be associated with CNS manifestations that have been described in animal studies⁴ and in COVID-19 neurological events.⁵

We declare no competing interests.

Paula M Marinho, Allexya A A Marcos, André C Romano, *Heloisa Nascimento, Rubens Belfort Jr
helomn@gmail.com

Instituto Paulista de Estudos e Pesquisas em Oftalmologia, São Paulo, Brazil; and Instituto da Visão, Federal University of São Paulo, São Paulo 04023-062, Brazil

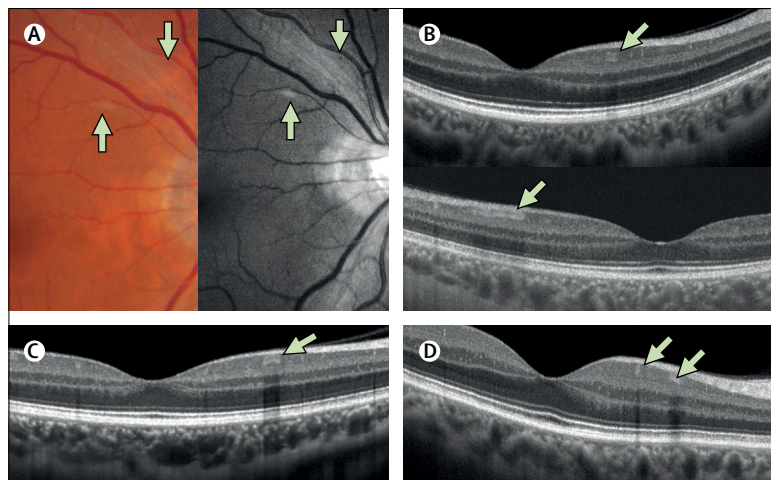


Figure: Retinal findings in four patients with COVID-19

Panels A–D represent four different patients. (A) Colour fundus photography and red-free imaging show a cotton wool spot at the superior retinal arcade with subtle microhaemorrhage. (B–D) Cross-sectional B-scan OCT in three patients shows hyper-reflective lesions at the level of the inner plexiform and ganglion cell layers, a feature observed in all patients. COVID-19=coronavirus disease 2019. OCT=optical coherence tomography.

- 1 Wu P, Duan F, Luo C, et al. Characteristics of ocular findings of patients with coronavirus disease 2019 (COVID-19) in Hubei province, China. *JAMA Ophthalmol* 2020; published online March 31. DOI:10.1001/jamaophthalmol.2020.1291.
- 2 Kurup SP, Khan S, Gill MK. Spectral domain optical coherence tomography in the evaluation and management of infectious retinitis. *Retina* 2014; **34**: 2233–41.
- 3 Seah I, Agrawal R. Can the coronavirus disease 2019 (COVID-19) affect the eyes? A review of coronaviruses and ocular implications in humans and animals. *Ocul Immunol Inflamm* 2020; **28**: 391–95.
- 4 Wang Y, Detrick B, Yu ZX, Zhang J, Chesky L, Hooks JJ. The role of apoptosis within the retina of coronavirus-infected mice. *Invest Ophthalmol Vis Sci* 2000; **41**(10): 3011–18.
- 5 Moriguchi T, Harii N, Goto J, et al. A first case of meningitis/encephalitis associated with SARS-coronavirus-2. *Int J Infect Dis* 2020; **94**: 55–58.