

research article

# Efficacy of transvaginal ultrasound versus magnetic resonance imaging for preoperative assessment of myometrial invasion in patients with endometrioid endometrial cancer: a prospective comparative study

Anis Cerovac<sup>1,2</sup>, Dzenita Ljuca<sup>2</sup>, Lejla Arnautalic<sup>3</sup>, Dubravko Habek<sup>4</sup>, Gordana Bogdanovic<sup>2,5</sup>, Jasminka Mustedanagic-Mujanovic<sup>2,6</sup>, Gordana Grgic<sup>2,5</sup>

<sup>1</sup> Department of Gynaecology and Obstetrics, General Hospital Tešanj, Tešanj, Bosnia and Herzegovina

<sup>2</sup> School of Medicine, University of Tuzla, Tuzla, Bosnia and Herzegovina

<sup>3</sup> Clinic for Radiology and Nuclear Medicine, University Clinical Centre Tuzla, Tuzla, Bosnia and Herzegovina

<sup>4</sup> University Department of Gynaecology and Obstetrics Clinical Hospital "Sveti Duh", Zagreb, School of Medicine, Catholic University of Croatia, Zagreb, Croatia

<sup>5</sup> Clinic for Gynaecology and Obstetrics, University Clinical Centre Tuzla, Tuzla, Bosnia and Herzegovina

<sup>6</sup> Department for Pathology, Polyclinic for Laboratory Diagnostic, University Clinical Center Tuzla, Tuzla, Bosnia and Herzegovina

Radiol Oncol 2022; 56(1): 37-45.

Received 03 09 2021

Accepted 13 12 2021

Correspondence to: Anis Cerovac, M.D., Department of Gynaecology and Obstetrics, General Hospital Tešanj, Tešanj, Bosnia and Herzegovina. E-mail: Cerovac.anis@gmail.com

Disclosure: No potential conflicts of interest were disclosed.

This is an open access article under the CC BY-NC-ND license (<http://creativecommons.org/licenses/by-nc-nd/4.0/>).

**Background.** We compared the accuracy of preoperative transvaginal ultrasound (TVUS) versus magnetic resonance imaging (MRI) for the assessment of myometrial invasion (MI) in patients with endometrial cancer (EC), while definitive histopathological diagnosis served as a reference method.

**Patients and methods.** Study performed at a single tertiary centre from 2019 to 2021, included women with a histopathological proven EC, hospitalized for scheduled surgery. TVUS and MRI were performed prior to surgical staging for assessment MI, which was estimated using two objective TVUS methods (Gordon's and Karlsson's) and MRI. Patients were divided into two groups, after surgery and histopathological assessment of MI: superficial ( $\leq 50\%$ ) and deep ( $> 50\%$ ).

**Results.** Sixty patients were eligible for the study. According to the reference method, there were 34 (56.7%) cases in the study with MI  $< 50\%$ , and 26 (43.3%) with MI  $> 50\%$ . Both objective TVUS methods and MRI showed no statistical significant differences in overall diagnostic performance for the preoperative assessment of MI. The concordance coefficient between both TVUS methods, MRI and histopathology was statistically significant ( $p < 0.001$ ). Gordon's method calculating MI reached a positive predictive value (PPV) of 83%, negative predictive value (NPV) of 83%, 77% sensitivity, 88% specificity, and 83% overall accuracy. Karlsson's method reached PPV of 82%, NPV of 79%, 69% sensitivity, 88% specificity, and 80% overall accuracy. Accordingly, MRI calculating MI reached PPV of 83%, NPV of 97%, 97% sensitivity, 85% specificity, and 90% overall accuracy.

**Conclusions.** We found that objective TVUS assessment of myometrial invasion was performed with a diagnostic accuracy comparable to that of MRI in women with endometrial cancer.

Key words: endometrial neoplasms; radiology; oncology; cancer staging

## Introduction

Endometrial cancer (EC) is the most common malignancy in the female genital tract in developed countries and its incidence is increasing.<sup>1-3</sup> Due to the early occurrence of abnormal uterine bleeding, most cases are diagnosed at first stage, when prognosis is very good, with a 5-year survival rate of 90%.<sup>4</sup> The EC prognosis is determined by the FIGO (International Federation of Obstetrics and Gynecology) stage of disease, the histological type and grade of tumour, the depth of myometrial invasion (MI), cervical stromal invasion, and lymph nodes involvement.<sup>1-3</sup> The depth of MI > 50%, which is considered to be one of the most important prognostic factors, highly correlates with lymph node metastases.<sup>1-3</sup> The preoperative assessment of the depth of MI is crucial to determining the most effective therapeutic approach and to decide whether the patient should be referred for

hysterectomy with bilateral adnexectomy or pelvic lymphadenectomy is need.<sup>1-3</sup>

The depth of MI can be evaluated by a number of imaging methods. These are magnetic resonance imaging (MRI), computer tomography (CT) and transvaginal ultrasonography (TVUS), among which the best results can be achieved by the MRI.<sup>1,3</sup> TVUS has been used extensively to assess depth of MI by EC.<sup>3</sup> TVUS when carried out by experienced hands has been shown to perform equally well as MRI, in the preoperative staging of EC.<sup>4</sup>

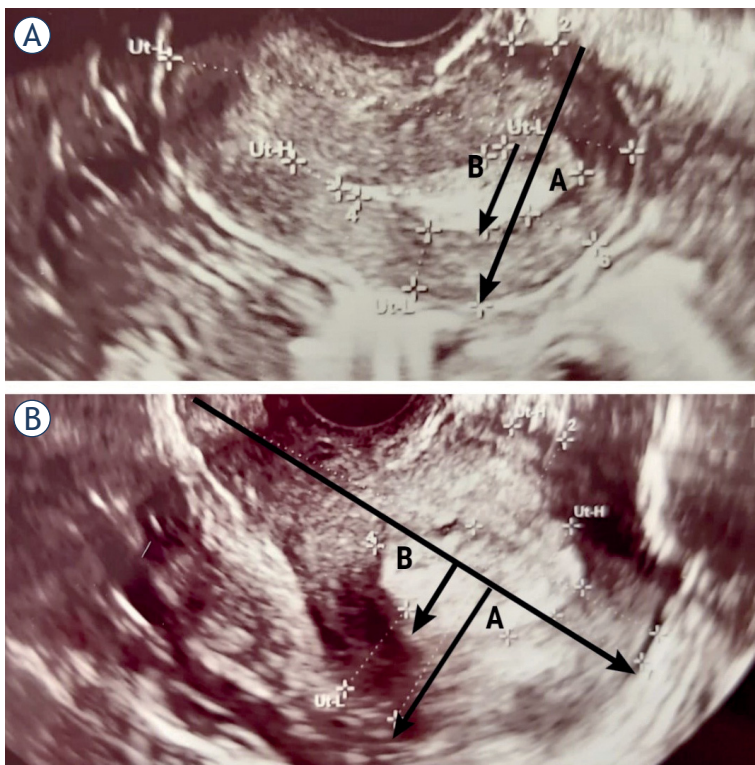
Several studies, systematic review and meta-analyses compared subjective assessment and objective TVUS measurements techniques<sup>2,5,6</sup>, TVUS (subjective assessment) and MRI<sup>3,7-11</sup>, three-dimensional TVUS and MRI<sup>12</sup>, and different MRI techniques.<sup>13-15</sup> However, to the best of our knowledge this is the first study that compared two objective TVUS measurements techniques (Gordon's and Karlsson's method) with MRI on the same set of patients.

The aim of our study was to determine the accuracy of preoperative TVUS *versus* MRI for the assessment of MI depth in EC patients, while definitive histopathological diagnosis served as a reference method.

## Patients and methods

### Patients

This prospective cohort study included 60 women with a histopathological proven endometrioid EC by dilatation and curettage, hospitalized for scheduled surgery during the period between July 2019 and April 2021 at the Clinic for Gynaecology and Obstetrics, University Clinical Centre Tuzla. Inclusion criteria were women with a histopathological proven endometrioid EC. Exclusion criteria were women with another malignant disease, who previously have surgery for EC or other malignant disease, who have previously received chemotherapy and/or radiotherapy due to a malignant disease, women with a histopathological proven EC who preoperatively have made pelvic CT, cases that were diagnosed incidentally after hysterectomy. Patients were divided into two groups, after surgery and histopathological assessment of depth of MI: invasion to less or equal and to more than half the thickness of the myometrium. The survey was approved by the Ethics Committee of the University Clinical Centre (No 02-09/2-2/20) Tuzla and signed informed consent of patients was obtained.



**FIGURE 1.** Assessment of myometrial invasion in patients with transvaginal ultrasonography (TVUS). Stage IA endometrial cancer in a 61-year-old postmenopausal woman, correctly diagnosed by TVUS and MRI. Karlsson's method indicating infiltration of superficial muscle (29%) (A). Stage IA endometrial cancer in a 53-year-old postmenopausal woman. Gordon's method indicating infiltration of superficial muscle (35%) (B).

## Methods

### Transvaginal ultrasonography

All TVUS examinations were performed by a single ultrasound examiner (CA), certified for ultrasound diagnostics, on standardized study protocol containing all investigated sonographic parameters defined before the beginning of the study. TVUS was made using a Voluson E8<sup>®</sup> equipped with a 5–9-MHz two-dimensional transducer, within ten days before surgery, without insight into the MRI finding. We assessed of MI by two TVUS methods, those proposed by Gordon *et al.* and Karlsson *et al.*<sup>2,5</sup> Transvaginally, the whole uterus was observed in sagittal and transversal section.<sup>5</sup>

Depth of MI was measured as the ratio between the maximum AP diameter of the endometrial tumor (B) and the uterine AP diameter (A) in sagittal plane, with  $B/A > 50\%$  indicating deep MI introduced by Karlsson *et al.* (Figure 1A, Figure 2A).<sup>2,5</sup> In other objective method, investigated by Gordon *et al.*, depth of MI was measured as the ratio of the distance between the maximum tumor depth (B) and the total myometrial thickness (A) in sagittal plane, with  $B/A > 50\%$  indicating deep MI (Figure 1B, Figure 2B).<sup>2,5</sup>

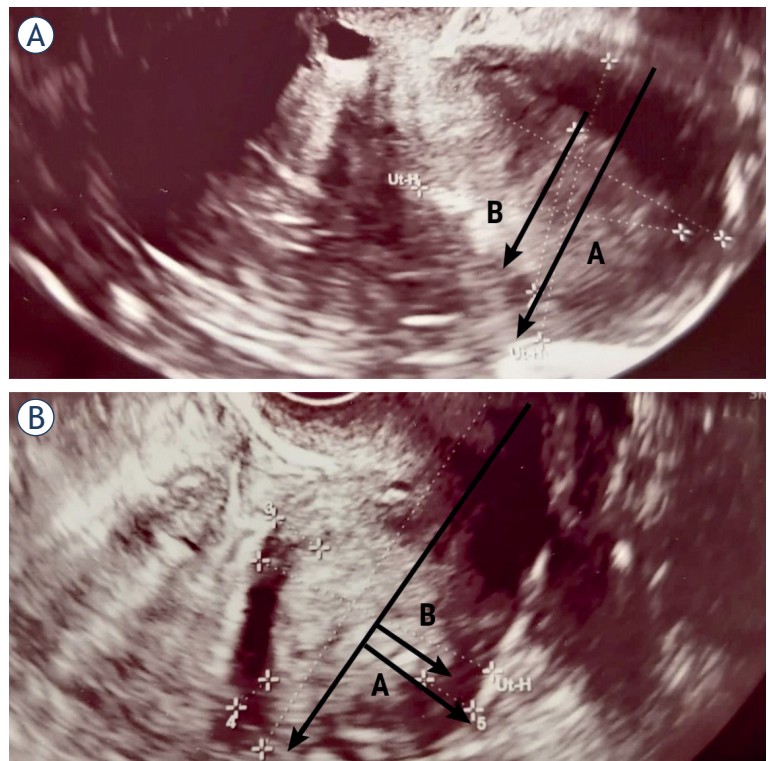
The selected cut-off limit for the extent of MI (50%) followed FIGO staging classification from 2009.<sup>5</sup>

Static images with all measurements were collected for each patient and examination protocols were noted immediately during image acquisition.

### Magnetic resonance imaging

Abdominal and pelvic MRI examination was composed of T2 and T1-weighted images and dynamic contrast-enhanced fat-suppressed images at 1.5 Tesla Avanto Siemens Medical Systems<sup>®</sup> device, according to the dedicated MRI protocol of the European Society of Uro-Genital Radiologists since 2009 for the diagnosis of EC.<sup>11,16</sup> All study participants underwent abdominal and pelvic MRI examination within 10 days prior to surgery.

MRI protocol for accurate assessment of MI, based on T2-weighted images in three orthogonal planes oriented perpendicular and parallel to the uterine cavity (sagittal, axial, coronal and oblique axial), in axial and sagittal plane in T1-weighted images and T1-weighted contrast-enhanced fat-suppressed images.<sup>14,16</sup> For optimal assessment of MI dynamic contrast-enhanced fat-suppressed MRI was done after intravenous bolus injection of



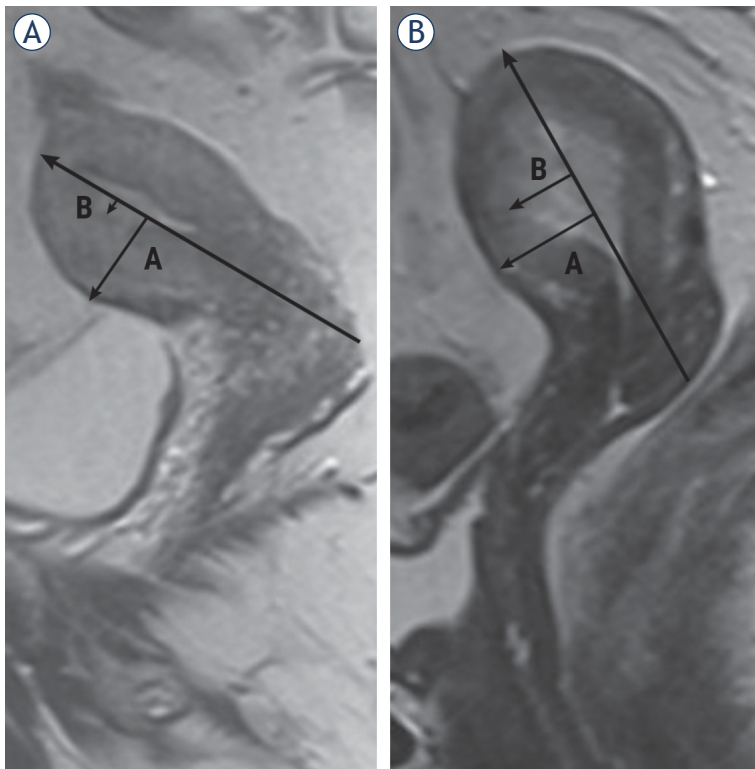
**FIGURE 2.** Assessment of myometrial invasion in patients with transvaginal ultrasonography (TVUS). Stage IB endometrial cancer in a 78-year-old postmenopausal woman, correctly diagnosed by TVUS and MRI. Karlsson's method indicating infiltration of deep muscle (58%) (A). Stage IB endometrial cancer in an 83-year-old postmenopausal woman. Gordon's method indicating infiltration of deep muscle (73%) (B).

1 mg/kg of a paramagnetic contrast agent is administered.<sup>14,16</sup>

The criteria for MRI MI diagnosis was disruption and irregularity of the endomyometrial junctional zone.<sup>12</sup> The ratio of the tumor to the endomyometrial junctional zone and the depth of MI to the junctional zone were determined. If the signal intensity of the tumour on T2W was greater than half, it was regarded as a deep MI.<sup>12</sup>

In order to measure the depth of MI on MRI, the line must be drawn along the expected inner edge of the myometrium (corresponding to the endomyometrial junctional zone) on axial oblique plane obtained perpendicular to the endometrium; then, two measures should be taken: one represents the thickness of the entire myometrium; the second is measuring the maximum range of tumor within the myometrium. The ratio of these measures represents the percentage of MI. The ratio of the thickness of the tumor from the uterine cavity to the outer border and the total thickness of the





**FIGURE 3.** Assessment of myometrial invasion in patients with MRI, sagittal T2-weighted. Stage IA endometrial cancer in a 68-year-old postmenopausal woman, correctly diagnosed by TVUS and MRI. Arrow shows blurring of the junctional zone and the infiltration of superficial muscle (20%) (A). Stage IB endometrial cancer in a 58-year-old postmenopausal woman, correctly diagnosed by TVUS and MRI. Arrows refers to deep myometrial infiltration (60%) (B).

myometrial wall on the side on which the tumor is located was calculated (Figure 3).

The radiologist was not blinded to the diagnosis of EC but remained unaware of the TVUS results. All analyses have been performed by the same radiologist (LA), with experience in analysing abdominal and pelvic MRI.

### Surgical procedure

Primary surgery was performed by an gynaecological oncological surgeon with experience in gynaecologic-oncological surgery in median ten days after MRI, and ten day after TVUS.

Scheduled surgery was indicated based on preoperative histopathological diagnosis with tumour type and grade, TVUS and MRI. The surgeon was not blinded towards the histopathological diagnosis, TVUS and MRI results.<sup>11</sup> Surgery was performed by an open abdominal approach and according to the decision of the gynaecologic-

**TABLE 1.** Demographic and clinical characteristics of 60 women with histologically confirmed endometrial cancer

Characteristics	Value (%)
Age (years)	60 (40–83)
Body mass index (kg/m <sup>2</sup> )	32.05 (21.6–49.2)
Postmenopausal	45 (75)
Myometrial invasion	
Superficial ( $\leq 50\%$ )	34 (56.7)
Deep ( $> 50\%$ )	26 (43.3)
Hystological grade	
Grade 1	18 (30)
Grade 2	35 (58)
Grade 3	7 (12)

Data are given as median (5th percentile; 95th percentile) for continuous variables; n (%) for categorical variables.

oncological interdisciplinary tumour board. The surgical approach was planned based on the FIGO classification derived from MRI.<sup>11</sup> The depth of MI obtained by TVUS and MRI has been correlated to help shed light on the dilemma of whether classical hysterectomy with bilateral adnexectomy is sufficient or pelvic lymphadenectomy is necessary for oncological treatment to be adequate.

### Histopathological diagnosis

Surgical specimens were examined by pathologists with experience in gynaecologic oncology using a predetermined protocol regarding: histological subtype, grade, lymphovascular invasion, tumour size, depth of myometrial invasion, minimal tumour-free myometrium, presence of cervical stromal invasion, presence, location and number of fibroids.<sup>5</sup> The FIGO 2009 criteria were applied for clinical staging. The “gold standard” was based on final histology of the specimen obtained by hysterectomy.<sup>5</sup>

### Statistical analysis

Basic tests of descriptive statistics were made, showing the measures of central tendency and dispersion (Table 1). Sensitivity, specificity, positive predictive value (PPV) and negative predictive value (NPV), overall accuracy, likelihood ratio of a positive test, likelihood ratio of a negative test, as well as receiver operating characteristics (ROC)

**TABLE 2.** Myometrial invasion in endometrial cancer according to histopathology, transvaginal ultrasonography and magnetic resonance imaging

Histopathology	TVUS (Gordon)		TVUS (Karlsson)		MRI		Total N(%)
	≤ 50% N(%)	> 50% N(%)	≤ 50% N(%)	> 50% N(%)	≤ 50% N(%)	> 50% N(%)	
≤ 50% N (%)	30 (88.2)	4 (11.8)	30 (88.2)	4 (11.8)	29 (85.3)	5 (14.7)	34 (100)
> 50% N(%)	6 (23.1)	20 (76.9)	8 (30.8)	18 (69.2)	1 (3.8)	25 (96.2)	26 (100)
<b>Total</b>	36 (60)	24 (40)	38 (63.3)	22 (36.7)	30 (50)	30 (50)	60 (100)

TVUS = transvaginal ultrasound

curves assessing MI were calculated for each staging method (TVUS; Gordon's and Karlsson's method and MRI) in comparison to the final histology. Receiver operating characteristic (ROC) curves were used to evaluate the accuracy of the tests.

Statistical processing was done in the software package SPSS 24.0 (Chicago, IL, USA). All statistical tests were performed with a statistical probability level of 95% ( $p < 0.05$ ).

## Results

Of 72 cases diagnosed with endometrioid EC during the study period and who underwent preoperative TVUS and MRI, 60 cases were enrolled in the study, of mean (SD) age 60 (10) in range from 40–83 years. Forty-five (75%) out of the 60 were postmenopausal. Median body mass index was 32.05 kg/m<sup>2</sup> (range 21.6–49.2). The most frequently encountered histological grade was grade 2 (58%, 35/60).

Twelve cases (16.6%) evaluated during the study period were excluded from the database, because of preoperatively made CT (morbid obesity and/or claustrophobia).

The patient demographics and tumour characteristics are summarized in Table 1.

Regarding final surgical procedure, 60 cases (100%) underwent open surgery. Hysterectomy with bilateral adnexectomy was performed in 60 cases (100%). Pelvic lymphadenectomy was performed in 32 cases out of 60 (53.3%). Pelvic lymphadenectomy was performed in eight cases out of 36 (22.2%) with MI ≤ 50%, in 24 cases out of 26 (92.3%) with MI > 50%, that is statistically significant frequently in group with MI > 50% ( $z = -5.29$ ,  $p < 0.00001$ ).

According to the gold standard, histopathological diagnostics, there were 34 (56.7%) cases in the study with MI ≤ 50%, and 26 (43.3%) with MI > 50%.

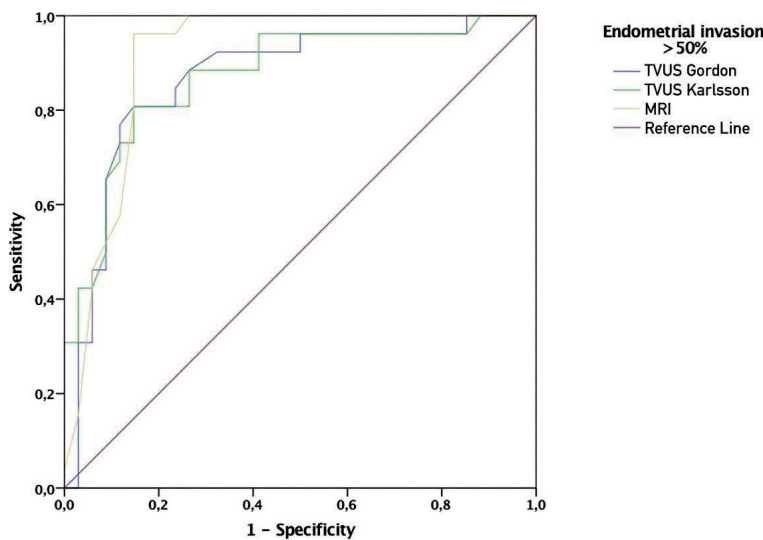
The depth of MI was correctly assessed by Gordon's method in 50 (83.3%) cases, overestimated in four (6.6%) and underestimated in six (10%) (Table 2).

The concordance coefficient between TVUS and histopathology was also statistically significant ( $p < 0.001$ ) and kappa was 0.658. These data corresponded to a PPV of 83% and NPV of 83%, 77% sensitivity, 88% specificity, and 83% overall accuracy (Table 3).

**TABLE 3.** Diagnostic performance of transvaginal ultrasonography and magnetic resonance imaging in predicting myometrial invasion in endometrial cancer

Diagnostic test measure	TVUS (Gordon)	TVUS (Karlsson)	MRI
	%, (95% CI)	%, (95% CI)	%, (95% CI)
<b>Accuracy</b>	83 (70–92)	80 (67–88)	90 (78–93)
<b>Sensitivity</b>	77 (62–87)	69 (54–79)	97 (83–99)
<b>Specificity</b>	88 (77–96)	88 (77–96)	85 (75–88)
<b>Positive predictive value</b>	83 (67–94)	82 (64–93)	83 (72–87)
<b>Negative predictive value</b>	83 (72–90)	79 (69–86)	97 (85–99)
<b>Likelihood Ratio of a Positive Test</b>	6.54 (2.65–19.00)	5.89 (2.30–18.17)	6.54 (3.31–8.37)
<b>Likelihood Ratio of a Negative Test</b>	0.26 (0.14–0.50)	0.35 (0.22–0.60)	0.05 (0.002–0.23)

The estimates are stated along with the 95% confidence intervals (95% CI); TVUS = transvaginal ultrasound



**FIGURE 4.** Receiver operating characteristics (ROC) analysis for percentage assessment of myometrial invasion (MI) with transvaginal ultrasound (TVUS) by Gordon's and Karlsson's, and with MRI

The depth of MI was correctly assessed by Karlsson's method in 48 (80%) cases, overestimated in four (6.6%) and underestimated in eight (13.3%) (Table 2). The concordance coefficient between TVUS and histopathology was statistically significant ( $p < 0.001$ ) and kappa was 0.585. Accordingly, Karlsson's method calculating MI reached PPV of 82% and NPV of 79%, 69% sensitivity, 88% specificity, and 80% overall accuracy (Table 3).

MRI correctly assessed MI in 54 (90%) cases, overestimated it in five (8.3%) cases and underestimated it in one (1.6%) (Table 2). The concordance coefficient between MRI and histopathology was statistically significant ( $p < 0.001$ ) and kappa was 0.80. Accordingly, MRI calculating MI reached PPV of 83% and NPV of 97%, 97% sensitivity, 85% specificity, and 90% overall accuracy (Table 3).

The diagnostic performance of two objective transvaginal ultrasonography methods assessment

and MRI calculations in predicting deep MI as well as the statistical comparison of ultrasonography to MRI method are introduced in Table 3.

Differences in the performance of the two TVUS imaging modalities (Karlsson *vs.* Gordon) were not statistically significant ( $p = 0.867$ ). Differences in the performance between the Gordon's method and MRI were not statistically significant ( $p = 0.417$ ). Differences in the performance between of the Karlsson's method and MRI were not statistically significant ( $p = 0.464$ ).

The prevalence of myometrial pathology was the same in the incorrectly classified patients in TVUS and MRI methods of assessment of MI. Of the 10 patients in whom infiltration was misclassified on TVUS and of the 6 patients misclassified on MRI, 5 (50%) and three (50%) had benign myometrial pathologies (adenomyosis and leiomyoma), respectively.

TVUS and MRI correctly estimated MI in 45 (75%) patients, underestimated it in one (1.6%) and overestimated it in two (3.3%). If we consider only the cases in which the two techniques were in agreement (48 cases), the concordance with histology was 80%.

Evaluation of diagnostic accuracy was performed through Receiver Operating Characteristics (ROC) analysis and for percentage assessment of MI with TVUS by Gordon's and Karlsson's method, and with MRI. A graphical representation of this analysis is given in Figure 4, and a tabular representation of the areas below the ROC curve (AUC) in the Table 4.

As can be seen, the best diagnostic accuracy according to the ROC analysis had MRI with an AUC of 0.911 (total accuracy 91.1%), which is in correlation with the already performed diagnostic accuracy analyses.

## Discussion

In this prospective, comparative, ultrasonographer-blinded study on patients with EC two objective TVUS methods (Gordon's and Karlsson's) and MRI were compared for the MI assessment in the same cohort of patients. All three tested approaches were found to be statistically significant predictors of the MI, exceeding AUC value of 0.85 and reaching final  $p$  value  $< 0.001$ . We found that MRI assessment of MI is better than any objective TVUS measurement technique in all measures of the diagnostic tests, but without statistically significance.

**TABLE 4.** Representation of the areas below the receiver operating characteristics (ROC) curve (AUC) for percentage assessment of MI with transvaginal ultrasound (TVUS) by Gordon and Karlsson, and with MRI

Method of assessment	AUC	P	95% CI for AUC	
			Lower limit	Upper limit
TVUS (Gordon)	0.872	$< 0.001$	0.769	0.965
TVUS (Karlsson)	0.865	$< 0.001$	0.766	0.964
MRI	0.911	$< 0.001$	0.833	0.989

Median age in our patients is similar to Pineda *et al.* study<sup>17</sup>, 60 vs. 60.9, respectively, however there are studies with higher<sup>1,4-6,8</sup>, and lower median age.<sup>12,18</sup>

Postmenopausal in recent study were 75% patients which correlate with other studies, where postmenopausal patients were in the range from 70.2% to 92%.<sup>5-10,15,17,19</sup> EC is disease of older and postmenopausal women, that was also confirmed by our study.<sup>3</sup>

Patients in recent study were obese with an median body mass index (BMI) of 32.05 which is similar to median BMI of 31 in Rei *et al.* study<sup>8</sup>, however there are studies with higher<sup>7,15</sup> and lower median BMI.<sup>4-6,17,19</sup> Obesity is a proven risk factor for developing EC, what was also confirmed by recent study.<sup>8</sup>

The most frequently encountered histological grade in recent study was grade 2 (58%) which is the same percentage as in Karatasli *et al.* study.<sup>15</sup> In most of the reviewed studies, histological grade 1 is more common than other grades which agrees with the fact that endometrial cancer is usually a well-differentiated.<sup>1,5-7,10,14,17</sup>

In current study according to the gold standard, histopathological diagnostics, it is more common superficial MI ( $\leq 50\%$ ), which correlate with most reviewed studies and with fact that EC is detected at an early stage in most cases.<sup>4-8,10-12,14,15,18,22,23</sup>

Several studies evaluated objective measurements such as those proposed by Gordon *et al.* and Karlsson *et al.*<sup>2,3</sup>

Alcazar *et al.* in systematic review and meta-analysis found that the overall diagnostic performance of TVUS for Karlsson's and Gordon's method in detecting deep MI in women with EC gave a pooled sensitivity of 84 % and 85 %, pooled specificity of 82% and 80% which is higher sensitivity and lower specificity than in our study for both methods.<sup>2</sup> They observed that both methods were similar, without statistical differences, in terms of diagnostic performance, similar as in our study.<sup>2</sup>

In reviewed studies diagnostic performance for Gordon's method reached sensitivity from 69.6% to 92.3%, specificity from 65.9% to 79.2%, PPV from 56.7% to 61%, NPV from 77.1% to 96.1% and overall accuracy from 67.3% to 82.6%.<sup>1,5</sup>

Recent studies reported for Karlsson's method sensitivity from 56.3% to 86.8%, specificity from 64.4% to 76.4%, PPV from 62.8% to 83.6%, NPV from 70% to 71.2% and overall accuracy 68.1%.<sup>5,6,19,21</sup>

Besides, current study did not find statistical differences between Gordon's and Karlsson's method. Although both TVUS objective calcula-

tions, Gordon's and Karlsson's method, had similar accuracy, the approach published by Gordon *et al.* have better sensitivity and accuracy in preoperative assessment of MI in EC. However, in our opinion Gordon's method might be more difficult for assessment of MI.<sup>5</sup> On the other side, under or overestimation of MI by Karlsson's method is often caused by large polypoid EC, submucosal leiomyomas and adenomyosis which make longer antero-posterior uterine diameter.<sup>5</sup>

In 2017 Alcazar *et al.* published a systematic review and meta-analysis based on preoperative detection of deep MI comparing TVUS and MRI on the same set of women.<sup>3</sup> However, they found out that sensitivity and specificity for diagnosing deep MI were 75% and 82% for TVUS, and 83% and 82% for MRI, respectively. MRI showed a better sensitivity than TVUS for detecting depth of MI in women with EC, but without statistical differences, as in our study.<sup>3</sup> However, none of these studies compared the three imaging methods altogether in one cohort of patients as is the case in our comparative study.

In analysed studies diagnostic performance for MRI reached sensitivity from 70% to 92.6%, specificity from 71% to 95%, PPV from 65% to 92.2%, NPV from 70% to 98%, and overall accuracy from 74% to 89%.<sup>7-10,12-15,20-22</sup>

We have shown that two imaging modalities (contrast-enhanced MRI and TVUS) perform equally well in the assessment of MI, differences in the performance were not statistically significant.

Cubo-Abert *et al.* obtained similar results as in our study, when it comes to the diagnostic accuracy of TVUS *versus* MRI in estimating the depth of MI, with the difference that they used the TVUS method based on the measurement of the minimal distance to the uterine serosa.<sup>24</sup>

Costas *et al.* in systematic review and meta-analysis have not found a satisfying number of studies about the comparison of 2D-TVUS and 3D-TVUS methods for MI assessment in EC.<sup>25</sup> They have identified lack of knowledge and studies regarding the objective methods used for 3D-TVUS assessment and their comparison with subjective 3D-TVUS methods.<sup>25</sup>

Although the definitive staging of endometrial cancer is based on histopathology, an accurate preoperative assessment of MI by TVUS and/or MRI provides the opportunity for surgical planning to provide an adequate type of surgery, the need of a multidisciplinary team, time management in the operating room, and avoid morbidity associated with unnecessary lymphadenectomy.<sup>8,9,23</sup>



Causes of over or understaging were similar for the TVUS and MRI: a polypoid EC, large exophytic tumors with distension and thinning of the myometrium with regular endometrial junction and without MI, fibromatosis, adenomyosis, leiomyomata, deep MI, small isolated glandular foci, uterine anomalies, uterine prolapse or retroversion, short time after previous endometrial biopsy, poorly defined endometrial borders on TVUS, and disappearance of the junctional zone on MRI.<sup>1,6,7,9,19</sup>

Considering that there are no statistically significant differences in diagnostic performance between TVUS and MRI and the cost and availability of MRI, TVUS may have a role as the first imaging technique for assessing MI in women with EC, especially as it is implemented in the everyday practice of gynecologists.<sup>1,2,4,8</sup>

As Miklos *et al.* concluded the diagnostic accuracy of the TVUS depends more on the individual experience and professional potential of the examiner than diagnostic accuracy of the MRI.<sup>1</sup> Examiner experience, technological advances and different protocols for assessing MI among the studies, for both TVUS and MRI can contribute to the heterogeneity of published results of TVUS and MRI in the assessment of MI.<sup>1,3,8</sup> Expert TVUS and MRI were comparable and superior to non-expert TVUS for assessing MI in EC.<sup>26</sup>

MRI, which is more expensive, time consuming and difficult to access, could be employed as a second-line imaging technique in patients in whom TVUS gives images of poor quality in case of obesity and factors above mentioned that may cause over or understaging.<sup>9</sup>

MRI is currently recommended for preoperative imaging in some guidelines, as the imaging modality of choice and most appropriate for the assessment of disease extent in patients with newly diagnosed EC.<sup>3,15,20</sup>

Iitsuka *et al.* in their study and review of literature found that their data and the pooled analysis with previous studies indicate that the frozen section diagnosis is sensitive as MRI assessment in predicting deep MI, and has a higher specificity compared with MRI.<sup>27</sup>

Contraindications for MRI should also be kept in mind, when MRI cannot be performed such as metal foreign body, pathologic obesity, contrast allergies and claustrophobia.

The main strength of our study is that, to the best of our knowledge, this is the first study that compares prospectively the two objective TVUS methods (Gordon's and Karlsson's) and objective MRI

method, for assessing MI in patients with endometrioid EC in the same set of patients. A strength of our study are the prospective design and the fact that the gynaecologists performing TVUS and the radiologists performing MRI were blinded to each other's results. Another strength is that all TVUS assessment of MI were made by the same physician, MRI assessment of MI by the same radiologist, and all surgeries and pathologic examinations were done at the same center. Strength of our study is also that we compared the three imaging methods altogether in one cohort of patients which is ideally, for comparing the diagnostic performance of different approaches to assess MI, and this is rarity in reviewed studies.

Limitations of our study are the relatively small number and short time of collection of participants, but this can be justified by the prospective design of the study, the strict inclusion and exclusion criteria, and in fact that the study was performed in the largest tertiary center in the country.

## Conclusions

In conclusion, we found that objective TVUS assessment of myometrial invasion was performed with a diagnostic accuracy comparable to that of MRI in women with endometrial cancer. Further multi-centric studies with prospective designs and standardized protocols are needed to investigate which objective measurement techniques and MRI have the highest reproducibility, and how well they perform in the hands of examiners with more or less experience. In addition, studies evaluating inter-observer agreement as well as the impact of TVUS training would be of great interest.

## Acknowledgments

This article is a part of research conducted within the doctoral dissertation of Anis Cerovac.

We are thankful to personnel of the Clinic for Gynecology and Obstetrics, Clinic for Radiology and Nuclear Medicine and Polyclinic for Laboratory Diagnostics, University Clinical Center Tuzla for their cooperation.

We give our deep appreciation to all women who participated in this trial because with their participation they can help women with endometrial cancer, but also offer new diagnostic approach and opportunities for future generations.



## References

- Miklos P, Klacko M, Babala P, Masak L, Ondrus D, Waczulikova I. Transvaginal ultrasound examination of myometrial infiltration by endometrial cancer. *Bratisl Lek Listy* 2014; **115**: 14-18. doi: 10.4149/bl\_2014\_003
- Alcázar JL, Orozco R, Martínez-Astorquiza Corral T, Juez L, Utrilla-Layna J, Mínguez JA, et al. Transvaginal ultrasound for preoperative assessment of myometrial invasion in patients with endometrial cancer: a systematic review and meta-analysis. *Ultrasound Obstet Gynecol* 2015; **46**: 405-13. doi: 10.1002/uog.14905
- Alcázar JL, Gastón B, Navarro B, Salas R, Aranda J, Guerrero S. Transvaginal ultrasound versus magnetic resonance imaging for preoperative assessment of myometrial infiltration in patients with endometrial cancer: a systematic review and meta-analysis. *J Gynecol Oncol* 2017; **28**: e86. doi: 10.3802/jgo.2017.28.e86
- Eriksson LSE, Lindqvist PG, Flöter Rådestad A, Dueholm M, Fischerova D, Franchi D, et al. Transvaginal ultrasound assessment of myometrial and cervical stromal invasion in women with endometrial cancer: interobserver reproducibility among ultrasound experts and gynecologists. *Ultrasound Obstet Gynecol* 2015; **45**: 476-82. doi: 10.1002/uog.14645
- Frühau F, Zikan M, Semerádova I, Dunder P, Nemejcova K, Dusek L, et al. The diagnostic accuracy of ultrasound in assessment of myometrial invasion in endometrial cancer: subjective assessment versus objective techniques. *Biomed Res Int* 2017; **2017**: 1318203. doi: 10.1155/2017/1318203
- Mascilini F, Testa AC, Van Holsbeke C, Amey L, Timmerman D, Epstein E. Evaluating myometrial and cervical invasion in women with endometrial cancer: comparing subjective assessment with objective measurement techniques. *Ultrasound Obstet Gynecol* 2013; **42**: 353-8. doi: 10.1002/uog.12499
- Ozdemir S, Celik C, Emlik D, Kiresi D, Esen H. Assessment of myometrial invasion in endometrial cancer by transvaginal sonography, Doppler ultrasonography, magnetic resonance imaging and frozen section. *Int J Gynecol Cancer* 2009; **19**: 1085-90. doi: 10.1111/IGC.0b013e3181ad3eb6
- Rei M, Rodrigues I, Condeco P, Igreja F, Verissimo C, Mendinhos G. Endometrial cancer: preoperative versus intraoperative staging. *J Gynecol Obstet Hum Reprod* 2019; 101647. doi: 10.1016/j.jogoh.2019.101647
- Savelli L, Ceccarini M, Ludovisi M, Fruscella E, De Iaco PA, Salizzoni E, et al. Preoperative local staging of endometrial cancer: transvaginal sonography vs. magnetic resonance imaging. *Ultrasound Obstet Gynecol* 2008; **31**: 560-6. doi: 10.1002/uog.5295
- Yin XH, Jia HY, Shi M, Wu H, Li YM. Magnetic resonance imaging for detection of depth of myometrial invasion and cervical invasion in patients with endometrial carcinoma. *Int J Clin Exp Med* 2015; **8**: 19501-5. PMID: PMC4694500
- Brockner KA, Radtke JP, Hallscheidt P, Sohn C, Schlemmer HP, Alt CD. Comparison of the determination of the local tumor extent of primary endometrial cancer using clinical examination and 3 Tesla magnetic resonance imaging compared to histopathology. *Arch Gynecol Obstet* 2019; **299**: 1391-8. doi: 10.1007/s00404-019-05072-5
- Yang T, Tian S, Li Y, Tian X, Wang W, Zhao J, et al. Magnetic resonance imaging (MRI) and three-dimensional transvaginal ultrasonography scanning for preoperative assessment of high risk in women with endometrial cancer. *Med Sci Monit* 2019; **25**: 2024-31. doi: 10.12659/MSM.915276
- Bi Q, Chen Y, Wu K, Wang J, Zhao Y, Wang B, et al. The diagnostic value of MRI for preoperative staging in patients with endometrial cancer: a meta-analysis. *Acad Radiol* 2020; **27**: 960-8. doi: 10.1016/j.acra.2019.09.018
- Goel G, Rajanbabu A, Sandhya CJ, Nair IR. A prospective observational study evaluating the accuracy of MRI in predicting the extent of disease in endometrial cancer. *Indian J Surg Oncol* 2019; **10**: 220-4. doi: 10.1007/s13193-018-0832-9
- Karataşlı V, Çakır I, Şahin H, Ayaz D, Sancı M. Can preoperative magnetic resonance imaging replace intraoperative frozen sectioning in the evaluation of myometrial invasion for early-stage endometrial carcinoma? *Ginekolo Pol* 2019; **90**: 128-33. doi: 10.5603/GP.2019.0023
- Rizzo S, Femia M, Buscarino V, Franchi D, Garbi A, Zanagnolo V, et al. Endometrial cancer: an overview of novelties in treatment and related imaging keypoints for local staging. *Cancer Imaging* 2018; **18**: 45. doi: 10.1186/s40644-018-0180-6
- Pineda L, Alcázar JL, Caparrós M, Mínguez JA, Idoate MA, Quiceno H, et al. Agreement between preoperative transvaginal ultrasound and intraoperative macroscopic examination for assessing myometrial infiltration in low-risk endometrioid carcinoma. *Ultrasound Obstet Gynecol* 2016; **47**: 369-73. doi: 10.1002/uog.14909
- Tatar B. Assessment of myometrial invasion of endometrial carcinoma with preoperative transvaginal sonography. *Eur J Gynaecol Oncol* 2021; **42**: 85-9. doi: 10.31083/j.ejgo.2021.01.2236
- Capozzi VA, Merisio C, Rolla M, Pugliese M, Morganelli G, Cianciolo A, et al. Confounding factors of transvaginal ultrasound accuracy in endometrial cancer. *J Obstet Gynaecol* 2021; **41**: 779-84. doi: 10.1080/01443615.2020.1799342
- Horváth K, Pete I, Vereczky I, Dudnykova A, Gódey M. Evaluation of the accuracy of preoperative MRI in measuring myometrial infiltration in endometrial carcinoma. *Pathol Oncol Res* 2014; **20**: 327-33. doi: 10.1007/s12253-013-9699-9
- Gastón B, Muruzábal JC, Lapeña S, Modroño A, Guarch R, García de Eulate I, et al. Transvaginal ultrasound versus magnetic resonance imaging for assessing myometrial infiltration in endometrioid low grade endometrial cancer: a prospective study. *J Ultrasound Med* 2022. **41**: 335-42. doi: 10.1002/jum.15708
- Wu WJ, Yu MS, Su HY, Lin KS, Lu KL, Hwang KS. The accuracy of magnetic resonance imaging for preoperative deep myometrium assessment in endometrial cancer. *Taiwan J Obstet Gynecol* 2013; **52**: 210-4. doi: 10.1016/j.tjog.2013.04.010
- Sobočan M, Ogrizek AM, Ledinek T, Takač I, Knez J. Importance of preoperative ultrasound examination and pathological tumour evaluation in the management of women with endometrial cancer. *Eur J Obstet Gynecol Reprod Biol* 2021; **257**:121-6. doi: 10.1016/j.ejogrb.2020.12.029
- Cubo-Abert M, Díaz-Feijoo B, Bradbury M, Rodríguez-Mías NL, Vera M, Pérez-Hoyos S, et al. Diagnostic performance of transvaginal ultrasound and magnetic resonance imaging for preoperative evaluation of low-grade endometrioid endometrial carcinoma: prospective comparative study. *Ultrasound Obstet Gynecol* 2021; **58**: 469-75. doi: 10.1002/uog.23607
- Costas T, Belda R, Alcázar JL. Transvaginal three-dimensional ultrasound for preoperative assessment of myometrial invasion in patients with endometrial cancer: a systematic review and meta-analysis. *Med Ultrason* 2021. [Ahead of print]. doi: 10.11152/mu-2961
- Dueholm M, Hjorth IM, Dahl K, Marinovskij E, Ørtoft G. Preoperative prediction of high-risk endometrial cancer by expert and non-expert transvaginal ultrasonography, magnetic resonance imaging, and endometrial histology. *Eur J Obstet Gynecol Reprod Biol* 2021; **263**: 181-91. doi: 10.1016/j.ejogrb.2021.05.041
- Iitsuka C, Asami Y, Hirose Y, Nagashima M, Mimura T, Miyamoto S, et al. Preoperative magnetic resonance imaging versus intraoperative frozen section diagnosis for predicting the deep myometrial invasion in endometrial cancer: our experience and literature review. *J Obstet Gynaecol Res* 2021; **47**: 3331-8. doi: 10.1111/jog.14891