



OPEN ACCESS

Images in cardiology

The wide spectrum of aortic root dilatation after the Ross operation

Ryo Torii^{1,2,*}, Michael Ibrahim³, Tarun Mittal⁴, Su-Lin Lee⁵, Magdi H. Yacoub^{2,3}

¹Department of Mechanical Engineering, University College London, UK

²Qatar Cardiovascular Research Center, Doha, Qatar

³Harefield Heart Science Centre, Harefield Hospital and Imperial College London, UK

⁴Department of Radiology, Harefield Hospital, UK

⁵Department of Computing, Imperial College London, UK

*Email: r.torii@ucl.ac.uk

INTRODUCTION

The Ross root replacement is the only technique that guarantees long-term viability of all the component parts of the root. The normal aortic root performs extremely sophisticated functions which are closely linked to its structure, dynamics and viability.¹ This has been shown to translate into clinically-relevant endpoints, such as survival and quality of life.² The insertion of the pulmonary autograft as a freestanding root guarantees optimal relationship between the component parts with no distortion.³ Although the pulmonary valve is known to adapt to the new environment,⁴ there is continuing concern about the risk of long-term autograft dilatation and aortic regurgitation.⁵ We here describe two patients with considerably different types of changes in shape and size of the aortic root, in comparison to two age- and gender-matched controls.

The patients are: (1) 62-year-old female, 13.4 years after the operation and (2) 47-year-old male, 15.6 years after the operation. The patients were scanned using Toshiba Aquilion 64 multi-slice scanner as part of clinical follow-up. Three-dimensional anatomical models of the aortic root were then reconstructed, by segmenting the luminal volume in reference to the CT image intensity. The shape of the root was visualized as in the figure, and the sinus sizes were quantified in terms of width, bulge and height of each sinus. The mean sinus diameters of the patients 1 and 2, as the average of three cusp-to-commissure lengths, were 31.9 mm and 51.9 mm, respectively. Those of controls were 32.6 mm and 32.8 mm. The 3D model as well as the sinus sizes plot demonstrate asymmetry feature of the autograft roots unlike controls which are symmetrical. The smaller autograft root (Patient 1) has symmetric bulge and height but asymmetric width whereas the larger autograft root (Patient 2) has symmetric width but asymmetric bulge and height, both of which indicate larger right- and non-coronary sinuses than left-coronary sinus (Figure 1).

CONCLUSIONS AND FUTURE DIRECTIONS

This investigation of two Ross roots shows a wide spectrum of aortic root shape and size as the result of adaptation more than 13 years after the operation. The findings demonstrate the patient-specific nature of the interaction between the tissue valve and the host.⁶ More comprehensive analysis over larger patient population is warranted.

<http://dx.doi.org/10.5339/gcsp.2014.9>

Submitted: 28 February 2014

Accepted: 11 April 2014

© 2014 Torii, Ibrahim, Mittal, Lee, Yacoub, licensee Bloomsbury Qatar Foundation Journals. This is an open access article distributed under the terms of the Creative Commons Attribution license CC BY 4.0, which permits unrestricted use, distribution and reproduction in any medium, provided the original work is properly cited.

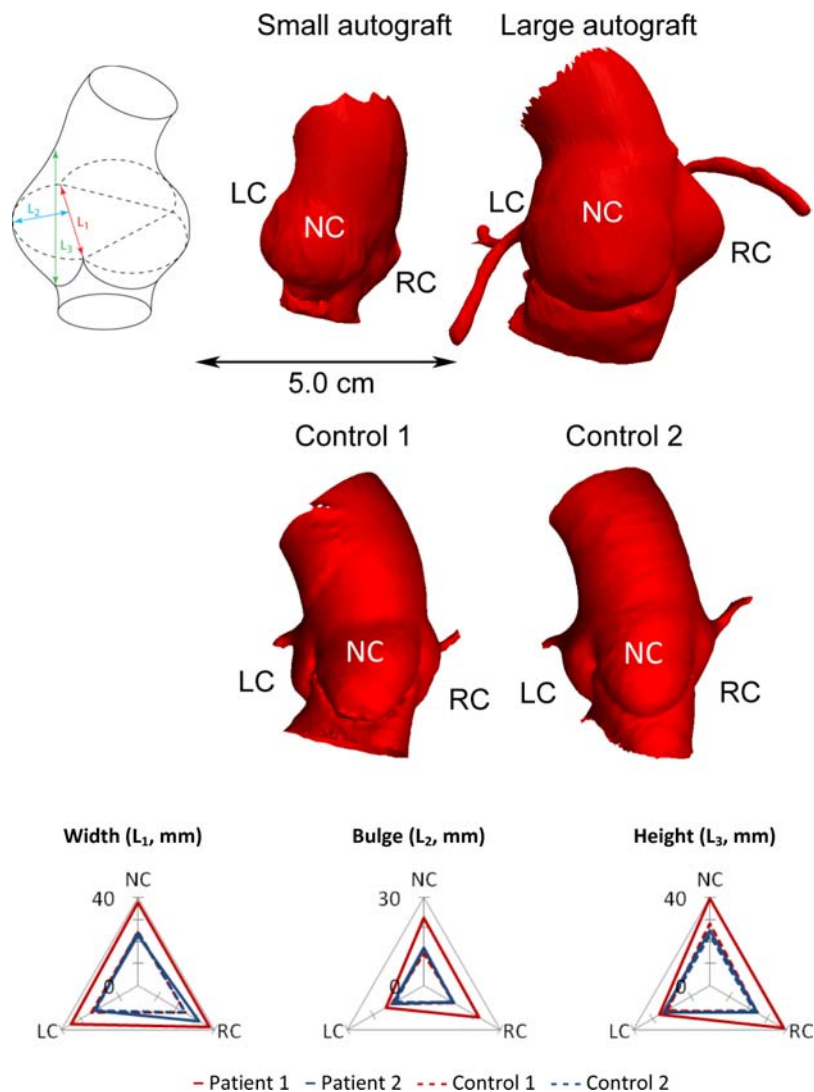


Figure 1. Two three-dimensional anatomical models of the aortic root reconstructed from CT angiogram of 62-year-old female (top middle) and 47-year-old male patient (top right) showing broad spectrum of the shape and size. Two normal anatomical models of age- and gender-matched controls as also shown in the middle panel. The sinus morphology was quantified using these models with the parameters in the top left panel (L_1 : width, L_2 : depth and L_3 : height) and the results are shown in the bottom panel. LC, NC and RC stand for left-coronary, non-coronary and right-coronary sinuses, respectively.

Acknowledgements

Dr Torii was supported by the Qatar Foundation as the Qatar Cardiovascular Research Center Fellow during a part of the study.

REFERENCES

- [1] Yacoub MH, Kilner PJ, Birks EJ, Misfeld M. The aortic outflow and root: a tale of dynamism and crosstalk. *Ann Thorac Surg.* 1999;68(3):S37–S43.
- [2] El-Hamamsy I, Eryigit Z, Stevens LM, Sarang Z, George R, Clark L, Melina G, Takkenberg JJ, Yacoub MH. Long-term outcomes after autograft versus homograft aortic root replacement in adults with aortic valve disease: a randomised controlled trial. *Lancet.* 2010;376(9740):524–531.
- [3] Gula G, Ahmed M, Thompson R, Radley-Smith R, Yacoub MH. Combined homograft replacement of the aortic valve and aortic root with replantation of the coronary arteries. *Circulation.* 1976;54(Suppl II):150.
- [4] Yacoub MH. The ross operation – an evolutionary tale. *Asian Cardiovasc Thorac Ann.* 2006;14(1):1–2.
- [5] Luciani GB, Casali G, Favaro A, Prioli MA, Barozzi L, Santini F, Mazzucco A. Fate of the aortic root late after Ross operation. *Circulation.* 2003;108(Suppl 1):1161–1167.
- [6] Yacoub MH, El-Hamamsy I. Valvular disease: the private life of tissue valves. *Nat Rev Cardiol.* 2010;7(8):424–426.