

Does Pedicle Screw Fixation Assisted by O-Arm Navigation Perform Better Than Fluoroscopy-guided Technique in Thoracolumbar Fractures in Percutaneous Surgery?

A Retrospective Cohort Study

Jianhua Lu, MD, Weikai Chen, MD, Hao Liu, MD, Huilin Yang, PhD, and Tao Liu, MD, PhD

Study Design: A retrospective cohort study.

Objective: To evaluate the effect of O-arm navigation in percutaneous surgeries for thoracolumbar fracture in comparison to the use of conventional fluoroscopic technique.

Summary of Background Data: O-arm navigation is a progressive surgical tool, with extensive research papers reporting its effects. Whereas, there were not many papers describing its accuracy and facet impingement rate when compared with fluoroscopy-guided technique in percutaneous surgeries, especially at varying fracture levels.

Materials and Methods: We conducted a retrospective comparative study of 97 consecutive patients of single-level neurological intact thoracolumbar fractures from November 2015 to October 2017 and they were all treated with percutaneous pedicle screw implantation. Screws were classified as 4 grades of perforations and 3 grades of facet joint violation. The association between variables such as anatomic perforation, functional perforation, and facet impingement were investigated by χ^2 test, Fisher exact test or *t* test. A *P*-value of <0.05 was considered statistically significant.

Results: A total of 573 pedicle screws were implanted and graded. The overall anatomic perforation rate and functional perforation rate were lower in the O-arm group compared with the fluoroscopy

group (8.3% vs. 15.0%, *P*=0.013, 1.1% vs. 4.2%, *P*=0.024). At fracture level, the rate of grade 2 perforation of the O-arm group was lower than that of the fluoroscopy group (0% vs. 6.1%, *P*=0.033). Furthermore, the O-arm group obviously reduced the facet impingement rate both at all levels and at fracture levels (*P*=0.002; 0.02).

Conclusions: In percutaneous pedicle screw placement for neurological intact thoracolumbar fracture, the introduction of O-arm navigation improved accuracy, reduced functional perforations, and minimized serious perforations compared with conventional fluoroscopic technique. It also decreased facet joint violation observably and helped to prevent development of adjacent segment degeneration.

Key Words: pedicle screw insertion, spinal navigation system, imaging-guided surgery, accuracy, facet impingement

(*Clin Spine Surg* 2020;33:247–253)

BACKGROUND

Thoracolumbar fracture is one of the most common fractures in the axial skeleton and usually results in a surgical correction.¹ Nowadays, owing to the benefit of achieving biomechanical stability and deformity correction of spine, pedicle screws are widely used in the treatment of various spinal disorders such as spinal trauma, degeneration, and deformity.² For neurological intact thoracolumbar fracture, percutaneous minimally invasive pedicle screw fixation might be a good choice.^{3,4} However, malposition of pedicle screws also raises much concern, as it can cause complications related to neural, vascular, or visceral injury. Moreover, study shows that after the fixation of pedicle screws, impingement of the facet joint aggravates adjacent segments and cause degeneration.^{5–7} This revealed that minimizing violation of the cranial facet joint should be highly considered.

With the development of navigation technology, a computer-assisted system called O-arm navigation was created to guide surgeons to insert pedicle screws percutaneously in real time. It could provide real-time 3 planes virtual images for surgeons to manipulate the instrumentation around bony

Received for publication February 4, 2019; accepted November 18, 2019. From the Department of Orthopaedic Surgery, The First Affiliated Hospital of Soochow University, Suzhou, Jiangsu, China. J.L. and W.C. contributed equally.

Informed consent was obtained from all individual participants included in the study.

T.L. and H.Y.: conceived, designed, and supervised the research. J.L., W.C., and H.L.: performed the study. J.L. and W.C.: performed data analyses. J.L. and W.C.: wrote the manuscript. T.L.: revised the manuscript. All authors have read and approved the final manuscript. The authors declare no conflict of interest.

Reprints: Tao Liu, MD, PhD, Department of Orthopaedic Surgery, The First Affiliated Hospital of Soochow University, 188 Shizi Street, Suzhou, Jiangsu 215006, China (e-mail: liutaospine@163.com).

Copyright © 2020 The Author(s). Published by Wolters Kluwer Health, Inc. This is an open-access article distributed under the terms of the Creative Commons Attribution-Non Commercial-No Derivatives License 4.0 (CCBY-NC-ND), where it is permissible to download and share the work provided it is properly cited. The work cannot be changed in any way or used commercially without permission from the journal.

structures.⁸ The O-arm navigation was reported to improve the accuracy of pedicle screw placement,⁹ but Toshiaki and colleagues found it only saved operation time.¹⁰ There is still limited clinical data on O-arm navigation system treatment, therefore more studies are needed to evaluate its effect.

In this study, patients with single-level neurological intact thoracolumbar fracture were treated with percutaneous pedicle screw placement using intraoperative O-arm navigation and free-hand fluoroscopy-guided technique. The accuracy of pedicle screw placement and the rate of facet joint violation were analyzed to evaluate the effect of O-arm navigation. To our knowledge, such studies have been rarely reported, especially on its accuracy at fracture level and facet joint violation in percutaneous surgeries.

MATERIALS AND METHODS

Study Design

The retrospective study started after the approval of the Ethics Committee of the First Affiliated Hospital of Soochow University. From November 2015 to October 2017, we enrolled 97 consecutive patients of single-level neurological intact thoracolumbar fractures who were treated with pedicle screw implantation. All the patients were informed of the advantages and risk of the surgery. Their agreement was obtained before being included in the study. The strict exclusion criteria were: neurogenic deficit, osteoporosis, ankylosing spondylitis, spinal malformation, and tumor. The patients were assigned into 2 groups. One group underwent O-arm navigation-based pedicle screw insertion (O-arm group). Another group applied free-hand pedicle screw insertion by fluoroscopy-guided technique (fluoroscopy group). All the patients underwent closed reduction, percutaneous pedicle screw, and rod system internal fixation. If the unilateral pedicle of the injured vertebral was broken, we chose the unilateral pedicle screw fixation in the normal pedicle.

Surgical Produces

In O-arm group, we utilized a minimally invasive pedicle screw insertion technique by O-arm and stealth navigation (Metromic Navigation, Louisville, CO). After midline minimal exposure, a reference frame was rigidly attached to the spinous process above surgical level. On the basis of the device placed on the spinous process, intraoperative CT (O-arm) was used to scan the surgical field. Then the 3D images data were automatically transferred to the Stealth Station Navigation system and were visualized on a monitor. According to the marked line located before, a minimal incision was performed. Appropriate depth and trajectory of pedicle screw could be confirmed by using a navigated probe according to real-time 3 planes images on the monitor. A rigid navigated electric drill followed by the probe was used to create a limited pilot canal. At last, the pedicle screws were inserted properly.

In the fluoroscopy group, conventional fluoroscopic pedicle screw placement was performed. By reviewing fluoroscopic images, pedicle entry point was determined.

Then the skin incision was performed and a T-shape awl was used to create a canal based on a fluoroscopic image. With the assistance of T-wires, the pedicle screw was inserted by free-hand technique. During implantation, only lateral fluoroscopy was used to verify entry point, depth, and trajectory.

All the surgeries were performed by 2 fellowship trained spine surgeons, both of whom were experienced in percutaneous pedicle screw placement using intraoperative O-arm navigation or free-hand fluoroscopy-guided technique.

Radiologic Evaluation

After all screws were in place, we made a second intraoperative 3D scan with the O-arm in the O-arm group or postoperative CT scan in the fluoroscopy group. After reviewing the axial CT images, the positions of the pedicle screws and violation of cranial facet joints were evaluated. Two observers independently assessed the images and discussed any controversies in order to reach a consensus. If an agreement was not made, an authoritative surgeon would be invited to provide the final decision.

Pedicle Perforation

It was considered an anatomic perforation if the pedicle was broken by the screw. The following classification of the pedicle screw misplacements (breaches) was applied¹¹:

Grade 0, pedicle screw completely contained within the pedicle (no breach, Fig. 1A);

Grade 1, any part of the screw extended beyond the cortex of the pedicle but not more than 2 mm (mild breach, Fig. 1B);

Grade 2, pedicle screw extended between 2 and 4 mm (medium breach, Fig. 1C); and

Grade 3, screw extension exceeded 4 mm (severe breach).

The perforation direction was also defined and classified as medial, lateral, superior, inferior, or anterior. On account of being close to the dural sac and nerve root, medial or inferior border of the breached pedicles were likely to cause neurological injury. We defined the perforation as functional perforation.¹²

Facet Impingement

Facet joint violation was evaluated according to the classification described by Seo and colleagues^{6,13}:

Grade 0, no impingement;

Grade 1, pedicle screw in contact/suspected to be in contact with facet joint (Fig. 1D); and

Grade 2, pedicle screw clearly invaded the facet joint.

Statistical Data Analysis

The association between categorical variables were investigated by the χ^2 test, and the Fisher exact test was used when expected frequencies were <5. The *t* test was used for continuous variables. All tests were 2-tailed and a *P*-value of <0.05 was considered statistically significant. All statistical analysis was performed using STATA 13.

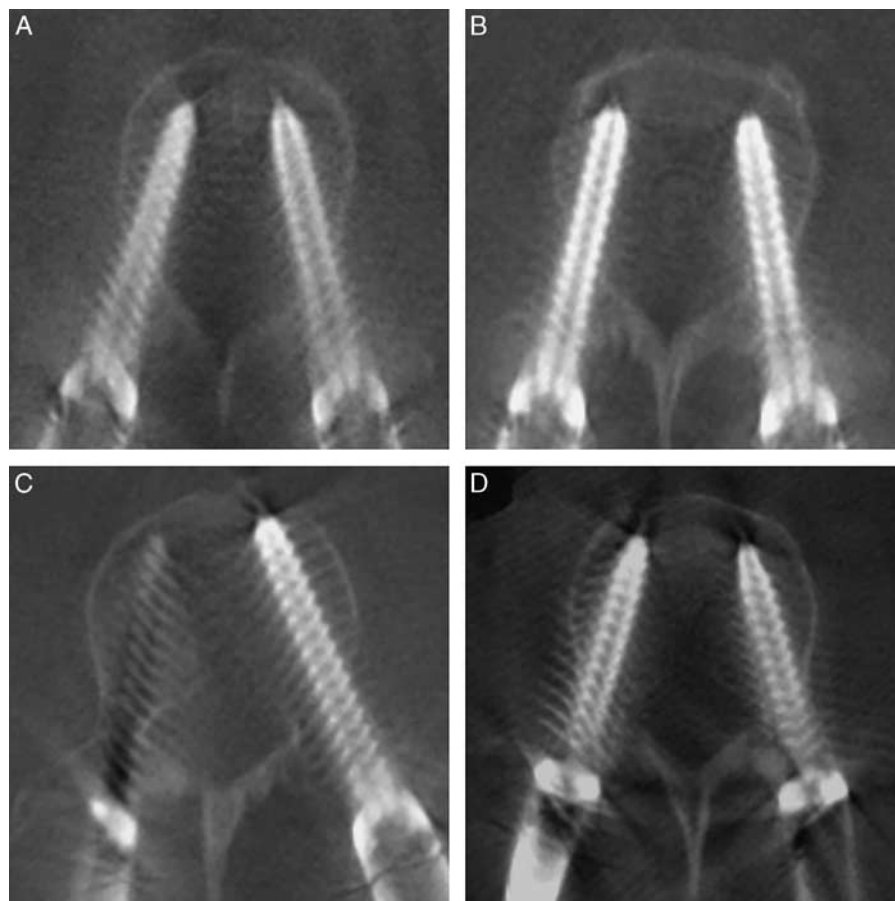


FIGURE 1. Different grades of perforations appeared in the study. A, Grade 0 of anatomic perforation: pedicle screw completely contained within the pedicle. B, Grade 1 of anatomic perforation: right part of a screw extended beyond the cortex of the pedicle but not more than 2 mm. C, Grade 2 of anatomic perforation: left part of a pedicle screw extended between 2 and 4 mm. D, Grade 1 of facet impingement: right part of the left pedicle screw was suspected to be in contact with facet joint.

RESULTS

Patients Included and Screws Implanted

Ninety-seven patients (53 males and 44 females) were finally included in this study. The mean age of the patients was 51.9 years (ranged from 22 to 81 y old). A total of 573 pedicle screws were implanted. Two hundred sixty-six screws were inserted into 45 patients of the O-arm group (24 males and 21 females) and 307 screws were inserted in 52 patients of the fluoroscopy group (29 males and 23 females). Unilateral pedicle screw fixation was performed on 9 patients; 4 patients were in the O-arm group and the other 5 patients were in the fluoroscopy group. The rest underwent bilateral pedicle screw fixation on the superior-inferior segment. Detailed information on the patients and the screws is shown in Table 1. No patient suffered from neurological injury due to screw misplacement and no patient had to undergo revision as a secondary surgery.

Pedicle Perforation

A total of 244 screws (91.7%) in the O-arm group and 261 screws (85.0%) in the fluoroscopy group were entirely within the confines of the pedicles. In the O-arm

group, there were 19 grade 1 screws (7.1%) and 3 grade 2 screws (1.1%). One perforation was in the medial of the pedicles and 2 perforations were in the inferior. In the fluoroscopy group, there were 33 grade 1 screws (10.7%) and 13 grade 2 screws (4.2%). Five medial perforations and 8 inferior perforations indicated a functional perforation rate of 4.2%. The overall anatomic perforation rate and functional perforation rate were both lower in the O-arm group when compared with the fluoroscopy group (8.3% vs. 15.0%, $P=0.013$; 1.1% vs. 4.2%, $P=0.024$). Besides, there were more overall grade 2 perforations and more grade 1 perforations at the thoracic level in the fluoroscopy group than in the O-arm group ($P=0.024$; 0.030) (Table 2).

At fracture level, 9 screws (10.5%) of the O-arm group and 18 screws (18.2%) of the fluoroscopy group were found to be misplaced. There was no statistical difference between anatomic perforation rates ($P=0.138$). However, we found that the O-arm group had less grade 2 perforations than the fluoroscopy group ($P=0.033$). When it comes to functional perforation, no statistical difference was found (2.3% vs. 8.1%, $P=0.109$) (Table 3).

TABLE 1. Basic Information of Patients and Screws

Characteristics	n (%)			P
	O-Arm	Fluoroscopy	Total	
Patients	45 (100)	52 (100)	97 (100)	—
Sex				0.810
Male	24 (53.3)	29 (55.8)	53 (54.6)	—
Female	21 (46.7)	23 (44.2)	44 (45.4)	—
Age				—
Mean (SD)	50.2 (13.9)	53.4 (15.1)	51.9 (14.6)	0.293
Range	22–74	26–81	22–81	—
Fracture level				—
T11	6 (13.3)	5 (9.6)	11 (11.3)	0.565
T12	13 (28.9)	14 (26.9)	27 (27.8)	0.829
L1	17 (37.8)	21 (40.4)	38 (39.2)	0.793
L2	7 (15.6)	9 (17.3)	16 (16.5)	0.817
L3	2 (4.4)	3 (5.8)	5 (5.2)	1.000
Screws in total	266	307	573	—
T10	12 (4.5)	10 (3.3)	22 (3.8)	0.436
T11	37 (13.9)	38 (12.4)	75 (13.1)	0.588
T12	70 (26.3)	79 (25.7)	149 (26.0)	0.874
L1	74 (27.8)	85 (27.7)	159 (27.7)	0.972
L2	51 (19.2)	65 (21.2)	116 (20.2)	0.552
L3	18 (6.8)	24 (7.8)	42 (7.3)	0.630
L4	4 (1.5)	6 (2.0)	10 (1.7)	0.758
Screws at fracture level	86	99	185	—
T11	11 (12.8)	10 (10.1)	21 (11.4)	0.565
T12	24 (27.9)	27 (27.3)	51 (27.6)	0.923
L1	34 (39.5)	39 (39.4)	73 (39.5)	0.984
L2	13 (15.1)	17 (17.2)	30 (16.2)	0.705
L3	4 (4.7)	6 (6.1)	10 (5.4)	0.753

L indicates lumbar; T, thoracic.

Facet Impingement

The rates of facet impingement are shown in Figure 2. More screws violated the facet in the fluoroscopy group than in the O-arm group (8.1% vs. 2.3%, $P = 0.002$). There were 6 grade 1 screws in the O-arm group and 18 grade 1 screws in the fluoroscopy group ($P = 0.032$). Grade 2 screws only appeared in the fluoroscopy group (0% vs. 2.3%, $P = 0.017$). What is more, there was also a lower rate of facet joint violation at fracture level in the O-arm group than in the fluoroscopy group (2.3% vs. 11.1%, $P = 0.02$) (Fig. 2).

DISCUSSION

Improving the accuracy and safety of pedicle screw insertion remains an arduous task in spinal surgery. Conventional free-hand fluoroscopy-guided pedicle screw implantation was reported to result in a misplacement rate of 5% to 15%.¹⁴ As a new technique, O-arm navigation system is gaining popularity. Van de Kelft et al¹⁵ declared that the use of the O-arm combined with a navigation system increased the accuracy of pedicle screw placement. They correctly placed 97.5% screws with O-arm navigation. Myuang and colleagues revealed that pedicle screw placement guided by the O-arm and navigation system was more accurate and safer than that under fluoroscopy guidance in thoracic and lumbosacral spines.¹⁶ However, a recent study made a different conclusion that the advent of new technologies, such as O-arm, did not alter accuracy

TABLE 2. Characteristic of All the Screws Placed in the Surgery

Classification	n (%)		P
	O-Arm	Fluoroscopy	
Screws placed	266 (100)	307 (100)	—
T	119 (100)	127 (100)	0.417
L	147 (100)	180 (100)	0.417
Classification			
Grade 0	244 (91.7)	261 (85.0)	0.013*
T	112 (94.1)	104 (81.9)	0.004*
L	132 (89.8)	157 (87.2)	0.470
Grade 1	19 (7.1)	33 (10.7)	0.134
T	5 (4.2)	15 (11.8)	0.030*
L	14 (9.5)	18 (10.0)	0.885
Grade 2	3 (1.1)	13 (4.2)	0.024*
T	2 (1.7)	8 (6.3)	0.104
L	1 (0.7)	5 (2.8)	0.229
Grade 3	0 (0)	0 (0)	—
Anatomic perforation	22 (8.3)	46 (15.0)	0.013*
T	7 (5.9)	23 (18.1)	0.003*
L	15 (10.2)	23 (12.8)	0.470
Perforation direction			
Medial	1 (0.4)	5 (1.6)	0.224
T	1 (0.8)	3 (2.4)	0.623
L	0 (0)	2 (1.1)	0.504
Lateral	12 (4.5)	21 (6.8)	0.233
T	3 (2.5)	9 (7.1)	0.097
L	9 (6.1)	12 (6.7)	0.842
Superior	7 (2.6)	12 (3.9)	0.394
T	3 (2.5)	8 (6.3)	0.152
L	4 (2.7)	5 (2.8)	1.000
Inferior	2 (0.8)	8 (2.6)	0.296
T	0 (0)	3 (2.4)	0.248
L	2 (1.4)	4 (2.2)	0.694
Anterior	0 (0)	0 (0)	—
Functional perforations	3 (1.1)	13 (4.2)	0.024*
T	1 (0.8)	6 (4.7)	0.121
L	2 (1.4)	7 (3.9)	0.194

* χ^2 test, $P < 0.05$.

L indicates lumbar; T, thoracic.

of screw placement.¹⁷ The variance on the effect of O-arm navigation needs more evidence to draw a conclusion.

Our study indicated that anatomic perforation rate and functional perforation rate in the O-arm group were both lower than those in the fluoroscopy group (8.3% vs. 15.0%, $P = 0.013$; 1.1% vs. 4.2%, $P = 0.024$). Houten et al¹⁸ reported that percutaneous pedicle screw placement with the O-arm multidimensional intraoperative imaging system could provide improvement in overall accuracy when compared with conventional fluoroscopic techniques. Our study obtained a similar result that O-arm navigation received a lower perforation rate between the 2 groups. It seemed safe for only 3 of the cortical perforations which exceeded 2 mm in the O-arm group while 13 perforations extended between 2 and 4 mm in the fluoroscopy group. Moreover, we detected that O-arm navigation helped more at the thoracic level. Owing to the real-time navigation, placing screws in the narrow thoracic pedicles became easier.

Most studies about pedicle screw placement involved various surgical indications such as degenerative lumbar spondylolysis, spinal stenosis, progressive scoliosis, and

TABLE 3. Characteristic of Screws Placed in Fracture Levels

Classification	n (%)		P
	O-Arm	Fluoroscopy	
Screws placed	86 (100)	99 (100)	—
T	35 (100)	37 (100)	0.644
L	51 (100)	62 (100)	0.644
Classification			
Grade 0	77 (89.5)	81 (81.8)	0.138
T	32 (91.4)	29 (78.4)	0.124
L	45 (88.2)	52 (83.9)	0.508
Grade 1	9 (10.5)	12 (12.1)	0.723
T	3 (8.6)	4 (10.8)	1.000
L	6 (11.8)	8 (12.9)	0.855
Grade 2	0 (0)	6 (6.1)	0.033#
T	—	4 (10.8)	0.115
L	—	2 (3.2)	0.500
Grade 3	0 (0)	0 (0)	—
Anatomic perforation	9 (10.5)	18 (18.2)	0.138
T	3 (8.6)	8 (21.6)	0.191
L	6 (11.8)	10 (16.1)	0.508
Perforation direction			
Medial	1 (1.2)	3 (3.0)	0.625
T	1 (2.9)	1 (2.7)	1.000
L	0 (0)	2 (3.2)	0.500
Lateral	5 (5.8)	6 (6.1)	0.944
T	1 (2.9)	4 (10.8)	0.358
L	4 (7.8)	2 (3.2)	0.407
Superior	2 (2.3)	4 (4.0)	0.687
T	1 (2.9)	2 (5.4)	1.000
L	1 (2.0)	2 (3.2)	1.000
Inferior	1 (1.2)	5 (5.1)	0.218
T	0 (0)	1 (2.7)	1.000
L	1 (2.0)	4 (6.5)	0.376
Anterior	0 (0)	0 (0)	—
Functional perforations	2 (2.3)	8 (8.1)	0.109
T	1 (1.2)	2 (5.4)	1.000
L	1 (2.0)	6 (9.7)	0.126

* χ^2 test, $P < 0.05$.

#Fisher exact test, $P < 0.05$.

L indicates lumbar; T, thoracic.

tumor.^{9,10,18–20} In this study, we limited the indications to thoracolumbar fracture in order to figure out a reliable outcome on the accuracy at fracture level. In fractured vertebra, 10.5% of 86 pedicle screws broke the cortex in the O-arm group and 18.2% of 99 pedicle screws broke the cortex in the fluoroscopy group ($P = 0.138$). No statistical differences were found in anatomic perforation and functional perforation. To insert pedicle screws in the fractured vertebrae is harder than in adjacent vertebrae. The instability and rotation of fractured vertebral bodies could make the process difficult to control. Fractured vertebrae could move slightly during insertion to disturb the operator. Using O-arm navigation did not provide superior benefits at the fracture level. Whereas, we noticed that no grade 2 screws appeared in the O-arm group at the fracture level. Manipulating the instrumentation with the help of real-time 3 planes virtual images may still be useful for avoiding serious perforations.

Many studies have pointed out that facet joint violation may be a significant factor in the development of adjacent segment degeneration, after spinal correction with pedicle screws.^{6,21} Our study showed that percutaneous

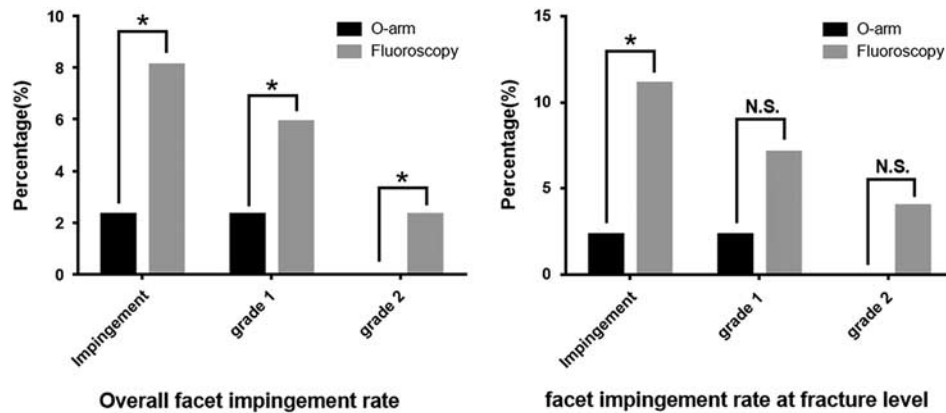
pedicle screw placement assisted by O-arm navigation had a significantly lower facet joint violation rate than that of the fluoroscopy group (2.3% vs. 8.1%, $P = 0.002$). Furthermore, 7 screws clearly invaded the facet joint and they were all in the fluoroscopy group ($P = 0.017$). O-arm navigation truly reduced the risk of facet joint violation compared with fluoroscopy-guided technique in percutaneous surgery. To the best of our knowledge, although many studies on the facet joint violation rate caused by pedicle screws showed various results with open and percutaneous technique,^{6,7} the beneficial outcome on facet joint violation of O-arm navigation in percutaneous surgery has not been reported before.

Why could O-arm navigation system achieve such satisfactory results? Several possibilities could be offered. First, O-arm navigation system provides anatomic digital information for the operator to choose a suitable screw and mimic an insertion procedure in 3-dimensional virtual imaging, thus optimizing trajectory and reducing the potential for nerve injury. Second, it could guide surgeons to manipulate the instrumentation in real time, which makes the surgery easier and safer. Thirdly, fluoroscopy is significantly limited by a small field of view, but O-arm navigation is typically able to capture 4 or 5 spinal levels.¹⁸ Finally, when the operator is aware that the screw is incorrectly placed, O-arm navigation would verify the assessment and help make the revision easier.

As Weinstein et al²² described, the position of the screw entry point may be an important factor to avoid facet joint impingement. Through real-time 3-dimensional virtual imaging provided by O-arm navigation, an operator could confirm more lateral screw entry points, making screws further away from the adjacent facet joint. The risk of facet joint impingement was reduced consequently. Besides, the orientation of the joint anatomic construction is a basic factor leading to facet joint violation. From inferior to superior lumbar, the facet joints rotate progressively into a more coronal orientation with the inferior levels angulated more coronal than the superior levels. In our study, most of the fracture levels were located in T11–L2. As a result, there were not many serious joint disturbances, which may be an objective reason for a low rate of facet joint violation.

O-arm navigation also has specific factors that would lead to the misplacement of pedicle screws: initial register error of spatial coordinates for navigation devices; inadvertent looseness and dislodgement of the location clamp on spinous process, and the microdeformation of the tracer. Such factors require that surgeons carefully confirm their procedure before the surgery and perform warily during operation. The development of the O-arm navigation system would reduce such risks as well.

There are several limitations in the present study. First, since the study was hard to control in a randomized manner, it was carried out retrospectively, which would lower the reliability of the conclusion. Second, 97 patients and 573 screws were included in our study. A larger sample size would make the consequence more persuasive. Third, O-arm navigation is a new technique to help spine



Classification [no. (%)]	O-arm	Fluoroscopy	P-value	O-arm	Fluoroscopy	P-value
Grade 0	260 (97.7)	282 (91.9)	0.002*	84 (97.7)	88 (88.9)	0.020*
T	117 (98.3)	116 (91.3)	0.014*	35 (100)	32 (86.5)	0.054
L	143 (97.3)	166 (92.2)	0.046*	49 (96.1)	56 (90.3)	0.291
Grade 1	6 (2.3)	18 (5.9)	0.032*	2 (2.3)	7 (7.1)	0.179
T	2 (1.7)	7 (5.5)	0.174	0 (0)	2 (5.4)	0.493
L	4 (2.7)	11 (6.1)	0.145	2 (3.9)	5 (8.1)	0.454
Grade 2	0 (0)	7 (2.3)	0.017#	0 (0)	4 (4.0)	0.125
T	-	4 (3.1)	0.123	-	3 (8.1)	0.240
L	-	3 (1.7)	0.279	-	1 (1.6)	1.000
Facet impingement	6 (2.3)	25 (8.1)	0.002*	2 (2.3)	11 (11.1)	0.020*

FIGURE 2. Histograms comparing the facet impingement between O-arm group and fluoroscopy group with classification of all screws. * χ^2 test, $P < 0.05$. #Fisher exact test, $P < 0.05$. L indicates lumbar; NS, no significance; T, thoracic.

surgery. Although our surgeons have performed many surgeries with O-arm navigation before this study, there may still be a learning curve that could have influenced our results.

CONCLUSIONS

In percutaneous pedicle screw placement for neurological intact thoracolumbar fracture, the introduction of O-arm navigation improved accuracy, reduced functional perforations, and minimized serious perforations compared with conventional fluoroscopic technique. It also decreased facet joint violation observably and helped to prevent development of adjacent segment degeneration.

REFERENCES

- Sun C, Guan G, Liu X, et al. Comparison of short-segment pedicle fixation with versus without inclusion of the fracture level in the treatment of mild thoracolumbar burst fractures. *Int J Surg*. 2016;36 (pt A):352–357.
- Gaines RW. The use of pedicle-screw internal fixation for the operative treatment of spinal disorders. *J Bone Joint Surg Am*. 2000;82a:1458–1476.
- Cimatti M, Forcato S, Polli F, et al. Pure percutaneous pedicle screw fixation without arthrodesis of 32 thoraco-lumbar fractures: clinical and radiological outcome with 36-month follow-up. *Eur Spine J*. 2013;22(suppl 6):S925–S932.
- Wang H, Zhou Y, Li C, et al. Comparison of open versus percutaneous pedicle screw fixation using the sextant system in the

- treatment of traumatic thoracolumbar fractures. *Clin Spine Surg*. 2017;30:E239–E246.
- Akhaddar A, Atmane el M. Pedicle screw malposition following spinal lumbar injury. *Pan Afr Med J*. 2014;17:266.
- Yson SC, Sembrano JN, Sanders PC, et al. Comparison of cranial facet joint violation rates between open and percutaneous pedicle screw placement using intraoperative 3-D CT (O-arm) computer navigation. *Spine*. 2013;38:E251–E258.
- Ohba T, Ebata S, Fujita K, et al. Percutaneous pedicle screw placements: accuracy and rates of cranial facet joint violation using conventional fluoroscopy compared with intraoperative three-dimensional computed tomography computer navigation. *Eur Spine J*. 2016;25: 1775–1780.
- Kleck CJ, Johnson C, Akiyama M, et al. One-step minimally invasive pedicle screw instrumentation using O-arm and stealth navigation. *Clin Spine Surg*. 2018;31:197–202.
- Wood M, Mannion R. A comparison of CT-based navigation techniques for minimally invasive lumbar pedicle screw placement. *J Spinal Disord Tech*. 2011;24:E1–E5.
- Kotani T, Akazawa T, Sakuma T, et al. Accuracy of pedicle screw placement in scoliosis surgery: a comparison between conventional computed tomography-based and O-arm-based navigation techniques. *Asian Spine J*. 2014;8:331–338.
- Xu R, Ebraheim NA, Ou Y, et al. Anatomic considerations of pedicle screw placement in the thoracic spine. Roy-Camille technique versus open-lamina technique. *Spine (Phila Pa 1976)*. 1998;23: 1065–1068.
- Boon Tow BP, Yue WM, Srivastava A, et al. Does navigation improve accuracy of placement of pedicle screws in single-level lumbar degenerative spondylolisthesis? A comparison between free-hand and three-dimensional O-arm navigation techniques. *J Spinal Disord Tech*. 2015;28:E472–E477.

13. Seo HY, Chung JY, Kang KD. Transpedicular screw violation of facet joint could lead to adjacent segment degeneration. Paper presented at The American Academy of Orthopaedic Surgeons. 2011.
14. Castro WH, Halm H, Jerosch J, et al. Accuracy of pedicle screw placement in lumbar vertebrae. *Spine (Phila Pa 1976)*. 1996;21:1320–1324.
15. Van de Kelft E, Costa F, Van der Planken D, et al. A prospective multicenter registry on the accuracy of pedicle screw placement in the thoracic, lumbar, and sacral levels with the use of the O-arm imaging system and StealthStation Navigation. *Spine (Phila Pa 1976)*. 2012;37:E1580–E1587.
16. Shin MH, Hur JW, Ryu KS, et al. Prospective comparison study between the fluoroscopy-guided and navigation coupled with O-arm-guided pedicle screw placement in the thoracic and lumbosacral spines. *J Spinal Disord Tech*. 2015;28:E347–E351.
17. Laudato PA, Pierzchala K, Schizas C. Pedicle screw insertion accuracy using O-arm, robotic guidance, or freehand technique: a comparative study. *Spine (Phila Pa 1976)*. 2018;43:E373–E378.
18. Houten JK, Nasser R, Baxi N. Clinical assessment of percutaneous lumbar pedicle screw placement using the O-arm multidimensional surgical imaging system. *Neurosurgery*. 2012;70:990–995.
19. Liu H, Chen W, Liu T, et al. Accuracy of pedicle screw placement based on preoperative computed tomography versus intraoperative data set acquisition for spinal navigation system. *J Orthop Surg*. 2017;25:2309499017718901.
20. Fu TS, Wong CB, Tsai TT, et al. Pedicle screw insertion: computed tomography versus fluoroscopic image guidance. *Int Orthop*. 2008;32:517–521.
21. Patel RD, Graziano GP, Vanderhave KL, et al. Facet violation with the placement of percutaneous pedicle screws. *Spine (Phila Pa 1976)*. 2011;36:E1749–E1752.
22. Weinstein JN, Spratt KF, Spengler D, et al. Spinal pedicle fixation: reliability and validity of roentgenogram-based assessment and surgical factors on successful screw placement. *Spine (Phila Pa 1976)*. 1988;13:1012–1018.