

A case of Takotsubo cardiomyopathy showing two modes of initiation for ventricular fibrillation: Augmented J-wave and torsade de pointes with QT prolongation



Masato Shimizu, MD, PhD,^{*} Mitsuhiro Nishizaki, MD, PhD,^{*} Noriyoshi Yamawake, MD, PhD,^{*} Hiroyuki Fujii, MD,^{*} Harumizu Sakudara, MD, PhD,[†] Masayasu Hiraoka, MD, PhD, FHRS[‡]

From the ^{*}Department of Cardiology, Yokohama Minami Kyosai Hospital, Yokohama, Japan, [†]Tokyo Metropolitan Health and Medical Treatment Corporation Ohkubo Hospital, Tokyo, Japan, and [‡]Tokyo Medical and Dental, University, Tokyo, Japan.

Introduction

The prognosis of Takotsubo cardiomyopathy (TTC) has generally been considered favorable, but fatal cardiac events, including ventricular tachycardia (VT) or ventricular fibrillation (VF), are occasionally observed.^{1,2} Development of VT/VF in patients with TTC appeared as an association with QT prolongation.² In long QT syndrome, a short-long-short sequence often precedes the onset of torsade de pointes (TdP). In cases with TTC, however, few reports have demonstrated a short-long-short sequence preceding TdP.³ In our previous report, J-wave appearing in the hyperacute phase of TTC was indicated as a risk factor for cardiac death owing to VT/VF.⁴ A J-wave was associated with increased cardiac mortality in various diseases, including idiopathic ventricular fibrillation,⁵ acute myocardial infarction,⁶ vasospastic angina,⁷ and Brugada syndrome.⁸ It has not yet been demonstrated that augmented J-wave leads to actual development of VT/VF in TTC. We present a case of TTC in whom VF was initiated with augmented J-wave in lateral leads and, in different occasions, VF was preceded by a short-long-short sequence with prolonged QT interval.

Case report

A 66-year-old woman was found in cardiopulmonary arrest at her home. Her son recognized her event by the sound of her falling down. He immediately called an ambulance and started chest compression. She was transferred to the hospital by the ambulance after ~10 minutes. In the ambulance, VF was detected, but the repeat applications of current shocks by an automated external defibrillator were unsuccessful in resuming sinus rhythm. Upon arrival at our hospital ~30

minutes after her cardiac arrest, her electrocardiogram (ECG) still showed VF. She underwent a support with a venoarterial extracorporeal membrane oxygenation system. Shortly after the start of the support, VF was terminated by electrical counter-shock, and emergency cardiac catheterization was performed. Coronary angiography showed no significant occlusion in the major branches, and the left ventriculography revealed akinesis of the apical segment and hyperkinesis of the basal wall (Figure 1). She was diagnosed as TTC. She had had no emotional stress during the preceding days of illness or past history, except for her complaint to her son about feeling sick a few days before cardiac arrest. She had no family history of sudden cardiac death or long QT syndrome. Her ECG taken 2 years before the admission showed no J-wave in the lateral leads (Figure 2A).

On admission to the coronary care unit, serum electrolytes were within normal limits. A 12-lead ECG displayed a notched type J-wave in lead V4–V6 and QT prolongation at 16 hours after admission, while no J-wave was seen on admission (Figure 2B and C, left). Twenty-four hours after her admission, the amplitudes of J-waves gradually augmented, and then polymorphic VT suddenly started degenerating into VF (Figure 3A). VF was terminated by electrical defibrillation. No remarkable changes in blood examination including serum electrolytes or acid-base balance were observed immediately after the termination of VF. At 8 hours after occurrence of the first VF in the hospital (32 hours after admission), QT interval was further prolonged with sinus bradycardia and a short-long-short sequence with premature atrial contraction inducing much-prolonged QT interval (Figure 3B). TdP suddenly occurred without augmentation of J-waves, which degenerated into VF. VF was terminated by electrical defibrillation. The events of TdP degenerating into VF recurred 7 times in the following 8 hours, and each VF was terminated by electrical defibrillation. Drugs, including beta blocker, magnesium sulfate, and lidocaine, were without effect. The 12-lead ECG monitor showed gradual attenuation of prolonged QT interval,

KEYWORDS Takotsubo cardiomyopathy; Ventricular tachycardia; Ventricular fibrillation; QT prolongation; J-wave
(Heart Rhythm Case Reports 2016;2:436–440)

Address reprint requests and correspondence: Dr Masato Shimizu, Yokohama Minami Kyosai Hospital, 1-21-1 Mitsuura-higashi, Kanazawaku, Yokohama 236-0037, Japan. E-mail address: mst-smz@my.email.ne.jp.

KEY TEACHING POINTS

- Takotsubo cardiomyopathy (TTC) is generally considered as a favorable prognosis, but sometimes fatal cardiac events, including ventricular tachycardia (VT) or ventricular fibrillation (VF), are observed.
- A 66-year-old woman presented cardiac arrest as the first manifestation of TTC. She developed 2 initiation modes of VF during the acute phase of TTC, 1 from augmented J-wave during the hyperacute phase and the other from a short-long-short sequence with prolonged QT interval leading to torsade de pointes (TdP)/ventricular fibrillation (VF) during the later phase.
- The first clinical manifestation of cardiac arrest, augmented J-wave followed by VF and QT prolongation leading to TdP/VF, indicates high risk and worse prognosis of TTC, which may reflect severe myocardial damage and/or progressive development of congestive heart failure.

without development of VF until 48 hours after admission. The ECG at 72 hours after admission did not exhibit any J-wave in lead V4–V6 and showed almost normal QT interval (Figure 2C, right).

As her clinical course became improved with hemodynamic stability, a venoarterial extracorporeal membrane oxygenation system was removed at the third day after admission. Although her echocardiography, recorded on the fourth day, revealed a recovery of contractility in the left ventricular apical wall, she did not regain consciousness. Brain computed tomography revealed massive edema and the electroencephalogram showed almost flat waves. She died 28 days after her admission.

Discussion

The present case showed 2 modes of VF initiation during the acute phase of TTC; the first VF in the hospital developed with augmented J-wave in the lateral leads and later VF repeatedly initiated from a short-long-short sequence, leading to TdP/VF with QT prolongation without the augmentation of J-wave. The initiation of VT/VF with augmented J-waves has not been documented in patients with TTC, whereas the initiation from prolonged QT interval and TdP is not rare.^{2,3}

The VF initiation in this case developed in 2 different time spans in the hospital admission during the acute phase of TTC. The augmented J-wave followed by VF appeared 24 hours after her admission to the coronary care unit, and at 30–40 hours a short-long-short sequence under QT prolongation was followed by the development of TdP, which degenerated into VF. These sequences of VF development appeared to involve different initiation mechanisms.

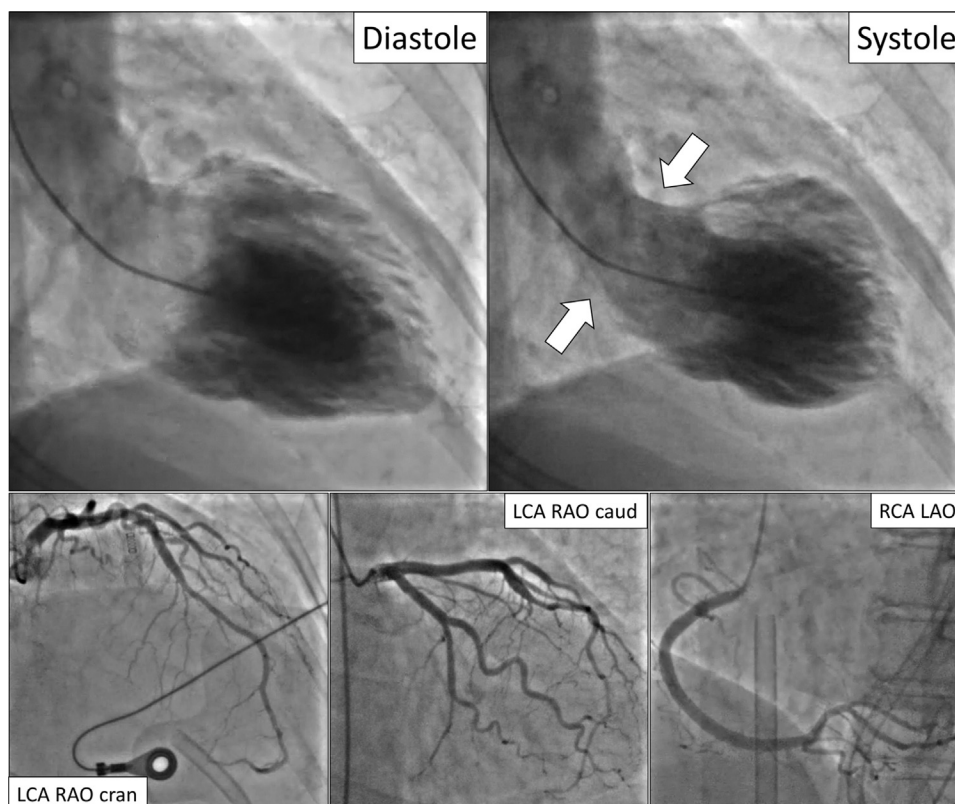


Figure 1 Left ventriculography (diastolic and systolic phases) exhibited akinesis of apical wall and hyperkinesis of basal wall. Angiography of the left coronary artery (LCA) and right coronary artery (RCA) showed no significant stenotic lesion. LAO = left anterior oblique; RAO caud = right anterior oblique and caudal angulation.

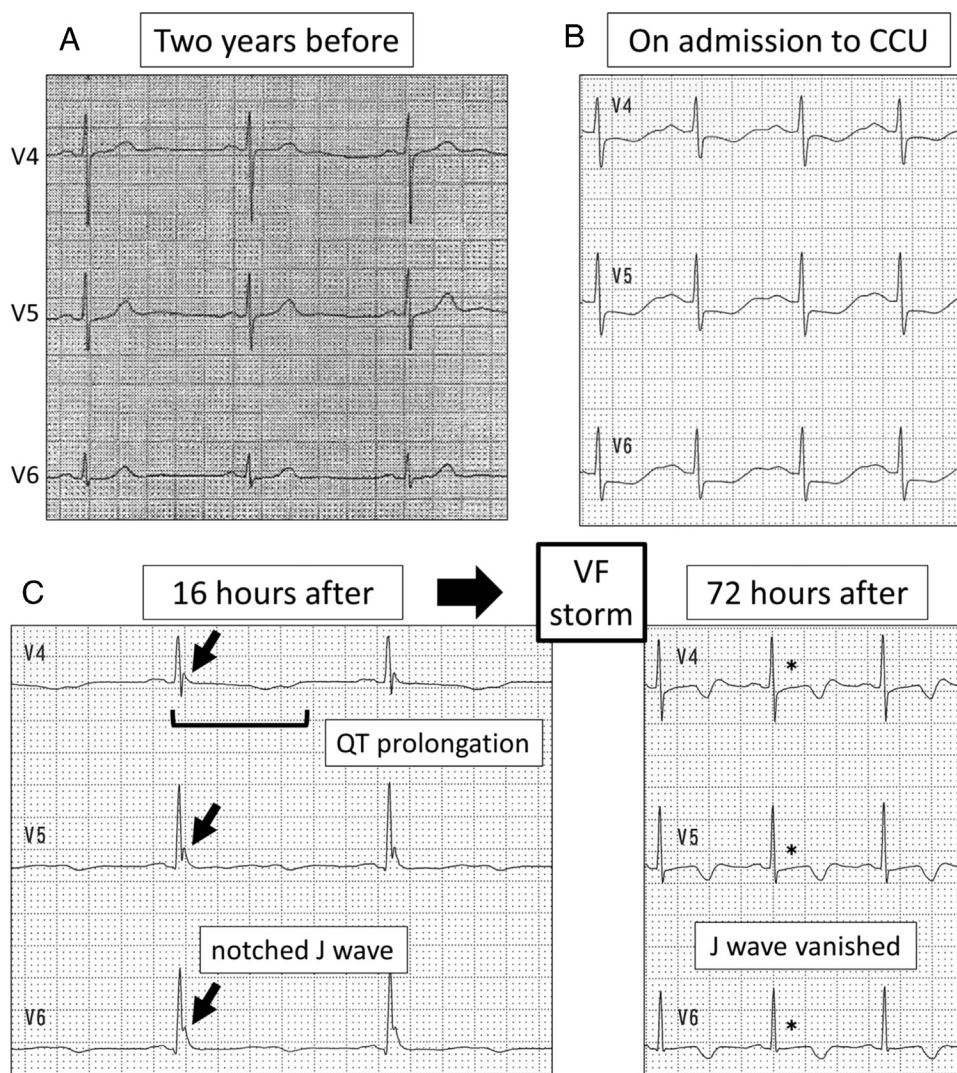


Figure 2 The time sequence of changes in electrocardiogram (ECG) records of leads V4–V6. (A) ECG recorded at 2 years before patient's admission. No J-wave is visible. (B) ECG recorded on admission to coronary care unit (CCU) without J-wave. (C) Left image shows ECG recorded after 16 hours of her admission. Arrows show prominent J waves. The QT interval is prolonged. Right image presents ECG records after 72 hours of admission. Asterisks indicate disappearance of J-waves. QT interval is nearly normalized. VF = ventricular fibrillation.

The mechanism of the VT/VF initiation caused by increased J-wave amplitude has been explained by the transmural voltage gradient during the early phase of action potential repolarization in cells at the inferolateral wall of the ventricle, which is similar to the genesis of ST-segment elevation in the right precordial leads by the heterogeneity of repolarization at the right ventricular outflow tract in Brugada syndrome.^{8,9} Action potentials of epicardial cells show a prominent notch during early repolarization because of well-developed transient outward potassium current (I_{to}), while endocardial action potentials lack this notch owing to less developed I_{to}. With increased I_{to} and other potassium current, or decreased sodium and calcium current, the notch of epicardial action potential becomes larger and leads to shortened action potentials in some regions, leading to increased dispersion of repolarization among contiguous cells. The condition provides an appearance of phase 2 reentry and development of polymorphic VT/VF. On the

other hand, a long-short-long sequence and subsequent development of TdP/VF have been observed in TTC with prolonged QT intervals,^{2,3} which are typically seen in congenital and acquired long QT syndrome.

The mechanism of myocardial damage in TTC was proposed as 2 theories, myocardial ischemia and catecholamine toxicity.¹⁰ Myocardial ischemia owing to multivessel spasm or microvascular impairment could cause stunning of the apical portion of the left ventricle. It was demonstrated that acute regional myocardial ischemia across the border zone resulted in markedly heterogeneous loss of I_{to}-mediated epicardial action potential dome, leading to phase 2 reentry capable of initiating VF.¹¹ If the region of stunned myocardium in TTC is caused by ischemia, the border zone facing the hypercontracting area exhibiting the I_{to}-mediated notch of epicardial action potentials followed by a prominent dome could produce marked heterogeneity of repolarization. The repolarization heterogeneity at the border zone may

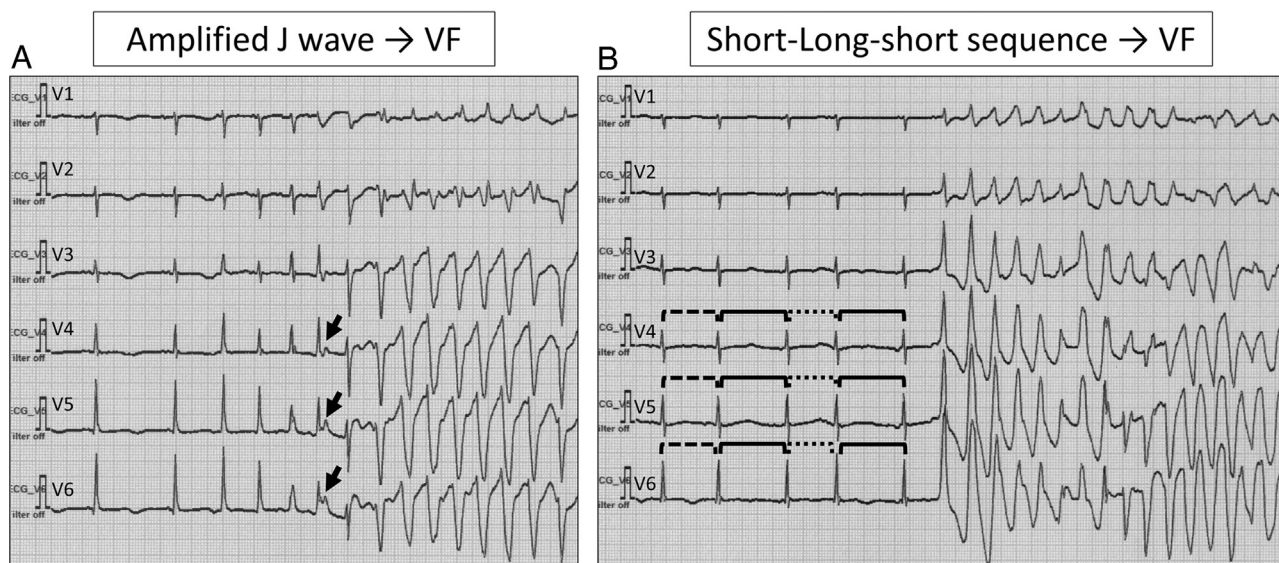


Figure 3 Two modes of ventricular fibrillation (VF) initiation. (A) Successive accentuation of J-wave amplitudes (arrows) followed by the initiation of VF. (B) Short-long-short sequence by premature atrial contraction causing prolonged QT interval and the initiation of torsade de pointes that degenerated into VF. Dashed line indicates a short beat-by-beat interval. Thick line indicates a long beat-by-beat interval.

become a source of augmented J-wave and arrhythmogeneity, leading to VF initiation. Myocardial ischemia in the apical region could also produce an outward shift in repolarizing currents owing to decreased Na^+ and/or Ca^{++} current, and by activation of the ATP-sensitive K^+ current, which might contribute to increased heterogeneity of repolarization. Catecholamine toxicity could induce Ca^{++} overload in myocardial cells, a condition that would be prone to develop delayed afterdepolarizations as the mechanism of arrhythmogeneity,¹² but their role in the J-wave formation was not clear.

The apical ballooning usually induces cardiac dysfunction and heart failure. Heart failure was shown to cause depression of various potassium currents, including I_{to} , inward rectifier potassium current, and slowly activating delayed outward potassium current (I_{ks}).^{13–15} Depression of these potassium currents could contribute to prolongation of the action potential duration and resultant QT prolongation in ECG, but J-wave might not be augmented because of decreased I_{to} with development of heart failure. On the other hand, depressed potassium currents can provide an association of QT prolongation and a short-long-short sequence leading to development of TdP.

The prognosis of TTC is generally considered favorable, but sometimes unfavorable cardiac events including VT/VF occur.^{1,2,10} The prognostic factors for TTC had not been clarified in detail, but the present case might give some clue to consider the risk of VT/VF and factors to determine the prognosis of TTC patients. The time course of changes in her VF attacks might be a reflection of a cardiac condition in TTC. The present case presented the first sign of illness as cardiac arrest owing to VF, which was quite unusual as the initial presentation of TTC. Patients with TTC generally manifest clinical signs of severe chest pain and ECG findings similar to acute ST-elevation myocardial infarction.¹⁰ Her

initial disease manifestation of cardiac arrest might indicate the severity of myocardial damage, and this might also explain a possible reason why her first VF event in the ambulance was resistant to electrical defibrillation, although a possible involvement of excess catecholamine for development of TTC was not excluded as a cause of unresponsiveness of VF to electrical defibrillation. Thus, the initial presentation of TTC as cardiac arrest could be regarded as a sign of high risk and indicate poor prognosis. In our previous study, J-wave and fragmented QRS in the hyperacute phase of TTC indicated the presence of severe myocardial damage.⁴ Actually, this case developed VF with the presence and augmentation of J-wave during the hyperacute phase of TTC. The appearance of J-wave during the hyperacute phase could be interpreted as another sign of high risk for VF and a determinant of poor prognosis. With further progression of TTC in elapsed time, she further developed QT prolongation and TdP, leading to VF preceded by a short-long-short sequence provoked by premature atrial contraction and bradycardia. The QT prolongation in TTC represented a progression of heart failure as discussed above, and it could also be regarded as a sign of high risk for VT/VF and a determinant of prognosis. Therefore, the development of the QT prolongation needs careful management of depressed cardiac function and care must be taken to avoid QT-prolonging drugs and electrolyte imbalance in patients with TTC. Appearance of premature contractions and bradycardia should be protected in the setting of QT prolongation.

Summary

A case of TTC developed 2 modes of initiation for VF with a separate time course, 1 from augmented J-wave initiating

VF and the other from a short-long-short sequence with prolonged QT interval leading to TdP/VF.

References

1. Bonello L, Com O, Ait-Moktar O, Théron O, Moro PJ, Salem A, Sbragia P, Paganelli F. Ventricular arrhythmias during Tako-Tsubo syndrome. *Intern J Cardiol* 2007;128:e50–e53.
2. Madias C, Fitzgibbons TP, Alsheikh-Ali AA, Bouchard JL, Kalsmith B, Garlitski AC, Tighe DA, Estes NA 3rd, Aurigemma GP, Link MS. Acquired long QT syndrome from stress cardiomyopathy is associated with ventricular arrhythmias and torsades de pointes. *Heart Rhythm* 2011;8:555–561.
3. Kawano H, Matsumoto Y, Arakawa S, Satoh O, Hayano M. Premature atrial contraction induces torsades de pointes in a patient of Takotsubo cardiomyopathy with QT prolongation. *Intern Med* 2010;49:1767–1773.
4. Shimizu M, Nishizaki M, Yamawake N, Fujii H, Sakurada H, Isobe M, Hiraoka M. J wave and fragmented QRS formation during the hyperacute phase in Takotsubo cardiomyopathy: possible markers for severity of myocardial damage. *Circ J* 2014;78:943–949.
5. Haïssaguerre M, Derval N, Sacher F, et al. Sudden cardiac arrest associated with early repolarization. *N Engl J Med* 2008;358:2016–2023.
6. Rudic B, Veltmann C, Kuntz E, Behnes M, Elmas E, Konrad T, Kuschyk J, Weiss C, Borggrefe M, Schimpf R. Early repolarization pattern is associated with ventricular fibrillation in patients with acute myocardial infarction. *Heart Rhythm* 2012;9:1295–1300.
7. Inamura Y, Nishizaki M, Shimizu M, Fujii H, Yamawake N, Suzuki M, Sakurada H, Hiraoka M, Isobe M. Early repolarization and positive T-wave alternans as risk markers for life-threatening arrhythmias in patients with vasospastic angina. *Int J Cardiol* 2015;196:7–13.
8. Antzelevitch C, Yan G. Cellular basis for the electrocardiographic J wave. *Circulation* 1996;93:372–379.
9. Yan GX, Antzelevitch C. Cellular basis for the Brugada syndrome and other mechanisms of arrhythmogenesis associated with ST segment elevation. *Circulation* 1999;100:1660–1666.
10. Akashi YJ, Goldstein DS, Barbaro G, Ueyama T. Takotsubo cardiomyopathy. A new form of acute, reversible heart failure. *Circulation* 2008;118:2754–2762.
11. Yan GX, Joshi A, Guo D, Hlaing T, Martin J, Xu X, Kowey OR. Phase 2 reentry as a trigger to initiate ventricular fibrillation during early acute myocardial ischemia. *Circulation* 2004;110:1036–1041.
12. January CT, Fozzard HA. Delayed afterdepolarizations in heart muscle: mechanisms and relevance. *Pharmacol Rev* 1988;40:219–227.
13. Tsuji Y, Opthof T, Kamiya K, Yasui K, Liu W, Lu Z, Kodama I. Pacing-induced heart failure causes a reduction of delayed rectifier potassium currents along with decreases in calcium and transient outward currents in rabbit ventricle. *Cardiovasc Res* 2000;48:300–309.
14. Li GR, Lau CP, Ducharme A, Tardif JC, Nattel S. Transmural action potential and ionic current remodeling in ventricles of failing canine hearts. *Am J Physiol Heart Circ Physiol* 2002;283:H1031–H1041.
15. Wang H, Chen Y, Zhu H, Wang S, Zhang X, Xu D, Cao K, Zou J. Increased response to β_2 -adrenoreceptor stimulation augments inhibition of IKr in heart failure ventricular myocytes. *PLoS One* 2012;7:e46186.