

# Concurrent nonfunctional paraganglioma of the retroperitoneum and urinary bladder: A case report with literature review

Poonam Sherwani, Rama Anand, Mahender Kaur Narula, Azaz Akhtar Siddiqui<sup>1</sup>, Shilpi Aggarwal<sup>2</sup>

Departments of Radiodiagnosis, <sup>1</sup>Surgery and <sup>2</sup>Pathology, Lady Hardinge Medical College and Associated Hospitals, New Delhi, India

**Correspondence:** Dr. Poonam Sherwani, Department of Radiodiagnosis, Lady Hardinge Medical College and Associated Hospitals, New Delhi - 110 001, India. E-mail:Poonam\_doc2003@yahoo.co.in

## Abstract

Paragangliomas are the neuroendocrine tumors which arise from the chromaffin cell. Tumors arising from the adrenal medulla are known as pheochromocytomas, while others originating from the extra-adrenal site are known as extra-adrenal paragangliomas. Paraganglioma can be multifocal which can arise synchronously or metachronously. Paragangliomas are less functionally active than the pheochromocytomas; they secrete noradrenaline and rarely dopamine, while adrenal pheochromocytomas secrete adrenaline or nor-adrenaline. Nonfunctional multifocal paragangliomas are very rare. We report a case of a 45-year-old female with multifocal nonfunctional paragangliomas of the retroperitoneum and urinary bladder which were surgically removed, and the diagnosis was confirmed on histopathology

**Keywords:** Imaging; neuroendocrine; paraganglioma; pheochromocytoma; retroperitoneum

## Introduction

Paraganglia are the cells of neuroendocrine origin which lie near or in the autonomic nervous system and extend from the skull base to the pelvic floor.<sup>[1]</sup> They are divided into two groups, that is, parasympathetic system located in the head, neck, and anterior mediastinum and those related to the sympathetic system which is found in posterior mediastinum and the retroperitoneum.<sup>[1]</sup> Most of the paragangliomas secrete catecholamines and the clinical presentations include headache, palpitations, and sweating; however, 10% of them are clinically silent and are

detected incidentally at imaging. Common sites of extra-adrenal paragangliomas are the para-aortic region at the level of renal hila (46%), at the organ of Zuckerkandl (29%), thoracic paraspinal region (10%), bladder (10%), and head and neck (2-4%).<sup>[2]</sup> Urinary bladder is rarely involved with predilection for anterior and posterior wall and the trigone is rarely involved.<sup>[3]</sup>

Isolated nonfunctional bladder paraganglioma is very rare and has been reported previously.<sup>[4]</sup> However, concurrent nonfunctional paraganglioma of the retroperitoneum and urinary bladder have not been reported so far, to the best of our knowledge.

## Case Report

A 45-year-old female presented in surgical OPD with pain in upper abdomen since 2 years, along with history of headache on and off. There was no history of palpitation, fainting attack or blackouts, or hematuria. There was no history of diabetes mellitus or hypertension. General physical examination did not reveal any significant

### Access this article online

#### Quick Response Code:



**Website:**  
www.ijri.org

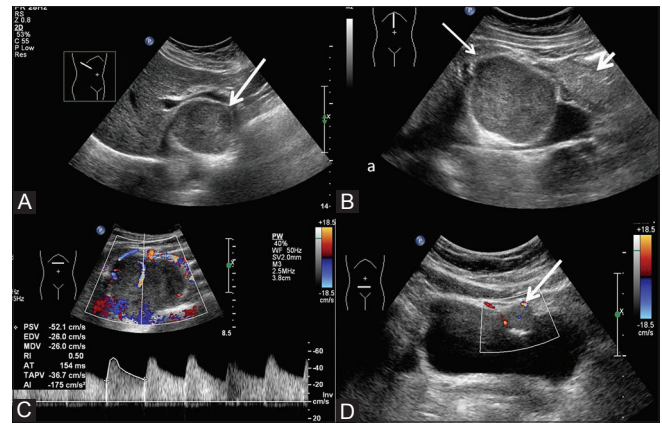
**DOI:**  
10.4103/0971-3026.155879

abnormality. Her routine hematological and biochemical parameters including serum calcium were within normal limits. USG abdomen was performed with curvilinear low frequency transducer (Philips IU 22, United States, Bothell, Washington, USA) which revealed a well-defined, round hypoechoic lesion measuring 5 × 4 cm in the retroperitoneum, lying in close relation to the pancreatic head and causing displacement of the pancreas anteriorly [Figure 1A and B]. On color Doppler, the mass was highly vascular showing peripheral and central vascularity and the spectral pattern revealed arterial waveform with low resistance waveform and high diastolic flow with a resistive index of 0.5 [Figure 1C]. In addition, similar vascular well-defined hypoechoic mass lesion was seen arising from the anterior wall of urinary bladder [Figure 1D].

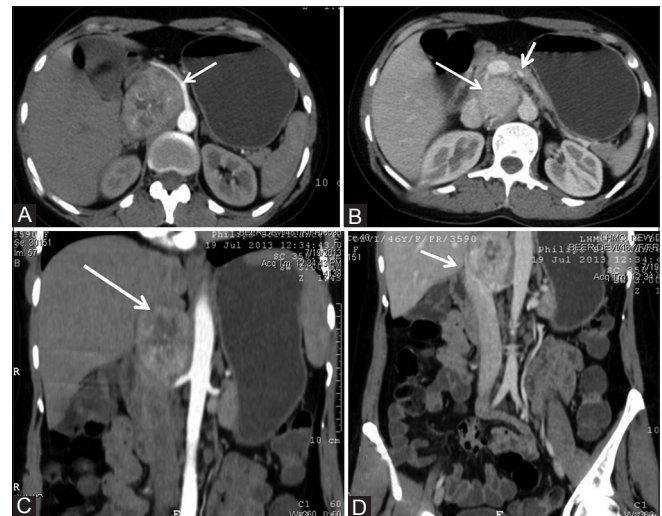
For further characterization, biphasic contrast-enhanced computed tomography (CECT) abdomen and pelvis was performed [40slice Philips Brilliance Scanner, New Jersey United States] subsequently. The mass lesion in the retroperitoneum was seen in aortocaval location, causing lateral displacement of inferior vena cava (IVC) [Figure 2B and D]. The mass showed significant enhancement in arterial phase and persistent heterogeneous enhancement in portal venous phase, along with few areas of necrosis. There was anterior displacement and splaying of celiac axis trunk [Figure 2A and B] with anterior displacement of portal vein and pancreas [Figure 2B]. Bilateral adrenal glands were normal [Figure 2C]. The anterior urinary bladder wall lesion also showed intense enhancement [Figure 3A]. There was another similar tiny enhancing lesion seen arising from the posterior wall of bladder [Figure 3B].

On imaging, based on the location of lesions along the sympathetic chain and the enhancement pattern, diagnosis of multifocal extra-adrenal paraganglioma was made. Differential diagnosis included neuroendocrine tumors of bladder and retroperitoneum and hypervascular metastatic lesions in the bladder and retroperitoneum. USG neck and CECT chest done to look for primary and other similar lesions did not reveal any abnormality. Serum catecholamines and 24-h urinary vanillylmandelic acid (VMA) levels were measured, which were within normal limits (VMA levels-3.89mg/g; normal ref range-1.60-4.20 mg/g). Urinary cytology did not reveal any malignant cells. Cystoscopy was done subsequently which revealed a 2 × 2 cm, highly vascular mass lesion arising from the anterior wall of urinary bladder.

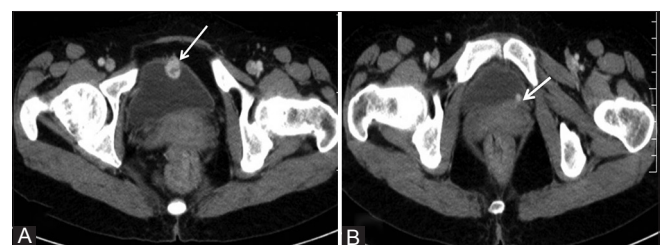Retroperitoneal and urinary bladder masses were surgically excised. Both the tumors were highly vascular. There were no significant perioperative and postoperative complications [Figure 4A and B]. Histopathology confirmed the diagnosis of paraganglioma. No capsular or vascular invasion was seen [Figure 5A and B].



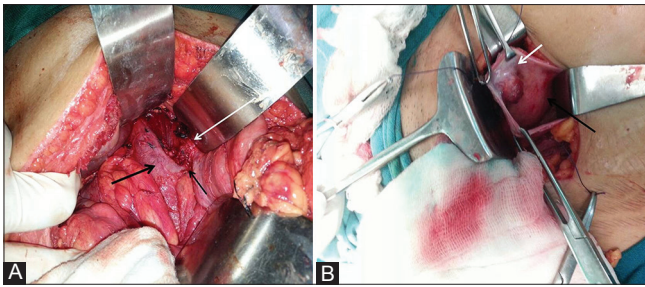
**Figure 1 (A-D):**(A and B)Transabdominal USG shows a well-defined hypoechoic lesion (arrows in A and B) in the retroperitoneum, causing anterior displacement of the pancreas (small arrow in B) (C) On color Doppler, the mass shows peripheral and central vascularity along with low-resistance arterial waveform (D) Well-defined similar vascular hypoechoic lesion (arrow) is seen arising from the anterior wall of urinary bladder



**Figure 2 (A-D):** CECT abdomen arterial phase axial (A) and coronal reformatted (C) images show the para-aortic mass (arrow in C) showing arterial enhancement. The mass is causing anterior displacement and splaying of celiac axis trunk (arrow in A) (B) Portal venous phase shows persistent enhancement of the mass (arrow), causing anterior displacement of pancreas (small arrow) and normal bilateral adrenal glands (D) Coronal reformatted image show the mass causing displacement and compression of IVC (arrow in D)



**Figure 3 (A and B):** CECT axial sections showing the enhancing mass lesion arising from the anterior wall of urinary bladder (arrow in A). Another similar tiny lesion was seen arising from the posterior wall of bladder (arrow in B)



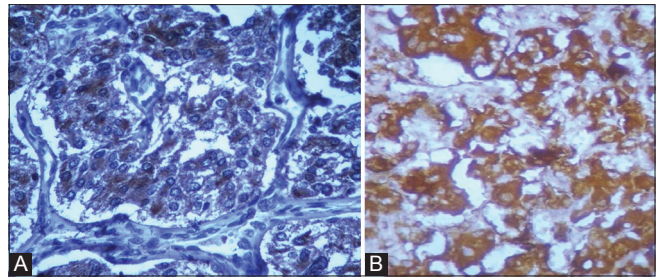
**Figure 4 (A and B):** (A) Surgical photograph of the retroperitoneal mass (white arrow) in relation to IVC (large black arrow) and renal vein (small black arrow). (B) Intraoperative photograph showing the bladder mass (white arrow) arising from the urinary bladder (black arrow)

## Discussion

Paraganglioma constitutes only 10% of pheochromocytomas.<sup>[5]</sup> Bladder paraganglioma constitutes 0.06% of all bladder tumors and 6% of all extra-adrenal paragangliomas.<sup>[4]</sup>

Paragangliomas are seen in adults and are mostly benign. The patient presented with signs and symptoms related to catecholamine secretion and included paroxysmal hypertension with anxiety, sweating, throbbing headache, and facial pallor or flushing during the attack. Classic triad includes palpitation, sweating, and throbbing headache. Functional tumors secrete epinephrine and other catecholamines but these metabolites were not detected in the blood in our case and there was no intraoperative fluctuation of blood pressure. 10-15% of these tumors are nonfunctional and in 10%, hormone activity does not manifest clinically.<sup>[6]</sup> Most of the extra-adrenal paragangliomas either arise sporadically as was seen in our case or have familial inheritance which is seen in 10% of cases. The mode of transmission is autosomal dominant with incomplete penetrance. These familial tumors are seen in association with multiple syndromes including neurofibromatosis 1, multiple endocrine neoplasia syndrome and Von Hippel-Lindau syndrome.<sup>[1]</sup> Paraganglioma is also seen as part of Carney triad which consists of gastric leiomyosarcoma, pulmonary chondroma, and extra-adrenal paraganglioma.<sup>[1]</sup>

USG is the first line of investigative modality to detect the silent as well as functioning ectopic lesions. Doppler demonstrates the vascular nature of these tumors, which was also observed in our case.<sup>[7]</sup> Biphasic CECT abdomen is the modality of choice to diagnose these tumors as the entire sympathetic chain can be evaluated. Multiple and small tumors can also be detected. In our case, additional urinary bladder lesion was detected on CT which was not seen on USG. Small tumors show arterial enhancement and appear homogeneous as compared to larger tumors which show heterogeneous enhancement as was observed in our case. Areas of calcification or hemorrhage can also be seen. On magnetic resonance imaging (MRI), these tumors are iso- to hypointense to liver parenchyma and markedly hyperintense on T2-weighted (T2W) images.



**Figure 5 (A and B):** (A) Photograph of histological specimen showing nest of tumor cells separated by blood vessels. The cells are large with eosinophilic granular cytoplasm, vesicular nucleus, and prominent nucleoli. No mitosis or necrosis seen. (B) Immunohistochemistry results with chromogranin A show cytoplasmic positivity

MRI does not have any advantage over CT except for better tissue characterization with no radiation hazard. I131-labeled metaiodobenzylguanidine (MIBG) scintigraphy is highly effective for diagnosis and has a sensitivity of 100% in the diagnosis of extra-adrenal pheochromocytoma.<sup>[8]</sup> It provides the functional information as well as shows multiple tumors and metastasis.<sup>[1]</sup>

Paragangliomas are seen anywhere from the head and neck to pelvis. Head and neck paragangliomas are nonfunctioning and present with mass effect.<sup>[1]</sup> Jugulotympanic paragangliomas are known as chemodectomas which are sensitive to changes in the blood gas.<sup>[1]</sup> Sporadic pheochromocytoma affects patients in 5<sup>th</sup>-7<sup>th</sup> decade with female predilection, while extra-adrenal paraganglioma affects patients in 2<sup>nd</sup> or 3<sup>rd</sup> decade with male predominance. Extra-adrenal paragangliomas are more often multifocal than the adrenal lesions. Extra-adrenal paragangliomas are aggressive tumors with 22-50% showing metastasis as compared to pheochromocytomas which show metastasis in 2-10%.<sup>[9]</sup> At gross examination, paragangliomas are large, firm, encapsulated masses that adhere to adjacent structures.<sup>[10]</sup> The mainstay of treatment is surgical removal,<sup>[11]</sup> but recurrent cases are treated by radiation therapy. Chemotherapy does not have a role except for metastatic disease.<sup>[12]</sup> However, imaging contributes to surgical planning as it not only helps in the diagnosis but also depicts multiple lesions. Imaging can also serve as a screening tool for patients with familial syndromes like MEN-2A, MEN-2B, Neurofibromatosis-1, Von Hippel-Lindau disease who are at high risk for extra-adrenal paraganglioma.

## References

1. Sahdev A, Sohaib A, Monson JP, Grossman AB, Chew SL, Reznick RH. CT and MR imaging of unusual locations of extra-adrenal paragangliomas (pheochromocytomas). *Eur Radiol* 2005;15:85-92.
2. Lee KY, Oh YW, Noh HJ, Lee YJ, Yong HS, Kang EY, *et al.* Extraadrenal paragangliomas of the body: Imaging features. *AJR Am J Roentgenol* 2006;187:492-504.
3. Honma K. Paraganglia of the urinary bladder. An autopsy study. *Zentralbl Pathol* 1994;139:465-9.

4. Xu DF, Chen M, Liu YS, Gao Y, Cui XG. Non-functional paraganglioma of the urinary bladder: A case report. *J Med Case Rep* 2010;4:216.
5. Thrasher JB, Rajan RR, Perez LM, Humphrey PA, Anderson EE. Pheochromocytoma of urinary bladder: Contemporary methods of diagnosis and treatment options. *Urology* 1993;41:435-9.
6. Karaçetin D, Halefoğlu A, Kabukçuoğlu F, Tatar Z. Retroperitoneal paraganglioma: Case presentation. *Istanbul Med J* 2010;11:137-141.
7. Cronan JJ, Do HM, Monchik JM, Stein BS. Bladder pheochromocytoma. Color Doppler sonographic correlation. *J Ultrasound Med* 1992;11:493-5.
8. Heyman J, Cheung Y, Ghali V, Leiter E. Bladder pheochromocytoma: Evaluation with magnetic resonance imaging. *J Urol* 1989;141:1424-6.
9. Rajiah P, Sinha R, Cuevas C, Dubinsky TJ, Bush WH Jr, Kolokythas O. Imaging of uncommon retroperitoneal masses. *Radiographics* 2011;31:949-76.
10. Pui MH, Liu MJ, Guo Y, Chen YM. Computed tomography of retroperitoneal paragangliomas. *Australas Radiol* 1999;43:303-6.
11. Bryant RL, Stevenson DR, Hunton DW, Westbrook KC, Casali RE. Primary malignant retroperitoneal tumors. Current management. *Am J Surg* 1982;144:646-9.
12. Mikhail RA, Moore JB, Reed DN Jr, Abbott RR. Malignant retroperitoneal paragangliomas. *J Surg Oncol* 1986;32:32-6.

**Cite this article as:** Sherwani P, Anand R, Narula MK, Siddiqui AA, Aggarwal S. Concurrent nonfunctional paraganglioma of the retroperitoneum and urinary bladder: A case report with literature review. *Indian J Radiol Imaging* 2015;25:198-201.

**Source of Support:** Nil, **Conflict of Interest:** None declared.