

Management of Children and Adolescents with Wilson Disease and Neurological Worsening Following D–Penicillamine Therapy: A Single Centre Experience

Madhan Kumar, Murugan T. P, Arul P. Lionel, Maya M. Thomas¹, Pavithra Mannam², Sangeetha Yoganathan¹

Departments of Paediatrics, ¹Neurological Sciences, ²Radiodiagnosis, Christian Medical College, Vellore, Tamil Nadu, India

Abstract

Background: Most centers in developing countries prefer chelation therapy with D-penicillamine for the management of Wilson's disease (WD) because of its easy availability and affordability. Neurological worsening following treatment with D-penicillamine is not uncommon. However, there is a paucity of Indian data on the incidence of neurological worsening in children and adolescents with WD following chelation therapy. Our study objectives were to identify the prevalence of neurological worsening in children and adolescents with WD following chelation with D–penicillamine therapy and to describe the management options and outcomes in these patients. **Materials and Methods:** In this retrospective chart review, children and adolescents with an established diagnosis of WD from 2010 to 2020 were identified from the hospital electronic database. Among these patients, data of children and adolescents with neurological worsening following D–penicillamine therapy were extracted and analyzed. **Results:** Neurological worsening was observed in 27/122 (22.1%) children and adolescents with WD on chelation therapy with D-penicillamine. Fifteen patients with neurological worsening following D-penicillamine therapy were managed with zinc monotherapy. Four patients were managed with a combination therapy of zinc and trientine. Five patients were treated with trientine monotherapy. Re-challenging with D-penicillamine at a lower dose followed by a slow dose escalation was attempted in three patients. Gradual clinical and functional status improvement was observed in 24 cases while one patient succumbed to pneumonia. **Conclusion:** Children and adolescents with WD who had neurological worsening on D-penicillamine therapy may be managed with trientine. Zinc monotherapy with copper restricted diet was also found to be effective in non-affordable patients.

Keywords: D-penicillamine, neurological worsening, trientine, Wilson disease, zinc

INTRODUCTION

Wilson disease (WD) is an autosomal recessive disorder caused by a mutation in the *ATP7B* gene, mapped to chromosome 13.^[1] *ATP7B* gene plays a key role in the copper metabolism in humans. As a result of a mutation in the *ATP7B* gene, an excessive accumulation of copper occurs in the liver, eye, brain, and heart. The worldwide prevalence of WD has been estimated to vary from 1 in 30,000 to 1.2 in 100,000.^[2,3] The clinical manifestations in WD may vary depending upon the organ involved. Diagnosis of WD must be considered in patients with typical clinical symptoms and signs, presence of Kayser–Fleischer (KF) rings, decreased serum ceruloplasmin level, elevated urinary copper excretion and *ATP7B* gene mutation. However, the typical clinical symptoms may not be observed in all patients with WD and the available biochemical testing may not be specific for WD. Leipzig scoring system includes typical clinical symptoms and signs, assessment for KF rings, and assessment of laboratory parameters such as low serum ceruloplasmin, coombs-negative hemolytic anemia, increased urinary copper excretion, increased hepatic copper content, and mutation analysis.^[4] Leipzig score improves the diagnostic accuracy in patients with WD and if the total score is ≥ 4 , the diagnosis of WD is established.^[4] In the early 1950s, Dimercaprol (BAL) administered as an intramuscular injection was used in the management of WD.^[5] Long-term use

of BAL resulted in declining clinical benefits and increasing adverse effects warranting a search for alternate medication. D–Penicillamine, another chelator used in WD was first introduced by John Walshe in 1955.^[6] This drug acts by adhering to tissue-bound copper in various organs thereby facilitating urinary copper excretion. Though widely used, adverse effects following chelation therapy with D–penicillamine are not uncommon and the neurological worsening following D-penicillamine is an important determinant of treatment modification. Apart from the copper chelators, drugs that decrease the intestinal absorption of copper such as zinc may

Address for correspondence: Dr. Sangeetha Yoganathan, Paediatric Neurology Unit, Department of Neurological Sciences, Christian Medical College, Vellore - 632 004, Tamil Nadu, India. E-mail: doc_ys@yahoo.co.in

Submitted: 06-Jun-2021 **Revised:** 09-Sep-2021 **Accepted:** 03-Oct-2021

Published: 09-Sep-2022

This is an open access journal, and articles are distributed under the terms of the Creative Commons Attribution-NonCommercial-ShareAlike 4.0 License, which allows others to remix, tweak, and build upon the work non-commercially, as long as appropriate credit is given and the new creations are licensed under the identical terms.

For reprints contact: WKHLRPMedknow_reprints@wolterskluwer.com

DOI: 10.4103/aian.aian_519_21

be an alternate or adjunctive therapy.^[7] Trientine has also been used in the management of WD and this drug is structurally different from D-penicillamine by the lack of sulfhydryl group. It chelates copper by forming stable complexes with nitrogen.^[8] The neurological worsening following treatment with D-penicillamine in children and adolescents has not been widely studied in the Indian population. Various treatment protocols have been employed in clinical practice in patients with WD having neurological worsening on D-penicillamine therapy. Our study objectives were to identify the prevalence of neurological worsening in children and adolescents with WD following chelation with D-penicillamine therapy and to describe the management options and outcomes in these patients.

MATERIALS AND METHODS

This retrospective study was approved by the Institutional Review Board of Christian Medical College, Vellore, Tamil Nadu, India. Data of children and adolescents with an established diagnosis of WD based on the typical clinical symptoms and signs, presence of Kayser-Fleischer rings, and low serum ceruloplasmin level who attended the Paediatric Neurology clinic from 2010 to 2020 were extracted from the hospital electronic database. Children and adolescents with WD who had neurological worsening following D-penicillamine therapy were identified from this cohort. Details of history, general and neurological examination findings, systemic examination findings, laboratory parameters, and imaging findings were documented. The elemental zinc dose used in our cohort was 25 mg thrice daily in children weighing <50 kg and 50 mg thrice daily in children ≥ 16 years of age.^[8,9] D-penicillamine was escalated slowly from 5 to 20 mg/kg/day in divided doses over a few weeks.^[10] Pyridoxine was administered in children and adolescents on D-penicillamine therapy. Chelation therapy was administered 1 hour before or 2 hours after meals. Treatment details and the clinical outcome at follow-up were entered on EpiData proforma. The statistical analysis was performed using the IBM® SPSS® Statistics Version 21.

RESULTS

Among 122 children and adolescents with an established diagnosis of WD, D-penicillamine related neurological and systemic adverse effects were detected in 31 children and adolescents. Neurological worsening was observed in 27/122 (22.1%) children and adolescents with WD following chelation therapy with D-penicillamine. Three patients treated with D-penicillamine had proteinuria while one had pancytopenia. Among 27 children and adolescents with WD who had neurological worsening on D-penicillamine therapy, the mean age at onset of disease was 10.2 ± 1.8 y. A male preponderance was identified in our study population (3.5:1). Among these patients, the clinical symptoms at presentation to our centre were deterioration of gross and fine motor functions, slurring of speech, swallowing dysfunction, cognitive decline,

involuntary movements, psychiatric symptoms, and seizures. Seizures were documented only in two (7.4%) patients. Though worsening of extrapyramidal symptoms was identified in all 27 patients, status dystonicus was observed only in six patients. Deterioration of scholastic performance was seen in 12/27 patients. Psychiatric manifestations including emotional lability, anger outbursts, and personality changes were identified in eight patients. D-penicillamine was initiated elsewhere in more than half of patients manifesting with neurological worsening. KF ring was detected in all 27 patients while sunflower cataract was detected in two patients. Bony deformities and tendo-achilles contractures were documented in seven patients. Spasticity, rigidity or variable tone was observed in 22 patients while the remaining had normal tone at presentation. The demographic and clinical profile of children and adolescents with WD at presentation who had neurological worsening following D-penicillamine therapy are summarized in Table 1.

Serum ceruloplasmin level was low in 26 patients while one patient had borderline serum ceruloplasmin level with elevated urinary copper excretion. All tested patients except for two had an elevated urinary copper level of more than 100 $\mu\text{g}/\text{dL}$. Though a history of jaundice was documented only in two patients, all 27 patients had radiological evidence of chronic liver disease. Four patients had radiological features of portal hypertension. The laboratory and radiological features of children and adolescents with WD who had

Table 1: Demographic and clinical profile of children and adolescents with WD at presentation who had neurological worsening following D-penicillamine therapy

Variable	n (%)
Mean age of onset of the disease (y)	10.2 \pm 1.8
Male:female	3.5:1
History of consanguinity	4 (14.8%)
Slurring of speech	20 (74%)
Swallowing dysfunction	17 (62.9%)
Lingual dystonia	9 (33.3%)
Deterioration of gross and fine motor functions	27 (100%)
Extrapyramidal involvement	27 (100%)
Status dystonicus	6 (22.2%)
Other movement disorders (chorea, athetosis, tremors, stereotypies)	2 (7.4%)
Poor scholastic performance	12 (44.4%)
Cognitive decline	12 (44.4%)
Seizure	2 (7.4%)
Psychiatric manifestations	8 (29.6%)
Impaired activities of daily living	21 (77.7%)
Past history of jaundice	2 (7.4%)
Kayser-Fleischer ring	27 (100%)
Cataract	2 (7.4%)
Bony deformities and tendo-achilles contractures	7 (25.9%)
Abnormal tone	22 (81.4%)
Hepatomegaly	1 (3.7%)
Splenomegaly	3 (11.1%)

neurological worsening on D-penicillamine are described in Table 2.

Brain MR images were available for review only in 23 children and adolescents. The spectrum of brain MRI findings in patients with WD who had neurological worsening on D-penicillamine therapy is summarized in Table 3. T2-weighted hyperintense signal changes were identified predominantly involving caudate, putamen, and thalami. About one-third of these patients had signal changes in the midbrain and pons. Other imaging findings observed were cerebral atrophy, cerebellar atrophy, and white matter signal changes. Diffusion restriction was seen predominantly in deep grey nuclei, brainstem, and thalami. In susceptibility-weighted imaging, blooming of globus pallidi was observed in 11 patients.

Among 27 children and adolescents with WD who had neurological worsening following chelation therapy with D-penicillamine, 19 (70.4%) received D-penicillamine as monotherapy while 8 (29.6%) received D-penicillamine and zinc at the initiation of treatment [Figure 1]. A copper restricted diet was emphasized in all children and adolescents with WD. None of the children and adolescents with WD were initiated on trientine or tetrathiomolybdate at the onset of treatment due to high cost and lack of easy availability. Fifteen patients with WD following worsening with D-penicillamine therapy were managed with zinc monotherapy while four patients were managed with combination therapy of zinc and trientine. Five patients were treated with trientine monotherapy. Re-initiation with D-penicillamine at a lower dose followed by a slow dose escalation was attempted in three patients and zinc was continued [Figure 2]. A copper restricted diet was continued in all cases. The choice of medications following a neurological worsening in children with WD was determined by the affordability, availability of alternate medications, and physician's decision. The frequency of follow-up visits was variable among the patients and the median duration of follow-up was 13.5 months (range: 3-72 months). Gradual improvement in the functional and neurological status was observed in 24/27 patients. All five patients treated with trientine monotherapy and four patients treated with a combination of trientine and zinc had shown gradual clinical improvement.

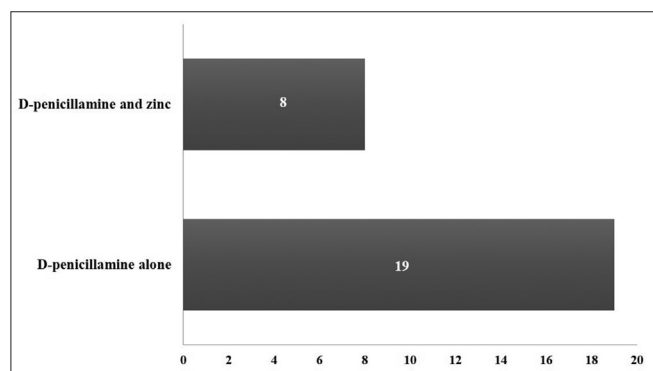


Figure 1: Initial drug treatment in 27 children and adolescents with WD prior to neurological worsening

Among 15 patients treated with zinc monotherapy, 13 patients had improved. Following re-initiation of treatment with a combination of low dose D-penicillamine with a slow escalation and zinc, two patients had gradually improved. One child in our study group succumbed to pneumonia.

DISCUSSION

WD, an inherited metal storage disorder manifests commonly with hepatic, neurological, and psychiatric manifestations. The hepatic manifestations include elevated liver enzymes, hepatomegaly, splenomegaly, fatty liver, acute hepatitis,

Table 2: Laboratory and abdominal ultrasonography findings of children and adolescents with WD who had neurological worsening following d-penicillamine

Laboratory parameters	Frequency
Elevated liver enzymes	9 (33.3%)
Low or borderline serum ceruloplasmin level	27 (100%)
Elevated 24 h urinary copper excretion (n=24)	22 (81.5%)
Chronic liver disease on ultrasonography	27 (100%)

Table 3: MRI brain findings in children and adolescents with WD who had neurological worsening following d-penicillamine

Site of involvement	T2-weighted images (n=23)	Diffusion-weighted images (n=23)
Caudate	22	3
Putamen	21	3
Globus pallidi	3	1
Thalami	10	1
Middle cerebellar peduncle	1	1
Subthalamic nuclei	2	0
Red nucleus	2	0
Pons	8	4
Mid-brain	8	5
Cerebellum	12	1
Cerebral cortex	19	1
White matter	2	0

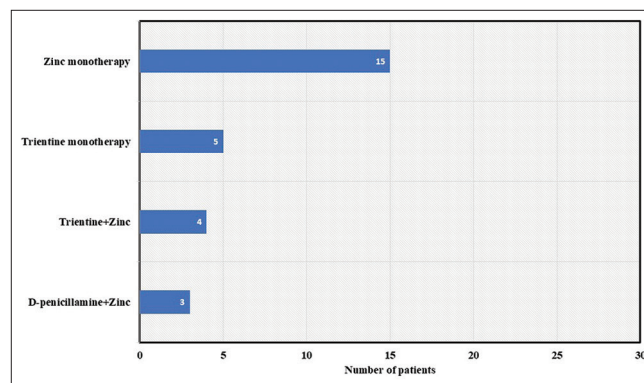


Figure 2: Drug treatment in children and adolescents with WD following neurological worsening with D-penicillamine

liver failure, cirrhosis, and hemorrhagic diathesis.^[8,11] Among 27 patients in our study group, all had radiological evidence of chronic liver disease. The neuropsychiatric manifestations described in patients with WD include dystonia, tremor, chorea, Parkinsonism, insomnia, dysarthria, seizures, headache, autonomic dysfunction, depression, psychosis, personality changes, and neurotic behavior.^[8,12] Our patients also manifested dystonia, dysarthria, bulbar dysfunction, deterioration of motor skills, seizures, and psychiatric symptoms. Serum ceruloplasmin level was low in all patients in our study group except one with a borderline serum ceruloplasmin level. Patients with WD may have normal serum ceruloplasmin if the level is estimated using the immunological assay or if there is an ongoing marked hepatic inflammation or with use of oral contraceptive medications.^[4] All tested patients in our cohort had elevated 24-hour urinary copper excretion except for two patients. Though urinary copper excretion was expected to be high in patients with WD, 16-23% of patients with WD may have a normal urinary copper level at presentation.^[8] Improper sample collection and absence of liver disease may attribute to normal urinary copper excretion in patients with WD.^[4] The imaging findings described in 364 patients with WD identified an involvement of putamen followed by pons and thalami.^[12] On the contrary, almost an equal proportion of patients had involvement of caudate and putamen followed by involvement of cerebral cortex, cerebellum, thalami and brain stem in our cohort of patients with WD who developed neurological worsening following D-penicillamine therapy.

Most centers in developing countries choose D-penicillamine as first-line therapy for the treatment of WD. The adverse effects reported in patients treated with D-penicillamine are fever, skin rash, lupus-like reaction, gastric symptoms, arthralgia, neurological worsening, aplastic anemia, leucopenia, thrombocytopenia, proteinuria, retinitis, hepatotoxicity, and renal impairment.^[8,13] A total of 31 patients in our cohort had adverse effects following D-penicillamine. Three patients had pancytopenia, one had proteinuria and 27 patients had neurological worsening. The reported incidence of neurological worsening following initial D-penicillamine therapy varied between 30% and 75% while the prevalence in our cohort was 22.1%.^[14] Weiss *et al.*^[15] identified only a lower incidence of neurological worsening in patients with WD. Most patients in our cohort with neurological worsening improved after discontinuation of D-penicillamine therapy. The neurological worsening in our patients occurred mostly within 1-3 months of treatment initiation which is similar to the other previous reports.^[14,16] The plausible explanation for clinical deterioration following treatment with D-penicillamine is due to mobilization of copper after chelation treatment with a resultant increase in free copper, increased malondialdehyde, and reduced glutathione.^[1] An animal model of WD also supports the same mechanisms.^[17] Other causes for neurological deterioration in patients with WD could possibly be due to the natural progression of the underlying disease, inadequate drug dosage, poor compliance to medications, rapid

escalation of chelation therapy, and non-adherence to a copper restricted diet. In our study, more than half of patients with WD were initiated on chelation treatment with D-penicillamine elsewhere before presentation to our hospital; hence, the exact detail of the dosing schedule was not available in most cases. It would be crucial to analyze this information which might be an important contributing factor to neurological worsening.

Chang *et al.*^[18] found a lower risk of clinical worsening in patients with WD initiated on a combination of low-dose D-penicillamine and high-dose zinc. Though copper chelators are efficacious in the management of patients with WD, zinc therapy appears to be a reasonable alternative drug to copper chelators.^[19-21] Zinc monotherapy resulted in neurological improvement in 90% of patients while no improvement or worsening of neurological symptoms was observed in 75% of patients on D-penicillamine therapy.^[21] Zinc acts by inducing intestinal and hepatic metallothionein which binds to free copper with high affinity, and it also competes with copper for absorption at the intestinal level and thereby prevents entry of copper into the portal circulation.^[1,22] Zinc also inhibits lipid peroxidation and increases the glutathione level thereby decreasing oxidative stress.^[1] Zinc may thus be beneficial in patients with WD manifesting with neurological symptoms.^[23] Trientine, another copper chelator may be better tolerated in patients with WD. Tetrathiomolybdate, another drug used in the management of WD acts by two different mechanisms.^[24] On administration with food, it prevents intestinal absorption of copper by binding copper in food while on administration without food, the drug enters in to the circulation and facilitates complexing of copper with albumin thereby preventing cellular uptake of copper.^[24]

In our cohort, the choice of alternate drugs was tailored according to the affordability of patients and the availability of trientine. In patients with WD and neurological worsening with documentation of rapid escalation of D-penicillamine

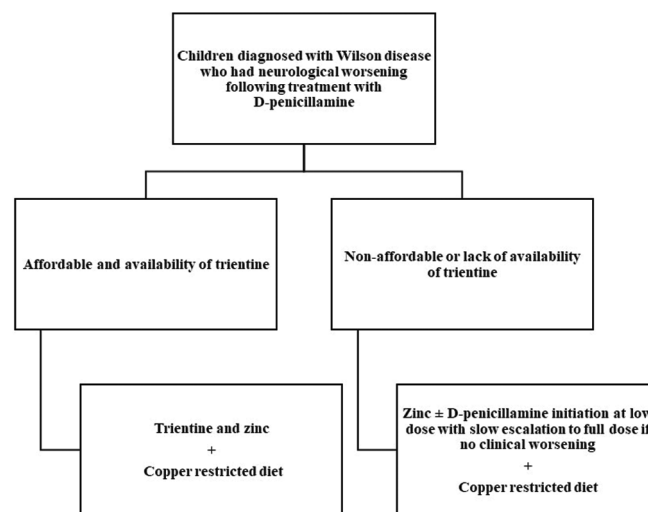


Figure 3: Proposed protocol for the treatment of children and adolescents diagnosed with Wilson disease who has neurological worsening following initial chelation with D-penicillamine

and non-affordability for trientine, re-initiation of a low dose of D-penicillamine and slow escalation over few weeks along with zinc was attempted. Not much variation in the clinical and functional improvement was identified among different regimens such as zinc monotherapy, trientine monotherapy, a combination of zinc and slow escalation of D-penicillamine, or a combination of zinc and trientine therapy in our study. Though trientine has been tried in patients with neurological worsening following D-penicillamine therapy, the reported risk of neurological worsening in these patients has been found to vary from 10-15%.^[8] A systematic review concluded that zinc may be preferred over D-penicillamine in patients with neurological manifestations.^[23] The proposed protocol for the treatment of children and adolescents diagnosed with WD developing neurological worsening following D-penicillamine therapy is shown in Figure 3. This is one of the fewer studies from India which analyzed patients with WD and neurological worsening following D-penicillamine therapy. As this is a retrospective chart review, clinical improvement was documented based on improvement in functional abilities and neurological status. A detailed formal assessment with rating scales at definite intervals were not available in most of these patients and this would be one of the major limitations.

CONCLUSION

To date, there is no clear consensus for the optimal management of patients with WD having neurological deterioration following initial D-penicillamine therapy. Children and adolescents with WD who had neurological worsening on D-penicillamine therapy may be managed with trientine. Although there is a lack of high-quality evidence, we conclude that zinc monotherapy and a copper-restricted diet may be effective in these patients in resource-limited settings. However, a prospective study with an appropriate study design and adequate sample size should be planned to confirm this observation.

Author's contribution

Madhan Kumar and Murugan T. P collected and analyzed the data and prepared the initial manuscript. Pavithra Mannam interpreted the neuroimaging findings and revised the manuscript. Arul P. Lionel and Maya M. Thomas revised the manuscript. Sangeetha Yoganathan supervised the data collection and analysis and revised the manuscript.

Financial support and sponsorship

Nil.

Conflicts of interest

There are no conflicts of interest.

REFERENCES

- Rodriguez-Castro KL, Hevia-Urrutia FJ, Sturniolo GC. Wilson's disease: A review of what we have learned. *World J Hepatol* 2015;7:2859-70.
- Pfeiffer R. Wilson's disease. *Semin Neurol* 2007;27:123-32.
- Poujois A, Woimant F. Wilson's disease: A 2017 update. *Clin Res Hepatol Gastroenterol* 2018;42:512-20.
- Ferenci P. Diagnosis of Wilson disease. *Handb Clin Neurol* 2017;142:171-80.
- Warnock CG, Neill DW. Dimercaprol in the pre-neurological stage of Wilson's disease (hepatolenticular degeneration). *J Neurol Neurosurg Psychiatry* 1954;17:70-4.
- Walshe JM. History of Wilson's disease: 1912 to 2000. *Mov Disord* 2006;21:142-7.
- Aggarwal A, Bhatt M. Advances in treatment of Wilson disease. *Tremor Hyperkinetic Mov* 2018;8:525.
- Roberts EA, Schilsky ML. Diagnosis and treatment of Wilson disease: An update. *Hepatology* 2008;47:2089-2111.
- Brewer GJ, Dick RD, Johnson VD, Fink JK, Kluin KJ, Daniels S. Treatment of Wilson's disease with zinc XVI: Treatment during the pediatric years. *J Lab Clin Med* 2001;137:191-8.
- Fukuoka N, Morita S, Hamatani S, Okada H, Kondoh M, Imai T, *et al.* [Appropriate administration schedule of D-penicillamine for pediatric Wilson's disease patients based on urinary copper excretion]. *Yakugaku Zasshi* 2002;122:585-8.
- European Association for the Study of the Liver. EASL clinical practice guidelines: Wilson's disease. *J Hepatol* 2012;56:671-85.
- Yu X-E, Gao S, Yang R-M, Han Y-Z. MR Imaging of the Brain in Neurologic Wilson Disease. *AJNR Am J Neuroradiol* 2019;40:178-83.
- Mohr I, Weiss KH. Current anti-copper therapies in management of Wilson disease. *Ann Transl Med* 2019;7(Suppl 2):S69.
- Kalita J, Kumar V, Chandra S, Kumar B, Misra UK. Worsening of Wilson disease following penicillamine therapy. *Eur Neurol* 2014;71:126-31.
- Weiss KH, Thurik F, Gotthardt DN, Schäfer M, Teufel U, Wiegand F, *et al.* Efficacy and safety of oral chelators in treatment of patients with Wilson disease. *Clin Gastroenterol Hepatol* 2013;11:1028-35.e2.
- Brewer GJ, Terry CA, Aisen AM, Hill GM. Worsening of neurologic syndrome in patients with Wilson's disease with initial penicillamine therapy. *Arch Neurol* 1987;44:490-3.
- Chen D-B, Feng L, Lin X-P, Zhang W, Li F-R, Liang X-L, *et al.* Penicillamine increases free copper and enhances oxidative stress in the brain of toxic milk mice. *PLoS One* 2012;7:e37709.
- Chang H, Xu A, Chen Z, Zhang Y, Tian F, Li T. Long-term effects of a combination of D-penicillamine and zinc salts in the treatment of Wilson's disease in children. *Exp Ther Med* 2013;5:1129-32.
- Członkowska A, Litwin T, Karliński M, Dziezyc K, Chabik G, Czerska M. D-penicillamine versus zinc sulfate as first-line therapy for Wilson's disease. *Eur J Neurol* 2014;21:599-606.
- Brewer GJ, Askari FK. Wilson's disease: clinical management and therapy. *J Hepatol* 2005;42:S13-21.
- Medici V, Trevisan CP, D'Inca R, Barollo M, Zancan L, Fagioli S, *et al.* Diagnosis and management of Wilson's disease: Results of a single center experience. *J Clin Gastroenterol* 2006;40:936-41.
- Bandmann O, Weiss KH, Kaler SG. Wilson's disease and other neurological copper disorders. *Lancet Neurol* 2015;14:103-13.
- Wiggelinkhuizen M, Tilanus MEC, Bollen CW, Houwen RHH. Systematic review: Clinical efficacy of chelator agents and zinc in the initial treatment of Wilson disease. *Aliment Pharmacol Ther* 2009;29:947-58.
- Brewer GJ, Askari F, Lorincz MT, Carlson M, Schilsky M, Kluin KJ, *et al.* Treatment of Wilson disease with ammonium tetrathiomolybdate: IV. Comparison of tetrathiomolybdate and trientine in a double-blind study of treatment of the neurologic presentation of Wilson disease. *Arch Neurol* 2006;63:521-7.