

Case Report

Osteomalacia as a Late Metabolic Complication of Ifosfamide Chemotherapy in Young Adults: Illustrative Cases and Review of the Literature

D. N. Church,¹ A. B. Hassan,² S. J. Harper,³ C. J. Wakeley,⁴ and C. G. A. Price¹

¹ Department of Medical Oncology, Bristol Haematology and Oncology Centre, Horfield Road, Bristol BS2 8ED, UK

² Department of Cellular & Molecular Medicine, School of Medical Sciences, University of Bristol, Bristol BS8 1TD, UK

³ Richard Bright Kidney Unit, Southmead Hospital, Westbury-on-Trym, Bristol BS10 5NB, UK

⁴ Department of Radiology, Bristol Royal Infirmary, Marlborough Street, Bristol BS2 8HW, UK

Received 22 August 2006; Accepted 7 March 2007

Recommended by Penella Woll

Purpose. Ifosfamide is a drug commonly used in the management of sarcomas and other solid tumours. One potential toxicity of its use is renal tubular damage, which can lead to skeletal abnormalities; rickets in children and osteomalacia in adults. We aimed to characterise this rare complication in adults. **Patients.** Three illustrative patient cases treated in our institution are presented. All were treated for sarcoma, and received varying doses of ifosfamide during their therapy. **Methods.** We performed a review of the literature on the renal tubular and skeletal complications of ifosfamide in adults. Papers were identified by searches of PubMed using the terms “osteomalacia,” “nephrotoxicity,” “Fanconi syndrome,” “ifosfamide,” and “chemotherapy” for articles published between 1970 and 2006. Additional papers were identified from review of references of relevant articles. **Results.** There are only four case reports of skeletal toxicity secondary to ifosfamide in adults; the majority of data refer to children. Risk factors for development of renal tubular dysfunction and osteodystrophy include platinum chemotherapy, increasing cumulative ifosfamide dose, and reduced nephron mass. The natural history of ifosfamide-induced renal damage is variable, dysfunction may not become apparent until some months after treatment, and may improve or worsen with time. **Discussion.** Ifosfamide-induced osteomalacia is seldom described in adults. Clinicians should be vigilant for its development, as timely intervention may minimise complications.

Copyright © 2007 D. N. Church et al. This is an open access article distributed under the Creative Commons Attribution License, which permits unrestricted use, distribution, and reproduction in any medium, provided the original work is properly cited.

1. INTRODUCTION

Ifosfamide is an alkylating oxazaphosphorine active against a number of malignancies including bone and soft tissue sarcomas as a single agent [1, 2] or in combination [3]. The development of mesna in 1979 largely ameliorated haemorrhagic cystitis as a complication of its use [4, 5] and the principal associated toxicities became myelosuppression, neurotoxicity, and nephrotoxicity; including glomerular, proximal, and distal tubular dysfunction [6, 7]. If severe, proximal tubular dysfunction may lead to Fanconi syndrome; characterised by glycosuria, aminoaciduria, and excess urinary excretion of phosphate, calcium, bicarbonate, potassium, sodium, and magnesium [8]. Left untreated, hypophosphatemia results in skeletal abnormalities: rickets in children and osteomalacia in adults [8]. While the renal and skeletal consequences of ifosfamide have been well described in the paediatric population [6, 7], there is limited information on such effects in adults.

Here, we report three adult patients in whom osteomalacia as a late consequence of ifosfamide-induced renal tubular dysfunction mimicked skeletal metastases. These cases were diagnosed over a three-year period at a regional cancer centre in which approximately 30–40 patients per year receive ifosfamide-based chemotherapy for sarcoma. In each case osteomalacia was diagnosed on the basis of radiological findings in combination with serum biochemical abnormalities. We define Fanconi syndrome as an acquired renal tubular defect resulting in excess loss of glucose, bicarbonate, amino acids, uric acid, and phosphate. All patients described gave informed consent for publication.

2. METHODS

Literature review was performed by searches of PubMed using the terms “osteomalacia,” “nephrotoxicity,” “Fanconi syndrome,” “ifosfamide,” and “chemotherapy” for articles

published between 1970 and 2006. Additional papers were identified from the references of relevant articles.

3. PATIENTS

3.1. Case 1

A 25-year-old man was referred to our institution with an undifferentiated high-grade soft tissue sarcoma of the right thigh in March 1998. He had no history of renal disease and serum electrolytes and creatinine $91 \mu\text{mol/L}$ were normal at presentation. He received neoadjuvant chemotherapy as described in Table 1 (Case 1, Regimen 1), without complication and with normal serum biochemistry throughout. The tumour responded to treatment and the patient proceeded to radiotherapy (kidneys not included in treatment field) and surgery.

In January 2000, lung metastases were detected in follow-up imaging and subsequently resected. No further systemic therapy was given. However, in August 2000 unresectable disease progression necessitated palliative chemotherapy (Table 1, Regimen 2). Biochemistry remained within normal range during treatment, and a partial response with effective palliation was achieved.

In June 2001, the patient developed further symptomatic progression of disease. Serum creatinine measured $123 \mu\text{mol/L}$, corresponding to a calculated glomerular filtration rate (GFR) of 80ml/min according to the method of Cockcroft and Gault [9]. Further chemotherapy was given (Table 1), but discontinued after 4 cycles due to lack of response. In view of the limited treatment options available and their previous efficacy, single-agent ifosfamide was used (Table 1). The patient required hospitalization after the first cycle for management of febrile neutropenia with antibiotics including gentamicin (4 doses at 4 mg/kg daily dose). During this admission transient hypokalemia (nadir 2.6 mmol/L) and elevation of serum creatinine (maximum $134 \mu\text{mol/L}$) were observed. Both normalised with supplementation and rehydration and remained within normal range during subsequent courses. Treatment resulted in significant tumour regression and effective palliation.

In April 2002, five months after cessation of ifosfamide treatment, concomitant with further progression of pulmonary disease, the patient complained of bilateral ankle pain following a snowboarding holiday. Isotope bone scan demonstrated increased uptake at sites of symptoms and serum alkaline phosphatase measured 266 IU/L . Though the possibility of skeletal metastases was considered, careful review of plain radiographs revealed insufficiency fractures of both ankles, confirmed on magnetic resonance (MR) scan (Figure 1). Biochemistry confirmed the characteristic hypokalaemia and hypophosphataemia (0.8 mmol/L) of renal Fanconi syndrome. There was no urinary sediment and serum whole parathyroid hormone (PTH) was normal. Oral alfacalcidol and potassium supplementation were prescribed.

Unfortunately, over the following months a steady decline in glomerular function developed with haemodialysis initiated in February 2003. During this period, continued disease progression occurred and despite treatment with two

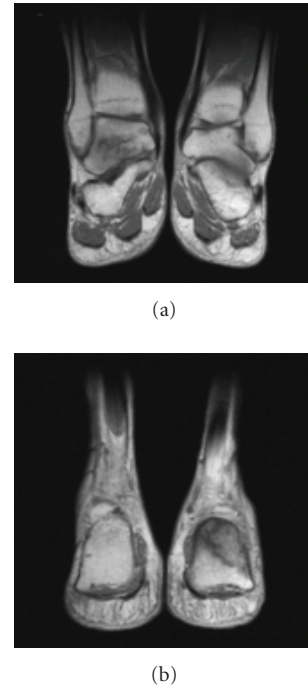


FIGURE 1: Case 1: T1-weighted magnetic resonance (MR) demonstrating stress fractures of (a) right talus and (b) left calcaneum.

nonnephrotoxic regimens (etoposide and gemcitabine) the patient died from disseminated malignancy in August 2003.

3.2. Case 2

A 33-year-old woman with Ewing's sarcoma of the left tibia was referred for management in May 2002. She had no history of renal disease, and serum creatinine at presentation measured $98 \mu\text{mol/L}$. Initial isotope bone scan is shown in Figure 2(a).

Neoadjuvant chemotherapy was administered, using the VIDE regimen [10] (Table 1). After the fifth cycle, the patient was hospitalised for management of febrile neutropenia, including 6 doses of gentamicin at 4 mg/kg daily dose (levels within normal range throughout). During this admission transient hypokalemia (nadir 3.1 mmol/L) and modest elevation of serum creatinine $115 \mu\text{mol/L}$ occurred, though both normalised with supplementation and rehydration. In view of this toxicity, the sixth cycle was prescribed at reduced dose, but further hypokalaemia (nadir 2.7 mmol/L) necessitated transient oral supplementation. After completion of chemotherapy, the patient underwent tumour excision with a free fibula graft.

Following surgery, adjuvant therapy was commenced in December 2002 as per standard practice in our institution. One cycle of VAI [10] (Table 1) was given, but complicated by febrile neutropenia requiring hospitalization for treatment including 3 doses of gentamicin at 4 mg/kg . During this admission an asymptomatic rise in creatinine to $167 \mu\text{mol/L}$

TABLE 1: Chemotherapeutic regimens used in cases. *Cis*: cisplatin, *dox*: doxorubicin, *ifos*: ifosfamide, *epi*: epirubicin, *vinb*: vinblastine, *dac*: dacarbazine, *vinc*: vincristine, *etop*: etoposide, *act*: actinomycin D, *cyclo*: cyclophosphamide. Note that *cisplatin* was administered with pre- and posthydration and ifosfamide was demonstrated as an infusion with concurrent mesna in all regimens.

	Regimen 1	Regimen 2	Regimen 3	Regimen 4	Total ifos dose
Case 1	Apr–Jul 1998	Aug–Nov 2000	Jun–Aug 2001	Oct–Nov 2001	
	<i>Cis</i> 100 mg/m ² , d1 <i>Dox</i> 25 mg/m ² , d1–3 <i>Alternating with</i> <i>Ifos</i> 5 g/m ² , d1 <i>Dox</i> 25 mg/m ² , d1–3 <i>5 cycles total</i>	<i>Ifos</i> 3.33 g/m ² , d1–4 <i>5 cycles (#1 at reduced dose)</i>	<i>Epi</i> 90 mg/m ² , d1 <i>Cis</i> 75 mg/m ² , d1 <i>Alternating with</i> <i>Vinb</i> 5 mg/m ² , d1 <i>Cis</i> 75 mg/m ² , d1 <i>Dac</i> 800 mg/m ² , d1 <i>4 cycles total</i>	<i>Ifos</i> 3.33 g/m ² , d1–4 <i>3 cycles</i>	
	Total ifos	10 g/m ²	60 g/m ²	40 g/m ²	110 g/m ²
Case 2	Jun–Oct 2002	Dec 2002–Feb 2003			
	<i>Vinc</i> 1.4 mg/m ² , d1 <i>Ifos</i> 3 g/m ² , d1–3 <i>Dox</i> 20 mg/m ² , d1–3 <i>Etop</i> 150 mg/m ² , d1–3 ¹⁰ <i>6 cycles (#6 at 65% dose)</i>	<i>Vinc</i> 1 mg/m ² , d1 <i>Act</i> 0.75 mg/m ² , d1, 2 <i>Ifos</i> 3 g/m ² d1, 2 <i>3 cycles, cyclo-substituted for ifos after #1</i>	—	—	
	Total ifos	51 g/m ²	6 g/m ²	—	57 g/m ²
Case 3	Jun–Sept 2004				
	<i>VIDE</i> (as above) ¹⁰ <i>4 cycles (reduced dose ifos from #3)</i>	—	—	—	
	Total ifos	24 g/m ²	—	—	24 g/m ²

occurred. Cyclophosphamide was therefore substituted for ifosfamide for subsequent courses, which were well tolerated with biochemistry remaining within normal range throughout.

Six months after completion of therapy and 10 months after surgery, the patient still complained of significant pain at the operation site. Plain radiographs demonstrated nonunion of the fibula graft but also areas of lucency in the proximal and distal tibia are demonstrated. Isotope bone scan added to suspicion of metastases, with several areas of increased uptake evident (Figure 2(b)). MR performed to further delineate the abnormality revealed a stress fracture within the fibula graft, and biopsies confirmed healing tissue only with no evidence of malignancy. Serum biochemistry demonstrated hypokalaemia and elevated alkaline phosphatase, confirming the diagnosis of osteomalacia secondary to Fanconi syndrome. No urinary sediment was identified, serum whole PTH was normal throughout. Oral alfacalcidol supplementation was commenced.

As of May 2006, the patient is clinically well under joint oncology and nephrology followup with no evidence of recurrent malignancy. She continues to require vitamin D supplementation and serum creatinine remains elevated, but stable at 133 μ mol/L.

3.3. Case 3

A 31-year-old man was referred in May 2004 for further management of a peripheral neuroectodermal tumour of the left kidney, having undergone left nephrectomy the preced-

ing month. He had no history of renal disease and serum creatinine at presentation measured 81 μ mol/L.

Staging investigations demonstrated no evidence of metastases and he therefore received adjuvant therapy using the *VIDE* regimen [10] (Table 1). Following the second cycle of treatment, the patient required hospitalization for management of nausea and vomiting. Significant biochemical derangement was noted on admission; serum creatinine measured 224 μ mol/L; urea 11.1 mmol/L; potassium 2.9 mmol/L; phosphate <0.3 mmol/L, and corrected calcium 2.06 mmol/L. Electrolytes normalised with supplementation and serum creatinine fell to 129 μ mol/L prior to cycle 3, for which a reduced dose of ifosfamide was used. Despite this, the patient again required hospital admission for management of febrile neutropenia after the two subsequent cycles, on both occasions treated without aminoglycosides. Although serum potassium remained within normal range during this period without supplementation, following the fourth and final cycle marked hypophosphatemia (nadir <0.3 mmol/L) and elevation of serum creatinine 162 μ mol/L were noted. Treatment was completed in September 2004.

During initial followup serum creatinine remained elevated but stable at 143–157 μ mol/L and the patient was able to discontinue all electrolyte supplementations. However in November 2004 a progressive decline in glomerular function became evident, with increase in creatinine to 300 μ mol/L. To exclude obstructive uropathy secondary to retroperitoneal tumour recurrence as cause of this, a CT of the abdomen and pelvis was performed. While this demonstrated no evidence of outflow obstruction, it revealed a number of abnormal

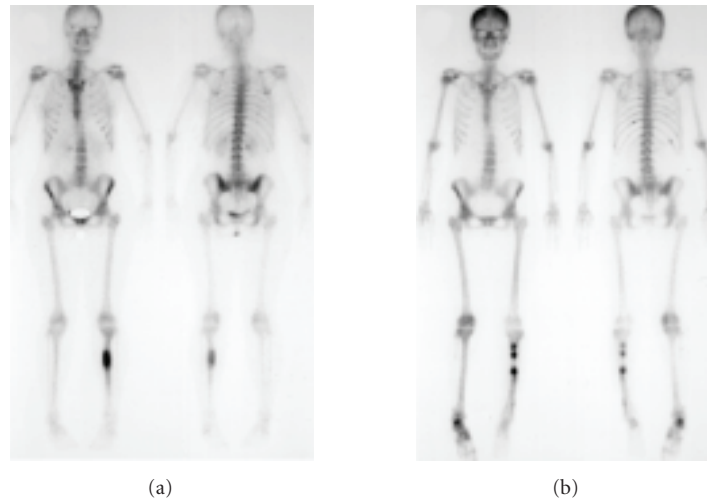


FIGURE 2: Case 2: isotope bone scans, (a) at diagnosis, demonstrating increased uptake at site of primary tumor in left tibia, (b) after ifosfamide therapy and surgery, demonstrating continued increased uptake at site of primary tumor and new abnormality in region of right ankle.

areas throughout the skeleton. A bone scan to further assess these showed increased uptake in the region of the left ankle. Further biochemical analysis confirmed elevated alkaline phosphatase, hypocalcaemia, and hypophosphataemia; consistent with osteomalacia secondary to Fanconi syndrome. Whole PTH was normal with no urinary sediment. Oral alfacalcidol supplementation was commenced.

Unfortunately, glomerular function continued to decline over subsequent months, renal biopsy revealed marked interstitial fibrosis, with dialysis initiated in August 2005. At time of this report (May 2006), the patient is free from recurrence, under joint oncology and nephrology followup.

4. DISCUSSION

The three cases presented illustrate the potential for the delayed development of osteomalacia secondary to ifosfamide-induced Fanconi syndrome in adult patients. Cumulative drug doses were variable; 110 g/m², 57 g/m², and 24 g/m² in Cases 1, 2, and 3, respectively. In addition to tubular dysfunction, each patient has shown evidence of associated deranged glomerular filtration, with two patients requiring dialysis.

Ifosfamide is associated with a variety of renal toxicities (see Skinner [6, 7] for comprehensive reviews) including glomerular dysfunction leading to fall in glomerular filtration rate (GFR) [11–15], distal tubular damage leading to poor urinary concentrating ability [16, 17], and more commonly, proximal tubular dysfunction [7, 13, 15] thought to be caused by chloroacetaldehyde [18–20], a metabolite of ifosfamide toxic to human proximal tubular cells [21]. Although mesna is theoretically capable of detoxifying chloroacetaldehyde, its efficacy may be incomplete [22] and its rapid tubular excretion may further impair any protective action at this site.

The incidence of proximal tubular dysfunction in children treated with ifosfamide varies according to the criteria used for assessment. While subclinical glycosuria was detected in 88% of patients in a large study [14], clinically significant abnormalities including Fanconi syndrome occur in between 1.3 and 27% of treated patients [11, 17, 23, 24]. Risk is increased by prior or concurrent platinum chemotherapy [11, 13, 15, 25, 26], increasing cumulative ifosfamide dose [12–14, 17, 25, 27], and reduced functioning nephron mass [13, 23, 25, 28], but not scheduling of ifosfamide dose [29, 30]. Whether aminoglycoside use increases risk is unclear [14, 31] although aminoglycosides per se may cause Fanconi syndrome [32].

It is important to note that whilst tubular damage secondary to ifosfamide may become apparent during therapy, it can develop months or even years after cessation of treatment [33, 34] as in these cases. The subsequent natural history is equally unpredictable; though damage may resolve with time [6, 33], with spontaneous resolution of secondary rickets [35], there may be no improvement in tubular function [34] and an associated progressive decline in GFR can occur [23, 36]. End-stage renal failure in adults secondary to ifosfamide has previously been documented in three patients after cumulative ifosfamide doses of 56 g/m², 80 g/m² and 33 g/m² [15]. All of these patients had been pretreated with cisplatin, whereas only one of the cases we report had previously received this agent.

Hypophosphatemic rickets occurs in 5–18% [17, 23, 24] of children treated with ifosfamide and may be the first manifestation of the underlying renal abnormalities [23, 24]. There are only four published cases of adults with Fanconi syndrome and renal osteomalacia secondary to ifosfamide [37–40]. In three of these, patients have displayed associated symptoms of significant renal dysfunction such as polyuria and polydipsia. By contrast, our patients were clinically well

at the time of diagnosis of stress fractures, leading to the suspicion of bone metastases.

Our experience highlights the fact that tubular and skeletal complications of ifosfamide are not restricted exclusively to a high-risk paediatric population. Indeed our second case occurred in a patient without any risk factors receiving standard drug doses. These findings clearly have implications for patient monitoring during and after ifosfamide chemotherapy. Whilst a comprehensive assessment of kidney function as described in the paediatric literature [41] may not be appropriate for all adult patients, assessment of GFR by ⁵¹Cr-EDTA clearance [42] and tubular function by serum and urine electrolyte measurements (including calculation of the renal tubular threshold for phosphate) [41] is straightforward and may help prevent the complications we describe. Unfortunately, the paucity of data on this subject in adults means that when faced with subtle changes in tubular function, clinicians may not have the evidence available upon which to base decisions as how to adjust ifosfamide doses.

These cases demonstrate the need for clinicians to be vigilant for signs of renal tubular dysfunction in patients receiving ifosfamide, particularly if cisplatin is pretreated, as timely intervention may prevent skeletal complications of this drug. They also illustrate the point that when faced with a patient in the clinic with bone pain and abnormal isotope bone scan after ifosfamide treatment, oncologists should be mindful that the cause may in fact be insufficiency fractures secondary to osteomalacia rather than metastatic disease, and further skeletal imaging may be required to differentiate between the two. This clinical caveat may be of increasing relevance, as a recent study has documented hypophosphataemia and abnormal bone metabolism in patients treated with the tyrosine kinase inhibitor imatinib, likely through inhibition of the platelet-derived growth factor (PDGF) receptor [43].

REFERENCES

- [1] V. H. C. Bramwell, H. T. Mouridsen, A. Santoro, et al., "Cyclophosphamide versus ifosfamide: final report of a randomized phase II trial in adult soft tissue sarcomas," *European Journal of Cancer and Clinical Oncology*, vol. 23, no. 3, pp. 311–321, 1987.
- [2] K. H. Antman, L. Ryan, A. Elias, D. Sherman, and H. E. Grier, "Response to ifosfamide and mesna: 124 previously treated patients with metastatic or unresectable sarcoma," *Journal of Clinical Oncology*, vol. 7, no. 1, pp. 126–131, 1989.
- [3] S. R. Patel, S. Vadhan-Raj, M. A. Burgess, et al., "Results of two consecutive trials of dose-intensive chemotherapy with doxorubicin and ifosfamide in patients with sarcomas," *American Journal of Clinical Oncology*, vol. 21, no. 3, pp. 317–321, 1998.
- [4] P. Bruhl, H. Hoefler-Janker, W. Scheef, and W. Vahlensieck, "Prophylactic alkalization of the urine during cytostatic tumor treatment with the oxazaphosphorine derivatives, cyclophosphamide and ifosfamide," *Onkologie*, vol. 2, no. 3, pp. 120–124, 1979.
- [5] W. Scheef, H. O. Klein, N. Brock, et al., "Controlled clinical studies with an antidote against the urotoxicity of oxazaphosphorines: preliminary results," *Cancer Treatment Reports*, vol. 63, no. 3, pp. 501–505, 1979.
- [6] R. Skinner, "Chronic ifosfamide nephrotoxicity in children," *Medical and Pediatric Oncology*, vol. 41, no. 3, pp. 190–197, 2003.
- [7] R. Skinner, I. M. Sharkey, A. D. J. Pearson, and A. W. Craft, "Ifosfamide, mesna, and nephrotoxicity in children," *Journal of Clinical Oncology*, vol. 11, no. 1, pp. 173–190, 1993.
- [8] J. W. Foreman and K. S. Roth, "Human renal Fanconi syndrome—then and now," *Nephron*, vol. 51, no. 3, pp. 301–306, 1989.
- [9] D. W. Cockcroft and M. H. Gault, "Prediction of creatinine clearance from serum creatinine," *Nephron*, vol. 16, no. 1, pp. 31–41, 1976.
- [10] S. J. Strauss, A. McTiernan, D. Driver, et al., "Single center experience of a new intensive induction therapy for ewing's family of tumors: feasibility, toxicity, and stem cell mobilization properties," *Journal of Clinical Oncology*, vol. 21, no. 15, pp. 2974–2981, 2003.
- [11] C. B. Pratt, W. H. Meyer, J. J. Jenkins, et al., "Ifosfamide, Fanconi's syndrome, and rickets," *Journal of Clinical Oncology*, vol. 9, no. 8, pp. 1495–1499, 1991.
- [12] M. S. Ashraf, J. Brady, F. Breatnach, P. F. Deasy, and A. O'Meara, "Ifosfamide nephrotoxicity in paediatric cancer patients," *European Journal of Pediatrics*, vol. 153, no. 2, pp. 90–94, 1994.
- [13] R. Rossi, A. Godde, A. Kleinebrand, et al., "Unilateral nephrectomy and cisplatin as risk factors of ifosfamide-induced nephrotoxicity: analysis of 120 patients," *Journal of Clinical Oncology*, vol. 12, no. 1, pp. 159–165, 1994.
- [14] R. Skinner, S. J. Cotterill, and M. C. G. Stevens, "Risk factors for nephrotoxicity after ifosfamide treatment in children: a UKCCSG Late Effects Group study. United Kingdom Children's Cancer Study Group," *British Journal of Cancer*, vol. 82, no. 10, pp. 1636–1645, 2000.
- [15] F. Marinez, G. Deray, P. Cacob, H. Beaufile, and C. Jacobs, "Ifosfamide nephrotoxicity: deleterious effect of previous cisplatin administration," *The Lancet*, vol. 348, no. 9034, pp. 1100–1101, 1996.
- [16] R. Rossi, A. Godde, A. Kleinebrand, B. Rath, and H. Jurgens, "Concentrating capacity in ifosfamide-induced severe renal dysfunction," *Renal Failure*, vol. 17, no. 5, pp. 551–557, 1995.
- [17] R. Skinner, A. D. J. Pearson, M. W. English, et al., "Risk factors for ifosfamide nephrotoxicity in children," *The Lancet*, vol. 348, no. 9027, pp. 578–580, 1996.
- [18] M. J. Zamlauski-Tucker, M. E. Morris, and J. E. Springate, "Ifosfamide metabolite chloroacetaldehyde causes Fanconi syndrome in the perfused rat kidney," *Toxicology and Applied Pharmacology*, vol. 129, no. 1, pp. 170–175, 1994.
- [19] M. Mohrmann, S. Ansorge, U. Schmich, B. Schonfeld, and M. Brandis, "Toxicity of ifosfamide, cyclophosphamide and their metabolites in renal tubular cells in culture," *Pediatric Nephrology*, vol. 8, no. 2, pp. 157–163, 1994.
- [20] J. E. Springate, "Ifosfamide metabolite chloroacetaldehyde causes renal dysfunction in vivo," *Journal of Applied Toxicology*, vol. 17, no. 1, pp. 75–79, 1997.
- [21] L. Dubourg, C. Michoudet, P. Cochat, and G. Baverel, "Human kidney tubules detoxify chloroacetaldehyde, a presumed nephrotoxic metabolite of ifosfamide," *Journal of the American Society of Nephrology*, vol. 12, no. 8, pp. 1615–1623, 2001.
- [22] M. Mohrmann, S. Ansorge, B. Schonfeld, and M. Brandis, "Dithio-bis-mercaptoethanesulphonate (DIMESNA) does not prevent cellular damage by metabolites of ifosfamide and cyclophosphamide in LLC-PK₁ cells," *Pediatric Nephrology*, vol. 8, no. 4, pp. 458–465, 1994.

- [23] C. D. Burk, I. Restaino, B. S. Kaplan, and A. T. Meadows, "Ifosfamide-induced renal tubular dysfunction and rickets in children with Wilms tumor," *Journal of Pediatrics*, vol. 117, no. 2 part 1, pp. 331–335, 1990.
- [24] A. Suarez, H. McDowell, P. Niaudet, E. Comoy, and F. Flamant, "Long-term follow-up of ifosfamide renal toxicity in children treated for malignant mesenchymal tumors: an International Society of Pediatric Oncology report," *Journal of Clinical Oncology*, vol. 9, no. 12, pp. 2177–2182, 1991.
- [25] R. Loebstein and G. Koren, "Ifosfamide-induced nephrotoxicity in children: critical review of predictive risk factors," *Pediatrics*, vol. 101, no. 6, p. E8, 1998.
- [26] N. M. Marina, C. A. Poquette, A. M. Cain, D. Jones, C. B. Pratt, and W. H. Meyer, "Comparative renal tubular toxicity of chemotherapy regimens including ifosfamide in patients with newly diagnosed sarcomas," *Journal of Pediatric Hematology/Oncology*, vol. 22, no. 2, pp. 112–118, 2000.
- [27] R. Skinner, A. D. J. Pearson, L. Price, M. G. Coulthard, and A. W. Craft, "Nephrotoxicity after ifosfamide," *Archives of Disease in Childhood*, vol. 65, no. 7, pp. 732–738, 1990.
- [28] R. Rossi, A. Kleinbrand, A. Godde, B. Rath, and H. Jurgens, "Increased risk of ifosfamide-induced renal Fanconi's syndrome after unilateral nephrectomy," *The Lancet*, vol. 341, no. 8847, p. 755, 1993.
- [29] A. V. Boddy, M. English, A. D. J. Pearson, J. R. Idle, and R. Skinner, "Ifosfamide nephrotoxicity: limited influence of metabolism and mode of administration during repeated therapy in paediatrics," *European Journal of Cancer—Part A*, vol. 32, no. 7, pp. 1179–1184, 1996.
- [30] R. Rossi, P. Schafers, J. Pleyer, C. Postler, J. Boos, and H. Jurgens, "The influence of short versus continuous ifosfamide infusion on the development of renal tubular impairment," *International Journal of Pediatric Hematology/Oncology*, vol. 4, no. 4, pp. 393–399, 1997.
- [31] R. M. Rossi, C. Kist, U. Wurster, W.-R. Kulpmann, and J. H. H. Ehrich, "Estimation of ifosfamide/cisplatin-induced renal toxicity by urinary protein analysis," *Pediatric Nephrology*, vol. 8, no. 2, pp. 151–156, 1994.
- [32] J. Z. Melnick, M. Baum, and J. R. Thompson, "Aminoglycoside-induced Fanconi's syndrome," *American Journal of Kidney Diseases*, vol. 23, no. 1, pp. 118–122, 1994.
- [33] H. N. Caron, N. Abeling, A. van Gennip, J. de Kraker, and P. A. Voucte, "Hyperaminoaciduria identifies patients at risk of developing renal tubular toxicity associated with ifosfamide and platinating regimens," *Medical and Pediatric Oncology*, vol. 20, no. 1, pp. 42–47, 1992.
- [34] R. Rossi, "Nephrotoxicity of ifosfamide—moving towards understanding the molecular mechanisms," *Nephrology Dialysis Transplantation*, vol. 12, no. 6, pp. 1091–1092, 1997.
- [35] S. van Gool, P. Brock, G. Wijndaele, et al., "Reversible hypophosphatemic rickets following ifosfamide treatment," *Medical and Pediatric Oncology*, vol. 20, no. 3, pp. 254–257, 1992.
- [36] V. K. Prasad, I. J. Lewis, S. R. Aparicio, et al., "Progressive glomerular toxicity of ifosfamide in children," *Medical and Pediatric Oncology*, vol. 27, no. 3, pp. 149–155, 1996.
- [37] A. A. Garcia, "Ifosfamide-induced Fanconi syndrome," *Annals of Pharmacotherapy*, vol. 29, no. 6, pp. 590–591, 1995.
- [38] A. Negro, G. Regolisti, F. Perazzoli, S. Davoli, C. Sani, and E. Rossi, "Ifosfamide-induced renal Fanconi syndrome with associated nephrogenic diabetes insipidus in an adult patient," *Nephrology Dialysis Transplantation*, vol. 13, no. 6, pp. 1547–1549, 1998.
- [39] C. Beckwith, K. K. Flaharty, A. K. Cheung, and P. G. Beatty, "Fanconi's syndrome due to ifosfamide," *Bone Marrow Transplantation*, vol. 11, no. 1, pp. 71–73, 1993.
- [40] L. Duck, J.-P. Devogelaer, A. Persu, et al., "Osteomalacia due to chemotherapy-induced Fanconi syndrome in an adult patient," *Gynecologic Oncology*, vol. 98, no. 2, pp. 329–331, 2005.
- [41] R. Skinner, A. D. J. Pearson, M. G. Coulthard, et al., "Assessment of chemotherapy-associated nephrotoxicity in children with cancer," *Cancer Chemotherapy and Pharmacology*, vol. 28, no. 2, pp. 81–92, 1991.
- [42] M. Rehling, M. L. Moller, B. Thamdrup, et al., "Simultaneous measurement of renal clearance and plasma clearance of ^{99m}Tc-labelled diethylenetriaminepenta-acetate, ⁵¹Cr-labelled ethylenediaminetetra-acetate and inulin in man," *Clinical Science*, vol. 66, no. 5, pp. 613–619, 1984.
- [43] E. Berman, M. Nicolaides, R. G. Maki, et al., "Altered bone and mineral metabolism in patients receiving imatinib mesylate," *New England Journal of Medicine*, vol. 354, no. 19, pp. 2006–2013, 2006.