

The correlation between acromial osteolysis and acromion types in the treatment of acromioclavicular joint dislocation with hook plate

Bedrettin Akar, MD^{a,*} 

Abstract

This study aimed to radiologically evaluate the effect of hook plates used in the treatment of acromioclavicular joint (ACJ) dislocations on the development of subacromial osteolysis (SAO) according to acromion types. A total of 43 patients with mean age of 38.5 (19–77) years who were diagnosed with AC dislocation and applied neutral clavicular hook plate between 2013 and 2020 were retrospectively evaluated. Acromion types were determined by measuring acromion slope angle on lateral shoulder radiography and 3-dimensional (D)-CT of the patients. Presence of SAO was classified according to the severity of erosion in the subacromial region (grade I: minimal osteolysis, grade II: subacromial erosion <2 mm, grade III: subacromial erosion >2 mm, grade IV: cut-through of the acromion) on postoperative 3D - CT and correlation with acromion types was analyzed. Incidence of SAO was significantly higher among type 1 acromion compared to type 2 and type 3 acromion ($P = .003$). While osteolysis was observed in 21 patients, no osteolysis was observed in 22 patients. Osteolysis occurred in all patients with type 1 acromion, 7 patients with type 2 acromion, and 5 patients with type 3 acromion. Since the hook tip in the sagittal plane passes posterior to the center of the acromion and the concavity of the subacromial surface is inadequate in the type 1 acromion, we believe that the increased pressure applied by the hook tip on the subacromial cartilage increases the risk of SAO. We predict that the use of hook plates with an angle of 15–20 degrees, similar to the patient's AC angle, rather than neutral hook plate, will reduce the risk of osteolysis in patients with type 1 acromion.

Abbreviations: AC = acromioclavicular, ACJ = acromioclavicular joint, D = dimensional, SAO = subacromial osteolysis.

Keywords: acromioclavicular joint, acromion, injuries, joint dislocation, osteolysis, surgical hook

1. Introduction

Acromioclavicular joint (ACJ) dislocation is a common trauma among athletes and constitutes 9% to 12% of all shoulder injuries.^[1–3] It usually occurs as a result of a direct fall on the shoulder while the arm is in adduction and presents with symptoms such as shoulder pain, functional limitation, and localized swelling.^[2,4,5] Factors such as sports injuries, traffic accidents, and falls play a role in its etiology.^[3,6,7] The Rockwood classification is currently used to both determine the type of dislocation and to guide treatment algorithms.^[4,8] Although many parameters are evaluated in this classification, the most important factor is the extent of the radiological increase in the coracoclavicular distance. The Rockwood classification consists of 6 categories (I–VI), and it has been stated in the literature that Type I and II injuries should be treated conservatively while Type IV to VI injuries should be treated surgically.^[2,5,7,9] There is no optimal treatment method for type III injuries; some surgeons recommend conservative and others surgical treatment. In our study, we preferred surgical treatment for type III injuries. Surgical fixation of an ACJ dislocation

is a complex procedure. AC hook plates are designed to fix the plate body to the distal clavicle with screws by placing the hook in the subacromial space just posterior to the ACJ. The hook acts as a lever in the ACJ to lower the clavicle to the acromion level and facilitates the healing of damaged ligaments.^[3,6,10] Although anatomical reduction is achieved with rigid fixation, these plates are known to have some complications such as subacromial osteolysis (SAO) and pain.^[3,6,9,11] In order to minimize acromial osteolysis, the pressure between the hook tip and the subacromial surface must be reduced and distributed. In order for the positioning of the hook plate to be safe, the structural relationship of the coronal plane between the distal clavicle and the acromion must be properly investigated. This coronal plane relationship is significant, especially in different acromial variations.^[7,12] Four acromion types are specified in the literature and they are classified as Type I—flat (12%), type II—curved (56%), type III—hooked (29%), and type IV—convex (3%).^[7,11,13,14]

In our study, hook plates used in ACJ dislocations; We aimed to demonstrate radiologically the correlation between the development of SAO with acromion types.

The authors have no funding and conflicts of interest to disclose.

All data generated or analyzed during this study are included in this published article [and its supplementary information files]

^a Sakarya Yenikent State Hospital, Department of Orthopedics and Traumatology, Sakarya, Turkey.

* Correspondence: Bedrettin Akar, Sakarya Yenikent State Hospital, Department of Orthopedics and Traumatology, Sakarya, Turkey (e-mail: drbedrettin@gmail.com).

Copyright © 2022 the Author(s). Published by Wolters Kluwer Health, Inc.

This is an open-access article distributed under the terms of the Creative Commons Attribution-Non Commercial License 4.0 (CCBY-NC), where it is permissible to download, share, remix, transform, and build up the work provided it is properly cited. The work cannot be used commercially without permission from the journal.

How to cite this article: Akar B. The correlation between acromial osteolysis and acromion types in the treatment of acromioclavicular joint dislocation with hook plate. *Medicine* 2022;101:43(e31632).

Received: 30 August 2022 / Received in final form: 11 October 2022 / Accepted: 12 October 2022

<http://dx.doi.org/10.1097/MD.00000000000031632>

2. Materials and methods

We included the patients with acute ACJ dislocations (Rockwood III–V) who were managed at our hospital from March 2013 to September 2020. Ethics committee approval was obtained from Sakarya University Faculty of Medicine on 16.04.2021 with document number E- 25261-258.

Patients with glenohumeral joint arthrosis, rheumatoid arthritis, ankylosing spondylitis, scapula fracture, clavicle fracture, and os acromiale were excluded from the study. One independent observer who was blinded with the treatment performed the clinical assessments. For radiological outcomes, we standardized the radiologic assessment with bilateral shoulder anteroposterior view images and 3D - CT. Acromion typing was performed by measuring the acromion slope angles of the patients' lateral shoulder x-rays and 3D - CT. The angle of the acromion slope was evaluated in the sagittal plane by measuring the angle between the anterior corner of the acromion and the line passing through its center and the line passing through the posterior of the acromion and extending to the center (Fig. 1). In the surgical technique, all patients were operated under general anesthesia in supine position. An approximately 8 cm incision was made 2 cm behind the distal end of the clavicle towards the distal clavicle. The distal clavicle, ACJ, and acromion were fully visualized. The hematoma and disc in the ACJ were cleared. The ACJ was reduced with a K wire and the hook plate was properly placed from the posterior of

the ACJ. After the plate was fixed to the clavicle with screws, the K-wire was removed and the joint capsule was repaired. The layers were closed anatomically and a Velpeau bandage was applied for 2 weeks. At the end of 2 weeks, rehabilitation was started with active and passive exercises. The patients were treated prophylactically with 1 gr cefazolin 3 × 1 antibiotics and enoxaparin 0.6 mL 1 × 1 treatment. The presence of SAO was investigated in patients who were evaluated with 3D - CT and 1-, 3-, and 6-months postoperatively. Presence and degree of SAO were visually evaluated on 3D - CT. SAO; classified according to the severity of erosion in the subacromial region by the grading of Chang et al.^[11] In this classification; grade I: minimal osteolysis, grade II: subacromial erosion <2 mm, grade III: subacromial erosion >2mm, grade IV: cut-through of the acromion.^[7,11] We analyzed the effects of different structural features of the acromion on the development of SAO in hook plate use by evaluating radiological AP radiographs of both shoulders and 3D - CT of shoulder.

2.1. Statistical analysis

Statistical analyzes were performed with the NCSS (Number Cruncher Statistical System) 2007 Statistical Software (Utah) package program. In addition to descriptive statistical methods (mean, standard deviation), distribution of the variables was assessed with Shapiro–Wilk normality test. One-way analysis of variance was used for intergroup comparisons of normally distributed variables, and Chi-square test was used for qualitative data. *P* < .05 was considered statistically significant (Table 1).

3. Results

Neutral clavicular hook plate was applied to 43 patients diagnosed with AC dislocation (Rockwood III–V). Our study consisted of 12 female and 31 male patients with a mean age of 38.5 (19–77) years and a mean follow-up period of 12 months (8–15). AC dislocations were observed in 21 right and 22 left shoulders of the 43 patients. According to the Rockwood classification, 24 patients were evaluated as class III, 3 patients as class IV, and 16 patients as class V. The average time from trauma to operation is 2.7 (1–6) days, and the average operation time is 38 (24–55) minutes. 9 patients were classified as type 1 straight, 21 patients as type 2 curved, and 13 patients as type 3 hooked. No type IV acromion was observed in our study. Statistical analysis revealed that the incidence of SAO

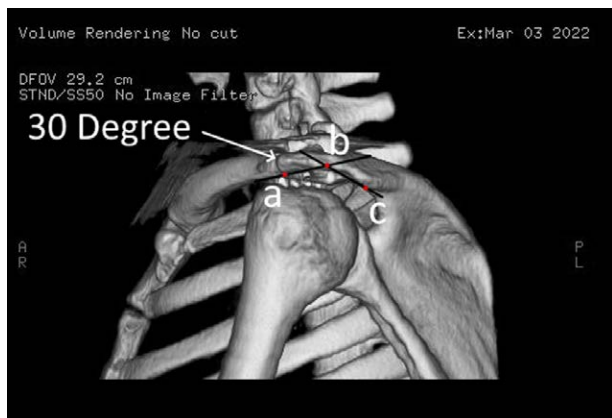


Figure 1. Acromial angle (a: acromion anterior corner, b: acromion center, c: acromion posterior corner).

Table 1

Statistical analysis.

		Acromion types			P	
		Type 1	Type 2	Type 3		
Age		35.33 ± 20.31			.623*	
Sex	Male	7	77.78%	15	71.43%	.904**
	Female	2	22.22%	6	28.57%	
Side	Right	5	55.56%	11	52.38%	.661**
	Left	4	44.44%	10	47.62%	
Rockwood Classification	Tip 3	7	77.78%	12	57.14%	.418**
	Tip 4	0	0.00%	2	9.52%	
	Tip 5	2	22.22%	7	33.33%	
Subacromial Osteolysis	No Osteolysis	0	0.00%	14	66.67%	.003**
	Grade I	1	11.11%	2	9.52%	
	Grade II	4	44.44%	4	19.05%	
	Grade III	4	44.44%	1	4.76%	

* One-way analysis of variance.

**Chi-square test.

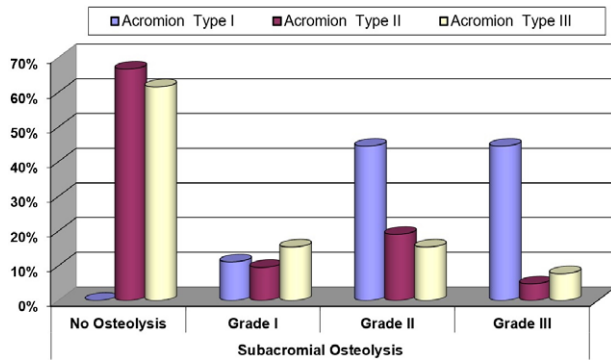


Figure 2. Distribution of subacromial osteolysis according to acromion types.

with the use of neutral hook plate was found to be significant in patients with Type 1 acromion compared to patients with type 2 and type 3 acromion. According to observational evaluation of the 6-month postoperative direct shoulder AP radiographs and 3D-CT of the patients, grade I osteolysis was present in 1 patient, grade II in 4 patients, and grade III in 4 patients with type 1 acromion. Osteolysis was observed in all patients with type 1 acromion. Grade I osteolysis was present in 2 patients, grade II in 4 patients, grade III in 1 patient, and no osteolysis in 14 patients with type 2 acromion. In patients with type 3 acromion, grade I osteolysis was present in 2 patients, grade II in 2 patients, grade III in 1 patient, and no osteolysis in 8 patients (Fig. 2). Of the 43 patients in our study, osteolysis was not observed in 22 (51.2%) patients, while different degrees of osteolysis was observed in 21 (48.8%) patients. Grade IV cut-through of the acromion was not observed in any patient. The plate was not removed in any of the patients, as no plate-related clinical or functional complications developed.

A statistically significant difference was observed between patients with type 1, type 2, and type 3 acromion types according to distribution of SAO ($P = .003$). Grade I and grade III SAO incidence was higher in patients with acromion type 1 compared to patients with type 2 and type 3 acromion. Grade II and grade III SAO incidence was significantly higher in patients with acromion type 1 compared to patients with acromion type 2 ($P = .003$) and acromion type 3 ($P = .015$). There was no significant difference between patients with type 2 and type 3 acromion in terms of distribution of SAO ($P = .930$).

4. Discussion

Treatment with hook plate is a frequently used method in AC dislocations. After the hook is placed in the subacromial region, the plate is fixed on the distal clavicle with screws, acting as a lever. In the lever mechanism, the plate is pushed down towards the distal clavicle, the distal end of the hook produces a constant upward pressure, providing rigid fixation of the AC joint and promotes healing of the damaged ligaments and joint capsule.^[1,3,9,10,12,15] While hook plates provide rigid fixation in the AC joint, they may cause SAO due to the pressure created by the hook in the subacromial region.^[6,7,13,16] In anatomical and morphological examinations, the axis of the tip of the hook in the placement traces of the axial plane of the clavicle and acromion forms the posterior of the acromion.^[2,3,17,18] In our study, it was seen on 3D-CT and radiographs that the hook tip was close to the posterior of the acromion center in sagittal and axial planes (Fig. 3). In addition, both acromion types and concavities were evaluated by measuring the acromial slope angles on lateral shoulder radiographs and 3D-CT. In the type 1 acromion, the acromial slope angle is low (0–10 degrees) and concavity is insufficient. In type 2 and type 3 acromion, slope angles range from 20 to 32 degrees and 35

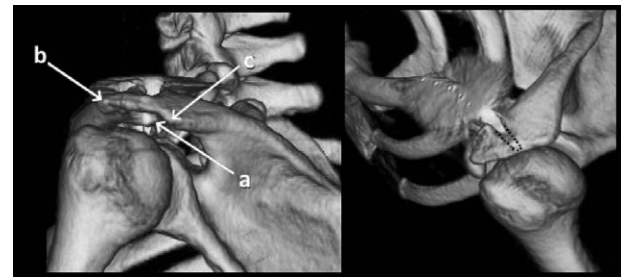


Figure 3. Hook plate sagittal and axial plane (a: hook tip, b: acromion anterior, c: acromion posterior).

to 45 degrees, respectively, and concavity is sufficient in both types. Insufficient concavity, especially in the posterior region of the type 1 acromion, causes excessive stress on the subacromial area of the hook tip, increasing the risk of osteolysis.^[16,19] El Maraghy et al emphasized that anatomical variations of the acromion cause significant changes in the positioning of the subacromial hook, which may increase postoperative complications such as osteolysis.^[6]

The incidence of osteolysis: Ying-Cheng-Huang et al; 37.5%, Chang-Hong Chen et al; 30.3%, Siwei Sun et al; 54.1%, Hao-Ming-Chang et al; 27.7%.^[7,10,11,13] In our study, the rate of osteolysis was 51.2%, and different degrees of osteolysis were detected in all patients with Type I acromion.

Guanghua Li et al stated that placement of the hook in the subacromial region causes increased friction and pressure in the acromion with shoulder movements, which increases the risk of osteolysis. They stated that instead of neutral hook plates, plates with a 15-degree hook angle may reduce subacromial friction and osteolysis.^[11] Peng-cheng-Shen et al stated that high degree of the distal clavicle-acromion angle and anatomical variations of the clavicle increase the risk of osteolysis.^[2] Sung-Jae-Kim et al reported that the incidence of osteolysis is quite high with the use of hook plates, and this problem can be prevented by bending the hook plates according to the individual acromioclavicular angle.^[4] Hao-Ming Chang et al anticipated that the use of hook plate and coracoclavicular suture fixation in AC dislocations would reduce the incidence of osteolysis compared to hook plate usage alone.^[11] According to our study, we observed that using 0-degree hook plates increased stress on the subacromial region and caused osteolysis, especially in patients with type 1 acromion lacking concavity. Therefore, we predict that the use of a 15° to 20° angled plate compatible with the patient's acromioclavicular angle instead of a 0° plate in the coronal plane would reduce the incidence of osteolysis in patients with type 1 acromion.

Joo et al used hook plates with an angle of 21 degrees, Li et al with an angle of 15 degrees, and Hyun et al with an angle of 10 degrees, and found that the risk of SAO was considerably less compared to hook plates without an angle.^[1,9,10] Sun et al stated that the incidence of SAO was common after hook plate application, but does not significantly affect shoulder functions, that most patients achieve a satisfactory functional prognosis, and plate removal is unnecessary unless there is a mandatory indication.^[7] Jafary et al emphasized that hook plates should be removed after 12 months, regardless of good scores and X-ray findings.^[16] In our study, plates were not removed from the patients, since osteolysis did not cause a clinical and functional condition that adversely affected prognosis.

Qiao et al reported that a personalized clavicle hook plate could not be manufactured due to individual differences in the shape of the acromion, since the region occupied by the hook in the subacromial space could not be measured, however, the incidence of osteolysis could be reduced by determining the acromion type before the operation and adjusting the hook

angle.^[20] In our study, the concavities of the acromion types were evaluated by measuring the slope angles, and it was determined that the incidence of osteolysis was higher in patients with type 1 acromion compared to other types due to inadequate concavity.

Our study had some limitations. The first limitation was the retrospective study design consisting of patients who were not randomized preoperatively. Secondly, the number of patients was insufficient to attain accurate results. The third was the difficulty of observationally evaluating SAO with direct radiographs and 3D-CT. The fourth limitation was the fact that acromial slope angles, which we used for determining concavity of acromion types, were not sensitive measurements. Furthermore, there may be a margin of error. In addition, the lack of studies in the literature regarding the use of hook plates according to acromion types had a negative impact on the evaluation of the results.

5. Conclusion

In regards to the treatment of AC dislocations with hook plate, we believe that the patient's acromion type should be determined with preoperative lateral shoulder radiography; since the hook tip passes posterior to the center of the acromion, the concavity of the subacromial surface is inadequate in the type 1 acromion, therefore the leverage effect of the hook plate tip and the increased pressure applied to the subacromial cartilage increases SAO. We predict that the use of hook plates with an angle of 15-20 degrees, similar to the patient's AC angle, rather than neutral hook plate, will minimize the risk of SAO in patients with type 1 acromion.

Author contributions

Conceptualization: Bedrettin Akar.

Data curation: Bedrettin Akar.

Investigation: Bedrettin Akar.

Methodology: Bedrettin Akar.

Project administration: Bedrettin Akar.

Software: Bedrettin Akar.

Supervision: Bedrettin Akar.

Writing – original draft: Bedrettin Akar.

Writing – review & editing: Bedrettin Akar.

References

- [1] Li G, Liu T, Shao X, et al. Fifteen-degree clavicular hook plate achieves better clinical outcomes in the treatment of acromioclavicular joint dislocation. *J Int Med Res.* 2018;46:4547–59.
- [2] Shen P, Zhu Y, Zhang H, et al. Three-dimensional morphological analysis of acromioclavicular joint in patients with and without subacromial erosion after hook plate fixation. *J Int Med Res.* 2017;46:511–21.
- [3] Karia M, Al-Hadithy N, Tytherleigh-Strong G. Recurrent acromioclavicular joint dislocation with an associated coracoid fracture following acromioclavicular joint reconstruction. *Ann R Coll Surg Engl.* 2020;102:e136–40.
- [4] Kim SJ, Kee YM, Park DH, et al. Evaluation of the acromioclavicular joint morphology for minimizing subacromial erosion after surgical fixation of the joint using a clavicular Hook plate. *Clin Shoulder Elb.* 2018;21:138–44.
- [5] Shen G, Sun S, Tang C, et al. Comparison of the TightRope system versus hook plate in acute acromioclavicular joint dislocations: a retrospective analysis. *Sci Rep.* 2021;11:11397.
- [6] El Maraghy AW, Devereaux MW, Ravichandiran K, et al. Subacromial morphometric assessment of the clavicle hook plate. *Injury.* 2010;41:613–9.
- [7] Sun S, Gan M, Sun H, et al. Does subacromial osteolysis affect shoulder function after clavicle Hook plating? *Biomed Res Int.* 2016;2016:4085305.
- [8] North AS, Wilkinson T. Surgical reconstruction of the acromioclavicular joint: can we identify the optimal approach? *Strateg Trauma Limb Reconstr.* 2018;13:69–74.
- [9] Oh JH, Min S, Jung JW, et al. Clinical and radiological results of Hook plate fixation in acute acromioclavicular joint dislocations and distal clavicle fractures. *Clin Shoulder Elb.* 2018;21:95–100.
- [10] Huang Y-C, Yang S-W, Chen C-Y, et al. Single coracoclavicular suture fixation with Mersilene tape versus hook plate in the treatment of acute type V acromioclavicular dislocation: a retrospective analysis. *J Orthop Surg Res.* 2018;13:110.
- [11] Chang H-M, Hong C-K, Su W-R, et al. Comparison of clavicular hook plate with and without coracoclavicular suture fixation for acute acromioclavicular joint dislocation. *Acta Orthop Traumatol Turc.* 2019;53:408–13.
- [12] Unal OK, Dagtas MZ. Comparison of the results of Hook plate and endo-button used in the surgical treatment of acromioclavicular joint separation. *Cureus.* 2020;12:e11987.
- [13] Chen C-H, Dong Q-R, Zhou R-K, et al. Effects of hook plate on shoulder function after treatment of acromioclavicular joint dislocation. *Int J Clin Exp Med.* 2014;7:2564–70.
- [14] Toivonen DA, Tuite MJ, Orwin JF. Acromial structure and tears of the rotator cuff. *J Shoulder Elbow Surg.* 1995;4:376–83.
- [15] Xu D, Shi Y, Luo P, et al. Influential factors of subacromial impingement syndrome after hook plate fixation for acromioclavicular joint dislocation: a retrospective study. *Medicine (Baltim).* 2021;100:e26333.
- [16] Jafary D, Keihan Shokouh H, Najd Mazhar F, et al. Clinical and radiological results of fixation of acromioclavicular joint dislocation by hook plates retained for more than five months. *Trauma Mon.* 2014;19:e13728.
- [17] Joo MS, Kwon HY, Kim JW. Clinical outcomes of bending versus non-bending of the plate hook in acromioclavicular joint dislocation. *Clin Shoulder Elb.* 2021;24:202–8.
- [18] Tamaoki MJ, Lenza M, Matsunaga FT, et al. Surgical versus conservative interventions for treating acromioclavicular dislocation of the shoulder in adults. *Cochrane Database Syst Rev.* 2019; doi:10.1002/14651858.cd007429.pub.
- [19] Jung K-H. Is bending the hook plate necessary in acromioclavicular joint dislocation? *Clin Shoulder Elb.* 2021;24:199–201.
- [20] Qiao R, Yang J, Zhang K, et al. To explore the reasonable selection of clavicular hook plate to reduce the occurrence of subacromial impingement syndrome after operation. *J Orthop Surg Res.* 2021;16:180.