



## Case Report

## Vagus nerve stimulation as a potential modulator of periictal psychotic episodes: A report of four cases



Montse Alemany<sup>a</sup>, Eva Real<sup>b</sup>, Núria Custal<sup>b</sup>, Jacint Sala-Padró<sup>c</sup>, Laura Rodríguez-Bel<sup>d</sup>, Gerard Plans<sup>e</sup>,  
Jaume Mora<sup>f</sup>, Mila Santurino<sup>c</sup>, Tim Vancamp<sup>g</sup>, Mercè Falip<sup>c,\*</sup>

<sup>a</sup> Neuro-Oncology Unit, Neurology Department, Hospital Universitari de Bellvitge, Hospitalet de Llobregat, Barcelona, Spain

<sup>b</sup> Epilepsy Unit, Psychiatry Department, Hospital Universitari de Bellvitge, Hospitalet de Llobregat, Barcelona, Spain

<sup>c</sup> Epilepsy Unit, Neurology Department, Hospital Universitari de Bellvitge, Hospitalet de Llobregat, Barcelona, Spain

<sup>d</sup> Institute of Image Diagnosis (IDI), PET Division, Hospital Universitari de Bellvitge, Hospitalet de Llobregat, Barcelona, Spain

<sup>e</sup> Epilepsy Unit, Neurosurgery Department, Hospital Universitari de Bellvitge, Hospitalet de Llobregat, Barcelona, Spain

<sup>f</sup> Institute of Image Diagnosis (IDI), SPECT division, Hospital Universitari de Bellvitge, Hospitalet de Llobregat, Barcelona, Spain

<sup>g</sup> e4Sci, Sabadell, Spain

## ARTICLE INFO

## Article history:

Received 31 October 2020

Revised 12 January 2021

Accepted 21 January 2021

Available online 11 February 2021

## Keywords:

Vagus nerve stimulation

Periictal psychotic episodes

Drug-resistant epilepsy

Psychosis

Positron emission tomography

## ABSTRACT

Drug resistant epilepsy (DRE) has been associated with a high incidence of psychotic disorders. Patients can develop psychosis after starting a new antiseizure medication, after undergoing resective surgery, or after implantation of a vagus nerve stimulation (VNS) system. The aim of this study was to investigate the modulation effect of VNS on psychotic episodes in DRE patients with a pre-existing history of periictal psychotic episodes (PPE).

We retrospectively report the outcome of four patients from a single tertiary center with PPE prior to implantation. None of the implanted patients developed *de novo* PPE after VNS therapy. Regarding seizure outcome, all patients demonstrated a response to VNS with two who experienced who status epilepticus and three patients with a change in semiology with after VNS implantation. PPE disappeared in all the study patients, two of them at 6 months post-implantation and in the others after 2 and 3 years, respectively. <sup>18</sup>F-FDG-PET results showed hypermetabolism in both anterior insular and medial frontal lobes which disappeared in the <sup>18</sup>F-FDG-PET 4 years post-implantation.

Based on the results of this series of cases we suggest that VNS therapy may be useful to modulate PPE in patients with DRE, though effectiveness may be time-dependent.

© 2021 The Author(s). Published by Elsevier Inc. This is an open access article under the CC BY-NC-ND license (<http://creativecommons.org/licenses/by-nc-nd/4.0/>).

## 1. Introduction

Psychiatric disorders affect patients with epilepsy more frequently than they do the general population. The reported prevalence of psychotic disturbances varies between 2% and 7%, with a pooled prevalence of 5.6% [1]. The variation becomes higher when compared to the general population (1%), especially in those with temporal lobe epilepsy (TLE), affecting nearly 20% of patients [2]. Psychosis may be seen based upon its temporal relationship with

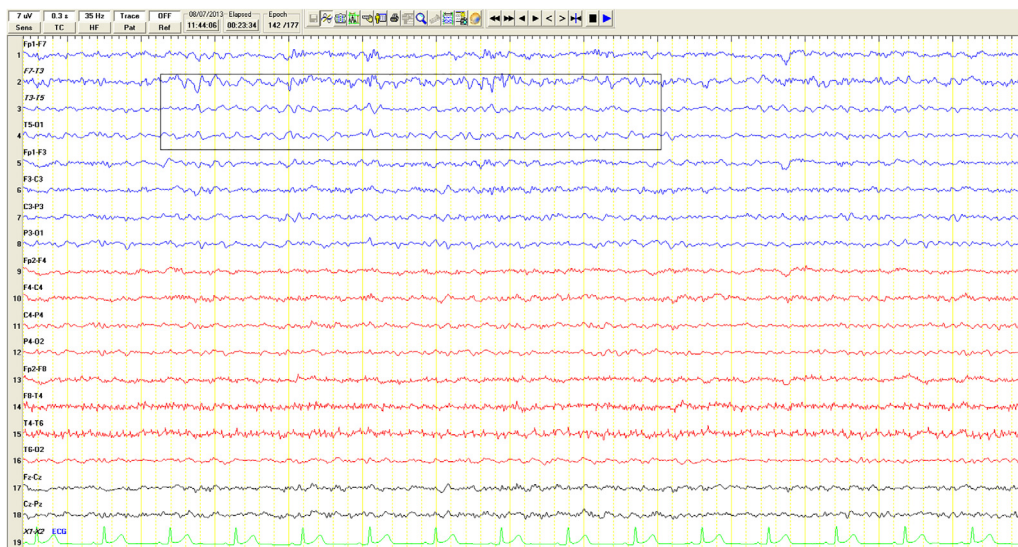
seizures and include preictal, ictal, and postictal psychosis. We separated them into periictal psychotic episodes (PPE) and interictal psychosis (IIP) when a relationship between psychosis and seizures did not exist.

For PPE we used the same definitions as those identified by Logsdail and Toone. PIP was defined as appearing within one week after a seizure or cluster of seizures, lasting from at least 15 hours up to 2 months, and preceded by a lucid period (24–72 h). Ictal psychosis was defined as psychosis appearing simultaneously with a prolonged seizure or status epilepticus as the clinical expression confirmed by an EEG without prominent motor symptoms [3].

Most of the old and new antiseizure drugs (ASD) as well as surgical treatment have been implicated in the emergence of PPE [4,5]. Psychotic symptoms in epileptic patients with PPE are thought to be influenced by a disruption in a chronic inhibitory mechanism. Immediately after a cluster of seizures, PIP patients

\* Corresponding author at: Epilepsy Unit, Neurology Department, Hospital Universitari de Bellvitge, Feixa Llarga S/N, 08907 Hospitalet de Llobregat, Barcelona, Spain.

E-mail addresses: [malemany@bellvitgehospital.cat](mailto:malemany@bellvitgehospital.cat) (M. Alemany), [ereal@bellvitgehospital.cat](mailto:ereal@bellvitgehospital.cat) (E. Real), [ncustal@bellvitgehospital.cat](mailto:ncustal@bellvitgehospital.cat) (N. Custal), [jacint.sala@gmail.com](mailto:jacint.sala@gmail.com) (J. Sala-Padró), [laurodriguez@bellvitgehospital.cat](mailto:laurodriguez@bellvitgehospital.cat) (L. Rodríguez-Bel), [gplans@bellvitgehospital.cat](mailto:gplans@bellvitgehospital.cat) (G. Plans), [jmora@bellvitgehospital.cat](mailto:jmora@bellvitgehospital.cat) (J. Mora), [msaturino@bellvitgehospital.cat](mailto:msaturino@bellvitgehospital.cat) (M. Santurino), [tim@e4sci.com](mailto:tim@e4sci.com) (T. Vancamp), [mfalip@bellvitgehospital.cat](mailto:mfalip@bellvitgehospital.cat) (M. Falip).



**Fig. 1.** EEG recording during a postictal psychosis Patient with visual hallucinations and feelings of being harmed by others. EEG records show a left temporal breach rhythm due to previous craniotomy. There were occasional interictal epileptiform discharges in the recording (box).

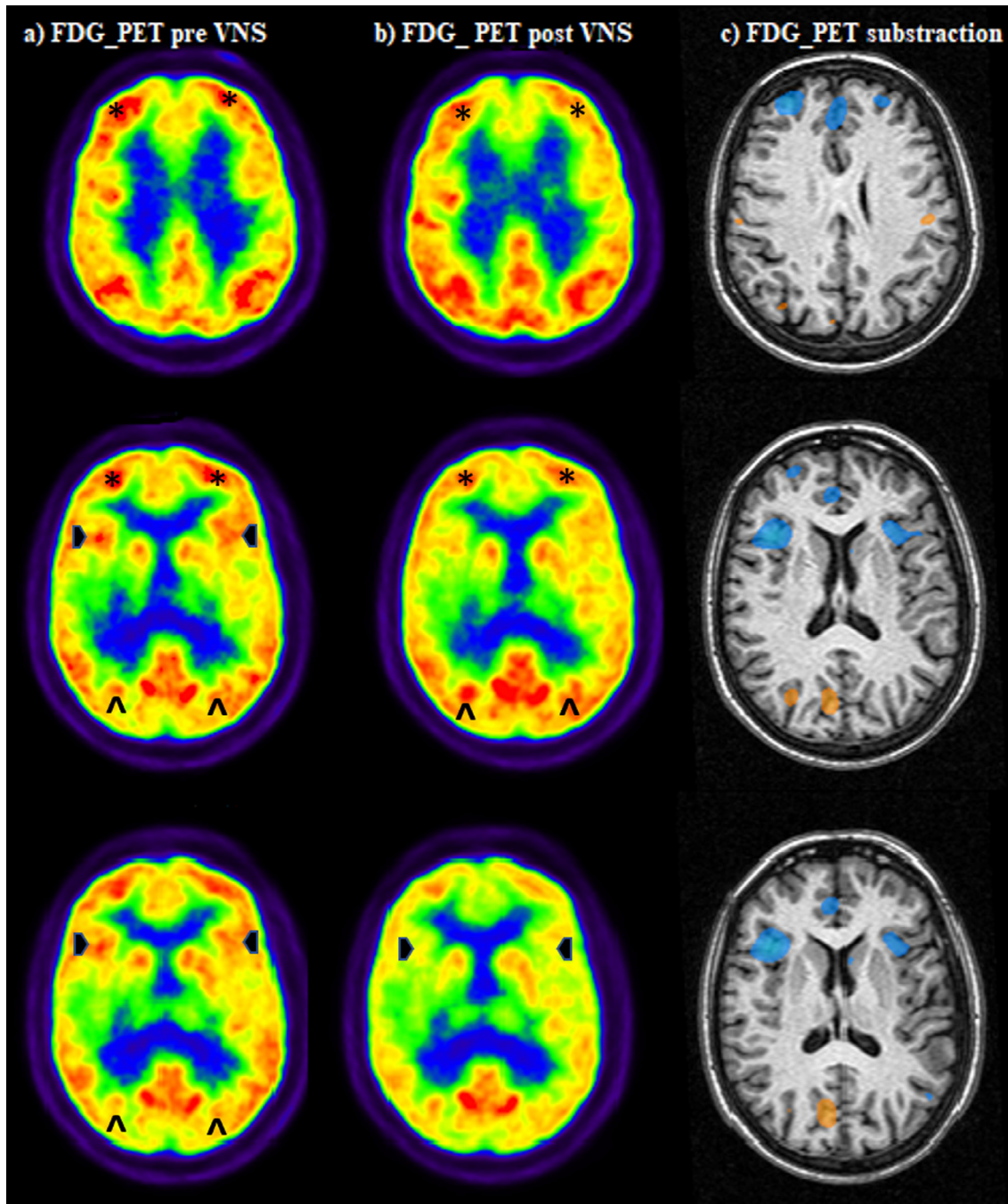
may experience an unusually profound depression of limbic function producing a disconnection of the temporal-limbic structures and the prefrontal structures and a loss of control over the prefrontal structures [6]. This concept was first introduced in 1953 by Landolt with the concept of ‘forced normalization theory’ to describe the appearance of psychotic episodes associated with total or partial normalization of the electroencephalogram (EEG) in patients with epilepsy [7]. In regard to this, vagus nerve stimulation (VNS) therapy has also played a role [8–11]. Paradoxically, a

positive effect in the modulation of psychiatric symptoms has been observed in VNS treated patients, and it has been approved as a non-pharmacological adjunctive treatment for depression [12]. Moreover, a recent study conducted in an animal model for schizophrenia found VNS provided a positive effect in controlling psychotic symptoms [13].

We aimed to study the neuro-modulatory effect of VNS on psychotic episodes in drug-resistant epilepsy (DRE) patients with a pre-existing history of PPE in a single-center retrospective analysis.



**Fig. 2.** EEG recording during an ictal psychosis Patient with visual hallucinations and heteroaggressive behaviour. EEG record during the episode shows (A) interictal epileptiform activity over T7, P7, P3 (box) and (B) subclinical seizures (42 subclinical seizures in 6 hours) starting with alpha rhythm in T8 and spreading to the right frontotemporal area (box).



**Fig. 3.**  $^{18}\text{F}$ -FDG-PET pre- and post-VNS implantation **a)**  $^{18}\text{F}$ -FDG-PET pre-VNS shows hypometabolism in both superior parietal lobes (^), more intense in the right (epileptogenic area) and relative hypermetabolism in the mesial frontal areas (\*) and the anterior insulas (.). **b)**  $^{18}\text{F}$ -FDG-PET post-VNS shows less intense hypometabolism in both superior parietal lobes (^) with a normalization of the hypermetabolism in the frontal lobes (\*) and insular lobes (.). **c)** Z map of the  $^{18}\text{F}$ -FDG-PET subtraction co-registered with the MRI, showing the cortical areas that underwent a change of more than 2SD in metabolism; frontal areas with a decrease of metabolism (**blue blob**) and right parietal areas with increase of metabolism (**orange blob**). (For interpretation of the references to colour in this figure legend, the reader is referred to the web version of this article.)

A total of 48 patients diagnosed with DRE and treated with VNS therapy from 2006 to 2016 were identified. None of the implanted patients developed psychosis. In the present study we included 4 patients from the series with a prior history of PPE.

Patient evaluation included a formal intermittent psychiatric examination, prolonged video-EEG (vEEG), structural magnetic resonance imaging (MRI) study with a standard epilepsy protocol, and  $^{18}\text{F}$ -labelled fluoro-2-deoxyglucose-positron emission tomography ( $^{18}\text{F}$ -FDG-PET) co-registered with MRI.

### 1.1. Case 1

A 40-year-old male patient was diagnosed at the age of 23 with non-lesional bitemporal DRE. The patient experienced 8 episodes per month of focal impaired awareness seizure (FIAS), and occasionally focal to bilateral tonic-clonic seizure (FBTCS). Several ASDs were tested without achieving seizure control, with oxcarbazepine (OXC), clobazam (CBM) and brivaracetam (BRV) the last combination tried. Anterior temporal lobe resection of the most affected

temporal lobe was done at the age of 34 without changes in seizure frequency. After nine months, the patient started suffering PIP episodes at a frequency of 3 episodes per year. PIP episodes began in the 12–24 hours after the seizure and lasted for 3–5 days. These episodes were characterised by a state of confusion and auditory hallucinations, requiring hospitalization in one case. No prior history of psychotic disorder was reported. During PIP episodes normal EEG background with fronto–temporal interictal epileptiform discharges was recorded (see Fig. 1). VNS device was implanted one year later to achieve better seizure control. After a 5-year follow-up seizures were reduced by 62.5% in addition to a change in semiology (focal aware seizure with distorted body perception) and reduced seizure severity. In terms of PIP, 3 episodes in the 2nd year was noted and no new episodes appeared after the third year of stimulation.

1.2. Case 2

A 54-year-old male patient was diagnosed at the age of 14 with DRE secondary to a malformation of cortical development. Bitemporal seizures at a frequency of 6–8 episodes per month were reported. FIAS not preceded by aura and occasionally Focal to bilateral tonic-clonic seizures (FBTCS) were the typical seizure types. Several ASDs (OXC, phenytoin (PHT) and lacosamide (LCM)) were tested without achieving seizure control. At the age of 43 the patient started suffering recurrent episodes of postictal psychosis which started between 8 and 12 hours after a seizure, characterised by a state of confusion with hallucinations and paranoia. No prior history of psychotic disorder was reported. Antipsychotic treatment was initiated with quetiapine (QTP) and haloperidol (HLP); however, episodes were still present occurring with a frequency of 2–3 times per year, requiring hospitalization on two occasions. VNS therapy was implanted at the age of 48. After a 6-year follow-up seizures were reduced by 42.8% with a change in semiology (appearing only nocturnally). No further episodes of postictal psychosis were documented one year after VNS implantation.

1.3. Case 3

A 47-year-old female patient was diagnosed at the age of 12 with DRE secondary to a parietal tumour. Initial surgery was done in another center when the patient was 16 and the histopathology was reported as oligodendroglioma, with complete resection. The patient was seizure free for 3 years but then the seizures reappeared and became more and more frequent. No evidence of tumor relapse was observed. She was reoperated twice, at the ages of 25

and 31 including a left parietal topectomy and a right amygdalo-hippocampectomy. At the age of 36 she started suffering ictal psychosis during episodes characterised by delusions, anxiety, agitation, and heteroaggressivity. These psychotic episodes appeared simultaneously with an exacerbation of seizure clustering. No prior history of psychotic disorder was reported. She was monitored in our center from 2012, and at that time she suffered 1–2 seizures per day and 1 episode of psychosis per month. EEG findings during these episodes showed seizures arising in one parietal or temporal lobe evolving to contralateral areas without recovery between them (see Fig. 2). Antipsychotic treatment was initiated with QTP and clozapine (CPZ), but unfortunately the episodes remained, with a frequency of 6–8 per year. In relation to post-surgical changes, MRI showed areas of encephalomalacia-gliosis on the right temporal-insular cortex and left parietal splenium of the corpus callosum. At the age of 43, a VNS was implanted achieving a reduction of seizures by 82.5% and elimination of the episodes of SE over a 4 year follow-up period. Post-VNS the semiology of seizures also changed to focal aware seizures and falls. Only 1 episode of ictal psychosis was documented in the 1st year and was completely eliminated by the 2nd year after VNS implantation.

1.4. Case 4

A 61-year-old female patient was diagnosed at the age of 18 with non-lesional DRE, temporal and biparietal lobes. The patient experienced FIAS not preceded by aura with a frequency of 10–15 episodes per month, and 1–2 SE per month (starting with clusters of 5–7 seizures for 3–4 hours and continuing with an altered mental state of confusion and disorientation for 3 days). Several ASDs were trialed without achieving seizure control. The last trial included combination therapy with levetiracetam and lamotrigine. At the age of 50 during periods when the frequency of seizures was higher, the patient started suffering ictal psychosis characterised by episodes of agitation, auditory hallucinations, and perspicuous feelings. No prior history of psychotic disorders was reported. Antipsychotic treatment was initiated with risperidone without achieving control of psychotic episodes which continued with a frequency of 2–4 per year requiring hospitalization on 7 occasions, 3 of them due to suicide attempts.

At the age of 58 VNS was implanted achieving a reduction of seizure frequency by 60% and elimination of SE over a 4 year follow-up period. Seizure severity also changed due to changes in semiology to focal aware seizures with somatosensory aura in the right foot not followed by impaired awareness most of the time when she acutely activated magnet-induced VNS stimulation. No

**Table 1**  
Demographics and clinical characteristics of patients with prior history of periictal psychosis (PPE) and VNS therapy.

|   | P 1                                | P 2                                  | P 3                                    | P 4  |
|---|------------------------------------|--------------------------------------|--|--|
| Gender  | Male                               | Male                                 | Female                                 | Female   |
| Age (Yrs)                                     | 40                                 | 54                                   | 47                                     | 61   |
| Age at epilepsy onset (Yrs)                   | 23                                 | 14                                   | 12                                     | 18   |
| Aetiology                                     | Unknown                            | Malformation of cortical development | Left oligodendroglioma                 | Unknown  |
| Seizures localization                         | Bitemporal                         | Bitemporal                           | Left parietal, bitemporal              | Left temporal, biparietal                                |
| Age at psychosis onset (Yrs)                  | 34                                 | 43                                   | 36                                     | 50   |
| Psychiatric symptoms                          | Confusion, auditory hallucinations | Confusion, Hallucinations, paranoia  | Anxiety, agitation, heteroaggressivity | Agitation, auditory hallucinations, perspicuous feelings |
| Psychiatric disorder in relation to seizures* | Postictal                          | Postictal                            | Ictal                                  | Ictal  |
| Age at VNS implantation (Yrs)                 | 35                                 | 48                                   | 43                                     | 58   |
| VNS** follow-up time (Yrs)                    | 5                                  | 6                                    | 4                                      | 3  |
| Intensity/frequency VNS*                      | 1 mA/ on 30'' off 5'               | 2 mA/ on 30'' off 5'                 | 2.25 mA/ on 30'' off 1.8'              | 2 mA/ on 30'' off 3'                                     |

\* Psychotic disorder due to epilepsy, according to DSM-IV criteria (code 293.0: Diagnostic and Statistical Manual of Mental Disorders); \*\*VNS: Vagal nerve stimulation.

further psychotic episodes were documented after the first year of VNS implantation.

Additionally, <sup>18</sup>F-FDG-PET before VNS implantation was performed showing hypometabolism in both superior parietal lobes, more evident in the right, and relative hypermetabolism in the mesial frontal areas and anterior insulas. <sup>18</sup>F-FDG-PET after 4 years following VNS implantation showed less intense hypometabolism in both superior parietal lobes with a normalisation of the hypermetabolism in the frontal lobes, insular lobes, and left caudate nucleus (shown in Fig. 3).

A summary of demographics and clinical characteristics of the reported cases and VNS therapy effects are shown in Table 1 and Table 2, respectively.

## 2. Discussion/Conclusion

New onset psychotic episodes after VNS implantation have been reported in the literature [10]. These are may be seen in patients with DRE when they suddenly become seizure-free, presumably due to forced normalization. In contrast, one study has shown an antipsychotic effect after VNS implantation [12]. Recently, Lee et al. [14] reported the first case of forced normalization after turning off VNS in a patient suffering from Lennox-Gastaut syndrome.

Regarding the VNS mechanisms of action, it is thought that afferent vagal fibers modulate the release of different neurotransmitters in the brainstem involving the locus coeruleus, the nucleus of the solitary tract, thalamus, and limbic system structures. The dysregulation of neurotransmitters has also been identified relative to altered seizure threshold and in psychiatric disorders [15].

In our study, the results showed that patients suffering from PPE had their ictal or postictal psychotic episodes controlled after VNS implantation. However, the positive psychotropic effect was not immediate. Combined time-frame analysis showed a latency effect of VNS to control psychosis of 8.3 months (range: 6–36 months). This occurred despite the absence of seizure control, however, in three of the cases semiology changed after VNS implantation.

<sup>18</sup>F-FDG-PET images showed a normalization of metabolism in both medial prefrontal cortical areas and anterior insulas in one of our patients, after VNS implantation. Interestingly, perfusion changes in the same areas have been described apart from the epileptogenic foci in psychotic and epileptic patients [16–18]. Normalization of medial frontal metabolism, one of the cortical areas of the cortico-striatal-thalamic-cortical loop circuits has been suggested as important in schizophrenia patients and has also been observed in DRE patients suffering psychosis [19].

Although it is speculative, this positive psychotropic effect in DRE patients suffering ictal and postictal psychosis could be related to a long-term neuromodulator effect of the VNS, independent of its antiseizure effect [20–22]. Despite these encouraging preliminary results, future research is needed to confirm our findings and to determine whether VNS-induced brain changes are associated with a favorable outcome in patients with VNS and ictal or postictal psychosis. Larger prospective studies are recommendable to validate our initial observation.

## 3. Statements

### 3.1. Ethics statement

The study was approved by the Ethics Committee of the University Hospital of Bellvitge (Hospitalet de Llobregat, Barcelona, Spain) and conducted in accordance with the Declaration of Helsinki, PR 349/18. The patients' confidential information was protected

**Table 2**  
VNS therapy effects.

|     | Pre-VNS                  |                               |  |  | Post-VNS                            |                           |                                 |                                      |                            |  |                                     |                               |                                     |
|-----|--------------------------|-------------------------------|--|--|-------------------------------------|---------------------------|---------------------------------|--------------------------------------|----------------------------|--|-------------------------------------|-------------------------------|-------------------------------------|
|     | Seizure type             | Seizure frequency (per month) | Seizure treatment (dose mg/day)                    | Psychotic episode frequency (per year) | Psychiatric treatment (dose mg/day) | Seizure type              | Reduction Seizure frequency (%) | Seizure treatment (dose mg/day)      | Magnet-controlled seizures | Psychotic episode Frequency (per year) | Psychiatric treatment (dose mg/day) | Psychotic episode-free* (Yrs) | Psychotic episode-free period (Yrs) |
| PT1 | FIAS, occasionally FBTCs | 8                             | Surgery OXC (1500)<br>CBM (10)<br>BRV (100)        | 3                                      | -                                   | Focal awareness           | 62.5%                           | OXC (1200)<br>CBM (10)<br>LCM (20)   | Yes                        | 3 episodes in the 1-2nd year           | -                                   | 3rd                           | 2                                   |
| PT2 | FIAS, occasionally FBTCs | 8-6                           | OXC (1200)<br>PHT (350)<br>LCM (200)               | 2-3                                    | QTP (200) HLP (6)                   | Nocturnal seizures        | 42.8%                           | PHT (350)<br>LCM (200)<br>ESL (1600) | No                         | No episodes                            | QTP (100)<br>HLP (4)                | 1st                           | 6                                   |
| PT3 | FIAS                     | 30-50 SE 1                    | Surgery (3)<br>ZNS (300)<br>CBZ (1200)<br>CBM (20) | 6-8                                    | QTP (100) CZP (100)                 | Focal awareness and falls | 82.5% SE 100%                   | CBZ (1200)<br>ZNS (300)<br>CBM (20)  | No                         | 1 episode in the 1st year              | QTP (100)                           | 2nd                           | 3                                   |
| PT4 | FIAS                     | 10-15 SE 1-2                  | LVT (2000)<br>LMT (400)                            | 2-4                                    | RPD (10)                            | Focal awareness           | 60% SE 100%                     | LVT (1000)<br>LMT (400)              | Yes                        | No episodes                            | QTP (100)                           | 1st                           | 3                                   |

Abbreviations: FIAS: Focal impaired awareness seizure; FBTCs: focal to bilateral tonic-clonic seizure; SE: status epilepticus; BRV: brivaracetam; CBZ: carbamazepine; CBM: clobazam; LCM: lacosamide; LMT: lamotrigine; LVT: levetiracetam; OXC: oxcarbazepine; PHT: phenytoin; ZNS: zonisamide; CPZ: clobazam; HLP: haloperidol; QTP: quetiapine, RPD: risperidone. \* Determined to be the first psychotic episode-free year after VNS implantation.

according to the current European and Spanish regulations. All patients signed an informed consent.

### Acknowledgments

We gratefully thank all the patients who selflessly participated in the study.

### Declaration of Competing Interest

T. Vancamp is also an employee of LivaNova. All other authors report no conflicts of interest.

### Study funding

No financial or any other support has been provided to the authors to perform this study, nor to compose this manuscript.

### Authors' contributions:

I. Conception and design: M. Falip, T. Vancamp, and M. Alemany.

II. Administrative support: M. Santurino.

III. Provision of study materials for patients: G. Plans, E. Real, N. Custal, and J. Mora.

IV. Collection and assembly of data: M. Falip, L. Rodríguez-Bel, and M. Alemany.

V. Data analysis and interpretation: M. Falip, J. Sala-Padró, and M. Alemany.

VI. Manuscript writing: All authors.

VII. Final approval of manuscript: All authors

### References

- [1] Clancy MJ, Clarke MC, Connor DJ, Cannon M, Cotter DR. The prevalence of psychosis in epilepsy; a systematic review and meta-analysis. *BMC Psychiatry* 2014;14:75.
- [2] Kanner AM, Soto A, Gross-Kanner H. Prevalence and clinical characteristics of postictal psychiatric symptoms in partial epilepsy. *Neurology* 2004;62(5):708–13.
- [3] Logsdail SJ, Toone BK. Post-ictal psychoses. A clinical and phenomenological description. *Br J Psychiatry* 1988;152:246–52.
- [4] Ramos-Perdigués S, Baillés E, Mané A, Carreño M, Donaire A, Rumià J, et al. Psychiatric symptoms in refractory epilepsy during the first year after surgery. *Neurotherapeutics* 2018;15(4):1082–92.
- [5] Jaliha V, Shankar R, Henley W, Parrett M, Tittensor P, McLean BN, et al. Eslicarbazepine acetate as a replacement for levetiracetam in people with epilepsy developing behavioral adverse events. *Epilepsy Behav* 2018;80:365–9.
- [6] Wolf P. Acute behavioral symptomatology at disappearance of epileptiform EEG abnormality. Paradoxical or forced normalization. *Adv Neurol* 1991;55:127–1427.
- [7] Krishnamoorthy ES, Trimble MR, Sander JWAS, Kanner AM. Forced normalization at the interface between epilepsy and psychiatry. *Epilepsy Behav* 2002;3(4):303–8.
- [8] Trimble MR. Behaviour changes following temporal lobectomy, with special reference to psychosis. *J Neurol Neurosurg Psychiatry* 1992;55(2):89–91.
- [9] Buranee K, Teeradej S, Chusak L, Michael M. Epilepsy-related psychoses and psychotic symptoms are significantly reduced by resective epilepsy surgery and are not associated with surgery outcome or epilepsy characteristics: a cohort study. *Psychiatry Res* 2016;245:333–9.
- [10] Blumer D, Davies K, Alexander A, Morgan S. Major psychiatric disorders subsequent to treating epilepsy by vagus nerve stimulation. *Epilepsy Behav* 2001;2(5):466–72.
- [11] De Herdt V, Boon P, Vonck K, Goossens L, Nieuwenhuis L, Paemeleire K, et al. Are psychotic symptoms related to vagus nerve stimulation in epilepsy patients?. *Acta Neurol Belg* 2003;103(3):170–5.
- [12] Koutroumanidis M, Binnie CD, Hennessy MJ, Alarcon, G, Elwes RD, Toone BK, et al. VNS in patients with previous unsuccessful resective epilepsy surgery: antiepileptic and psychotropic effects. *Acta Neurol Scand.* 2003;107(2):117–121.
- [13] Perez SM, Carreno FR, Frazer A, Lodge DJ. Vagal nerve stimulation reverses aberrant dopamine system function in the methylazoxymethanol acetate rodent model of schizophrenia. *J Neurosci* 2014;34(28):9261–7.
- [14] Lee S, Denton A, Ladino LD, Waterhouse K, Vitali A, Tellez-Zenteno JF. Forced normalization after turning off vagus nerve stimulation in Lennox-Gastaut syndrome. *Epilepsy Behav Case Rep* 2019;11:81–3.
- [15] Vonck K, Boon P. The mechanism of action of vagus nerve stimulation therapy. *Eur Neurol Rev* 2008;3(2):97–100.
- [16] Allebone J, Kanaan R, Wilson SJ. Systematic review of structural and functional brain alterations in psychosis of epilepsy. *J Neurol Neurosurg Psychiatry* 2018;89:611–7.
- [17] Fong GCY, Fong KY, Mak W, Tsang KL, Chan KH, Cheung RT, et al. Postictal psychosis related regional cerebral hyperperfusion. *Cit J Neurol Neurosurg Psychiatry* 2000;68:100–1.
- [18] Hasan A, Wolff-Menzler C, Pfeiffer S, Falkai P, Weidinger E, Jobst A, et al. Transcutaneous noninvasive vagus nerve stimulation (tVNS) in the treatment of schizophrenia: a bicentric randomized controlled pilot study. *Eur Arch Psychiatry Clin Neurosci* 2015;265(7):589–600.
- [19] Peters SK, Dunlop K, Downar J. Cortico-striatal-thalamic loop circuits of the salience network: a central pathway in psychiatric disease and treatment. *Front Syst Neurosci* 2016;10:104.
- [20] Graat I, Figeé M, Denys D. The application of deep brain stimulation in the treatment of psychiatric disorders. *Int Rev Psychiatry* 2017;29(2):178–90.
- [21] Hadar R, Bikovski L, Soto-Montenegro ML, Schimke J, Maier P, Ewing S, et al. Early neuromodulation prevents the development of brain and behavioral abnormalities in a rodent model of schizophrenia. *Mol Psychiatry* 2018;23(4):943–51.
- [22] Corripio I, Roldán A, Sarró S, McKenna PJ, Alonso-Solís A, Rabella M, et al. Deep brain stimulation in treatment resistant schizophrenia: a pilot randomized cross-over clinical trial. *EBioMedicine* 2020;51:102568.