



Original Research

Warty (follicular) dyskeratoma on the mons pubis☆☆☆



P.E. Kerr*, M.J. Murphy

Department of Dermatology, University of Connecticut School of Medicine, Farmington, CT

ARTICLE INFO

Article history:

Received 23 June 2017

Received in revised form 6 July 2017

Accepted 6 July 2017

Keywords:

Warty dyskeratoma

acantholysis

dyskeratosis

follicle

vulva

ABSTRACT

Warty (follicular) dyskeratoma (WD) is a discrete nodular lesion that demonstrates the characteristic histopathologic findings of acantholysis and dyskeratosis. WDs most commonly occur on the head and neck of adults. We present a case of WD that occurred on the mons pubis of a 53-year-old woman. Only a few other cases of WDs occurring on the vulva have been reported. WD most likely represents a tumor of the follicular infundibulum. Despite its name, there is no evidence that WD is caused by a human papillomavirus (HPV) infection. Although occurrences on the vulva are rare, they must be distinguished from HPV-induced squamous tumors when found in this area.

© 2017 The Authors. Published by Elsevier Inc. on behalf of Women's Dermatologic Society. This is an open access article under the CC BY-NC-ND license (<http://creativecommons.org/licenses/by-nc-nd/4.0/>).

Introduction

Warty dyskeratoma (WD) is a benign epithelial tumor that was first described by Helwig in 1954. Shortly thereafter, Graham and Helwig (1958) noted similarities to an isolated lesion of Darier's disease and applied the term "isolated dyskeratosis follicularis." In his review of seven new cases, Szymanski (1957) first used the designation "warty dyskeratoma." He summarized the salient features of the condition in the name by combining the sometimes "warty" clinical appearance with "dyskerato-," which refers to a principal pathologic feature of dyskeratosis, and "-oma," which indicates a tumor. The most common clinical presentation of WD is an isolated papule or nodule on the head and neck of adults (Kaddu et al. 2002; Tanay and Mehregan 1969). Histopathologically, WD is characterized by focal acantholysis and dyskeratosis, which is typically present at the base of a cup-shaped epidermal invagination (Kaddu et al. 2002). WD has only rarely been reported to involve the vulva (Cooper 1989; Duray et al. 1983; Lora et al. 2015; Torres and Junkins-Hopkins 2016). We present a case that involves the mons pubis.

Case report

A 53-year-old woman presented with a 5-month history of a slowly enlarging, firm nodule on the central portion of the mons pubis (Fig. 1).

There was no history of bleeding or drainage. She was otherwise in good health and had no other significant dermatologic history or complaints. The patient's family history was unremarkable. A physical examination revealed a round, 0.6-cm, firm, hyperkeratotic, hyperpigmented nodule. No bleeding or exudate was observed. Clinically, the lesion was suspected to be a dermatofibroma. No other contributory skin findings were discovered elsewhere on the patient's body. A 6-mm punch biopsy was performed. On microscopic examination, a circumscribed, cup-shaped, epidermal invagination that extended into the midportion of the underlying dermis was observed (Fig. 2). The invagination was filled with a plug of keratinous material that contained numerous grains. The base of the invagination consisted of hyperplastic epithelium with uniform digitate projections ("villi") into the subjacent dermis (Fig. 3). The epithelium exhibited acantholysis and dyskeratosis, and there was a mild, predominantly lymphocytic infiltrate in the papillary dermis.

Discussion

WD is an unusual tumor that rarely occurs on the vulva. In the two largest case series published to date, one describes 112 cases of WD (Tanay and Mehregan 1969) and the other 46 cases (Kaddu et al. 2002), but none of these cases involved the genital area of patients. Our case is one of only a few ever reported on the vulva. The first such report describes WDs that occurred on the labia majora of three women (Duray et al. 1983). The second describes a WD that occurred on the left inguinal fold of a 63-year-old woman (Cooper 1989). Another report describes a WD that occurred on the mons pubis of a 61-year-old patient (Lora et al. 2015), and the most recent

* Conflicts of interest: None.

☆☆ Funding sources: None.

* Corresponding Author.

E-mail address: pkerr@uchc.edu (P.E. Kerr).

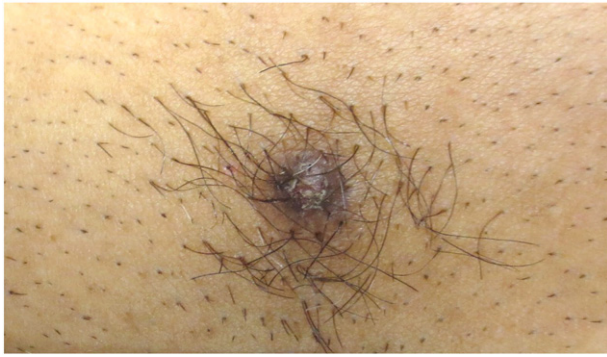

Fig. 1. Solitary, hyperkeratotic, hyperpigmented nodule on the mons pubis

report describes a WD that arose in the context of an infundibular cyst on the left aspect of the vulva of a 53-year-old patient (Torres and Junkins-Hopkins 2016).

Given the similarity that some WDs have with common viral warts, there is concern that human papillomavirus (HPV) infection may play a causative role (Kaddu et al. 2002; Kaugers et al. 1984). This would be especially concerning for WDs that occur on or near patients' genitals. To address this concern, Kaddu et al. (2002) performed a polymerase chain reaction analysis for HPV DNA on 13 lesions of WD and found no evidence of HPV DNA.

Historically, WD has been a tumor of unclear histogenesis. The lining of the typical cup-shaped invagination resembles that of the follicular infundibulum, and because many examples of WD connect to pilosebaceous units, a convincing argument has been made that WD is a follicular adnexal neoplasm (Diallo et al. 2007; Kaddu et al. 2002). Yet, there are occasional reports in the literature of WDs that occur on the oral mucosa (Allon and Buchner 2012; Gorlin and Peterson 1967; Kaugers et al. 1984). The presence of a WD arising on the oral mucosa would argue against a follicular derivation because this anatomic site normally lacks hair follicles. However, more recently, authors have argued that cases that were reported as oral warty dyskeratoma are a form of focal acantholytic dyskeratosis

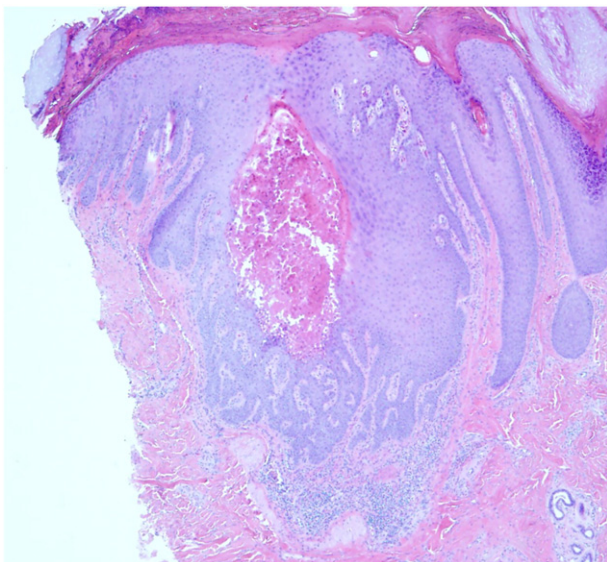


Fig. 2. Circumscribed, cup-shaped, epidermal invagination that is lined by stratified squamous epithelium and filled with a plug of parakeratotic material including numerous grains

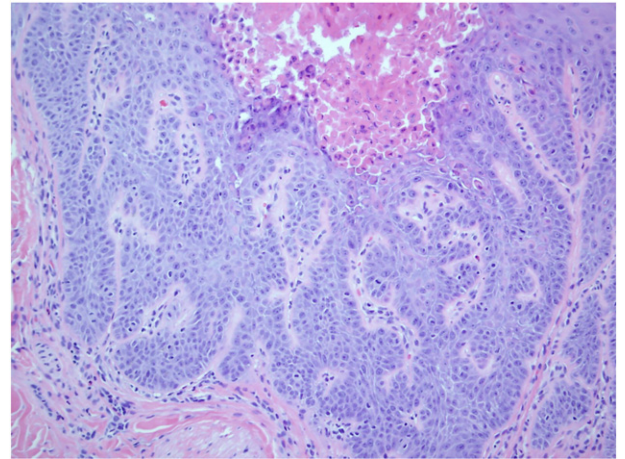


Fig. 3. Acantholysis and prominent dyskeratosis at the base of the epidermal invagination that affects the upper portion of the epithelium as well as numerous interconnecting digitate projections that extend into the subjacent dermis

that is distinct from the WDs seen on the skin surface (Allon and Buchner 2012; Kaddu et al. 2002). Of note, in an immunohistochemical analysis of 10 cases of WDs that occurred on the skin surface, cytokeratin (CK) 5 and CK17 were expressed in the basal layers of the lesions, while CK1 and CK10 were seen in the suprabasal layers (Diallo et al. 2007). This pattern of cytokeratin expression supports the concept of WD as an adnexal tumor with follicular differentiation. Harkening back to the name originally proposed by Graham and Helwig (1958), “isolated dyskeratosis follicularis,” the term follicular dyskeratoma has been proposed (Kaddu et al. 2002) to replace “warty dyskeratoma” because it better reflects its apparent follicular infundibular derivation and because the lesions are typically not clinically verrucous nor are they caused by an HPV infection.

In conclusion, we present a case of warty (follicular) dyskeratoma that occurred on the mons pubis. Histopathologically, our case of WD is indistinguishable from WDs found on more typical locations such as the head and neck. Despite its rarity on the vulva, WD must be distinguished clinically and histologically from the more concerning HPV-induced squamous lesions that are found in this area.

Epilogue

A great mentor is central to individual, departmental, and institutional success. Jane Grant-Kels has always been guided by this important responsibility. Her leadership skills, combined with her vast knowledge and expertise, have been instrumental in fostering so many creative, productive, and successful physicians at University of Connecticut Department of Dermatology. Like all great mentors, Jane is a good listener, a skilled facilitator, and a fantastic role model. It is with deep appreciation that we recognize Dr. Grant-Kels for delivering superb patient care and for her dedication to providing the finest education for our medical students and residents. Moreover, we can imagine no greater champion for the happiness and advancement of her faculty. For this, we will be eternally grateful.

References

- Allon I, Buchner A. Warty dyskeratoma/focal acantholytic dyskeratosis – An update on a rare oral lesion. *J Oral Pathol Med* 2012;41:261–7.
- Cooper PH. Acantholytic dermatosis localized to the vulvocrural area. *J Cutan Pathol* 1989;16:81–4.
- Diallo M, Cribier B, Scrivener Y. Warty dyskeratoma: Infundibular histogenesis. Anatomoclinical study of 43 cases. *Ann Dermatol Venerol* 2007;134:633–6.
- Duray PH, Merino MJ, Axiotis C. Warty dyskeratoma of the vulva. *Int J Gynecol Pathol* 1983;2:286–93.

- Gorlin RJ, Peterson WC. Warty dyskeratoma: A note concerning its occurrence on the oral mucosa. *Arch Dermatol* 1967;95:292–3.
- Graham JH, Helwig EB. Isolated dyskeratosis follicularis. *Arch Dermatol* 1958;77:377–89.
- Helwig EB. Seminars on the Skin. Neoplasms and Dermatoses. Proceedings of the 20th Seminar of the American Society of Clinical Pathologists. Paper presented at: International Congress of Clinical Pathology. September 11, 1954; Washington, DC; 1954.
- Kaddu S, Dong J, Mayer G, Kerl H, Cerroni L. Warty dyskeratoma – Follicular dyskeratoma: Analysis of clinicopathologic features of a distinctive follicular adnexal neoplasm. *J Am Acad Dermatol* 2002;47:423–8.
- Kaugers GE, Lieb RJ, Abbey LM. Focal oral warty dyskeratoma. *Int J Dermatol* 1984;23:123–30.
- Lora V, Scarabello A, Cota C. Warty dyskeratoma as a cutaneous horn of the mons pubis. *Am J Dermatopathol* 2015;37:802–4.
- Szymanski FJ. Warty dyskeratoma: A benign cutaneous tumor resembling Darier's disease microscopically. *Arch Dermatol* 1957;75:567–72.
- Tanay A, Mehregan AH. Warty dyskeratoma. *Dermatologica* 1969;138:155–64.
- Torres KM, Junkins-Hopkins JM. Cystic acantholytic dyskeratosis of the vulva: An unusual presentation of a follicular adnexal neoplasm. *Indian Dermatol Online J* 2016;7:272–4.