



Surgical Management of a Massive Frontal Bone Hemangioma: Case Report

Cylaina E. Bird¹ Jeffrey I. Traylor¹ Zachary D. Johnson¹ Jun Kim² Jack Raisanen³ Babu G. Welch¹
Kalil G. Abdullah⁴

¹Department of Neurological Surgery, University of Texas Southwestern Medical Center, Dallas, Texas, United States

²Department of Neurosurgery, Westmead Hospital, Westmead, Sydney, Australia

³Department of Pathology, University of Texas Southwestern Medical Center, Dallas, Texas, United States

⁴Department of Neurosurgery, University of Pittsburgh, Pittsburgh, Pennsylvania, United States

Address for correspondence Kalil G. Abdullah, MD, Department of Neurosurgery, University of Pittsburgh, 200 Lothrop St Suite b-400, Pittsburgh, PA 15213, United States (e-mail: kaa194@pitt.edu).

J Neurol Surg Rep 2022;83:e72–e76.

Abstract

Intraosseous hemangiomas are rare, benign tumors that can arise from the calvarium. These lesions often invade the outer table of the skull, but typically spare the inner table and intracranial structures. En bloc surgical resection is the standard treatment for intraosseous hemangiomas. However, a piecemeal resection may be required to safely remove the tumor in cases involving the inner table to protect the underlying brain parenchyma and vascular structures. Proper reconstruction is critical to optimize the cosmetic outcome, and a staged procedure allowing implantation of a custom-made implant can be considered for large lesions involving the forehead. We present a case of a patient with a large frontal intraosseous hemangioma with intradural involvement to highlight the surgical nuances of resection and review the existing literature regarding optimal management of these patients.

Keywords

- ▶ frontal bone
- ▶ intraosseous hemangioma
- ▶ skull
- ▶ surgical management

Importance

Intraosseous cavernous hemangiomas are rare, benign tumors.^{1–18} These lesions represent 0.2% of primary cranial bone tumors and predominantly present as solitary lesions in the frontal or parietal bone.^{1–5,7–10,12–17,19–32} They often involve the outer table and diploic space, while sparing the inner table, and are treated with en bloc surgical resection and cranioplasty.^{2,13,14,20} Few reports have described intraosseous cavernous hemangiomas extending beyond the inner table or with substantial involvement of the bifrontal calvarium.^{2,8,11,24} We present a case highlighting the surgical management of a frontal hemangioma with intradural ex-

ension, including a staged reconstruction aimed at optimizing postoperative cosmesis.

Clinical Presentation

An otherwise healthy 38-year-old female presented for evaluation of a large, painless mass on the forehead that slowly progressed in size over 7 months. Physical examination revealed a large, palpable, nontender mass in the frontal region. She was worked up with a noncontrast computed tomography (CT) head demonstrating a 5.5 × 3.2 × 5.6 cm well-circumscribed mass with an internal sunburst pattern of trabecular thickening, expanding through the inner and

received

May 18, 2021

accepted

March 29, 2022

DOI <https://doi.org/>

10.1055/s-0042-1750366.

ISSN 2193-6358.

© 2022. The Author(s).

This is an open access article published by Thieme under the terms of the Creative Commons Attribution-NonDerivative-NonCommercial-License, permitting copying and reproduction so long as the original work is given appropriate credit. Contents may not be used for commercial purposes, or adapted, remixed, transformed or built upon. (<https://creativecommons.org/licenses/by-nc-nd/4.0/>)

Georg Thieme Verlag KG, Rüdigerstraße 14, 70469 Stuttgart, Germany

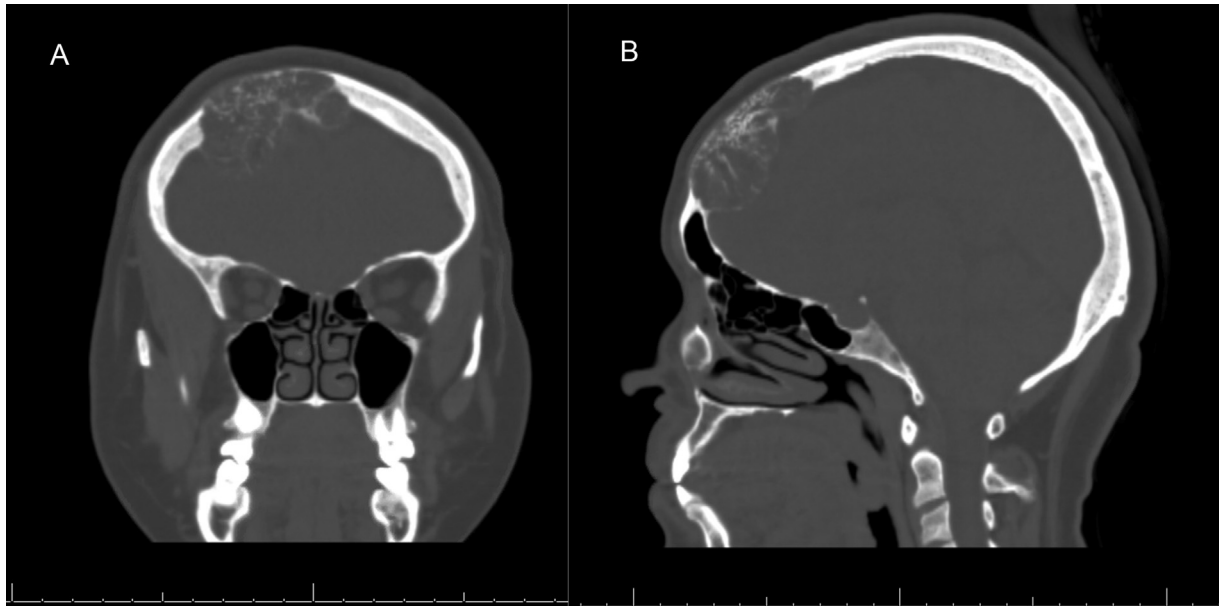


Fig. 1 Noncontrast computed tomography (CT) preoperative coronal (A) and sagittal (B) images displaying well-circumscribed mass with trabecular thickening.

outer tables of the right anterior frontal bone (►**Fig. 1**). A contrast-enhanced magnetic resonance imaging (MRI) of the lesion was obtained for better characterization, which demonstrated a heterogeneously enhancing lesion with T2 hyperintensity causing significant mass effect on the underlying brain parenchyma (►**Fig. 2**).

While the lesion was favored to represent an intraosseous hemangioma, metastasis remained on the differential. A CT of the chest, abdomen, and pelvis was obtained. The chest CT revealed a 2.4 × 3.3 cm right lateral breast mass most consistent with a hamartoma on follow-up mammogram. Given the size of the frontal lesion and associated mass effect on the underlying brain parenchyma, surgical resection of the lesion was recommended. She underwent evaluation for pre-

operative embolization to assist with resection of the lesion. During the diagnostic cerebral arteriogram, the anterior falcine artery was found to be the lesion's major blood supply and was secondarily supplied by a branch of the right superior temporal artery (STA). The anterior falcine artery had an anastomosis with the right ophthalmic artery, therefore endovascular embolization was not further pursued given the risk of postprocedural blindness.

The patient was taken to the operating room for surgical intervention. A bicoronal incision was made (►**Fig. 3**), and the branch of the STA found angiographically to be supplying the lesion was cauterized. After adequate exposure was obtained, a 5-mm diamond burr was used to create a full-thickness trough around the lesion. The tumor was then

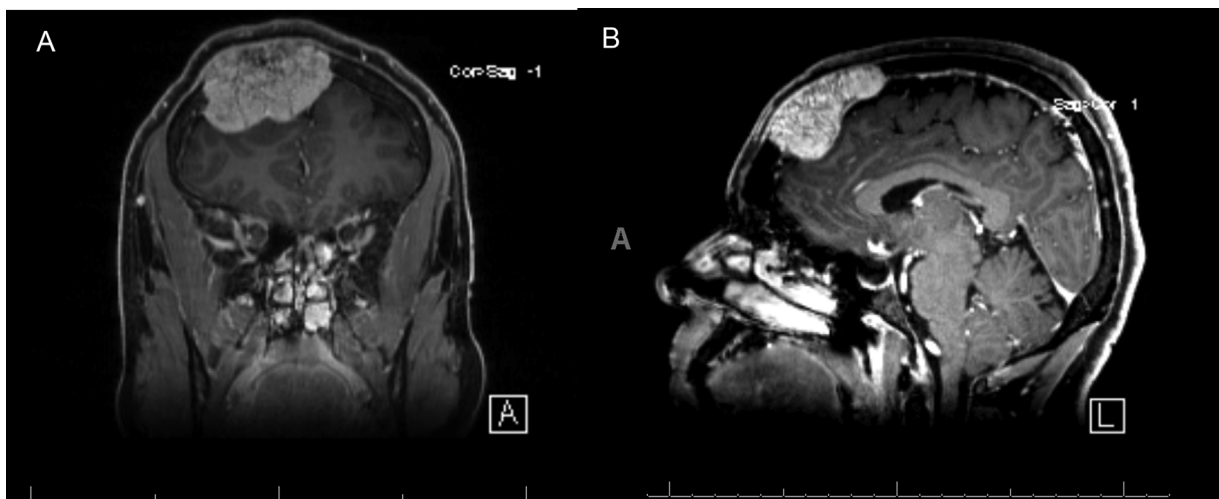


Fig. 2 Preoperative T1-weighted postcontrast magnetic resonance imaging demonstrating large heterogeneously enhancing extra-axial lesion with mass effect on the underlying brain parenchyma. Representative coronal (A) and sagittal images (B).

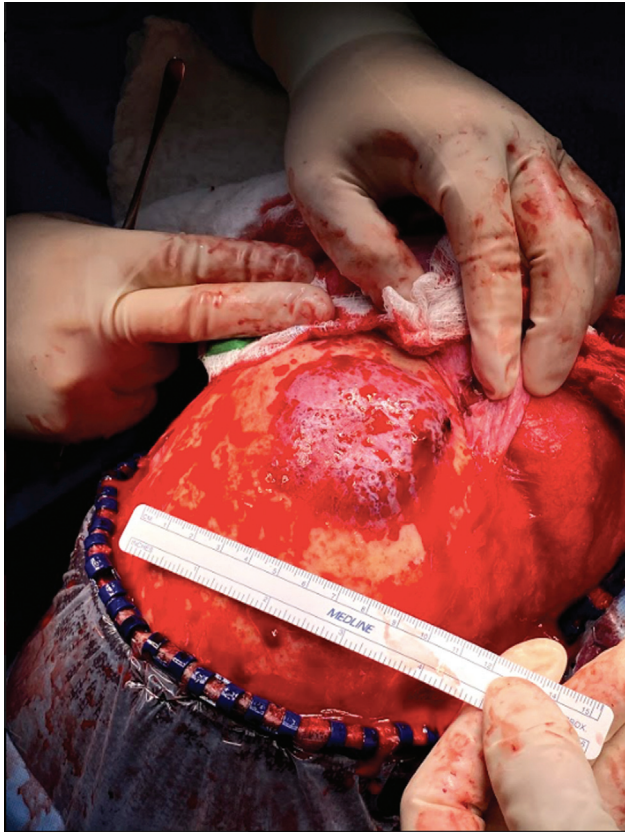

Fig. 3 Intraoperative exposure of large frontal bone lesion utilizing a bicoronal incision.

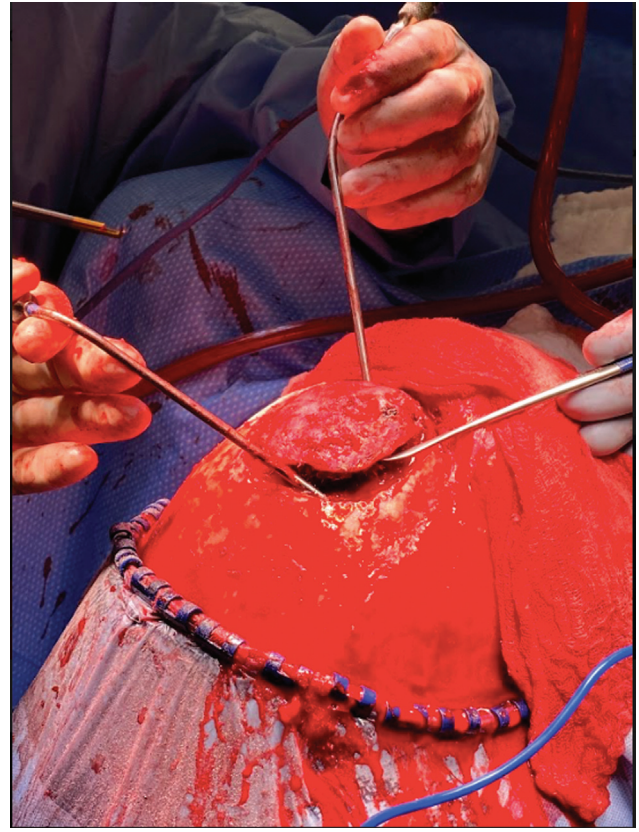


Fig. 4 Intraoperative elevation of frontal bone lesion revealing intradural extension of tumor and adherence to underlying brain parenchyma.

elevated and noted to be extending intradurally with adherence to the underlying brain parenchyma (→ **Fig. 4**). The bulk of the tumor was removed to better visualize the intradural component, as it was deemed unsafe to remove the mass in an en bloc fashion (→ **Fig. 5**). The remainder of the tumor was gently dissected from the underlying cortex and removed in a piecemeal fashion. A dural patch was sewn in and a temporary titanium mesh cranioplasty was placed. The final pathologic diagnosis confirmed intraosseous hemangioma.

Postoperatively, a thin-cut CT was obtained to design a custom polymethyl methacrylate implant. The patient returned to the operating room 3 weeks later for removal of the titanium mesh and placement of the permanent implant (→ **Fig. 6**).

Discussion

Intraosseous cavernous hemangiomas are benign vascular tumors. They present as firm, solitary masses that slowly progress over months or years.^{1,2,4,6–11,13,15,16,19,20,25,28,33,34} Intracranial extension of a calvarial based intraosseous hemangioma is an infrequent occurrence.^{1–3,5,13,14,19,20} Few prior reports have noted expansion of these lesions beyond the dural plane.^{2,8,11,13,24} Park et al and Khanam et al describe patients with intracranial expansion loosely attached to the dura, while Peterson et al describe a patient with extension through the dura and anastomoses with the thin-walled vessels on the surface of the cerebellum.^{8,11,13} Further, Nasi et al describe a

case with complete erosion of the dural plane and invasion of the subdural space.² Similar to our patient, these cases consisted of a progressive mass with dural involvement and mass effect. To our knowledge, no specific factors have been identified that correlate with internal expansion of these lesions.

The treatment of choice is en bloc resection with 5 to 10 mm wide bone margin for the primary goals of limiting painful progression, improving cosmesis, and avoiding potential complications such as hemorrhage.^{1,2,4,5,7–9,11–14,17,19,20,25,34,35} Utilization of preoperative embolization can be considered to aid surgical resection by decreasing intraoperative blood loss.^{7,10,20,25}

Following surgical resection, the remaining cranial defect must be reconstructed which is particularly challenging with large lesions and those involving the forehead. We propose a staged approach as an option to optimize postoperative cosmesis, particularly for lesions involving the forehead. Several preoperative and technical nuances were helpful in this case. The first is preoperative angiography, which while unable to embolize the main anterior cerebral artery feeder, identified the branch of the STA that supplied substantial blood flow to the lesion. Given that the authors typically spare the STA if at all possible, this led to a more efficient surgical case when it was sacrificed during lesion exposure. Second, the use of a diamond drill bit to decrease intraoperative blood loss. Given the intrinsically hemorrhagic nature of these lesions, use of a diamond bur provided hemostatic capacity while allowing for debulking of the lesion.

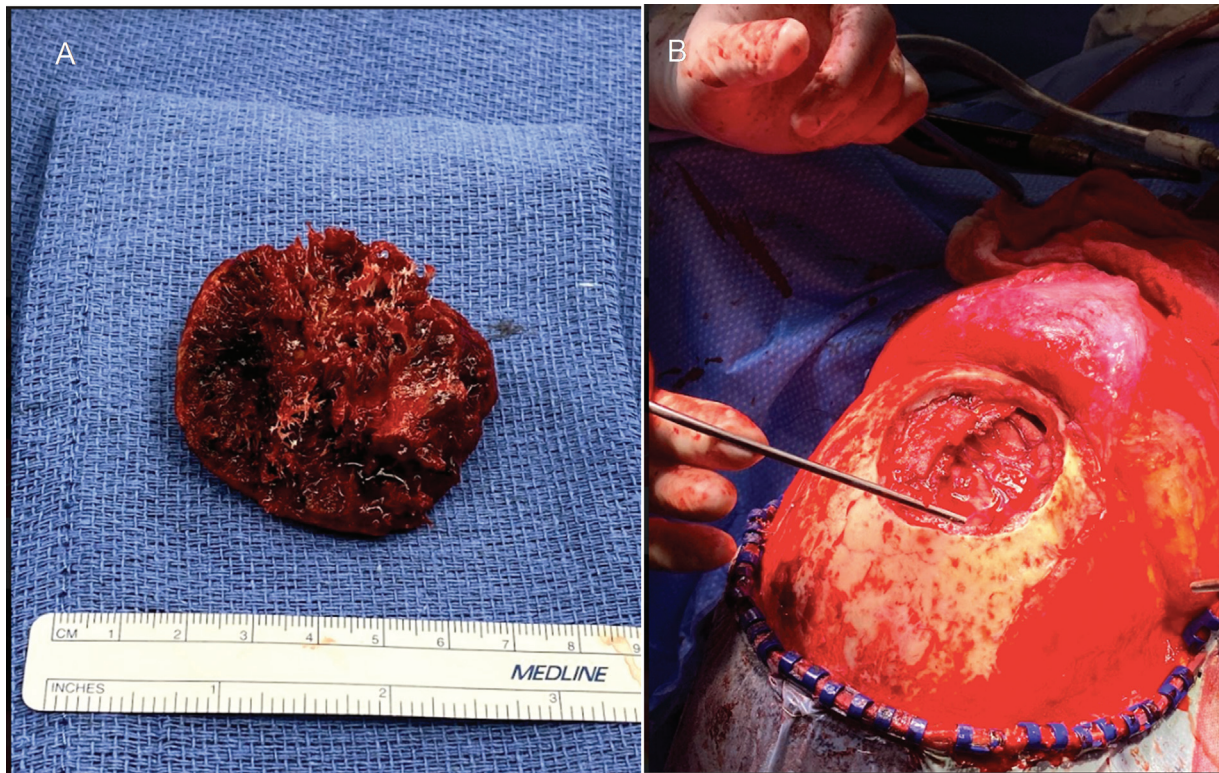


Fig. 5 Intraoperative photos display resected bulk of frontal bone tumor (A) and the resection cavity with the exposed underlying brain parenchyma (B).

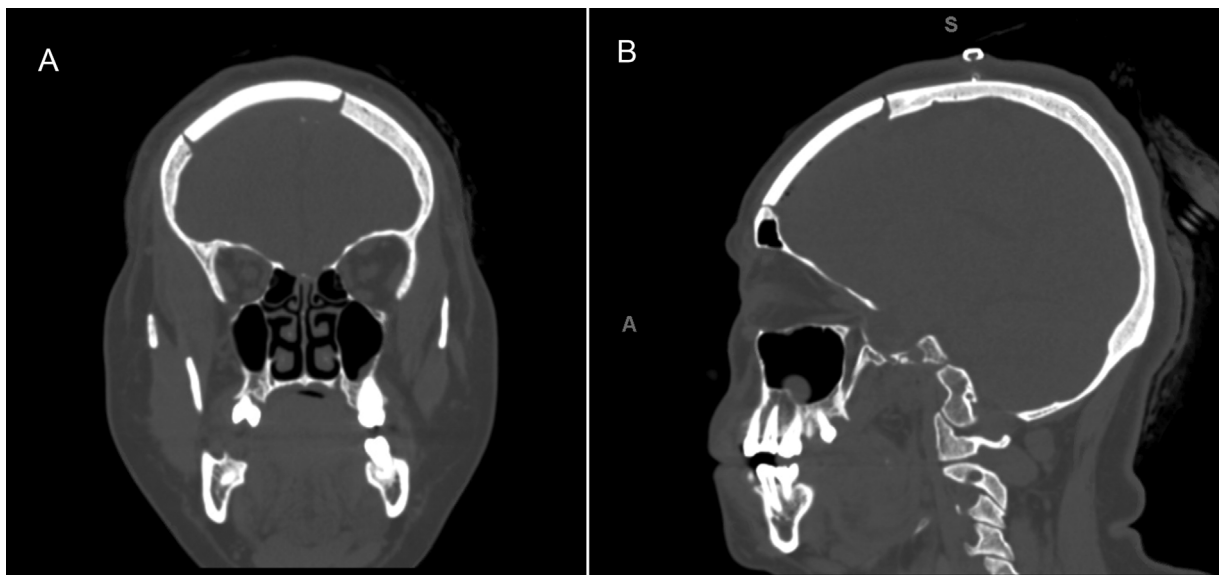


Fig. 6 Postoperative computed tomography (CT) coronal (A) and sagittal (B) images after placement of permanent implant 3 weeks after the initial resection.

Conclusion

The patient did very well postoperatively with a good cosmetic and neurologic outcome. An MRI obtained at 6 months postoperatively demonstrated no evidence of tumor recurrence. While rare, intraosseous cavernous hemangiomas can involve the inner table and have intradural expansion making an en

bloc resection a more challenging surgical treatment strategy. In these cases, removal in a piecemeal fashion should be considered to minimize the risk of injury to the underlying brain parenchyma and vascular structures. Proper reconstruction is critical for achieving a good cosmetic outcome, and a staged reconstruction with a custom-made implant can be considered for large lesions and those involving the forehead.

Funding

This research was funded by the Eugene P. Frenkel, M.D. Scholar in Clinical Medicine Endowment (to K.G.A.). The University of Texas Southwestern Medical Center – Dallas holds a Physician-Scientist Institutional Award from the Burroughs Wellcome Fund (to C.E.B.).

Conflict of Interest

None declared.

Informed Consent

We obtained informed consent from the patient for the use of imaging and intraoperative photographs. Institutional review board approval was waived as this case report did not meet the criteria for regulated research set by the department of Health and Human Services.

References

- Sáenz AA, Porto NF, Sánchez MP. Intraosseous cavernous hemangioma: presentation of a clinical case. *Egyptian J Neurosurg* 2018; 33(01):22
- Nasi D, Somma Ld, Iacoangeli M, et al. Calvarial bone cavernous hemangioma with intradural invasion: an unusual aggressive course-case report and literature review. *Int J Surg Case Rep* 2016;22:79–82
- Kirman AR, Sarmast AH, Bhat AR. A unique case of calvarial hemangioma. *Surg Neurol Int* 2016;7(Suppl 14):S398–S401
- Cheng NC, Lai DM, Hsieh MH, Liao SL, Chen YB. Intraosseous hemangiomas of the facial bone. *Plast Reconstr Surg* 2006;117(07):2366–2372
- Uemura T, Sawai K, Kikuchi M, Masuoka J, Matsushima T. Technical strategies for en bloc resection and immediate reconstruction in hemangioma of the frontal bone. *J Craniofac Surg* 2014;25(04):e402–e403
- Valentini V, Nicolai G, Lorè B, Aboh IV. Intraosseous hemangiomas. *J Craniofac Surg* 2008;19(06):1459–1464
- Seo BF, Kang KJ, Jung SN, Byeon JH. Skeletal cavernous hemangiomas of the frontal bone with orbital roof and rim involvement. *Arch Craniofac Surg* 2018;19(03):214–217
- Peterson DL, Murk SE, Story JL. Multifocal cavernous hemangioma of the skull: report of a case and review of the literature. *Neurosurgery* 1992;30(05):778–781, discussion 782
- Naama O, Gazzaz M, Akhaddar A, et al. Cavernous hemangioma of the skull: 3 case reports. *Surg Neurol* 2008;70(06):654–659
- Liu JK, Burger PC, Harnsberger HR, Couldwell WT. Primary intraosseous skull base cavernous hemangioma: case report. *Skull Base* 2003;13(04):219–228
- Park BH, Hwang E, Kim CH. Primary intraosseous hemangioma in the frontal bone. *Arch Plast Surg* 2013;40(03):283–285
- Murrone D, De Paulis D, Millimaggi DF, Del Maestro M, Galzio RJ. Cavernous hemangioma of the frontal bone: a case report. *J Med Case Reports* 2014;8:121
- Khanam H, Lipper MH, Wolff CL, Lopes MBS. Calvarial hemangiomas: report of two cases and review of the literature. *Surg Neurol* 2001;55(01):63–67, discussion 67
- Davis E, Morgan LR. Hemangioma of bone. *Arch Otolaryngol* 1974; 99(06):443–445
- Cervoni L, Artico M, Delfini R. Intraosseous cavernous hemangioma of the skull. *Neurosurg Rev* 1995;18(01):61–64
- Hornblass A, Zaidman GW. Intraosseous orbital cavernous hemangioma. *Ophthalmology* 1981;88(12):1351–1355
- Bravo-Martinez A, Marrero-Gonzalez AP, Suleiman-Suleiman MN, Vicenty-Padilla JC, Trullenque-Martinez E. Radiologic features with pathologic correlation of an unusual large intraosseous skull cavernous hemangioma. *Am J Case Rep* 2019;20:525–530
- Yu J, Li Y, Duan X. Posttraumatic cavernous hemangioma of the skull. *J Craniofac Surg* 2014;25(01):e48–e51
- Vernet O, Bernasconi A, Fankhauser H. Cavernous hemangioma of the frontal bone: a case report. *Turk Neurosurg* 1993;3(03): 118–121
- Faerber TH, Hiatt WR. Hemangioma of the frontal bone: review of the literature and report of a case. *J Oral Maxillofac Surg* 1991;49(09):1018–1022
- Suzuki Y, Ikeda H, Matsumoto K. Neuroradiological features of intraosseous cavernous hemangioma—case report. *Neurol Med Chir (Tokyo)* 2001;41(05):279–282
- Clauser L, Mandrioli S, Polito J, Galiè M. Surgical techniques for the removal of forehead hemangioma. *J Craniofac Surg* 2006;17(04): 702–704
- Dörner L, Buhl R, Hugo HH, Jansen O, Barth H, Mehdorn HM. Unusual locations for cavernous hemangiomas: report of two cases and review of the literature. *Acta Neurochir (Wien)* 2005; 147(10):1091–1096, discussion 1096
- Sharma A, Singh UR, Sihag P. Frontal bone hemangioma in an 8-year-old female: a common tumor in a rare location. *J Neurosci Rural Pract* 2016;7(Suppl 1):S91–S93
- Prasad GL, Pai K. Pediatric cranial intraosseous hemangiomas: a review. *Neurosurg Rev* 2018;41(01):109–117
- Gupta SD, Tiwari IN, Pasupathy NK. Cavernous haemangioma of the frontal bone: case report. *Br J Surg* 1975;62(04):330–332
- Dutta M, Jotdar A, Kundu S, Mukhopadhyay S. Primary cavernous haemangioma of the frontal bone: computed tomography features. *J Clin Diagn Res* 2015;9(12):MJ01–MJ02
- Singh U, Kalavakonda C, Venkitachalam S, Patil S, Chinnusamy R. Intraosseous hemangioma of sella: case report and review of literature. *World Neurosurg* 2019;3:100030
- Tang Chen YB, Wornom IL III, Whitaker LA. Intraosseous vascular malformations of the orbit. *Plast Reconstr Surg* 1991;87(05): 946–949
- Heckl S, Aschoff A, Kunze S. Cavernomas of the skull: review of the literature 1975–2000. *Neurosurg Rev* 2002;25(1-2):56–62, discussion 66–67
- Hsiao IH, Cho DY, Liu CL. Multifocal osteolytic lesions of the skull: a primary cavernous hemangioma mimicking a neoplastic invasive lesion. *Biomedicine (Taipei)* 2015;5(02):12
- Yang Y, Guan J, Ma W, et al. Primary intraosseous cavernous hemangioma in the skull. *Medicine (Baltimore)* 2016;95(11):e3069
- Wang T, Pham A, Yoo S, et al. Identifying disparities in care in treating glioblastoma: a retrospective cohort study of patients treated at a safety-net versus private hospital setting. *World Neurosurg* 2020;137:e213–e220
- Wang C, Zhang D, Wang S, Zhang Y, Wang R, Zhao J. Intraosseous cavernous malformations of the skull: clinical characteristics and long-term surgical outcomes. *Neurosurg Rev* 2020;43(01):231–239
- Yousif S, Lampe G, Pattavilakom A. Large frontal osseous hemangioma with dural sinus involvement in a patient with Klippel-Trenaunay syndrome: a rare case report. *Surg Neurol Int* 2018; 9:205