

# Ovarian Cancer Immature Teratoma Type in Pregnancy: Management and Feto-Maternal Outcomes

Lany Christina Prajawati Ni Luh<sup>\*</sup>, Bayu Mahendra I Nyoman, Putra Wiradnyana AAG, Ariawati Ketut, Sri Mahendra Dewi I Gusti Ayu

*Department of Obstetrics and Gynaecology, Pediatrics, Anatomical Pathology, Medical Science Faculty of Udayana University, Sanglah Hospital, Bali, Indonesia*

## Abstract

**Citation:** Ni Luh LCP, I Nyoman BM, AAG PW, Ketut A, I Gusti Ayu SMD. Ovarian Cancer Immature Teratoma Type in Pregnancy: Management and Feto - Maternal Outcomes. Open Access Maced J Med Sci. 2019 Mar 30; 7(6):1016-1020. <https://doi.org/10.3889/oamjms.2019.129>

**Keywords:** Pregnancy; BEP chemotherapy; Premature ovarian failure (POF); Surgical staging; Immature teratoma

**\*Correspondence:** Lany Christina Prajawati Ni Luh. Department of Obstetrics and Gynaecology, Pediatrics, Anatomical Pathology Medical Science Faculty of Udayana University/Sanglah Hospital, Bali, Indonesia. E-mail: lanychristina2@yahoo.com

**Received:** 18-Dec-2018; **Revised:** 08-Mar-2019; **Accepted:** 09-Mar-2019; **Online first:** 15-Mar-2019

**Copyright:** © 2019 Lany Christina Prajawati Ni Luh, Bayu Mahendra I Nyoman, Putra Wiradnyana AAG, Ariawati Ketut, Sri Mahendra Dewi I Gusti Ayu. This is an open-access article distributed under the terms of the Creative Commons Attribution-NonCommercial 4.0 International License (CC BY-NC 4.0)

**Funding:** This research did not receive any financial support

**Competing Interests:** The authors have declared that no competing interests exist

**BACKGROUND:** Immature teratoma is malignant ovarian germ cell tumours (MOGCTs). The case in pregnancy is very rare which less than 1% of all ovarian teratoma cases. The aim is to reach optimal and comprehensive management for immature ovarian teratoma in pregnancy to gain the healthiest maternal and fetal outcomes.

**CASE PRESENTATION:** Thirty-one years old female G2P1A0, 8 weeks 1-day pregnancy, with left ovarian solid tumour 15 x 15 x 15 cm in size. At gestational age (GA) of 19 weeks 5 days, the size of the tumour was increasing rapidly to 30 x 30 x 30 cm. Alfa-fetoprotein raised to 699.9 IU/mL and LDH 579 U/L. The patient had gone primary conservative left oophorectomy, omentectomy, and ascites fluid cytology with histopathological conclusion grade II immature teratoma of left ovary containing the immature neuroepithelial and fat component: magnetic resonance imaging (MRI) at 25 weeks 3 days GA, no spreading. Amniocentesis performed at 27 weeks 2 days GA, the fetus had normal 46 chromosomes and sex XX without major structural abnormality. The patient had BEP chemotherapy start at 27 weeks 2 days GA. Patient in labour at 40 weeks 2 days GA. The female baby had spontaneous delivery with 2700 grams in body weight without congenital abnormality. Complete surgical staging performed at 58th days postpartum and histopathological result there was no malignant cell anymore, but post-chemotherapy ovarian atrophy feature had found on the contralateral ovary. The patient showed psychosocial problem including post-chemotherapy depression and premature ovarian failure (POF). Immunohistochemistry (IHC) ER and PR of teratoma tissue showed immature component had ER (-) and PR (+). Follow up of the baby was in good condition.

**CONCLUSION:** BEP chemotherapy become regimen choice for this case with fetal outcomes was good, but there was a POF sign on the mother. Survival of patient on this case is 62%, free recurrence survival post-BEP 84% and progressivity post complete surgical staging 8% without delay the chemotherapy.

## Introduction

Malignant Ovarian Germ cell tumours (MOGCTs) is ovarian primordial cells origin, the most common is dysgerminoma, the second is immature teratoma, and the third is yolk sac tumour. The incidence of MOGCTs in pregnancy is very rare, 1 in 12,500-25,000 of all pregnancy [1].

Immature teratoma is teratoma which contains embryonal neuroectodermal tissue component. The incidence of immature teratoma in pregnancy is considered as < 1% of all ovarian teratoma cases which occur in the first three decades of life and reproductive period. The incidence of

immature teratoma in 2017 at Sanglah Hospital Denpasar – Bali was very rare, from 5 cases just 1 case in pregnancy.

The incidence of immature teratoma in pregnancy is very rare which cause a rare consensus about its management strategy. Pregnancy which occurs at the same time with immature teratoma type ovarian cancer will arise vice-versa effects both directly or indirectly for the pregnancy itself, fetus, and the progressivity of immature teratoma. The multidisciplinary approach involves oncologist, pathologist, and perinatologist is needed for early diagnosis, definitive operation procedure, chemotherapy choice, management of delivery, perinatology management, long-term follow up of

maternal and fetal chemotherapy effects, and the necessity of complete surgical staging relaparotomy and evaluation the possibility of metastasis.

## Case Illustration

Thirty-one-year-old female, G2P1A0, 8 weeks 1 day GA, with solid ovarian tumour 15 x 15 x 15 cm in size. At 19 weeks 5-day GA, the tumour size became 30 x 30 x 30 cm, solid, rough surface, mobile, and painful. Tumour marker was raising, AFP 699.9 IU/mL and LDH 579 U/L. The patient had conservative primary surgery (left oophorectomy, omentectomy, and ascites fluid cytology). Midline incision performed, Durante operation evaluation with minimal uterus manipulation and seen solid mass 40 x 40 x 40 cm in size, rough surface, left ovary origin, omental attach then adhesiolysis done, rupture, and successfully removed. Internal abdominal organ evaluation: uterus corresponding 18-20 weeks GA, right and left Fallopian tube, right ovary, peritoneum, omentum, and liver normal. Histopathological concluded grade II immature teratoma of the left ovary with the neuroepithelial and fat immature component.

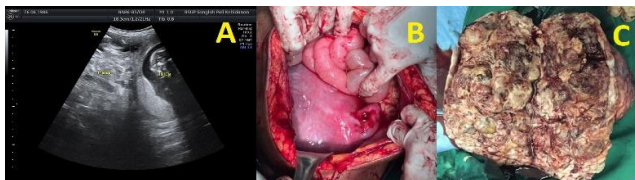

Figure 1: Ultrasonography and Macroscopy of Immature Teratoma Durante Operation. A. Left adnexal mass hypohyperechoic with size that cannot reach by the probe at 19 weeks 5 day GA; B. Uterus size corresponding with 18-20 weeks GA, left Fallopian tube normal, post-oophorectomy; C. Lobulated solid mass with multiseptate cystic inside it.

Patient management post-primary conservative surgery was contrasted MRI at 25 weeks 3 day GA with the result there was no spreading. Chromosome analysis (amniocentesis) at 27 weeks 2 day GA with the result the number of chromosome 46, XX, and not seem abnormality. It was decided to perform 4 cycles BEP chemotherapy administration, started at 27 weeks 2 day GA and stopped 2 weeks before labour (37 weeks 6 day GA) with regular fetomaternal USG evaluation (fetal scanning and fetal well being) every 2 weeks post chemotherapy, not found abnormality, and regular non stress test (NST) at GA > 34 weeks show reactive result.

The pregnancy continued until at term; the female baby was born at 40 weeks 2 day GA, 2700 gram, spontaneous *pervaginam*, APGAR score 7-8, not seen a congenital abnormality. Placental metastasis can occur even though it is very unlikely; the incidence has reported since 1866 just less than 80 cases [2]. It will be better if the placenta is keep

being evaluated pathologically, to exclude metastasis. The evidence of fetal metastasis has reported to date just 11 cases [2]. In this case, the placenta was seemed complete born, histopathological examination of the placenta and the amniotic membrane was performed, not seen immature teratoma cell invasion. The postpartum condition of the mother was good and followed up of the baby condition not found the sign of transient myelosuppression, IUGR (the baby born with weight 10%-25% at percentile), no congenital abnormality, no abdominal mass, and the level of AFP in the normal range.

Supporting investigation at 1 week postpartum not found any signs of transient myelosuppression that is leucopenia (WBC count < 5000/mm<sup>3</sup>), neutropenia (absolute neutrophil count < 1500/mm<sup>3</sup>), anaemia, thrombocytopenia (PLT count < 15.000/mm<sup>3</sup>). The baby has WBC count 17,230/mm<sup>3</sup>; hemoglobin 21.41 g/dL; Neutrophil 3,240/mm<sup>3</sup>; platelets 276,600/mm<sup>3</sup>. Alpha-fetoprotein of the patient > 5000 IU/mL which still in normal range (normal level for 2 weeks postpartum: 33.113 IU/mL), it is suggested for routine AFP follow up every month for 2 years. The patient was not suggested to breastfeeding at the chemotherapy period. The patient was not suggested to breastfeeding at the chemotherapy period.

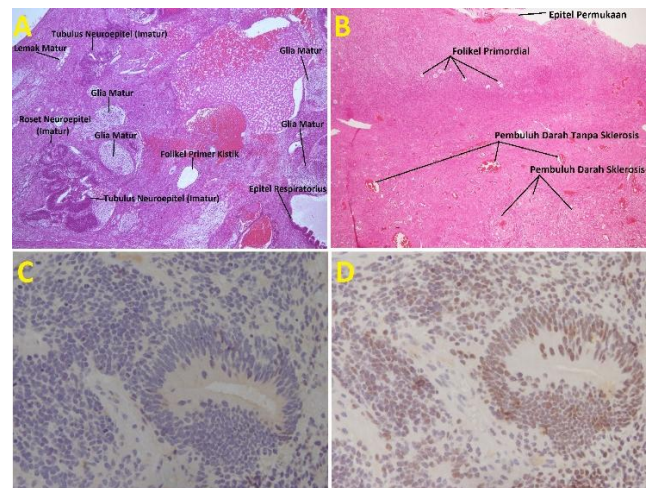


Figure 2: Histopathology of Left Ovarian Immature Teratoma and Atrophy of Right Ovary. A. Immature neuroepithelial component (40 X magnification); B. Cortex contain primordial follicle depletion which some of it did not contain oocyte and blood vessels sclerosis (40X magnification); C. IHC ER-negative and D. IHC PR positive on neuroepithelial component (100 X magnification)

Relaparotomy complete surgical staging including TAH, salpingectomy *sinistra*, SOD, lymphadenectomy pelvic bilateral and paraaortic, omentectomy, also peritoneal biopsy (bilateral paracolic-prevesical-Douglas cavity) performed at 58<sup>th</sup> days postpartum. The result of histopathological examination there was no malignant cell and metastasis.

The patient shows the psychological signs of POF including frightening and worry, irritability feeling,

easy to mad, hard to concentrate, behaviour changes, depression, libido disturbance, and FSH level 50.01 mU/L at post relaparotomy complete surgical staging. The result of histopathological examination of right ovary (contralateral) show ovarian atrophy. Immunohistochemistry to detect (estrogen receptor) ER and progesterone receptor (PR) were performed on left ovarian tumour (immature teratoma), with conclusion ER (-) and PR (+), so hormonal replacement therapy (HRT) can be given to managing POF signs with the possibility of tumour to relapse due to hormonal administration is low.

## Discussion

The increasing of serum tumour marker during pregnancy often associated with the physiology of normal pregnancy. Tumour markers for diagnosis of the solid ovarian tumour are alpha-fetoprotein (AFP), CEA, LDH, CA19-9, and  $\beta$ -HCG. Immature teratoma often associated with the increasing of AFP and LDH [3]. Imaging for diagnosis of ovarian cancer including USG which have sensitivity 90%, specificity 87%, positive predictive value (PPV) 69% and negative predictive value (NPV) 97% in define of malignancy suspected ovarian mass [4]. Magnetic Resonance Imaging (MRI) performed if the diagnosis of USG is uncertain or to evaluate the spreading outside of the ovary. The using of MRI with contrast gadolinium-based is saved during second and third trimester; it proved to have no mutagenic or teratogenic effects [5].

Alpha-fetoprotein is increased in part of a patient with pure immature teratoma which from embryogenic cells, but  $\beta$ -HCG is not increased [6]. In this patient the AFP level 699.9 IU/mL (normal level of AFP at second trimester 22-93 IU/mL), LDH: 579 U/L (normal level at second trimester: 240-480), CEA: 12.43 ng/mL, CA 19-9 216 U/mL. During pregnancy, AFP is produced by the fetal yolk sac and then continued by the liver and gastrointestinal tract, the high level of AFP is suspected for the existence of neural defect abnormalities such as spina bifida, anencephaly, oesophageal defect, the failure of babies abdominal closing, and trisomy 21. Amniocentesis most accurate performed at 16 to 18 weeks of gestational age [7], [8]. The patient had an amniocentesis at 27 weeks 2 days of gestational age for indication of the raising of AFP and searching congenital and also the chromosomal abnormality of the baby. If there is lethal anomaly abnormality, the pregnancy suggested being terminated. The result of amniocentesis analysis was not found chromosomal abnormality, the number chromosome was 46 with fetal sex chromosome XX and was not seen any major structural abnormality, and the result of fetal scanning ultrasonography after 22 weeks gestational

age was not found major abnormality and the level of AFP gradually decrease after primary tumour removal until postpartum periods. The increasing of AFP level of the patient highly suspected from the primary tumour (germ cell).

Estrogen and progesterone are increased during pregnancy. High level of estrogen receptor (ER) is often found in ovarian cancer cells. Meanwhile, a tumour with positive progesterone receptor (PR) has a higher survival rate compared with negative PR tumour [8].

The effects of ovarian cancer to pregnancy can be direct or indirect — the direct factor which affected directly such the metastasis to placenta and fetus. Metastasis to the placenta is very rare; it incidence since 1866 have reported less than 80 cases and proved fetal metastasis until now just have been 11 cases [2]. The indirect effects are mediated by operative procedure and chemotherapy effects [3], [5], [8], [9].

### *Conservative Laparotomy Operation*

The side effect of surgery for the baby including exposure of anaesthetic agent, intrapartum and postpartum complication. The effect of anaesthetic agent administration that is hypoxia, hypotension, hypoglycemia, fever, pain, infection or thrombosis can cause serious side effects for the health of the baby. During surgery, it is necessary to minimalise the manipulation and retraction of the uterus to avoid decreasing of uteroplacental blood flow and separation of the placenta. Postpartum period needs adequate analgesic administration for pain can induce premature contraction [10].

The result of several studies, adnexal mass removal during pregnancy is safe enough for the mother and the baby [5]. The second trimester of pregnancy is 'safety period' or the best moment for performing surgery intervention of adnexal mass because at this period the dependency of hormonal secretion from corpus luteum during pregnancy is decreased so that the risk of spontaneous abortion is low [2], [5], [11]. There was a tocolytic administration consensus, the tocolytic agent can be given before or immediately after surgery and to be continued 24 to 48-hour post-surgery [12]. Routine tocolytic administration still controversial, but the administration can be considered if there are signs of preterm labour [7], [13]. Tocolytic has benefit on ovarian tumour surgery, from 28 cases is proved that 86% of it had not found any uterine contraction and Mathevet, et. al., (2003) reported that 48 laparoscopy cases at first trimester (n = 17), second trimester (n = 27), and third trimester (n = 4), tocolytic administration just for the indication of ovarian torsion, rupture of cyst, or persistent mass removal. The result showed minimal risk to the mother and the baby with the surgical technique and supporting expert experiences as

consideration. On the cases without tocolytic before or after surgery was not found the signs of preterm labour postoperative. It is necessary to perform minimal manipulation of uterine to prevent contraction.

Adnexal mass detected at trimester I or low malignancy suspected is managed by conservative (observation). But, septal mass, solid, papillary, nodular or persistent until 16 weeks of GA, surgery delay until trimester II (16-18 weeks GA) due to spontaneous abortion risk can reach 10%. Other surgery indications are acute abdomen: pain, rupture, and torsion [13]. Retrospective study show conservative management have high morbidity and mortality due to cystic fluid spill caused by spontaneous rupture [14], [15].

Corticosteroid administration for fetal lung maturation performed a minimum of 48 hours before the operation when it did at 24-34 weeks GA [7]. Adnexal mass detected after 35 weeks GA removed at the same time with *section Caesarea* [5].

Primary conservative surgery at an early stage is unilateral *oophorectomy* or *cystectomy*, *omentectomy*, and peritoneal fluid cytology. In advanced stage (II-IV), the pregnancy considered to be terminated before 24 weeks GA followed by adnexal mass removing and chemotherapy. If the advanced stage tumour found at more than 24 weeks GA, it just performed a biopsy, and following chemotherapy cytoreduction delay until labour [16], [17]. Relaparotomy complete surgical staging or cytoreduction performed after 3-6 weeks *postpartum*.

without significant side effects for the fetus [20]. Chemotherapy administration at trimester I raise 10-20% the incidence of congenital malformation, fetal death, and spontaneous abortion [4], [5], [19]. Meanwhile, at trimester II and III, it raises the risk of IUGR (7%), low birth weight, preterm labour (5%), and stillbirth (5%). Chemotherapy after 35 weeks GA can raise the risk of neonatal neutropenia. At birth and first weeks of life can be found transient myelosuppression signs which can promote severe infection. At long term follow up can be found neurological development and psychological effects on the child.

The first choice chemotherapy combination for MOGCTs is 4 cycle every 3 weeks of *bleomycin-etoposide-cisplatin* (BEP). *Bleomycin-etoposide-cisplatin* has a recurrence-free survival rate of 84% [5]. The first side effects of BEP at trimester II: found 1 case cerebral atrophy accompanied by ventriculomegaly, 4 cases polyhydramnios and IUGR, nephrotoxic suspected induced by cisplatin and neonatal alopecia [20]. The second, liver damage which caused decreasing synthesis of plasma procoagulant proteins and anticoagulant including fibrinopeptide A protein, fibrinolytic, factor VIII and thrombocyte activator that can be activated disseminated intravascular coagulation/DIC, thrombosis, and also bleeding. The third, indirectly destroy primordial follicle reserve, oocyte, and ovarian stroma caused premature ovarian failure (POF). Fertility profile of female BEP patients: primordial follicle decrease and stromal fibrosis in cortical atrophy with 42% of a patient developing POF [15].

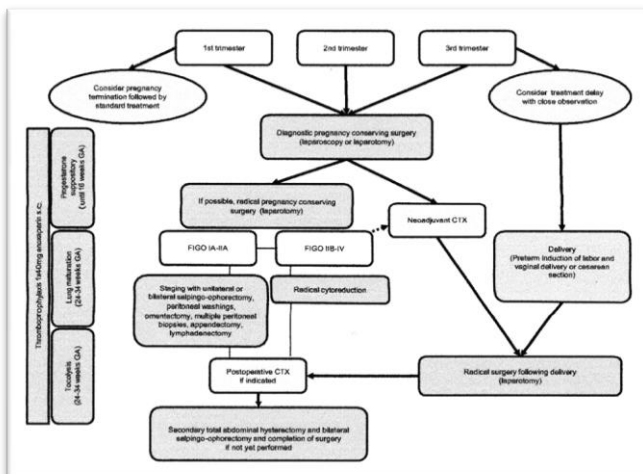


Figure 3: Surgery Management Algorithm of Ovarian Cancer in Pregnancy [18]

## Chemotherapy

The Society of Obstetricians and Gynecologist Canada (SOGC) recommended chemotherapy at trimester II with the period of teratogenesis at organogenesis as consideration, so the best time is  $\geq 12-14$  weeks or trimester III (until 35-37 weeks GA) [19]. Chemotherapy is given on the same dosage as a woman without pregnancy and it

Table 1: Cancer Therapy Choice Corresponding to Gestational Age [19]

	Surgery	Chemotherapy	Radiotherapy <sup>a</sup>
First trimester	Possible	Contraindicated	Possible with adequate shielding
Second trimester	Possible, consider intraoperative fetal heart rate monitoring $\geq 24-26$ weeks	Possible $\geq 12-14$ weeks	Possible with adequate shielding
Third trimester	Possible, consider intraoperative fetal heart rate monitoring	Possible, aim for 3-week interval between 3-weekly chemotherapy and delivery	Contraindicated <sup>b</sup>

## The Mode of Delivery

The optimal time to labour is after 35-37 weeks and 3 weeks post-chemotherapy to avoid accumulation of chemotherapy and to allow recovery from possible bone marrow suppression of both mother and baby [8]. Mode of delivery preference was spontaneous vaginal delivery rather than a caesarean section. The benefits of spontaneous delivery are related to less blood loss, less operative risk and reduced infection risk. Mother under chemotherapy is not recommended to breastfeed due to several chemotherapy regimens excreted through breast milk which could result in neonatal pancytopenia [19].

## Prognosis

A grade of immaturity predicted metastasis potency and prognosis. Five years survival rate is 82%, 62%, and 30% for grade 1, 2, and 3 respectively

in patients with grades 1, 2, and 3 treated with optimum chemotherapy, which it recurrence is 36% on 6 years follow up, and 50% of patient succeed reach term pregnancy after performing primary surgical. The progressivity of patients performing complete surgical staging 8 % without delay the chemotherapy [3]. Long term outcome of a study done in Mexico on 84 children who got affected by chemotherapy intrauterine due to their mother had cancer, not found congenital abnormality, development of neurology, cardiology, psychology and also disturbance in their marks at school [21].

In conclusion, the incidence of ovarian cancer in pregnancy is very rare. The choice of BEP chemotherapy, the time of operation and chemotherapy, regular follow up of fetal well-being will determine prognosis. Fetal outcome is good, but occur the signs of POF on the mother. Patients survival 62%, post-BEP free survival rate 84%, and progressivity post complete surgical staging 8% without delay chemotherapy.

## References

1. Health Department Republic of Indonesia. Pusat Data dan Informasi 2015, 2015.
2. Berek JS, Friedlander ML, Hacker NF. Germ Cell and Nonepithelial Ovarian Cancer In: Berek and Hacker's Gynecologic Oncology. 6th Edition. Philadelphia: Wolters Kluwer, 2015: 539-41.
3. Voulgaris E, Pentheroudakis G, Pavlidis N. Cancer and pregnancy: a comprehensive review. *Surgical oncology*. 2011; 20(4):e175-85. <https://doi.org/10.1016/j.suronc.2011.06.002> PMID:21733678
4. Robert JK, Lora HE, Brigitte MR. Blaustein's Pathology of the Female Genital Tract. Sixth Edition. New York: Springer, 2011.
5. Amant F, et al. Gynaecologic Cancer Complicating Pregnancy: An Overview. *Best Practice&Research Clinical Obstetrics and Gynaecology*. 2010; 24:61-79. <https://doi.org/10.1016/j.bpobgyn.2009.08.001> PMID:19740709
6. Ali MK, Abdelbadee AY, Shazly SA, Abbas AM. Adnexal torsion in the first trimester of pregnancy: A case report. *Middle East Fertility Society Journal*. 2013; 18(4):284-6. <https://doi.org/10.1016/j.mefs.2012.05.002>
7. de Haan J, Verheecke M, Amant F. Management of ovarian cysts and cancer in pregnancy. *Facts, views & vision in Ob Gyn*. 2015; 7(1):25-31. PMID:25897369 PMCID:PMC4402440
8. Jeon SY, Hwang KA, Choi KC. Effect of steroid hormones, estrogen and progesterone, on epithelial mesenchymal transition in ovarian cancer development. *The Journal of steroid biochemistry and molecular biology*. 2016; 16: 1-32. <https://doi.org/10.1016/j.jsbmb.2016.02.005> PMID:26873134
9. Koren G, Carey N, Gagnon R, Maxwell C, Nulman I, Senikas V. Cancer chemotherapy and pregnancy. *SOGC Clinical Practice Guideline*. 2013; 288:263-78. [https://doi.org/10.1016/S1701-2163\(15\)30999-3](https://doi.org/10.1016/S1701-2163(15)30999-3)
10. Shaaban AM, Rezvani M, Elsayes KM, Baskin Jr H, Mourad A, Foster BR, Jarboe EA, Menias CO. Ovarian malignant germ cell tumors: cellular classification and clinical and imaging features. *Radiographics*. 2014; 34:778. <https://doi.org/10.1148/rq.343130067> PMID:24819795
11. Budiana ING. Tumor Ovarium: Prediksi Keganasan Prabedah. *Jurnal Ilmiah Kedokteran*. 2013; 44:179-85.
12. Jain M, Budhwani C, Jain AK, Hazari RA. Pregnancy with ovarian dysgerminoma: an unusual diagnosis. *Journal of Dental and Medical Sciences*. 2013; 11(5):53-7. <https://doi.org/10.9790/0853-1155357>
13. Morice P, Uzan C, Gouy S, Verschraegen C, Haie-Meder C. Gynaecological cancers in pregnancy. *Lancet*. 2012; 379(9815):558-69. [https://doi.org/10.1016/S0140-6736\(11\)60829-5](https://doi.org/10.1016/S0140-6736(11)60829-5)
14. Ngu S, Cheung VY, Pun T. 2014. Surgical Management of Adnexal Masses in Pregnancy. *Journal of the Society of Laparoendoscopic Surgeons*. 2014; 18:71-5. <https://doi.org/10.4293/108680813X13693422521007>
15. Morgan S. How Do Chemotherapeutic Agents Damage the Ovary? Edinburgh: The University of Edinburgh, 2014.
16. Gui T, Cao D, Shen K, Yang J, Fu C, Lang J, Liu X. Management and Outcome Ovarian, 2013.
17. Gezginc K, Karatayli R, Yazici F, Acar A, Celik C, Capar M. Ovarian Cancer during Pregnancy. *International Journal of Gynecology and Obstetrics*. 2011; 115:150-3. <https://doi.org/10.1016/j.ijgo.2011.05.025> PMID:21872237
18. Kodama M, Grubbs BH, Blake EA, Cahoon SS, Murakami R, Kimura T, Matsuo K. Feto-maternal outcomes of pregnancy complicated by ovarian malignant germ cell tumor: a systematic review of literature. *European Journal of Obstetrics & Gynecology and Reproductive Biology*. 2014; 181:145-56. <https://doi.org/10.1016/j.ejogrb.2014.07.047> PMID:25150953
19. Anton C, Carvalho FM, Oliveira EI, Maciel GA, Baracat EC, Carvalho JP. A comparison of CA125, HE4, risk ovarian malignancy algorithm (ROMA), and risk malignancy index (RMI) for the classification of ovarian masses. *Clinics*. 2012; 67(5):437-41. [https://doi.org/10.6061/clinics/2012\(05\)06](https://doi.org/10.6061/clinics/2012(05)06)
20. Stavrou S, Domali E, Paraoulakis I, Haidopoulos D, Thomakos N, Loutradis D, Drakakis P. Immature Ovarian Teratoma in 21 Year-Old Woman. A Case Report and Review of the Literature. *J Gen Pract*. 2016; 4(2):1-4.
21. Shahzadi SH. Immature Placental Teratoma. Case Report. *J Postgrad Med Inst*. 2014; 28(3):324-7.