

Esophageal polyp as a posterior mediastinal mass: Intraoperative dynamic airway obstruction requiring emergency tracheostomy

Suvadeep Sen, Anjolie Chhabra, Arpita Ganguly¹, Dalim Kumar Baidya

Department of Anaesthesia and Intensive Care, All India Institute of Medical Sciences, ¹Department of Anaesthesia, Max Superspeciality Hospital, Saket, New Delhi, India

Abstract

Anesthesia in the presence of a mediastinal mass is difficult and challenging as the mass can involve or compress the heart, great vessels, tracheo-bronchial tree and the surrounding structures. We describe a case of severe tracheo-bronchial obstruction requiring emergency tracheostomy during the intraoperative period after an uneventful induction of anesthesia in a patient with a large esophageal polyp presenting as a posterior mediastinal mass.

Key words: Intraoperative dynamic airway obstruction, large esophageal polyp, posterior mediastinal mass

Introduction

A mediastinal mass can involve or compress the heart, great vessels, tracheobronchial tree, and other surrounding structures. Available literature describes cases of life-threatening respiratory or cardiovascular collapse which occurred during induction of anesthesia in patients with anterior mediastinal mass.^[1]

Case Report

A 24-year-old 52 kg male was diagnosed with esophageal polyp and posted for elective polypectomy via transcervical approach. On preoperative evaluation, there was history of dysphagia, pressure sensation in throat and exertional breathlessness grade II for last 3 months. The symptoms were unrelated to change in position. No history of hoarseness of

voice, congestion or puffiness of face, syncope, or palpitation was present. On examination, his pulse was 86/minute, blood pressure 110/70 mmHg and respiratory rate 20/minute. Airway examination was unremarkable.

Hematological and biochemical investigations were unremarkable. Chest X-Ray lateral view revealed a mass in the posterior mediastinum. Computed tomography (CT) scan of chest showed an intraluminal pedunculated polypoidal lesion of 10 × 4 cm size extending from upper end of esophagus to the junction of middle and lower third of esophagus with compression of lower end of trachea and both the bronchi. Tracheobronchial compression ratio was less than 50%. Preoperative flow volume study and esophagography were not done.

Sedative premedication was avoided. In the operating room, intravenous access was obtained; a flexible fiber-optic bronchoscope, a rigid bronchoscope, and tracheostomy set were kept ready. After adequate preoxygenation, anesthesia was induced with gradually increasing concentration of sevoflurane. After confirming bag and mask ventilation, inj. Succinylcholine 100 mg was administered and fiberoptic bronchoscope guided tracheal intubation was performed with 8.0-mm polyvinylchloride (PVC) endotracheal tube (ETT). The tip of the ETT was kept in the compressed lower end of the trachea. However, both the main bronchi were found to be compressed as well. But ventilation was adequate and airway pressure was normal. Two wide bore intravenous access and left radial artery canula were taken. Anesthesia

Address for correspondence: Dr. Dalim Kumar Baidya, Room number 507, 5th Floor, Academic Wing, CDER, All India Institute of Medical Sciences, New Delhi - 110 029, India. E-mail: dalimkumarb001@yahoo.co.in

Access this article online

Quick Response Code:



Website:
www.joacp.org

DOI:
10.4103/0970-9185.125715

was maintained with oxygen, air, isoflurane, morphine, and intermittent dose of vecuronium.

After an oblique cervical incision, esophagotomy was performed and the polyp was attempted to be pulled up. Initial 3-4 cm of the mass was exited smoothly but after that increasing resistance was encountered and the polyp could not be pulled up any further. Airway pressure increased from 18 to 42 cm H₂O. Manual ventilation was started. Any ETT kinking/obstruction, distal migration into the bronchus and bronchospasm were ruled out. Manual ventilation became increasingly difficult, end-tidal CO₂ reached 65-70 mm Hg and airway pressure 40-45 cm H₂O. Increased external compression of the tracheobronchial tree by the pulled up polyp was likely diagnosis. Attempts to push the mass back into the mediastinum with an expectation to relieve the obstruction also failed. Oxygen saturation decreased to 86%. Emergency tracheostomy was immediately performed which revealed a compressed ETT inside trachea; a gum-elastic bougie was introduced into the tracheostomy stoma and a reinforced flexometallic 8.0-mm ETT was advanced over the bougie forcibly to bypass the obstruction. Immediately airway pressure declined and SpO₂ improved. Rest of intraoperative course remained uneventful. The mass was successfully retrieved transcervically and resected [Figure 1]. His tracheostomy tube was decannulated after 2 weeks after ruling out any possible tracheomalacia.

Discussion

Clinical presentation of large pedunculated esophageal polyps include dysphagia, retrosternal or epigastric discomfort, odynophagia, vomiting, weight loss, respiratory symptoms such as persisting cough and shortness of breath and sometimes regurgitation of the mass from mouth.^[2] Feared complication

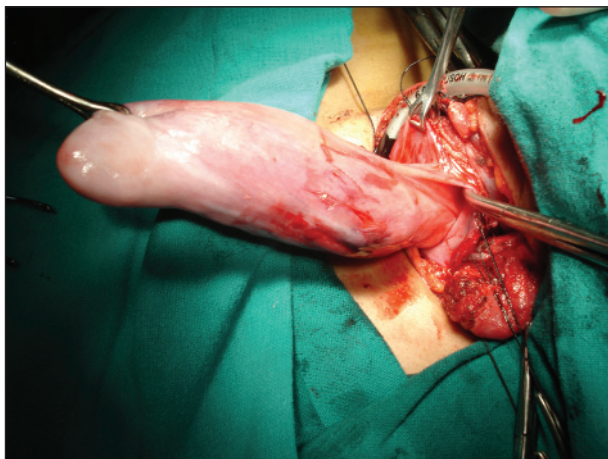


Figure 1: Large esophageal polyp taken out by transcervical route, flexible endotracheal tube seen passing through the tracheostomy stoma

is polyp aspiration and fatal asphyxiation.^[3] It can also lead to occult gastrointestinal bleeding due to ulceration of the polyp, and twisting of polyp may lead to hemorrhage and necrosis of the lesion.^[4] Diagnosis is made by endoscopy, barium swallow, CT scan, and magnetic resonance imaging. Resection of these lesions may be approached endoscopically or surgically through a transcervical or thoracotomy approach, depending on the location.^[5]

Anterior mediastinal tumors cause the most severe and often life-threatening complications relating to compression of the airways and vascular structures, particularly after induction of anesthesia.^[6] Although, posterior mediastinal masses have been suggested to carry a low risk of anesthetic complications^[6], hemodynamic, and respiratory decompensation upon induction of general anesthesia in a patient with posterior mediastinal mass has been reported.^[7]

The importance of appropriate preoperative evaluation and/or tests, risk of general anesthesia and the best treatment modalities in perioperative period in patients with anterior mediastinal mass have been elucidated in literature.^[5,6] The risk varies with the size, position and pathology of the mass, compression of surrounding structures, clinical compressive features, findings of imaging studies, nature of surgical procedures, and age of the patient whether pediatric or adult.^[8] Insufficient preoperative diagnosis, inadequate preoperative preparation or incorrect anesthetic technique can result in fatal outcome. These complications can occur while placing the patient in supine position, at the induction of anesthesia, at extubation and even a few days after extubation.^[6] Features of compressive symptoms are related to compression of structures like tracheobronchial tree, heart, great vessels, thoracic duct, recurrent laryngeal nerve, and phrenic nerve. Symptoms are graded mild, moderate, or severe according to the patient's tolerance of the supine position.^[9]

It is prudent to determine before surgery the position in which the patient experiences the fewest symptoms and to consider repositioning in the event of intraoperative cardiorespiratory compromise to the 'most comfortable' position. Even if the patient's history and clinical examination are reassuring, the administration of anesthesia cannot always be regarded as safe. Patients who showed no preoperative symptoms can also develop very severe complications perioperatively.^[10] Verification of possible cardiorespiratory compromise must, therefore, be supplemented by the use of additional tests. All patients with a mediastinal mass should have a chest radiograph and a CT scan prior to any surgical procedure. A cross-sectional tracheal area less than 50% of normal diameter on CT scan predict perioperative respiratory complications under general anesthesia.

The use of dynamic assessment techniques like awake fiberoptic tracheobronchoscopy and flow-volume loops can assist the estimation of possible respiratory decompensation. Determination of the flow volume curve (recumbent, sitting), and hence the dynamic expiratory and inspiratory airway flows, provides an indirect indication as to functional airway obstructions.^[9] But apart from sporadic case reports, studies of flow-volume loops have shown a poor correlation with the degree of airway obstruction.^[11] If the clinical or CT examination suggests hemodynamic compromise, transthoracic, or transesophageal echocardiography is indicated.

General anesthesia may be graded as: 'safe', 'uncertain', 'unsafe' depending on compressive symptoms and CT tracheobronchial compression percentage.^[9]

Induction of anesthesia in all cases of mediastinal mass should be gradual with short-acting medication with adequate control of respiratory and hemodynamic parameters. Induction should be done in position that is 'comfortable' (position with least hemodynamic and respiratory compromise) determined in preoperative visit. Patient with 'unsafe' category should undergo awake fiberoptic bronchoscope guided intubation. Any intra-operative life threatening event should be managed by either of the following manoeuvre:

1. Positioning patient to the direction with least compression by the tumor,
2. Rigid bronchoscopy and ventilation distal to obstruction,
3. Immediate sternotomy and surgical elevation of the mass of the great vessel,
4. Establishment of cardiopulmonary bypass (CPB) by femoral cannulations and extra-corporeal membrane oxygenation. In this context, though general recommendation is to cannulate femoral vessels preoperatively under local anesthesia,^[12] most of recent literature has questioned its acceptance due to controversial benefit.^[13]

In the present case there was no positional pressure symptom, CT scan showed posterior mediastinal mass with tracheobronchial compression less than 50%. Therefore, the patient was categorized as 'uncertain' in risk stratification. So we planned inhalational induction and fiberoptic bronchoscope-guided intubation. Rigid bronchoscope was kept ready. CPB was not prepared. Fiberoptic bronchoscopy was performed to place the tip of ETT in the compressed lower portion of the trachea. Since both the proximal bronchi were also compressed it was not possible to keep the tip of ETT distal to the compression. However, airway pressure and capnography were normal after intubation. When the mass was pulled up it further compressed the trachea and ETT inside the trachea got compressed and obstructed.

This resulted in sudden high airway pressure, difficulty in ventilation and subsequent desaturation. Emergency low tracheostomy and passage of bougie-guided reinforced ETT relieved the obstruction. Elective tracheostomy and placement of a reinforced ETT could be performed before induction of general anesthesia or after endotracheal intubation. This would have possibly prevented kinking and obstruction of ETT during transcervical retrieval of polyp. Target-controlled infusion using propofol, remifentanyl, or dexmedetomidine could be used for sedation during fiberoptic bronchoscope-guided intubation. This would avoid the use of muscle relaxants and ensure more safety.^[14,15] Tan PC *et al.*, reported fiberoptic intubation under dexmedetomidine sedation followed by anesthesia maintenance with dexmedetomidine, propofol, and sevoflurane to avoid muscle relaxants in a patient with retrosternal goitre with intrathoracic tracheal narrowing.^[15]

This case report highlighted a unique problem to a posterior mediastinal mass in an asymptomatic adult patient that led to an intraoperative potentially life-threatening airway obstruction due to surgical manipulation after an uneventful induction of anesthesia. We conclude that

1. A posterior mediastinal mass may demand the same cautious approach required for patients with anterior mediastinal mass,
2. A large esophageal polyp as a posterior mediastinal mass may cause severe respiratory obstruction even after uneventful induction and intubation in the intra-operative period particularly during surgical manipulation via transcervical approach and
3. In case of any mediastinal mass with the potential to cause such dynamic airway obstruction, reinforced endotracheal tube should be preferred and
4. This kind of cases should be performed with all due precautions and preferably in a cardiac center with CPB ready as backup.

References

1. Gothard JW. Anesthetic considerations for patients with anterior mediastinal masses. *Anesthesiol Clin* 2008;26:305-14.
2. Drenth J, Wobbes T, Bonenkamp JJ, Nagengast FM. Recurrent esophageal fibrovascular polyps: Case history and review of the literature. *Dig Dis Sci* 2002;47:2598-604.
3. Carrick C, Collins KA, Lee CJ, Prahlow JA, Barnard JJ. Sudden death due to asphyxia by esophageal polyp: Two case reports and review of asphyxial deaths. *Am J Forensic Med Pathol* 2005;26:275-81.
4. Blacha MM, Sloots CE, Van Munster IP, Wobbes T. Dysphagia caused by a fibrovascular polyp: A case report. *Cases J* 2008;1:334.
5. Caceres M, Steeb G, Wilks SM, Garrett HE Jr. Large pedunculated polyps originating in the esophagus and hypopharynx. *Ann Thorac Surg* 2006;81:393-6.
6. Bécharard P, Létourneau L, Lacasse Y, Côté D, Bussièrès JS. Perioperative cardiorespiratory complications in adults with

- mediastinal mass: Incidence and risk factors. *Anesthesiology* 2004;100:826-34.
7. Anderson DM, Dimitrova GT, Awad H. Patient with posterior mediastinal mass requiring urgent cardiopulmonary bypass. *Anesthesiology* 2011;114:1488-93.
 8. Takeda S, Miyoshi S, Akashi A, Ohta M, Minami M, Okumura M, *et al.* Clinical spectrum of primary mediastinal tumours: A comparison of adult and pediatric populations at a single Japanese institution. *J Surg Oncol* 2003;83:24-30.
 9. Erdős G, Tzanova I. Perioperative anaesthetic management of mediastinal mass in adults. *Eur J Anaesthesiol* 2009;26:627-32.
 10. Goh MH, Liu XY, Goh YS. Anterior mediastinal masses: An anaesthetic challenge. *Anaesthesia* 1999;54:670-4.
 11. Hnatiuk OW, Corcoran PC, Sierra A. Spirometry in surgery for anterior mediastinal masses. *Chest* 2001;120:1152-6.
 12. Tempe DK, Arya R, Dubey S, Khanna S, Tomar AS, Grover V, *et al.* Mediastinal mass resection: Femorofemoral cardiopulmonary bypass before induction of anesthesia in the management of airway obstruction. *J Cardiothoracic Vasc Anesth* 2001;15:233-6.
 13. Slinger P, Karsli C. Management of the patient with a large anterior mediastinal mass: Recurring myths. *Curr Opin Anaesthesiol* 2007;20:1-3.
 14. Tsai CJ, Chu KS, Chen TI, Lu DV, Wang HM, Lu IC. A comparison of effectiveness of dexmedetomidine versus propofol target-controlled infusion for sedation during fiberoptic nasotracheal intubation. *Anaesthesia* 2010;65:254-9.
 15. Tan PC, Esa N. Anaesthesia for massive retrosternal goitre with severe intrathoracic tracheal narrowing: The challenges imposed — A case report. *Korean J Anesthesiol* 2012;62:474-8.

How to cite this article: Sen S, Chhabra A, Ganguly A, Baidya DK. Esophageal polyp as a posterior mediastinal mass: Intraoperative dynamic airway obstruction requiring emergency tracheostomy. *J Anaesthesiol Clin Pharmacol* 2014;30:97-100.
Source of Support: Nil, **Conflict of Interest:** None declared.