



## Association of electrocardiographic markers with myocardial fibrosis as assessed by cardiac magnetic resonance in different clinical settings

George Bazoukis, Sebastian Garcia-Zamora, Göksel Çinier, Sharen Lee, Enes Elvin Gul, Jesús Álvarez-García, Gabi Miana, Mert İlker Hayıroğlu, Gary Tse, Tong Liu, Adrian Branchuk

**Specialty type:** Cardiac and cardiovascular systems

**Provenance and peer review:**

Unsolicited article; Externally peer reviewed.

**Peer-review model:** Single blind

**Peer-review report's scientific quality classification**

Grade A (Excellent): 0  
Grade B (Very good): 0  
Grade C (Good): C, C  
Grade D (Fair): 0  
Grade E (Poor): 0

**P-Reviewer:** Hamilton-Craig C, Australia; Tan X, China

**Received:** April 9, 2022

**Peer-review started:** April 9, 2022

**First decision:** May 31, 2022

**Revised:** May 31, 2022

**Accepted:** August 17, 2022

**Article in press:** August 17, 2022

**Published online:** September 26, 2022



**George Bazoukis**, Department of Cardiology, Larnaca General Hospital, Larnaca 6036, Cyprus

**George Bazoukis**, Department of Basic and Clinical Sciences, University of Nicosia Medical School, Nicosia 2414, Cyprus

**Sebastian Garcia-Zamora**, Department of Cardiology, Delta Clinic, Santa Fe 341, Argentina

**Göksel Çinier, Mert İlker Hayıroğlu**, Department of Cardiology, Dr. Siyami Ersek Thoracic and Cardiovascular Surgery Training and Research Center, Istanbul 34668, Turkey

**Sharen Lee**, Cardiovascular Analytics Group, Laboratory of Cardiovascular Physiology, Hong Kong 999077, China

**Enes Elvin Gul**, Division of Cardiac Electrophysiology, Madinah Cardiac Centre, Madinah 42351, Saudi Arabia

**Jesús Álvarez-García**, Department of Cardiology, Ramon y Cajal University Hospital, Madrid 28034, Spain

**Gabi Miana**, Telehealth Center of Hospital das Clínicas, Hong Kong 999077, China

**Gary Tse**, Kent and Medway Medical School, Canterbury, Canterbury CT2 7FS, United Kingdom

**Gary Tse**, Tianjin Key Laboratory of Ionic-Molecular Function of Cardiovascular Disease, Department of Cardiology, Tianjin Institute of Cardiology, Second Hospital of Tianjin, Tianjin Medical University, Tianjin 300211, China

**Tong Liu**, Department of Cardiology, The Second Hospital of Tianjin Medical University, Tianjin 300211, China

**Adrian Branchuk**, Department of Cardiology, Queen's University, Ontario K7L 3N6, Canada

**Corresponding author:** George Bazoukis, MD, PhD, Doctor, Department of Cardiology, Larnaca General Hospital, Inomenon Polition Amerikis, Larnaca 6036, Cyprus.

[gbazoukis@yahoo.gr](mailto:gbazoukis@yahoo.gr)

## Abstract

### BACKGROUND

Cardiac magnetic resonance (CMR) is a unique tool for non-invasive tissue characterization, especially for identifying fibrosis.

### AIM

To present the existing data regarding the association of electrocardiographic (ECG) markers with myocardial fibrosis identified by CMR - late gadolinium enhancement (LGE).

### METHODS

A systematic search was performed for identifying the relevant studies in Medline and Cochrane databases through February 2021. In addition, we conducted a relevant search by *Reference Citation Analysis* (RCA) (<https://www.referencecitationanalysis.com>).

### RESULTS

A total of 32 studies were included. In hypertrophic cardiomyopathy (HCM), fragmented QRS (fQRS) is related to the presence and extent of myocardial fibrosis. fQRS and abnormal Q waves are associated with LGE in ischemic cardiomyopathy patients, while fQRS has also been related to fibrosis in myocarditis. Selvester score, abnormal Q waves, and notched QRS have also been associated with LGE. Repolarization abnormalities as reflected by increased Tp-Te, negative T-waves, and higher QT dispersion are related to myocardial fibrosis in HCM patients. In patients with Duchenne muscular dystrophy, a significant correlation between fQRS and the amount of myocardial fibrosis as assessed by LGE-CMR was observed. In atrial fibrillation patients, advanced inter-atrial block is defined as P-wave duration  $\geq 120$  ms, and biphasic morphology in inferior leads is related to left atrial fibrosis.

### CONCLUSION

Myocardial fibrosis, a reliable marker of prognosis in a broad spectrum of cardiovascular diseases, can be easily understood with an easily applicable ECG. However, more data is needed on a specific disease basis to study the association of ECG markers and myocardial fibrosis as depicted by CMR.

**Key Words:** Myocardial fibrosis; Late gadolinium enhancement; Electrocardiogram; Cardiac magnetic resonance

©The Author(s) 2022. Published by Baishideng Publishing Group Inc. All rights reserved.

**Core Tip:** Myocardial fibrosis, a reliable marker of prognosis in a broad spectrum of cardiovascular diseases, can be easily understood with an easily applicable electrocardiogram (ECG). However, more data is needed on a specific disease basis to study the association of ECG markers and myocardial fibrosis as depicted by cardiac magnetic resonance.

**Citation:** Bazoukis G, Garcia-Zamora S, Çinier G, Lee S, Elvin Gul E, Álvarez-García J, Miana G, Hayiroğlu Mİ, Tse G, Liu T, Baranchuk A. Association of electrocardiographic markers with myocardial fibrosis as assessed by cardiac magnetic resonance in different clinical settings. *World J Cardiol* 2022; 14(9): 483-495

**URL:** <https://www.wjgnet.com/1949-8462/full/v14/i9/483.htm>

**DOI:** <https://dx.doi.org/10.4330/wjc.v14.i9.483>

## INTRODUCTION

Cardiac magnetic resonance (CMR) is a useful non-invasive and radiation-free imaging modality that is the gold standard for estimating left ventricular volumes and ejection function[1]. Furthermore, CMR is a unique tool for non-invasive tissue characterization, especially for identifying edema, infarction, scar, and fibrosis. Tissue characterization can provide useful data not only for diagnostic purposes but also for the risk stratification of patients in different clinical settings[2-6]. In this setting, late gadolinium enhancement (LGE) is a commonly used CMR technique to identify myocardial fibrosis. However, CMR is not a widely available imaging modality, and also the high cost limits its widespread use in clinical practice.

On the other hand, electrocardiogram (ECG) is a well-established, easily obtained, low-cost diagnostic tool that is the cornerstone of cardiological evaluation. ECG markers have been associated with the presence of myocardial fibrosis, as depicted from CMR evaluation. This systematic review aimed to present the existing data regarding the association of ECG markers with myocardial fibrosis identified by CMR-LGE.

## MATERIALS AND METHODS

This systematic review was performed in accordance with the Preferred Reporting Items for Systematic Reviews and Meta-Analyses (PRISMA Statement; PROSPERO ID: CRD42021225119)[7].

### Search strategy

This study aimed to identify all relevant studies that provided data about the association of ECG markers with myocardial fibrosis as depicted by CMR. Two independent investigators searched Medline and Cochrane databases systematically through February 2021. The reference lists of all included studies, relevant review studies, systematic reviews, and meta-analyses were manually searched. The following keywords were used in the search strategy: “(CMR OR cardiac magnetic resonance) AND (LGE OR late gadolinium enhancement) AND (ECG OR electroc\*)” without any limitations. We first screened the titles and abstracts of each retrieved study, and in case of considering a study relevant, we studied the full text. In addition, we conducted a relevant search by *Reference Citation Analysis* (RCA) (<https://www.referencecitationanalysis.com>).

### Inclusion/exclusion criteria

We included studies that provided data regarding the association of any ECG markers with myocardial fibrosis as depicted by CMR in different clinical settings. We excluded studies that did not provide data about the studied outcome, studies that provided data about the association of endocardial electrograms with fibrosis, or data about the association of atrial LGE with atrial fibrillation, as well as review studies, case reports/series, and experimental studies.

### Data extraction

The data extraction was performed independently by two authors. The following data were extracted: First author, year of publication, journal, type of study (single or multicenter), number of patients, gender, age, clinical setting, ECG markers that were studied, as well as the major outcomes reported in each study. The Newcastle-Ottawa Quality Assessment Scale was used for the quality assessment of the observational studies[8].

## RESULTS

### Study search

Of the 616 studies initially retrieved, 534 were excluded at the title/abstract level, and 50 were excluded at the full-text level. Finally, 32 studies were included in the systematic review[9-40]. The search strategy is shown in [Figure 1](#).

### Study characteristics

The baseline characteristics and the main findings of the included studies are presented in [Tables 1 and 2](#). Our search strategy identified 15 studies in hypertrophic cardiomyopathy patients[9-23], two with ventricular arrhythmias patients[24,25], two with non-ischemic cardiomyopathy patients[26,27], one with drug refractory AF patients[32], two with myotonic dystrophy patients[28,29], two with myocardial infarction patients[30,31], two about myocarditis[33,34], two including general population [35,36], one with arrhythmogenic cardiomyopathy patients[37], one with patients with preserved ejection fraction[38], one in cardiac sarcoidosis patients[39], and one in patients with left bundle branch block (LBBB)[40]. The quality assessment of the included studies is summarized in [Supplementary Tables 1 and 2 \(Supplementary material\)](#). Overall, the included studies were classified as high-quality studies.

### Association of ECG markers with LGE in different clinical settings

**Hypertrophic cardiomyopathy:** Fragmented QRS (fQRS) is defined as additional notches in the QRS complex. fQRS has been found to be related to more extensive myocardial fibrosis in HCM patients ([Figure 2A](#))[9]. A recent study showed that quantitative fQRS, defined as the total amount of deflections in the QRS complex in all 12 routine ECG leads together, was an independent predictor of myocardial fibrosis and showed a good performance in identifying patients with a higher fibrotic burden[9]. Dohy

**Table 1** Baseline characteristics of the included studies

Ref.	Setting	Country of origin	Multicenter	n	Enrolment period	Mean age	Male (%)	LVEF (%)
Oebel <i>et al</i> [25], 2017	PVCs ablation	Germany	No	101	2015-2016	57	59	46
Sakamoto <i>et al</i> [24], 2015	VT/VF	Japan	No	34	-	60	71	45
Piers <i>et al</i> [26], 2016	NICM	Netherlands	No	40	2011-	57	83	30
Becker <i>et al</i> [27], 2020	DCM	Netherlands	No	165	2016-2018	59	62	36
Cho <i>et al</i> [29], 2017	Duchenne muscular dystrophy	Korea	No	37	-	16	-	55
Cardona <i>et al</i> [28], 2019	Myotonic dystrophy 1	United States	No	52	2012-2017	41	38	60
Nadour <i>et al</i> [30], 2014	MI	United States	No	235	2006-2009	62	82	33
Chew <i>et al</i> [31], 2018	MI	Canada	No	705	2011-2014	64	84	40
Ciuffo <i>et al</i> [32], 2020	AF	United States	No	152	2010-2015	60	76	57
Ferrero <i>et al</i> [33], 2020	Myocarditis	Italy	Yes	80	2008-2019	34	82	55
Fischer <i>et al</i> [34], 2020	Myocarditis	Switzerland	No	587	2002-2015	48	59	48
Inoue <i>et al</i> [35], 2017	General population	United States	Yes	1669	2000 - 2002	67	50	62
De Lazzari <i>et al</i> [37], 2018	AC	Italy	No	79	2006-2016	33	60	58
Mewton <i>et al</i> [38], 2016	HFpEF	United States	No	77	2009-2010	60	68	60
Sobue <i>et al</i> [39], 2015	Sarcoidosis	Japan	No	59	2006-2010		29	51
Wieslander <i>et al</i> [36], 2015	General population	United States	No	193	2011-2013	63	66	49
Wieslander <i>et al</i> [40], 2018	LBBB	United States	Yes	325	-	63	52	36
Bi <i>et al</i> [9], 2020	HCM	China	No	69	2015-2020	46	62	65
Chen <i>et al</i> [10], 2014	HCM	China	No	118	2005-2012	46	72	72
Chen <i>et al</i> [11], 2020	HCM	China	No	135	2012-2016	51	51	62
Riza-Demir <i>et al</i> [12], 2019	HCM	Turkey	No	74	2016-2018	51	65	66
Dohy <i>et al</i> [13], 2020	HCM	Hungary	No	181	-	49	57	63
Fronza <i>et al</i> [14], 2016	HCM	Italy	No	88	2004-2014	42	74	62
Grall <i>et al</i> [15], 2014	HCM	France	No	42	2008-2012	47	72	62
Guerrier <i>et al</i> [16], 2016	Pediatric HCM	United States	No	37	2006-2014	16	89	69
Kawasaki <i>et al</i> [17], 2015	HCM	Japan	No	60	2010-2013	66	76	64
Konno <i>et al</i> [18], 2015	HCM	Japan	No	108	2008 - 2014	62	65	-
Matsuki <i>et al</i> [19], 2020	HCM	Japan	No	41	-	62	76	65

Park <i>et al</i> [20], 2018	HCM	Korea	No	88	-	57	74	6
Sakamoto <i>et al</i> [21], 2015	HCM	Japan	No	42	2004-2014	59	79	58
Suwa <i>et al</i> [22], 2014	HCM	Japan	Yes	50	2004 - 2012	-	-	-
Tangwiwat <i>et al</i> [23], 2019	HCM	Thailand	No	144	2005 - 2015	66	60	73

LVEF: Left ventricular ejection fraction; PVC: Premature ventricular complex; VT/VF: Ventricular tachycardia/ fibrillation; NICM: Non-ischemic cardiomyopathy; DCM: Dilated cardiomyopathy; MI: Myocardial infarction; AF: Atrial fibrillation; AC: Arrhythmogenic cardiomyopathy; HFpEF: Heart failure with preserved ejection fraction; LBBB: Left bundle branch block; HCM: Hypertrophic cardiomyopathy.

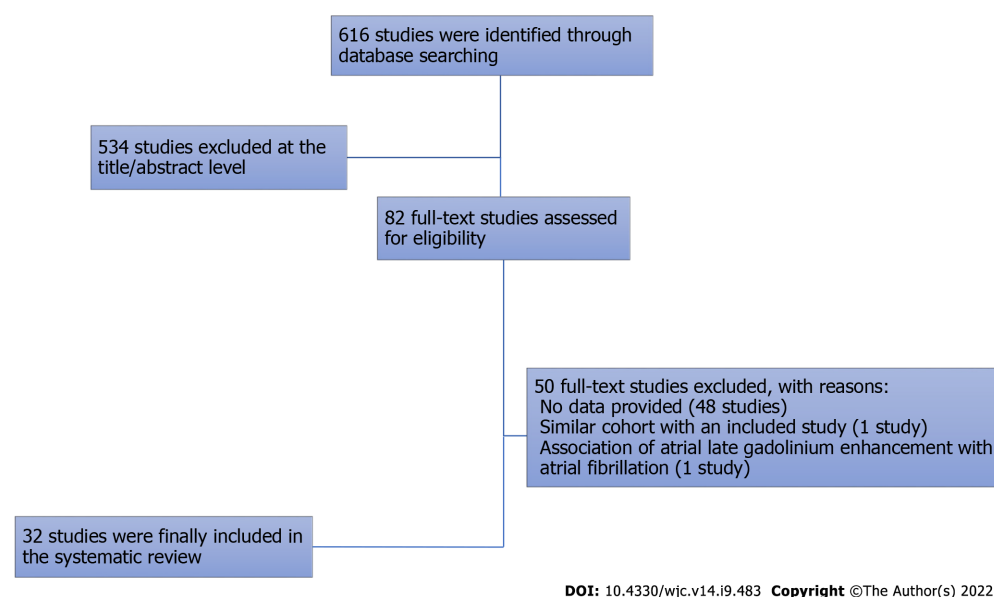


Figure 1 Flow diagram of the search strategy.

*et al*[13] showed that fQRS and the strain pattern predicted more fibrosis, while the Cornell index was a negative predictor of myocardial fibrosis. The number of fQRS leads has been significantly correlated to %LGE, average ECV, and T2, while more than one lead with fQRS could predict > 5% of LGE mass with a 58% sensitivity and 63% specificity[20]. Suwa *et al*[22] showed that the presence of fQRS was associated with apical LGE. On the other hand, Tangwiwat *et al*[23] showed that fQRS was not associated with LGE. Chen *et al*[11] studied the role of Selvester QRS scoring criteria in diagnosing myocardial scar in HCM patients. The authors found that the Selvester score 1 showed a better performance in predicting LGE presence. Also, the same study showed a positive association between the Selvester score and the extent of LGE[11]. Abnormal Q waves are more prevalent in patients with LGE, but no correlation between the location of Q waves on ECG and territory of LGE on CMR was revealed (Figure 2B)[15]. Interestingly, quantitative analysis of LGE was not related to the presence of abnormal Q waves[15]. However, findings of another study showed that abnormal Q waves were associated with more ventricular segments with extensive LGE[10]. In a cohort study, LGE was associated with notched QRS, leftward QRS axis, and prolonged QRS duration, but not with abnormal Q waves, R-wave amplitude, or ST-T changes[17]. fQRS has been found to have higher diagnostic accuracy for detecting myocardial fibrosis compared to abnormal Q waves in HCM patients[18]. A cut-off of the number of leads with notched QRS  $\geq 2$  was found to predict the presence or absence of myocardial fibrosis, with a sensitivity of 70% and specificity of 81%[17]. Interestingly, the same study showed that the number of notched QRS leads was positively correlated with LGE volume, while a correlation between the lead distribution of notched QRS and the location of LGE was revealed[17]. Although giant negative T waves have been associated with apical HCM, no significant association was demonstrated with apical LGE[10]. On the other hand, in another observational study, repolarization disturbances, including negative T waves in lateral and anterior leads, have been correlated with “parietal” LGE scores, while QT dispersion has been associated with “global” LGE score[14]. Tp-Te has also been found to be an independent predictor of LGE, while a cut-off value of 99.4 ms can detect the LGE with a sensitivity of 64.3% and specificity of 84.2%[12]. In a small cohort of the pediatric population, the presence of LGE was associated with significantly decreased voltages in SV1, RV6, and

**Table 2 Summary of the main findings of all included studies in the systematic review**

Ref.	ECG markers studied	Main findings
Bi <i>et al</i> [9], 2020	fQRS, AF, bundle branch block	Quantitative fQRS was an independent predictor for myocardial fibrosis in HCOM
Chen <i>et al</i> [10], 2014	ST and T waves, LVH, Q waves, 1° AV block, 2° and 3° AV block, QRS duration	Abnormal Q waves were related to basal anteroseptal hypertrophy and extensive segmental LGE in HCM
Chen <i>et al</i> [11], 2020	QRS duration, QTc, LVH, RBBB, LAFB, LBBB, Selvester score	Selvester score showed a significant positive correlation with the extent of LGE enhancement in HCM
Riza Demir <i>et al</i> [12], 2019	QRS duration, QTc, TP-e interval, TP-e/QTc	TP-e interval was an independent predictor of LGE in HCM
Dohy <i>et al</i> [13], 2020	fQRS, Q wave, ST deviation, Sokolow, Cornell, and Romhilt-Estes score	fQRS and ST deviation (strain pattern) predicts myocardial fibrosis in HCM
Fronza <i>et al</i> [14], 2016	Q waves, LBBB, signs of LV hypertrophy, negative T waves, ST depression	Negative T waves were correlated with LGE, whereas Q waves were associated with asymmetric hypertrophy in HCM
Grall <i>et al</i> [15], 2014	AF, QRS duration, ST deviation, negative T wave, Q wave, Sokolow, Cornell, Romhilt-Estes score	Q waves were more prevalent in the presence of LGE but didn't correlate with LGE location and extent in HCM
Guerrier <i>et al</i> [16], 2016	QRS axis, QTc, PR interval, T wave inversion, ST depression, Q waves, LVH	Low left ventricle precordial voltages in ECG were associated with LGE in pediatric HCM patients
Kawasaki <i>et al</i> [17], 2016	QRS duration and axis, QTc, AF, LVH, Q wave, ST deviation, T wave inversion, notched QRS	Notched QRS was correlated with LGE in HCM without LBBB
Konno <i>et al</i> [18], 2015	Pathological Q waves and fQRS	fQRS was correlated with LGE in HCM, whereas Q waves were not correlated with LGE
Matsuki <i>et al</i> [19], 2020	QT interval, QRS duration, Sum of R-wave amplitude, ventricular late potentials	Ventricular late potentials were not correlated with LGE in HCM
Park <i>et al</i> [20], 2018	QRS, QTc, biphasic T wave, Q waves, sum S V1-3, Sokolow, Cornell, fQRS, AF, giant T wave inversion	The number of fQRS leads was significantly correlated to LGE in HCM
Sakamoto <i>et al</i> [21], 2015	24-hour ECG recordings and Time-domain T-wave alternans and QT dispersion	T-wave alternans and QT dispersion were associated with LGE in HCM
Suwa <i>et al</i> [22], 2014	QRS, QTc, Sokolow, max ST, max T waves, fQRS	fQRS was associated with impaired apical contraction and apical LGE in HCM
Tangwiwat <i>et al</i> [23], 2019	QRS duration, QTc, QRS axis, T-wave inversion, Sokolow, Cornell	fQRS in HCM was found to be associated with myocardial fibrosis in univariate analysis but not in the multivariate analysis
Sakamoto <i>et al</i> [24], 2015	HR, QT, QTc, QTe/RR slope, QTa/RR slope, day/night slope, VT/FV	QTe day/night and QTa day/night ratios were significantly greater in patients with Ventricular Arrhythmias and LGE
Oebel <i>et al</i> [25], 2017	PVC morphologies	RBBB, LBBB morphology and multiple PVC morphologies were associated with LGE in patients undergoing PVC ablation
Piers <i>et al</i> [26], 2016	Prolongation of the paced QRS duration after premature stimulation	QRS duration was associated with ventricular tachycardia but not with LGE in non-ischemic cardiomyopathy
Becker <i>et al</i> [27], 2020	HR, AV delay, 1° AV block, QRS duration, LBBB	QRS-prolongation was not correlated with LGE in non-ischemic dilated cardiomyopathy
Cardona <i>et al</i> [28], 2017	PR, QRS, QT, QTc, Frontal QRS-T angle, LVH Cornell	Surface conduction abnormality was not associated with LGE in myotonic muscular dystrophy type 1
Cho <i>et al</i> [29], 2019	fQRS	f-QRS was correlated with LGE in Duchenne muscular dystrophy with low statistical significance levels
Nadour <i>et al</i> [30], 2014	Q waves	Q waves in ECG have low value to detect a past myocardial infarction in the general population
Chew <i>et al</i> [31], 2018	QRS 120 ms, QRS fragmentation, Axis, AF	fQRS was associated with increased peri-infarct zone LGE and unfavorable left ventricle remodeling
Ferrero <i>et al</i> [33], 2020	fQRS	fQRS was correlated with LGE in patients with myocarditis
Fischer <i>et al</i> [34], 2020	QTc, QRS-T angle, fQRS, BBB, ST deviation, PR depression, low voltage, Q and T wave	fQRS, low voltage and QRS-T angle > 90° were independently correlated with LGE in myocarditis



Inoue <i>et al</i> [35], 2020	QRS duration, QTc, Sokolov and Cornell	QRS Cornell voltage, QRS duration, and QTc were significantly associated with LGE presence, while QRS Sokolow-Lyon voltage was not shown a significant correlation with LGE-CMR
Wieslander <i>et al</i> [36], 2015	LBBB, RBBB, LAFB, RBBB + LAFB and Selvester score	Selvester score was not accurate to detect myocardial scar and LGE in patients with conduction abnormalities and BBB
De Lazzari <i>et al</i> [37], 2018	Depolarization and repolarization abnormalities	Low QRS voltages in limb leads predicted LGE in Arrhythmogenic Cardiomyopathy
Mewton <i>et al</i> [38], 2016	QRS d, QTc, QRS-T angle, QRS score, T wave alternans	A significant association between T-wave alternans value and total scar. Patients with a myocardial ischemic scar had greater QRS duration. QRS-T angle was not associated with total myocardial scar size, core of scar, and gray zone size in grams by LGE-CMR
Sobue <i>et al</i> [39], 2015	QRS duration, atrioventricular block, LAFB, RBBB, Selvester QRS score	Selvester score was correlated with LGE in cardiac sarcoidosis
Wieslander <i>et al</i> [40], 2018	LBBB	Selvester score was not accurate to detect myocardial scar and LGE in patients with LBBB
Ciuffo <i>et al</i> [32], 2020	Inter-atrial block	Advanced IAB is associated with more fibrosis, while longer P-wave duration is also associated with more LA fibrosis.

fQRS: Fragmented QRS; AF: Atrial fibrillation; HCOM: Hypertrophic obstructive cardiomyopathy; HCM: Hypertrophic cardiomyopathy; AV: Atrioventricular; LGE: Late gadolinium enhancement; LVH: Left ventricular hypertrophy; RBBB: Right bundle branch block; LBBB: Left bundle branch block; LAFB: Left anterior fascicular block; PVC: Premature ventricular complexes; IAB: Inter-atrial block.

SV1 + RV6 despite increased septal dimensions[16]. Furthermore, the slopes of the QTe/RR and QTa/RR have been found to be significantly steeper in the LGE positive patients, while both slopes have been significantly correlated with the total LGE scores[24]. The association of late potentials with myocardial fibrosis has also been studied in HCM patients. However, ventricular late potentials were not found to be a reliable marker for the detection of myocardial fibrosis as assessed by LGE on CMR [19].

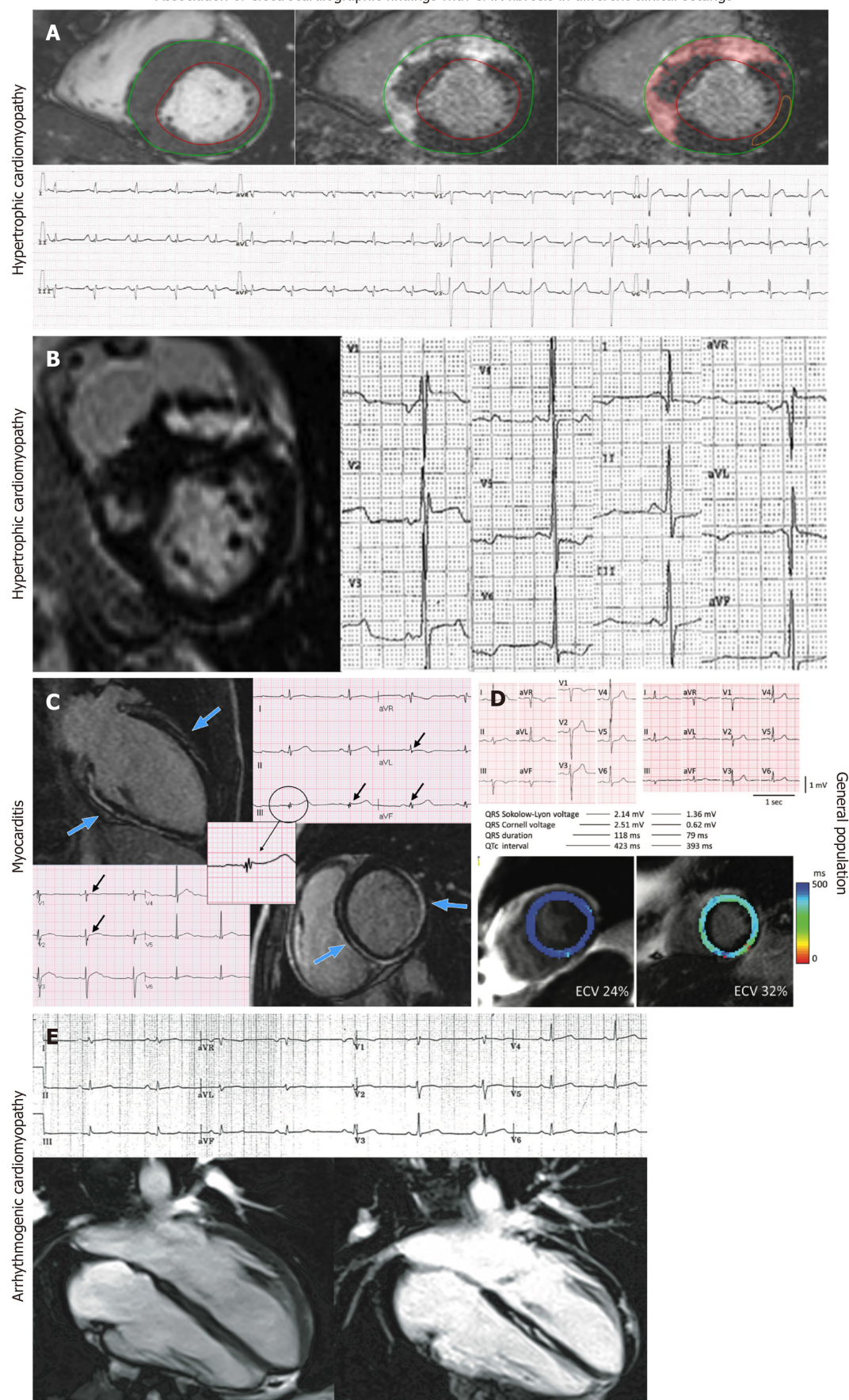
**Ischemic and non-ischemic cardiomyopathy:** Two studies were identified through the search strategy regarding the association of ECG markers with fibrosis as identified by CMR. Nadour W *et al*[30] studied the comparative efficacy of Q waves and CMR-LGE to predict prior myocardial infarction. Interestingly, the authors found that ECG-defined scars had a lower sensitivity compared to CMR-LGE-defined scars. Specifically, it was found that a significant number of pathological Q waves had absent infarct etiology, indicating high false positivity[30]. Chew *et al*[31] showed that in myocardial infarction patients, fQRS has been found to be significantly associated with the peri-infarct zone but not with core infarct volume. In the setting of non-ischemic cardiomyopathy, two studies were identified. Specifically, Piers *et al*[26] found that prolongation of the paced QRS duration after premature stimulation was related to long, thick strands of fibrosis but not to focal LGE-CMR. CMR has been reported to have a complementary role to ECG findings in dilated cardiomyopathy patients[27]. Specifically, it has been found that while QRS prolongation and septal mid-wall LGE are often co-existed, no significant correlation between these markers was revealed[27].

**Myocarditis:** Two studies that provided data about ECG markers with CMR fibrosis were identified. In myocarditis patients, fQRS has been correlated with the distribution of LGE (Figure 2C and D)[33]. Interestingly, fQRS was also associated with ongoing inflammation and poor prognosis in terms of ventricular function and fatal arrhythmias[33]. Fischer *et al*[34] studied the association of ECG parameters with LGE-CMR in patients with clinical suspicion of acute or subacute myocarditis. In this population, a wide QRS-T angle, low voltage, and fQRS were found to be significantly associated with LGE-CMR[34].

**Myotonic dystrophy:** Two studies were found to provide data about ECG markers and myocardial fibrosis in patients with muscular dystrophy. Specifically, in patients with Duchenne muscular dystrophy, a significant correlation between fQRS and the amount of myocardial fibrosis as assessed by LGE-CMR was observed[29]. On the other hand, in patients with myotonic muscular dystrophy type 1, PR, QRS, and QTc duration, frontal QRS-T angle, absolute Cornell voltage, LVH-Cornell, LBBB, right bundle branch block (RBBB), fascicular block, bifascicular block, AH interval, and HV interval were not significantly different between LGE positive and LGE negative patients[28].

**Other clinical settings:** Ciuffo *et al*[32] studied the association between the interatrial block and atrial fibrosis using CMR imaging in patients with drug-refractory AF. It was found that advanced inter-atrial block, defined as P-wave duration  $\geq 120$  ms and biphasic morphology in inferior leads, was significantly associated with left atrial fibrosis[32]. Furthermore, P-wave duration was also independently associated with left atrial fibrosis in this clinical scenario[32]. Mewton *et al*[38] studied the association of ECG markers in patients with preserved ejection fraction. A significant independent and positive association

## Association of electrocardiographic findings with CMR fibrosis in different clinical settings



**Figure 2** Association of electrocardiographic indices with cardiac magnetic resonance fibrosis in different clinical settings. A: Association of Fragmented QRS (fQRS) with myocardial fibrosis in hypertrophic cardiomyopathy patients (Adapted from Dohy Z *et al*[13], 2020-permission is not required for this



type of reuse); B: Association of Q wave with fibrosis in hypertrophic cardiomyopathy patients (adapted from Grall S *et al*[15], 2014-permission is not required for this type of reuse); C: Association of fQRS with fibrosis in myocarditis patients (adapted from Ferrero P *et al*[33], 2020-permission is not required for this type of reuse); D: Association of QRS voltage, QRS duration and QTc with fibrosis in the general population (adapted from Inoue YY *et al*[35], 2017-with permission from the Radiological Society of North America); E: Association of low QRS voltages with fibrosis in arrhythmogenic cardiomyopathy patients (adapted from De Lazzari M *et al* [37], 2018- permission is not required for this type of reuse).

between T-wave alternans value and total scar was revealed[38]. Furthermore, patients with a myocardial ischemic scar had significantly greater QRS duration as compared with patients with nonischemic scar and patients without a myocardial scar. On the other hand, QRS-T angle was not associated with total myocardial scar size, core of scar, and gray zone size in grams by LGE-CMR[38]. In the clinical setting of PVC, the presence of an RBBB pattern as the clinically dominant PVC morphology or the presence of multiple PVC morphologies were significantly correlated with the presence of LGE-defined fibrosis[25]. On the other hand, in patients with VT or VF, the slopes of the QTc/RR (QT measured at the apex of the T waves) and QTa/RR (QT measured at the end of T waves) were significantly steeper in the LGE positive patients while both slopes were significantly correlated with the total LGE scores[24]. Interestingly, the QTc day/night and QTa day/night ratios were significantly greater in LGE positive patients than in LGE negative patients, clearly demonstrating the correlation between fibrosis and QT dynamicity[24]. In the setting of cardiac sarcoidosis, QRS estimated scar using Selvester QRS score was significantly correlated with CMR-LGE scar while it was related with life-threatening arrhythmic events[39]. However, the Selvester QRS score intended for use in the presence of conduction abnormalities was not found to predict CMR-defined LV scar in a general population with suspected cardiovascular disease[36]. Similarly, the LBBB Selvester QRS score showed poor accuracy in the detection and quantification of myocardial scar in LBBB patients[40]. In ARVC patients,  $\epsilon$  wave and terminal activation duration > 55 ms were not associated with either right or left ventricular LGE[37]. On the other hand, the presence of low QRS voltages in limb leads was associated with the presence of left ventricular LGE but not with right ventricular LGE (Figure 2E)[37]. In addition, the presence and extent of right precordial T-wave inversions were associated with the presence of right ventricular but not with left ventricular LGE[37]. Finally, in a prospective cross-sectional study that included individuals free of prior coronary heart disease, QRS Cornell voltage, QRS duration, and QTc were significantly associated with LGE presence, while QRS Sokolow-Lyon voltage was not shown to have a significant correlation with LGE-CMR (Figure 2D)[35].

## DISCUSSION

In our systematic review, we examined in detail studies that have reported associations between ECG markers and CMR-reported myocardial fibrosis. In the literature, studies have reported controversial results regarding the association between pathological Q wave presence in ECG and LGE-CMR at first glance[10,17]. Moreover, another controversy on the association between fQRS and LGE in apical hypertrophic cardiomyopathy was reported[22,23]. These findings should be evaluated with caution because the study population, study design, ECG parameters used, and statistical approach have been heterogeneous among the included studies. Considering all included data, fQRS, QRS duration, Selvester QRS score, and ventricular repolarization variables have been detected to have great predictive value for myocardial fibrosis, which is validated by LGE-CMR in various cardiovascular diseases. The studies examining the association between ECG markers and CMR have been first evaluated in patients with HCM and ischemic cardiomyopathy. HCM has always been attracted attention due to its heterogeneous electrocardiographic presentations, and it is rational to assess the fibrosis markers of ECG in HCM with the validation of CMR[41]. Since myocardial fibrosis has been associated with the arrhythmia burden in patients with HCM, early detection of myocardial fibrosis using 12-lead ECG has the potential to rapidly change management strategy in these patients[42,43]. LGE-CMR has been proposed as one of the predictors of clinical prognosis in patients with HCM[44]. Thus in the next step, ECG parameters correlated with LGE-CMR may be investigated in the risk scoring of HCM in addition to other well-known risk factors to provide more precise prediction in the follow-up of these patients. As the use of CMR is limited due to its high cost, ECG parameters found to represent myocardial fibrosis according to LGE-CMR may easily be used for the risk assessment.

In the evaluation of myocardial scar in patients with ischemic and non-ischemic cardiomyopathy, there appears to be a clear performance difference between CMR and ECG. The highly promising ECG parameters such as fQRS and pathological Q waves have not satisfied the expected performance compared to LGE-CMR[30]. The pathophysiological occurrence of myocardial scar in infarction may play an important role while explaining the poor performance of pathological Q waves in predicting myocardial fibrosis of LGE-CMR. Since Q waves symbolize a loss of electrical activity, not purely myocardial fibrosis, pathological Q waves without evident LGE-CMR may be explained for this reason

[45]. However, fQRS, which has not been correlated with core infarct volume, has been associated with peri-infarct volume[31]. In myocarditis, fQRS has been demonstrated to have a good LGE-CMR prediction performance, similar to its significance in patients with HCM[33,34]. Since ECG variables, including fQRS, change dynamically during the disease course of myocarditis, more investigations are warranted to determine the time of obtained ECG, which should be examined to correlate LGE-CMR. On the other hand, ECG parameters regarding atrial tissue fibrosis have been closely related to LGE-CMR because there have been several investigations defending the association between P-wave duration and morphology and left atrial fibrosis. Therefore, P-wave duration and inter-atrial block have a great potential to present left atrial fibrosis, which has been validated by CMR[32].

## CONCLUSION

Myocardial fibrosis, which is a reliable marker of prognosis in a wide spectrum of cardiovascular diseases, can be easily understood with an easily applicable ECG. More investigations are needed on a specific disease basis to fill the gap of evidence regarding the association of ECG markers and CMR, which may practically change our daily clinical practice.

## ARTICLE HIGHLIGHTS

### **Research background**

Electrocardiogram (ECG) is a well-established, easily obtained, low-cost diagnostic tool that is the cornerstone of cardiological evaluation. ECG markers have been associated with the presence of myocardial fibrosis, as depicted from cardiac magnetic resonance (CMR) evaluation.

### **Research motivation**

ECG can be a valuable tool for the risk stratification of sudden cardiac death in different clinical settings.

### **Research objectives**

To elucidate the association of ECG markers with CMR-late gadolinium enhancement in different clinical settings.

### **Research methods**

Methodology of Systematic reviews in accordance with the Preferred Reporting Items for Systematic Reviews and Meta-Analyses (PRISMA Statement).

### **Research results**

Our results summarize the existing evidence about the association of ECG markers with fibrosis as identified by CMR. Existing data show that fragmented QRS, Q waves and repolarization abnormalities are some of the ECG indices that are associated with myocardial fibrosis.

### **Research conclusions**

Myocardial fibrosis, a marker of prognosis in a wide spectrum of clinical settings, can be easily identified by ECG indices.

### **Research perspectives**

Future research should be focused on the identification of ECG markers that are reliably associated with myocardial fibrosis in different clinical settings. Furthermore, the association of ECG markers with all-cause mortality and arrhythmic events is of great importance.

## FOOTNOTES

**Author contributions:** Bazoukis G had the inception of the idea and wrote the first draft; Bazoukis G and Garcia-Zamora S performed the systematic search; Bazoukis G, Garcia-Zamora S, Cinier G, Lee S, Gul EE, García JA, Miana G, Hayiroğlu ML, Tse G, Liu T, and Baranchuk A performed major revisions and approved the final manuscript; Baranchuk A supervised the study.

**Conflict-of-interest statement:** All authors declare no conflicts of interest.

**PRISMA 2009 Checklist statement:** All authors have read the PRISMA 2009 Checklist, and the manuscript was prepared and revised according to the PRISMA 2009 Checklist.

**Open-Access:** This article is an open-access article that was selected by an in-house editor and fully peer-reviewed by external reviewers. It is distributed in accordance with the Creative Commons Attribution NonCommercial (CC BY-NC 4.0) license, which permits others to distribute, remix, adapt, build upon this work non-commercially, and license their derivative works on different terms, provided the original work is properly cited and the use is non-commercial. See: <https://creativecommons.org/licenses/by-nc/4.0/>

**Country/Territory of origin:** Cyprus

**ORCID number:** George Bazoukis 0000-0003-1009-9772; Tong Liu 0000-0003-0482-0738.

**S-Editor:** Wang LL

**L-Editor:** Wang TQ

**P-Editor:** Wang LL

## REFERENCES

- 1 **Hundley WG**, Meshack BM, Willett DL, Sayad DE, Lange RA, Willard JE, Landau C, Hillis LD, Peshock RM. Comparison of quantitation of left ventricular volume, ejection fraction, and cardiac output in patients with atrial fibrillation by cine magnetic resonance imaging versus invasive measurements. *Am J Cardiol* 1996; **78**: 1119-1123 [PMID: 8914874 DOI: 10.1016/s0002-9149(96)90063-6]
- 2 **Raiker N**, Vullaganti S, Collins JD, Allen BD, Choudhury L. Myocardial tissue characterization by gadolinium-enhanced cardiac magnetic resonance imaging for risk stratification of adverse events in hypertrophic cardiomyopathy. *Int J Cardiovasc Imaging* 2020; **36**: 1147-1156 [PMID: 32166506 DOI: 10.1007/s10554-020-01808-6]
- 3 **Gräni C**, Eichhorn C, Bière L, Murthy VL, Agarwal V, Kaneko K, Cuddy S, Aghayev A, Steigner M, Blankstein R, Jerosch-Herold M, Kwong RY. Prognostic Value of Cardiac Magnetic Resonance Tissue Characterization in Risk Stratifying Patients With Suspected Myocarditis. *J Am Coll Cardiol* 2017; **70**: 1964-1976 [PMID: 29025553 DOI: 10.1016/j.jacc.2017.08.050]
- 4 **Gräni C**, Benz DC, Gupta S, Windecker S, Kwong RY. Sudden Cardiac Death in Ischemic Heart Disease: From Imaging Arrhythmogenic Substrate to Guiding Therapies. *JACC Cardiovasc Imaging* 2020; **13**: 2223-2238 [PMID: 31864982 DOI: 10.1016/j.jcmg.2019.10.021]
- 5 **Aljaroudi WA**, Flamm SD, Saliba W, Wilkoff BL, Kwon D. Role of CMR imaging in risk stratification for sudden cardiac death. *JACC Cardiovasc Imaging* 2013; **6**: 392-406 [PMID: 23473115 DOI: 10.1016/j.jcmg.2012.11.011]
- 6 **Patel AR**, Kramer CM. Role of Cardiac Magnetic Resonance in the Diagnosis and Prognosis of Nonischemic Cardiomyopathy. *JACC Cardiovasc Imaging* 2017; **10**: 1180-1193 [PMID: 28982571 DOI: 10.1016/j.jcmg.2017.08.005]
- 7 **Moher D**, Liberati A, Tetzlaff J, Altman DG; PRISMA Group. Preferred reporting items for systematic reviews and meta-analyses: the PRISMA statement. *PLoS Med* 2009; **6**: e1000097 [PMID: 19621072 DOI: 10.1371/journal.pmed.1000097]
- 8 **Marshall SC**, Molnar F, Man-Son-Hing M, Blair R, Brosseau L, Finestone HM, Lamothe C, Korner-Bitensky N, Wilson KG. Predictors of driving ability following stroke: a systematic review. *Top Stroke Rehabil* 2007; **14**: 98-114 [PMID: 17311796 DOI: 10.1310/tsr1401-98]
- 9 **Bi X**, Yang C, Song Y, Yuan J, Cui J, Hu F, Qiao S. Quantitative fragmented QRS has a good diagnostic value on myocardial fibrosis in hypertrophic obstructive cardiomyopathy based on clinical-pathological study. *BMC Cardiovasc Disord* 2020; **20**: 298 [PMID: 32552709 DOI: 10.1186/s12872-020-01590-2]
- 10 **Chen X**, Zhao T, Lu M, Yin G, Xiangli W, Jiang S, Prasad S, Zhao S. The relationship between electrocardiographic changes and CMR features in asymptomatic or mildly symptomatic patients with hypertrophic cardiomyopathy. *Int J Cardiovasc Imaging* 2014; **30** Suppl 1: 55-63 [PMID: 24723003 DOI: 10.1007/s10554-014-0416-x]
- 11 **Chen S**, Wang X, Huang L, Chen Y, Zhang Q. Performance of 12-lead electrocardiogram Selvester QRS scoring criteria to diagnose myocardial scar in patients with hypertrophic cardiomyopathy. *Ann Noninvasive Electrocardiol* 2020; **25**: e12762 [PMID: 32378804 DOI: 10.1111/anec.12762]
- 12 **Riza Demir A**, Celik Ö, Sevinç S, Uygur B, Kahraman S, Yilmaz E, Cemek M, Onal Y, Erturk M. The relationship between myocardial fibrosis detected by cardiac magnetic resonance and Tp-e interval, 5-year sudden cardiac death risk score in hypertrophic cardiomyopathy patients. *Ann Noninvasive Electrocardiol* 2019; **24**: e12672 [PMID: 31152489 DOI: 10.1111/anec.12672]
- 13 **Dohy Z**, Vereckei A, Horvath V, Czibalmos C, Szabo L, Toth A, Suhai FI, Csecs I, Becker D, Merkely B, Vago H. How are ECG parameters related to cardiac magnetic resonance images? *Ann Noninvasive Electrocardiol* 2020; **25**: e12763 [PMID: 32329134 DOI: 10.1111/anec.12763]
- 14 **Fronza M**, Raineri C, Valentini A, Bassi EM, Scelsi L, Buscemi ML, Turco A, Castelli G, Ghio S, Visconti LO. Relationship between electrocardiographic findings and Cardiac Magnetic Resonance phenotypes in patients with Hypertrophic Cardiomyopathy. *Int J Cardiol Heart Vasc* 2016; **11**: 7-11 [PMID: 28616518 DOI: 10.1016/j.ijcha.2016.02.001]
- 15 **Grall S**, Biere L, Clerfond G, Mateus V, Prunier F, Furber A. ECG characteristics according to the presence of late gadolinium enhancement on cardiac MRI in hypertrophic cardiomyopathy. *Open Heart* 2014; **1**: e000101 [PMID: 25332813 DOI: 10.1136/openhrt-2014-000101]
- 16 **Guerrier K**, Madueme PC, Jefferies JL, Anderson JB, Spar DS, Knilans TK, Czosek RJ. Unexpectedly low left ventricular voltage on ECG in hypertrophic cardiomyopathy. *Heart* 2016; **102**: 292-297 [PMID: 26740481 DOI: 10.1136/heartjnl-2015-308633]
- 17 **Kawasaki T**, Harimoto K, Honda S, Sato Y, Yamano M, Miki S, Kamitani T. Notched QRS for the assessment of

- myocardial fibrosis in hypertrophic cardiomyopathy. *Circ J* 2015; **79**: 847-853 [PMID: [25739570](#) DOI: [10.1253/circj.CJ-14-1109](#)]
- 18 **Konno T**, Hayashi K, Fujino N, Oka R, Nomura A, Nagata Y, Hodatsu A, Sakata K, Furusho H, Takamura M, Nakamura H, Kawashiri MA, Yamagishi M. Electrocardiographic QRS Fragmentation as a Marker for Myocardial Fibrosis in Hypertrophic Cardiomyopathy. *J Cardiovasc Electrophysiol* 2015; **26**: 1081-1087 [PMID: [26102305](#) DOI: [10.1111/jce.12742](#)]
  - 19 **Matsuki A**, Kawasaki T, Kawamata H, Sakai C, Harimoto K, Kamitani T, Yamano M, Matoba S. Ventricular late potentials and myocardial fibrosis in hypertrophic cardiomyopathy. *J Electrocardiol* 2020; **58**: 87-91 [PMID: [31790854](#) DOI: [10.1016/j.jelectrocard.2019.10.003](#)]
  - 20 **Park CH**, Chung H, Kim Y, Kim JY, Min PK, Lee KA, Yoon YW, Kim TH, Lee BK, Hong BK, Rim SJ, Kwon HM, Choi EY. Electrocardiography based prediction of hypertrophy pattern and fibrosis amount in hypertrophic cardiomyopathy: comparative study with cardiac magnetic resonance imaging. *Int J Cardiovasc Imaging* 2018; **34**: 1619-1628 [PMID: [29728953](#) DOI: [10.1007/s10554-018-1365-6](#)]
  - 21 **Sakamoto N**, Sato N, Oikawa K, Karim Talib A, Sugiyama E, Minoshima A, Tanabe Y, Takeuchi T, Akasaka K, Saijo Y, Kawamura Y, Hasebe N. Late gadolinium enhancement of cardiac magnetic resonance imaging indicates abnormalities of time-domain T-wave alternans in hypertrophic cardiomyopathy with ventricular tachycardia. *Heart Rhythm* 2015; **12**: 1747-1755 [PMID: [25916568](#) DOI: [10.1016/j.hrthm.2015.04.028](#)]
  - 22 **Suwa K**, Satoh H, Sano M, Nobuhara M, Saitoh T, Saotome M, Urushida T, Katoh H, Tawarahara K, Ohtani H, Wakabayashi Y, Takase H, Terada H, Takehara Y, Sakahara H, Hayashi H. Functional, morphological and electrocardiographical abnormalities in patients with apical hypertrophic cardiomyopathy and apical aneurysm: correlation with cardiac MR. *Open Heart* 2014; **1**: e000124 [PMID: [25332823](#) DOI: [10.1136/openhrt-2014-000124](#)]
  - 23 **Tangwivat C**, Kaolawanich Y, Krittaphong R. Electrocardiographic predictors of myocardial fibrosis and apical hypertrophic cardiomyopathy. *Ann Noninvasive Electrocardiol* 2019; **24**: e12612 [PMID: [30403441](#) DOI: [10.1111/anec.12612](#)]
  - 24 **Sakamoto N**, Sato N, Talib AK, Sugiyama E, Minoshima A, Tanabe Y, Fujino T, Takeuchi T, Akasaka K, Saijo Y, Kawamura Y, Hasebe N. Late Gadolinium Enhancement on Cardiac MRI Correlates with QT Dynamicity Represented by QT/RR Relationship in Patients with Ventricular Arrhythmias. *Ann Noninvasive Electrocardiol* 2016; **21**: 126-135 [PMID: [26104916](#) DOI: [10.1111/anec.12280](#)]
  - 25 **Oebel S**, Dinov B, Arya A, Hilbert S, Sommer P, Bollmann A, Hindricks G, Paetsch I, Jahnke C. ECG morphology of premature ventricular contractions predicts the presence of myocardial fibrotic substrate on cardiac magnetic resonance imaging in patients undergoing ablation. *J Cardiovasc Electrophysiol* 2017; **28**: 1316-1323 [PMID: [28791747](#) DOI: [10.1111/jce.13309](#)]
  - 26 **Piers SR**, Askar SF, Venlet J, Androulakis AF, Kapel GF, de Riva Silva M, Jongbloed JJ, van Tintelen JP, Schaliq MJ, Pijnappels DA, Zeppenfeld K. QRS prolongation after premature stimulation is associated with polymorphic ventricular tachycardia in nonischemic cardiomyopathy: Results from the Leiden Nonischemic Cardiomyopathy Study. *Heart Rhythm* 2016; **13**: 860-869 [PMID: [26699238](#) DOI: [10.1016/j.hrthm.2015.12.021](#)]
  - 27 **Becker MAJ**, Allaart CP, Zweerink A, Cornel JH, van de Ven PM, van Rossum AC, Germans T. Correlation between septal midwall late gadolinium enhancement on CMR and conduction delay on ECG in patients with nonischemic dilated cardiomyopathy. *Int J Cardiol Heart Vasc* 2020; **26**: 100474 [PMID: [32021905](#) DOI: [10.1016/j.ijcha.2020.100474](#)]
  - 28 **Cardona A**, Arnold WD, Kissel JT, Raman SV, Zareba KM. Myocardial fibrosis by late gadolinium enhancement cardiovascular magnetic resonance in myotonic muscular dystrophy type 1: highly prevalent but not associated with surface conduction abnormality. *J Cardiovasc Magn Reson* 2019; **21**: 26 [PMID: [31046780](#) DOI: [10.1186/s12968-019-0535-6](#)]
  - 29 **Cho MJ**, Lee JW, Lee J, Shin YB, Lee HD. Relationship Between Fragmented QRS Complexes and Cardiac Status in Duchenne Muscular Dystrophy: Multimodal Validation Using Echocardiography, Magnetic Resonance Imaging, and Holter Monitoring. *Pediatr Cardiol* 2017; **38**: 1042-1048 [PMID: [28456833](#) DOI: [10.1007/s00246-017-1616-7](#)]
  - 30 **Nadour W**, Doyle M, Williams RB, Rayarao G, Grant SB, Thompson DV, Yamrozik JA, Biederman RW. Does the presence of Q waves on the EKG accurately predict prior myocardial infarction when compared to cardiac magnetic resonance using late gadolinium enhancement? *Heart Rhythm* 2014; **11**: 2018-2026 [PMID: [25063692](#) DOI: [10.1016/j.hrthm.2014.07.025](#)]
  - 31 **Chew DS**, Wilton SB, Kavanagh K, Vaid HM, Southern DA, Ellis L, Howarth AG, White JA, Exner DV. Fragmented QRS complexes after acute myocardial infarction are independently associated with unfavorable left ventricular remodeling. *J Electrocardiol* 2018; **51**: 607-612 [PMID: [29996998](#) DOI: [10.1016/j.jelectrocard.2018.04.004](#)]
  - 32 **Ciuffo L**, Bruña V, Martínez-Sellés M, de Vasconcellos HD, Tao S, Zghaib T, Nazarian S, Spragg DD, Marine J, Berger RD, Lima JAC, Calkins H, Bayés-de-Luna A, Ashikaga H. Association between interatrial block, left atrial fibrosis, and mechanical dyssynchrony: Electrocardiography-magnetic resonance imaging correlation. *J Cardiovasc Electrophysiol* 2020; **31**: 1719-1725 [PMID: [32510679](#) DOI: [10.1111/jce.14608](#)]
  - 33 **Ferrero P**, Piazza I, Kühl U, Grosu A, Tschöpe C, Senni M. QRS fragmentation as a possible electrocardiographic diagnostic marker in patients with acute myocarditis: preliminary histopathological validation. *ESC Heart Fail* 2020; **7**: 2527-2533 [PMID: [32562382](#) DOI: [10.1002/ehf2.12821](#)]
  - 34 **Fischer K**, Marggraf M, Stark AW, Kaneko K, Aghayev A, Guensch DP, Huber AT, Steigner M, Blankstein R, Reichlin T, Windecker S, Kwong RY, Gräni C. Association of ECG parameters with late gadolinium enhancement and outcome in patients with clinical suspicion of acute or subacute myocarditis referred for CMR imaging. *PLoS One* 2020; **15**: e0227134 [PMID: [31923225](#) DOI: [10.1371/journal.pone.0227134](#)]
  - 35 **Inoue YY**, Ambale-Venkatesh B, Mewton N, Volpe GJ, Ohyama Y, Sharma RK, Wu CO, Liu CY, Bluemke DA, Soliman EZ, Lima JA, Ashikaga H. Electrocardiographic Impact of Myocardial Diffuse Fibrosis and Scar: MESA (Multi-Ethnic Study of Atherosclerosis). *Radiology* 2017; **282**: 690-698 [PMID: [27740904](#) DOI: [10.1148/radiol.2016160816](#)]
  - 36 **Wieslander B**, Nijveldt R, Klem I, Lokhnygina Y, Pura J, Wagner GS, Ugander M, Atwater BD. Evaluation of Selvester QRS score for use in presence of conduction abnormalities in a broad population. *Am Heart J* 2015; **170**: 346-352 [PMID: [26299233](#) DOI: [10.1016/j.ahj.2015.05.005](#)]



- 37 **De Lazzari M**, Zorzi A, Cipriani A, Susana A, Mastella G, Rizzo A, Rigato I, Bauce B, Giorgi B, Lacognata C, Iliceto S, Corrado D, Perazzolo Marra M. Relationship Between Electrocardiographic Findings and Cardiac Magnetic Resonance Phenotypes in Arrhythmogenic Cardiomyopathy. *J Am Heart Assoc* 2018; 7: e009855 [PMID: 30571483 DOI: 10.1161/JAHA.118.009855]
- 38 **Mewton N**, Strauss DG, Rizzi P, Verrier RL, Liu CY, Tereshchenko LG, Nearing B, Volpe GJ, Marchlinski FE, Moxley J, Killian T, Wu KC, Spooner P, Lima JA. Screening for Cardiac Magnetic Resonance Scar Features by 12-Lead ECG, in Patients with Preserved Ejection Fraction. *Ann Noninvasive Electrocardiol* 2016; 21: 49-59 [PMID: 26806840 DOI: 10.1111/anec.12264]
- 39 **Sobue Y**, Harada M, Koshikawa M, Ichikawa T, Yamamoto M, Okuda K, Kato Y, Sarai M, Watanabe E, Ozaki Y. QRS-based assessment of myocardial damage and adverse events associated with cardiac sarcoidosis. *Heart Rhythm* 2015; 12: 2499-2507 [PMID: 26362576 DOI: 10.1016/j.hrthm.2015.09.008]
- 40 **Wieslander B**, Xia X, Jablonowski R, Axelsson J, Klem I, Nijveldt R, Maynard C, Schelbert EB, Sörensson P, Sigfridsson A, Chaudhry U, Platonov PG, Borgquist R, Engblom H, Couderc JP, Strauss DG, Atwater BD, Ugander M. The ability of the electrocardiogram in left bundle branch block to detect myocardial scar determined by cardiovascular magnetic resonance. *J Electrocardiol* 2018; 51: 779-786 [PMID: 30177312 DOI: 10.1016/j.jelectrocard.2018.05.019]
- 41 **Finocchiaro G**, Sheikh N, Biagini E, Papadakis M, Maurizi N, Sinagra G, Pelliccia A, Rapezzi C, Sharma S, Olivetto I. The electrocardiogram in the diagnosis and management of patients with hypertrophic cardiomyopathy. *Heart Rhythm* 2020; 17: 142-151 [PMID: 31349064 DOI: 10.1016/j.hrthm.2019.07.019]
- 42 **Cui H**, Schaff HV, Lentz Carvalho J, Nishimura RA, Geske JB, Dearani JA, Lahr BD, Lee AT, Bos JM, Ackerman MJ, Ommen SR, Maleszewski JJ. Myocardial Histopathology in Patients With Obstructive Hypertrophic Cardiomyopathy. *J Am Coll Cardiol* 2021; 77: 2159-2170 [PMID: 33926651 DOI: 10.1016/j.jacc.2021.03.008]
- 43 **Ariga R**, Tunnicliffe EM, Manohar SG, Mahmood M, Raman B, Piechnik SK, Francis JM, Robson MD, Neubauer S, Watkins H. Identification of Myocardial Disarray in Patients With Hypertrophic Cardiomyopathy and Ventricular Arrhythmias. *J Am Coll Cardiol* 2019; 73: 2493-2502 [PMID: 31118142 DOI: 10.1016/j.jacc.2019.02.065]
- 44 **Li X**, Lai L, Luo R, Yang H, Ma H, Yang Z, Zhao S, Su W, Hua W. The Clinical Prognosis of Presence and Location of Late Gadolinium Enhancement by Cardiac Magnetic Resonance Imaging in Patients with Hypertrophic Cardiomyopathy: a Single-Center Cohort Study. *J Cardiovasc Transl Res* 2021; 14: 1001-1016 [PMID: 33629154 DOI: 10.1007/s12265-021-10107-x]
- 45 **Hayiroğlu Mİ**, Uzun AO, Keskin M, Börklü EB, Tekkeşin Aİ, Türkkkan C, Kozan Ö. A simple independent prognostic electrocardiography parameter in first acute anterior myocardial infarction; Precordial total Q wave/precordial total R wave. *J Electrocardiol* 2018; 51: 38-45 [PMID: 29113641 DOI: 10.1016/j.jelectrocard.2017.09.008]



Published by **Baishideng Publishing Group Inc**  
7041 Koll Center Parkway, Suite 160, Pleasanton, CA 94566, USA

**Telephone:** +1-925-3991568

**E-mail:** [bpgoffice@wjgnet.com](mailto:bpgoffice@wjgnet.com)

**Help Desk:** <https://www.f6publishing.com/helpdesk>

<https://www.wjgnet.com>

