

Available online at www.sciencedirect.com

ScienceDirect

journal homepage: www.elsevier.com/locate/radcr

Case Report

Limb shaking movement as a rare manifestation of transient ischemic attacks caused by carotid stenosis disease: A case report[☆]

Kun Avriady Handoko, MD, Muhammad Hamdan, MD*, Dedy Kurniawan, MD, Ersifa Fatimah, MD

Department Neurology, Faculty of Medicine, Airlangga University – Dr. Soetomo General Hospital, Surabaya 60286, East Java, Indonesia

ARTICLE INFO

Article history:

Received 9 March 2023

Revised 23 March 2023

Accepted 29 March 2023

Keywords:

Carotid stenosis

Limb shaking

Transient ischemic attacks

ABSTRACT

A limb shaking TIA is a less common form of TIA that manifests as involuntary movement and is frequently confused with focal motor epilepsy. A 64-year-old female presented with a 7-month history of episodic involuntary shaking movements affecting her left arm and leg before admission. These attacks primarily occurred after she rose from a sitting or lying down position to a standing position, and were relieved by simply returning to a sitting or lying position. A neurological examination revealed no motor or sensory deficits in either extremity. Her magnetic resonance angiogram (MRA) and carotid Doppler revealed right ICA stenosis in her brain. It is important to distinguish this limb shaking TIA from other conditions such as focal motor seizures. Importantly, early detection and treatment of the associated carotid artery occlusion can not only prevent the patient's TIA episode, but also lower the risk of future stroke.

© 2023 The Authors. Published by Elsevier Inc. on behalf of University of Washington.

This is an open access article under the CC BY-NC-ND license (<http://creativecommons.org/licenses/by-nc-nd/4.0/>)

Introduction

Transient ischemic attacks (TIAs) are commonly characterized by neurological deficits such as unilateral weakness, decreased sensation, or vision loss. They typically last no longer than 24 hours and can occur once or multiple times. A limb shaking TIA is a less common type of TIAs that manifests as involuntary movement and is frequently confused with focal

motor epilepsy [1]. The difficulty in diagnosis stems not only from the phenomenological similarity to seizures, but also from the fact that ischemic infarction is the most common cause of partial seizures in the elderly [2].

It is critical to diagnose this uncommon form of TIA since early detection and treatment dramatically lower the probability of a catastrophic and incapacitating stroke in the future [3]. We present a case of TIA with limb shaking induced by severe contralateral internal carotid artery (ICA) stenosis.

[☆] Competing Interests: The material has not been published previously, and will not be submitted for publication elsewhere. Author declares no conflict of interest, financial, or otherwise.

* Corresponding author.

E-mail address: luki.hamdan@gmail.com (M. Hamdan).

<https://doi.org/10.1016/j.radcr.2023.03.056>

1930-0433/© 2023 The Authors. Published by Elsevier Inc. on behalf of University of Washington. This is an open access article under the CC BY-NC-ND license (<http://creativecommons.org/licenses/by-nc-nd/4.0/>)

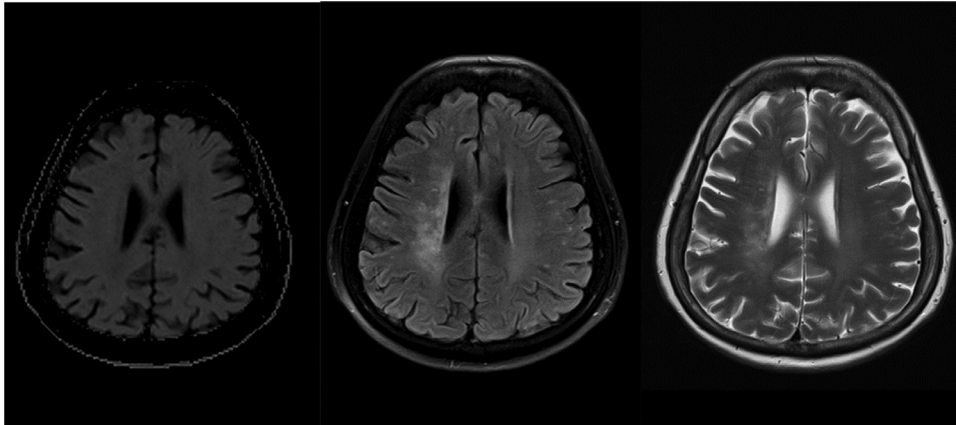


Fig. 1 – Diffusion-weighted imaging (DWI), fluid-attenuated inversion recovery (FLAIR), T2 of the brain revealed subacute right centrum semiovale and corona radiata infarct (internal watershed zone).

Case report

A 64-year-old female reported with a 7-month history of episodic involuntary shaking movement affecting her left arm and leg. These attacks primarily happened when she rose from a sitting or lying down posture to a standing one, and were eased by merely returning to a sitting or sleeping position. These assaults would last a few seconds to less than a minute and might reoccur 2-3 times each week. Throughout any of these incidents, she rejected any concomitant consciousness loss, tongue biting, urine incontinence, or vision abnormalities. The patient never complained of unilateral weakness, numbness, or vision disturbances between bouts. The patient was also given phenytoin orally as an initial medication from the prior hospital, but her symptoms did not improve.

Her medical history includes type II diabetes mellitus and hypertension. Her pulses were normal, and her blood pressure was 169/83 mmHg. A neurological examination revealed no motoric or sensory deficits in either extremity. Magnetic resonance imaging (MRI) (Fig. 1) of the brain revealed a subacute right centrum semiovale and corona radiata infarct (internal watershed zone). Her cerebral magnetic resonance angiogram (MRA) (Fig. 2) and carotid Doppler (Fig. 3) revealed stenosis of the right ICA (90%) and an increase in carotid intimal media thickness. Her electroencephalogram (EEG) showed intermittent right temporal slowing with no epileptiform characteristics.

We identified this patient with low flow TIA followed by limb shaking movement as a result of cerebral hypoperfusion at this point. For the time being, the patient is receiving intense medical care, including dual antiplatelet therapy (clopidogrel 75 mg daily and aspirin 100 mg daily), a high dosage statin, and the discontinuation of her previous antiepileptic drug. Throughout the first week of medication, the patient's symptoms gradually resolved. She was subsequently referred to vascular surgeons, who performed a carotid endarterectomy on her.

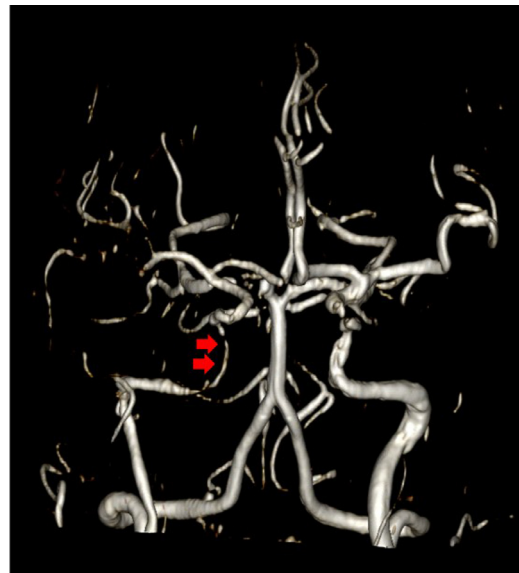


Fig. 2 – Magnetic resonance angiogram (MRA) showed right ICA stenosis (red arrows).

Discussion

Limb shaking TIA is an uncommon manifestation of TIAs and associated with contralateral carotid stenosis. This attack first reported by Miller-Fischer in 1962, described as a brief, jerking or arrhythmic flailing movements of arm or leg or both. A diagnosis of TIA is usually not considered in a patient presenting with episodic abnormal movements, because these attacks are classically believed to be associated with negative neurological symptoms. These attacks can be easily mistaken for focal motor epilepsy, and unsuccessful treatment with antiepileptic agent is often attempted [4].

There are, however, critical clinical indicators that might assist differentiate these events from seizures. These attacks

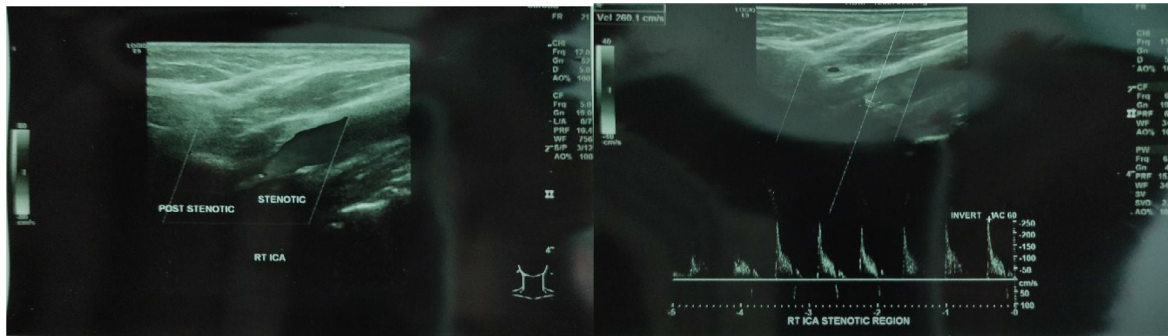


Fig. 3 – Right carotid Doppler showed right ICA stenosis.

are frequently preceded by postural alterations, a lack of aura, urine incontinence, a lack of tongue bite, or any other ictal motor phenomenon [5]. Clusters of rhythmic or arrhythmic involuntary hyperkinesia affecting the hand, arm, leg, hand-arm, or hand-arm-leg unilaterally are clinical characteristics of limb shaking TIA. The hands, arms, and legs are more often affected than the face muscles. The superior extremities are the most commonly affected of these areas [6].

Although the actual cause of the limb shaking TIA has not yet been determined, its incidence, which is associated to severe contralateral carotid stenosis, is thought to be caused by brief cerebral perfusion failure [2]. The fact that symptoms develop following movements that may conceivably cause cerebral hypoperfusion, such as getting out of bed or a chair or hyperextending the neck, is a practically universal clinical signal. In patients with severe carotid stenosis, postural change may momentarily impair brain perfusion [7]. The majority of these assaults, as was the case with our patient, happened when she stood up from a laying or sitting posture.

Inadequate cerebral perfusion and ischemia, particularly in the border zone regions of the cerebral vascular territories, are caused by limb shaking TIAs, which are also accompanied by severe contralateral carotid stenosis [6]. Vascular risk factors for atherosclerosis of large arteries, such the internal carotid artery, include diabetes mellitus, hypertension, and hyperlipidemia [8]. Infarction in the internal watershed area was visible on the patient's MRI. This indicates that there is stenosis in the ipsilateral carotid. Thereafter, the carotid Doppler and MRA of our patient verified the stenosis. These results suggest that the patient's limb tremors are not a focal seizure. The presence of an internal watershed infarction indicates that the limb shaking action is caused by a flow disruption rather than a seizure. Another clinical symptom that strongly supports a diagnosis of limb shaking TIA is the absence of epileptiform activity in ictal or interictal EEG [9]. Our patient also had an EEG recorded, which revealed simply slowing in the right temporal lobe with no epileptiform abnormalities.

Individuals who have these limb shaking TIAs are more likely to have a stroke. Low-flow TIA treatment focuses on preserving or enhancing cerebral blood flow with careful blood pressure control and surgical revascularization. Symptomatic relief has been documented in certain situations following

blood pressure elevation or surgical revascularization, such as endarterectomy [10]. As a result, our patient's care focuses on enhancing cerebral perfusion by treating stroke risk factors with antiplatelet agents and a lipid-lowering medicine, as well as surgical revascularization. In this scenario, carotid endarterectomy can alleviate symptoms and reduce future stroke risk.

Conclusion

It is important to identify this limb shaking TIA from other disorders such as focal motor seizures. A simple query concerning the triggering factor and other related symptoms will aid in the diagnosis of the condition. Notably, early detection and treatment of the related carotid artery stenosis can not only eradicate the patient's TIA episodes but also lower the risk of future stroke.

Patient consent

Patient has given permission and informed consent for the publication of this case report.

REFERENCES

- [1] Das A, Baheti NN. Limb-shaking transient ischemic attack. *J Neurosci Rural Pract* 2013;4:55–6. doi:10.4103/0976-3147.105615.
- [2] Alkutbi A, Elkady A. Limb-shaking transient ischemic attacks masquerading as focal seizures. *Cureus* 2020;12(5):e8157. doi:10.7759/cureus.8157.
- [3] Salah Uddin ABM. Limb shaking transient ischemic attack—an unusual presentation of carotid occlusive disease. A case report and review of the literature. *Parkinsonism Relat Disord* 2004;10:451–3. doi:10.1016/j.parkreldis.2004.04.006.
- [4] FISHER CM. Concerning recurrent transient cerebral ischemic attacks. *Can Med Assoc J* 1962;86(24):1091–9.
- [5] Baquis GD, Pessin MS, Scott RM. Limb shaking—a carotid TIA. *Stroke* [Internet] 1985;16(3):444–8. doi:10.1161/01.STR.16.3.444.

-
- [6] Ali S, Khan MA, Khealani B. Limb-shaking transient ischemic attacks: case report and review of literature. *BMC Neurol* [Internet] 2006;6(1):5. doi:[10.1186/1471-2377-6-5](https://doi.org/10.1186/1471-2377-6-5).
- [7] Yusuf M, Pratama IS, Gunadi R, Sani AF. Hemodynamic stroke in simultaneous cardio cerebral infarction: a new term for cardiologist. *Open Access Maced J Med Sci* 2021;9(C):114–17. doi:[10.3889/oamjms.2021.6388](https://doi.org/10.3889/oamjms.2021.6388).
- [8] Widjaja NA, Irawan R, Prihaningtyas RA, Ardiana M, Hanindita MH. Carotid intima-media thickness, hypertension, and dyslipidemia in obese adolescents. *Pan Afr Med J* 2019;34:134. doi:[10.11604/pamj.2019.34.134.18309](https://doi.org/10.11604/pamj.2019.34.134.18309).
- [9] Yanagihara T, Piepgras DG, Klass DW. Repetitive involuntary movements associated with episodic cerebral ischemia. *Ann Neurol* 1985;18:244–50. doi:[10.1002/ana.41019](https://doi.org/10.1002/ana.41019).
- [10] Siniscalchi A, Gallelli L, Malferrari G, De Sarro G. Limb-shaking transient ischemic attack associated with focal electroencephalography slowing: case report. *J Vasc Interv Neurol* 2012;5(1):3–5.