



Contents lists available at ScienceDirect

## Technical Innovations & Patient Support in Radiation Oncology

journal homepage: [www.sciencedirect.com/journal/technical-innovations-and-patient-support-in-radiation-oncology](http://www.sciencedirect.com/journal/technical-innovations-and-patient-support-in-radiation-oncology)



# Clinical implementation of the first Cherenkov imaging system in a community-based hospital

Erli Chen<sup>a,\*</sup>, Brian W. Pogue<sup>b</sup>, Petr Bruza<sup>b</sup>, Daniel A. Alexander<sup>b</sup>, Nancy L. Andino<sup>a</sup>, Savannah M. Decker<sup>b</sup>, Danielle M. Gaudet<sup>a</sup>, David J. Gladstone<sup>b,c</sup>, Melinda J. Lake<sup>a</sup>, Steven R. Levene<sup>a</sup>, Jennifer L. Michelson<sup>a</sup>, Hila L. Robinson<sup>a</sup>, Debra N. Stallings<sup>a</sup>, John E. Starkey<sup>a</sup>, Lesley A. Jarvis<sup>c,d</sup>

<sup>a</sup> Cheshire Medical Center – Dartmouth Health

<sup>b</sup> Thayer School of Engineering at Dartmouth

<sup>c</sup> Dartmouth Geisel School of Medicine

<sup>d</sup> Dartmouth Cancer Center - Dartmouth Health

## ABSTRACT

**Purpose:** To document experiences with one year of clinical implementation of the first Cherenkov imaging system and share the methods that we developed to utilize Cherenkov imaging to improve treatment delivery accuracy in real-time.

**Methods:** A Cherenkov imaging system was installed commissioned and calibrated for clinical use. The optimal room lighting conditions and imaging setup protocols were developed to optimize both image quality and patient experience. The Cherenkov images were analyzed for treatment setup and beam delivery verification.

**Results:** We have successfully implemented a clinical Cherenkov imaging system in a community-based hospital. Several radiation therapy patient setup anomalies were found in 1) exit dose to the contralateral breast, 2) dose to the chin due to head rotation for a supraclavicular field, 3) intrafractional patient motion during beam delivery, and 4) large variability (0.5 cm to 5 cm) in arm position between fractions. The system was used to deliver deep inspiration breath hold (DIBH) treatment delivery of an electron treatment beam. Clinical process and procedures were improved to mitigate the identified issues to ensure treatment delivery safety and to improve treatment accuracy.

**Conclusion:** The Cherenkov imaging system has proven to be a valuable clinical tool for the improvement of treatment delivery safety and accuracy at our hospital. With only minimal training the therapists were able to adjust or correct treatment positions during treatment delivery as needed. With future Cherenkov software developments Cherenkov imaging systems could provide daily surface guided radiotherapy (SGRT) and real time treatment delivery quality control for all 3D and clinical setup patients without adding additional radiation image dose as in standard kV, MV and CBCT image verifications. Cherenkov imaging can greatly improve clinical efficiency and accuracy, making real time dose delivery consistency verification and SGRT a reality.

## Introduction

In recent years, hypofractionated treatments and patient plan complexity have increased greatly. With fewer total treatment fractions for a course of therapy, the accuracy of each treatment delivery has more of an impact than ever [1]. The ability to monitor and readily adapt to a change in patient position during treatment without adding additional radiation exposure to the patient is the optimal method of delivering high quality treatments.

Cherenkov imaging is one such method for real-time, on patient treatment verification. This method captures light emitted during radiation treatments from tissues when charged particles travel at a velocity exceeding that of light, i.e. the Cherenkov effect. Cherenkov imaging systems enable the treatment team to visualize the extent of the

treatment field and radiation dose on the patient surface [2], providing a view of the treatment delivery in real-time or saved for post-treatment review. Fig. 1 shows the Cherenkov imaging system commissioned for clinical use. Initial experience with patients imaged on clinical trials indicates that Cherenkov imaging can detect MLC shapes and movements, identify patient misalignments that impact accurate treatment delivery and improves incident detection in radiation quality assurance programs [3].

The main purpose of this paper is to share our experience on how we utilized the first Cherenkov imaging system installed in a community based clinic to image patients undergoing routine radiotherapy treatments, and then to improve treatment delivery accuracy for 3D and clinical setups. Specific examples of where clinical practice was improved and also discuss where, with additional features, the system

\* Corresponding author.

<https://doi.org/10.1016/j.tipsro.2022.08.011>

Received 14 June 2022; Received in revised form 12 August 2022; Accepted 30 August 2022

Available online 9 September 2022

2405-6324/© 2022 Published by Elsevier B.V. on behalf of European Society for Radiotherapy & Oncology. This is an open access article under the CC BY-NC-ND license (<http://creativecommons.org/licenses/by-nc-nd/4.0/>).

could improve clinical practice further. The work was carried out using this tool as a standard assisting device, providing a new information stream to the clinical team. We tried to develop optimal practice methods through retrospective analysis of the images, and several case examples are reviewed here.

## Materials and methods

We installed the first Cherenkov imaging system for routine daily clinical use, in our community-based hospital on September 1, 2020. Upon installation, we followed AAPM TG 302 “Surface-guided radiotherapy” [4] recommendations on commissioning, calibrating and end to end testing of this Cherenkov imaging system. We used AAPM TG 100 “Application of risk analysis methods to radiation therapy quality management” [5] to evaluate this new process before releasing it for clinical use in March 15, 2021. During the six months prior to clinical use, we tested, added optical filters and adjusted room light sources, developed the optimal room lighting conditions and setup protocols to optimize both image quality and patient experience. One hour of hands-on operational training of the system was provided to the therapists by the vendor. Daily Cherenkov image system functionality testing was added to the daily machine warm up procedure. Patient body position images and Cherenkov images were recorded and reviewed in real time by therapists and analyzed post-treatment by physicists. We implemented this system for clinical use starting with free breathing (FB) and DIBH breast treatments, and then utilized it for spine and chest treatment sites.

The radiation therapists setup patients normally, according to the approved treatment plan and then imaged the patient per the ordered protocols with kV, MV and/or CBCT. Prior to leaving the room the therapists turned off the field light and ODI / SSD indicators and verified the room lighting dimmer was set at the pre-determined level for optimal Cherenkov imaging. They then delivered the treatments and observed Cherenkov images in real time. Utilizing cumulative Cherenkov image outlines from the first fraction of treatment as reference for the treatment area, they would then pause the treatment and alert the physicist if they observed Cherenkov data outside of the intended treatment area. As appropriate, the therapy team coached the patient to keep still, moved the patient’s hand out of the treatment field, or adjusted the patient’s arm and head positions before resuming the

treatment delivery. If the patients were unable to hold the position, they would pause the treatment and, inform the physician immediately. The treatment would be aborted based on physician’s clinical evaluation, not what was seen on Cherenkov images.

All analysis of patient data presented in this study followed either a Cherenkov clinical trial study or a retrospective protocol approved by our local Internal Review Board. Patient imaging was completed as a standard of care, and retrospective analysis of the data was completed for summary in this report.

## Results

We have successfully implemented a Cherenkov imaging system for clinical use since March 15, 2021 in our community-based hospital. During this year of clinical use, we observed over 1700 treatments with this Cherenkov imaging system that included about 650 DIBH treatments, 1000 3D treatments and 50 electron treatments. We detected several radiation therapy patient setup anomalies and modified our treatment procedures to ensure patient safety and improve the treatment delivery accuracy. We were also able use the Cherenkov imaging system to assist, monitor and gate electron DIBH during treatment delivery. The specific case examples found and our changes to standard procedures are enumerated below:

**Case. #1, Identification of contralateral breast dose.** A patient was treated in FB for a left breast boost treatment, using a breast board, alignment with two leveling tattoos and iso tattoo. During the first fraction of this left breast boost treatment, the Cherenkov image showed exit dose from the LPO field into the right breast as shown in Fig. 2. This type of dose delivery information/confirmation can only be observed with Cherenkov imaging system because common clinically utilized surface guidance systems are not capable of providing any dose delivery information. Upon this discovery, we changed our dosimetry treatment plan isodose display policy. If it is necessary to have a field exit through the contralateral breast due to tumor bed location, the 10 % isodose line must be displayed before sending the plan to the physician for plan evaluation.

**Case. #2, Head rotation causing unplanned dose to the chin.** A patient was treated in FB for a left breast boost treatment, using a breast board, alignment with two leveling tattoos and iso tattoo. On fraction 9 of the right breast treatment, therapists observed Cherenkov emission on the patient’s



**Fig. 1.** The Cherenkov imaging system commissioned for clinical use in our hospital. The left panel shows a Cherenkov camera mounted to the right of the treatment couch. The Right panel shows the Cherenkov image display at the treatment console.

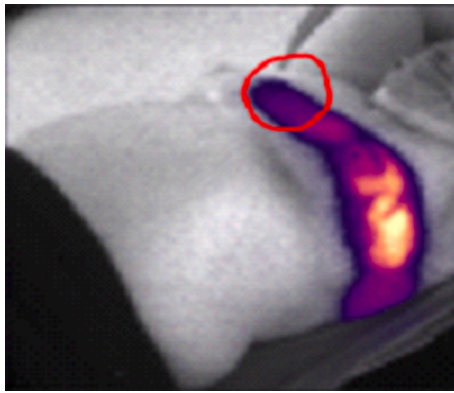


Fig. 2. Cherenkov image from Case #1 shows exit dose from a LPO field into the right breast.

chin due to exit dose from the posterior supraclavicular field, indicating dose being delivered there; The therapist paused the treatment, coached the patient to rotate her head more toward left, and then resumed treatment. Further Cherenkov emission from the chin was not seen during the subsequent treatment or in subsequent fractions.

**Case. #3, Monitoring of patient movement during treatment beam delivery.** A patient was treated for C & T spine with a 3D conformal plan using 3 fields and setup using two leveling tattoos and iso tattoo for alignment. The cumulative Cherenkov image outline from the first day's approved treatment was used as reference treatment area to monitor patient motion during treatment. The therapists observed intrafractional patient motion during delivery of the RPO field. The treatment was paused and the patient was coached to hold still. However, due to pain, the patient could not hold the treatment position. The therapist informed the treating physician immediately; the physician evaluated the patient on the treatment couch and then decided to abort the treatment. The cumulative Cherenkov image outlines documented the spatial dose difference between first fraction and last fraction when patient moved during treatment as shown in Fig. 3.

**Case. #4, Evaluation of positional accuracy of arm and chin.** A patient was on treatment for DIBH to the left breast using a setup with a breast board, alignment with two leveling tattoos and iso tattoo. DIBH Treatment delivery utilized Varian optical surface monitoring system. We observed large variability (0.5 cm to 5 cm) in arm position between each fraction of breast treatments as showing in Fig. 4. Early Cherenkov image research has shown that Cherenkov images can be used to assess positional accuracy [6]. We have tested and utilized the first day treatment position image recorded by the Cherenkov imaging system as a reference to guide daily setup in order to reduce arm position variations.

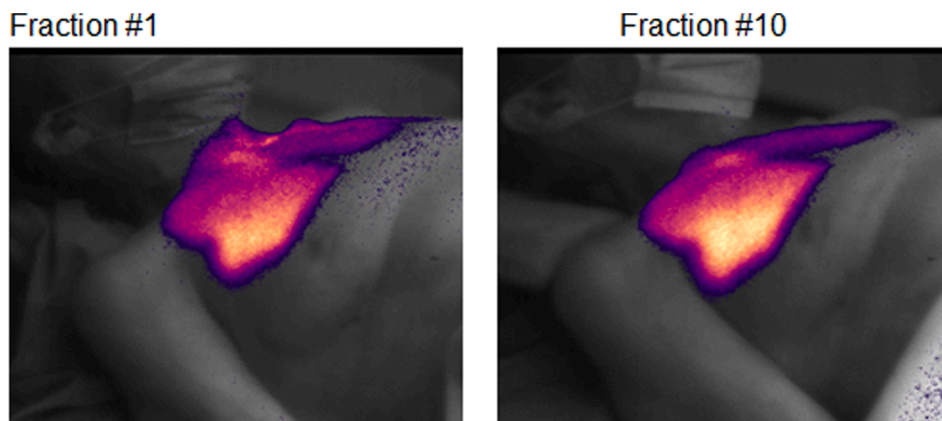


Fig. 3. Case #3, Utilization of cumulative Cherenkov image outline from first day approved treatment as reference treatment area to monitor patient motion.

**Case. #5, Verification of DIBH in an electron treatment.** Due to a tumor bed that was directly located on the top of the heart, electron DIBH treatment was utilized to reduce heart dose. The patient was setup with iso marker on breast board for daily gated electron DIBH treatments with Cherenkov image guidance. We were able to use the recorded body posture images from the initial DIBH photon treatment as the electron DIBH setup reference image. The distance between the end of electron cone to Cherenkov image of the first electron treatment was used to monitor and gate the electron DIBH treatment delivery and to verify treatment delivery accuracy in real time, shown in Fig. 5. Currently no linear accelerator can provide gated electron treatment delivery due to electron cone interference and no optical surface guidance system is designed to provide SGRT for an electron setup. In summary, we successfully utilized the Cherenkov imaging system to monitor, manually gate, deliver and verify electron DIBH treatment accuracies.

## Discussion

The Cherenkov imaging system was found to be a powerful tool, where a range of incidents were found in normal clinical use, and a range of outcomes were observed for each. It is hard to generalize this information, other than to say that the system provided real time feedback of gross treatment delivery accuracy, allowed for visualization of incidents with subsequent root cause analysis and systematic procedure improvement in the department. Perhaps most importantly, the therapists were able to utilize the images to alter treatment fractions or halt treatment delivery when dose was seen on body parts where it was not expected (contralateral breast and chin). Secondly, the imaging system was used to detect unexpected patient motion or variations in daily fractional position that needed to be corrected. These are workflow issues which are not easily categorized nor quantified, but the therapist ability to detect these led to improved treatment delivery through small practice changes in each of the four cases presented.

Case 5 was a situation where the use of the system was deployed with our clinical judgement that this system could be used to manually gate the delivery in DIBH, in a situation where there was no automated gating system available. While this choice was entirely based upon clinical decision making, and the clinical outcome was not really quantified, it presented as an example of improvements that can be made as new technology is presented into the clinic.

Extrapolating from the observations here, our clinical experiences indicate that developing additional user interfaces and functionalities could be useful to increase the clinical efficiency and adoptability. Specifically, future work would benefit from:

- The Cherenkov image system should ideally interface with treatment record and verify system and allow therapists to pull up patients by name or ID to synchronize Cherenkov image recording time with treatment machine delivery time.



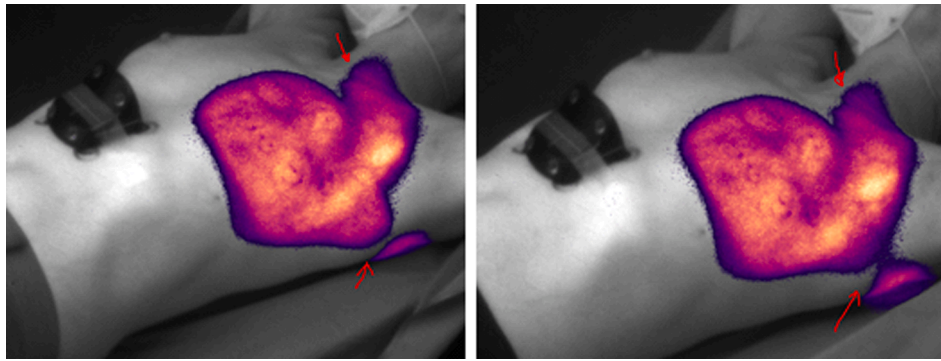


Fig. 4. Cherenkov images from Case #4 show chin and arm position variations between two treatments.

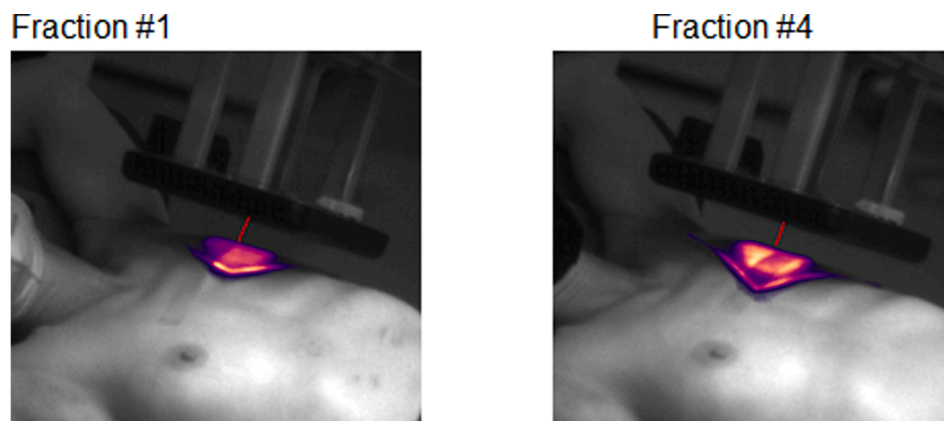


Fig. 5. Using Cherenkov imaging to monitor, gate and verify electron DIBH treatment delivery in Case #5.

- The Cherenkov image system should add an in room monitor and the current console area monitor should be smaller (8" to 10") and placed near the 4D control console of the TrueBeam, the same as the other 4 monitors within the direct view of treating therapists.
- A freehand drawing tool could be added that allows the therapist to trace landmarks such as chin, arm and gating marker positions on the first day treatment body posture images that paired with approved verification images.
- The ability to automatically convert first day Cherenkov body image to a reference image with the body features and marker outlines, then display these first day body outlines and markers on both in room and console monitors which therapists could use to superimpose on to live images to quickly check chin, arm and gating marker positions during treatment setup on following days.
- Display the cumulative Cherenkov image outline from first approved treatment as reference treatment area on the console monitor to enable therapists to evaluate real time gross treatment position accuracy.
- Addition of measuring and annotation tools to assist therapist with real time treatment position accuracy / variation evaluations.
- Automated post treatment image review process, to be able to send an alert for post treatment image analysis and evaluation if there was an anomaly found.

These are suggested features which may be coming, but were apparent upon use of the system in our clinical workflow. Also different than traditional SGRT optical surface monitor devices [7], Cherenkov imaging provides real-time patient positioning and dose information during the beam delivery. Cherenkov imaging can be combined with traditional SGRT systems by modifying the SGRT lights to be compatible with Cherenkov imaging cameras. A combined SGRT/Cherenkov system

is under development and will provide the most information about patient and beam accuracy, both during patient setup and while the treatment is being delivered. The combined system has not been implemented for clinical use and there has not been any direct comparisons between SGRT and Cherenkov. Future work will explore the clinical utility of each individual system, as well as a combined system.

### Conclusion

We have successfully implemented the first community based hospital Cherenkov imaging system. With a brief hands-on training, our therapists were able to operate the system, monitor patients and review the Cherenkov images in real time. Through live monitoring, the therapists can pause the treatment, adjust / correct treatment positions prior to or during treatment delivery as needed. If necessary, the delivery may be aborted. The Cherenkov imaging system has proven to be a valuable clinical tool for the improvement of treatment delivery safety and accuracy at our hospital.

Looking towards the future potential of this technology, to utilize it to its fullest potential in the adaptive SGRT era, Cherenkov software developments are likely necessary. This system might ideally interface with the record and verify system, be able to automatically generate and display body position outlines, markers and cumulative Cherenkov image intensity outlines on both in room and console monitors. We found that the therapists could utilize these outlines to verify the positions of the body, gating marker, arm and bolus in both FB and DIBH positions in real time. This system could be a powerful tool by combining surface image setup guidance, verification, and dose delivery confirmation into one system. A combined system would provide daily SGRT and real time treatment delivery quality control for all 3D and clinical setup patients without adding radiation image dose like standard kV,

MV and CBCT image verifications. We found that Cherenkov Imaging can greatly improve clinical efficiency, accuracy, making real time dose deliver consistency verification and surface guided radiation treatments a reality.

### Declaration of Competing Interest

The authors declare that they have no known competing financial interests or personal relationships that could have appeared to influence the work reported in this paper.

### Acknowledgements

This work was supported by the gift of equipment from DoseOptics LLC, supported by NIH grant R44 CA265654 and analysis through the staff support from the Dartmouth Cancer Center P30 CA023108.

### References

- [1] Fiagan YAC, Bossuyt E, Machiels M, Nevens D, Billiet C, Poortmans P, et al. Comparing treatment uncertainty for ultra- vs. standard-hypofractionated breast radiation therapy based on in-vivo dosimetry. *Phys Imag Radiat Oncol* 2022;22: 85–90.
- [2] Jarvis LA, Zhang R, Gladstone DJ, Jiang S, Hitchcock W, Friedman OD, et al. Cherenkov video imaging allows for the first visualization of radiation therapy in real time. *Int J Radiat Oncol Biol Phys* 2014;89(3):615–22. <https://doi.org/10.1016/j.ijrobp.2014.01.046>.
- [3] Jarvis LA, Hachadorian RL, Jermyn M, Bruza P, Alexander DA, Tendler II, et al. Initial Clinical Experience of Cherenkov Imaging in External Beam Radiation Therapy Identifies Opportunities to Improve Treatment Delivery. *Int J Radiat Oncol Biol Phys* 2021;109(5):1627–37. <https://doi.org/10.1016/j.ijrobp.2020.11.013>.
- [4] Al-Hallaq HA, Cerviño L, Gutierrez AN, Havnen-Smith A, Higgins SA, Kügele M, et al. *AAPM task group report 302: Surface-guided radiotherapy*. *Med Phys* 2022;49(4).
- [5] Saiful Huq M, Fraass BA, Dunscombe PB, Gibbons Jr JP, Ibbott GS, Mundt AJ, et al. *AAPM task group report 100: Application of risk analysis methods to radiation therapy quality management*. *Med Phys* 2016;43:4209. <https://doi.org/10.1118/1.4947547>.
- [6] Gill GS, Hachadorian RL, Alexander DA, Chen E, Bruza P, Gladstone DJ, et al. Cherenkov Imaging to Compare Positional Accuracy of Right Breast Irradiation Setup Using Optical Surface Imaging vs. Traditional Laser Alignment. *Int J Radiat Oncol Biol Phys* 2021;111(3):e532. <https://doi.org/10.1016/j.ijrobp.2021.07.1451>.
- [7] Hachadorian R, Alexander D, Chen E, Gladstone D, Jermyn M, Gill G, et al. Comparing Patient Setup Techniques Between Optical Surface Guidance and Conventional Tattoo/Laser Alignment Using Cherenkov Image Consistency Metrics. *Med Phys* 2021;48(6).