




A Laryngeal Closure Technique for the Treatment of Patients With Head and Neck Cancer

Tatsuya Furukawa, MD; Hirokazu Komatsu, MD; Hisami Fujio, MD, PhD; Yasutaka Kojima, MD; Naruhiko Morita, MD; Masanori Teshima, MD; Hirotaka Shinomiya, MD ; Koichi Morimoto, MD, PhD; Naoki Otsuki, MD, PhD ; Makoto Kano, MD, PhD; Ken-ichi Nibu, MD, PhD 

Background: In 2008, Kano developed a new laryngeal closure technique (Kano's method) for the treatment of severe aspiration. The aim of this study was to evaluate the safety and efficacy of this technique in patients with head and neck cancer.

Methods: Since June 2014 until March 2018, six patients underwent Kano's method for management of severe aspiration after the treatment of head and neck cancers. The anterior parts of the thyroid and the cricoid cartilages were excised widely. The glottis was closed by suturing bilateral vocal folds and reinforced by the sternohyoid muscle. A tracheostoma was created with skin flaps, subglottic mucosal flaps, and stumps of cricoid and trachea cartilages.

Results: No severe complications were observed after the surgery. Oral intake improved without developing aspiration.

Conclusions: Kano's method can provide satisfactory functional results with minimal invasion for treating severe aspiration after advanced surgery, chemotherapy, and/or chemoradiotherapy, in patients with head and neck cancer.

Key Words: Laryngeal closure, severe aspiration, head and neck cancer, Kano's method.

Level of Evidence: 4

INTRODUCTION

In recent years, most patients with advanced head and neck cancer have been treated with multidisciplinary approaches, including surgeries with or without free flap reconstruction, radiotherapy, and chemotherapy. Even though patients receive surgeries to improve their swallowing function, such as laryngeal and cricopharyngeal myotomy, and undergo intensive swallowing rehabilitation, many of them may suffer from severe swallowing dysfunction.

Chronic aspiration and repeated pneumonia may become life threatening events.

Tracheostomy is often employed for preventing such severe aspiration. However, using inflated tracheostomy cuffs may not stop aspiration; therefore, some patients

still may experience aspiration pneumonia. In addition, patients cannot orally take food, so they need to receive percutaneous endoscopic gastrostomy or to use a nasogastric tube for nutrient intake.

To practically prevent aspiration and enable oral intake for patients with severe aspiration, several surgical procedures have been reported, including laryngeal closure and laryngotracheal separation. Total laryngectomy, a classical surgical procedure, has been most widely applied for patients with severe dysphasia since 1960s.¹ Although various new surgical procedures for severe aspiration have been developed,²⁻⁵ the standard surgical procedure has not been established because laryngocutaneous fistulas frequently occur after these surgeries, especially in irradiated patients.

To address this issue, in 2008, Kano developed a new glottic closure technique, called Kano's method, dealing with such problems and reported this procedure as a safe and excellent prevention of aspiration for bedridden patients with malnutrition.⁶ In this method, the anterior parts of the thyroid and the cricoid cartilage are widely removed, and the glottis is closed with incised bilateral vocal folds, which is reinforced by a sternohyoid muscle flap. Encouraged by their reports, we have employed this surgical procedure for the treatment of patients with refractory severe aspiration after their surgeries for head and neck cancer (HNC) since 2014.

MATERIALS & METHODS

Patients

Since June 2014 until March 2018, Kano's method has been performed to prevent refractory severe aspiration in

This is an open access article under the terms of the Creative Commons Attribution-NonCommercial-NoDerivs License, which permits use and distribution in any medium, provided the original work is properly cited, the use is non-commercial and no modifications or adaptations are made.

From the Department of Otolaryngology-Head and Neck Surgery (T.F., H.K., H.F., N.M., M.T., H.S., K.M., N.O., Ken-ichi.N.), Kobe University Hospital, Kobe, Japan; the Department of Otorhinolaryngology-Head and Neck Surgery (Y.K.), Nishi-Kobe Medical Center, Kobe, Japan; and the Department of Otorhinolaryngology-Head and Neck Surgery (M.K.), Ohara General Hospital, Fukushima, Japan

Presentation: A part of this study was presented in 5th congress of Asian Society of Head and Neck Oncology on March 2017 in Bali, Indonesia.

Funding: This work was partly supported by the grant from Japan Agency for Medical Research and Development (Grant#:18ck0106223h003).

Conflict of Interest: The authors have no conflict of interest related to this article to be disclosed.

Send correspondence to Naoki Otsuki, MD, PhD, Department of Otolaryngology-Head and Neck Surgery, Kobe University Hospital, 7-5-1, Kusunoki-cho, Chuo-Ku, Kobe, Hyogo 650-0017, Japan. Email: naokies@medkobe-u.ac.jp

DOI: 10.1002/liv.2.253

TABLE I.
Characteristics of the Patients.

No.	Age	Sex	Primary Disease	Past History	Previous Treatment	Preoperative Status			
						FOIS	Pneumonia	Tracheostomy Speech	Albumin (g/dl) Lymphocyte (μ l)
1	75	M	Oropharyngeal Ca (T3N2bM0) Esophageal Ca (T2N0M0)	COPD	Oropharyngeal Resection Ipsilateral ND Esophagectomy	2	Repeated	Done Normal	3.3 1420
2	70	M	Oral Ca (T4aN2cM0)	Diabetes Dementia	Subtotal Glossectomy Mandibulectomy Bilateral ND Postoperative CRT	1	Repeated	Done Incapable	3.0 1520
3	73	M	Hypopharyngeal Ca (T3N0M0)	Gastric Ca Lung Tumor Prostate Ca. Glottic Ca+	Partial Pharyngectomy Unilateral ND RT	2	Repeated	- Normal	2.5 1540
4	77	M	Oral Ca (T4aN2cM0)	Dementia Gastric Ulcer Diabetes Esophageal Ca. Alcoholism PSP	Subtotal Glossectomy Mandibulectomy Bilateral ND Postoperative RT	1	Once	Done Incapable	4.0 930
5	71	M	Oropharyngeal Ca (T1N2aM0)		Tonsillectomy Unilateral ND CCRT	2	Repeated	- Severe Impaired	3.2 1000
6	76	M	Larynx Ca (T2N2cM0)	Aortic Stenosis Cerebral Aneurysm	CCRT Bilateral ND	1	Repeated	- Severe Impaired	3.5 1320

+ treated by radiation, Ca = cancer; CCRT = concurrent chemoradiotherapy; COPD = chronic obstructive pulmonary disease; FOIS = functional oral intake scale; ND = neck dissection; RT = radiation; PSP = progressive supranuclear palsy.

6 patients who had radical surgery, radiotherapy, and/or chemotherapy for the treatment of HNC.

Indications of Kano's method for qualifying HNC patients are as follows: existing severe swallowing dysfunction and/or refractory severe aspiration pneumonia that is resistant to conservative treatment, acceptance of losing vocal function, and no recurrence of HNC. All patients were men, and their age ranged from 70 to 77. Among them, three patients had double cancers (patient 1 had simultaneous esophageal cancer, and patient 3 previously had

early glottic cancer and received radiotherapy). Two patients received chemoradiotherapy with neck dissection. Four patients received radical surgery with microvascular free flap reconstruction.

Two of those four received postoperative chemoradiotherapy. Details of the six patients were summarized in Table I.

To evaluate the safety and efficacy of Kano's method, we used patients' medical records to collect all data: surgical time, bleeding volume, preoperative nutritional status

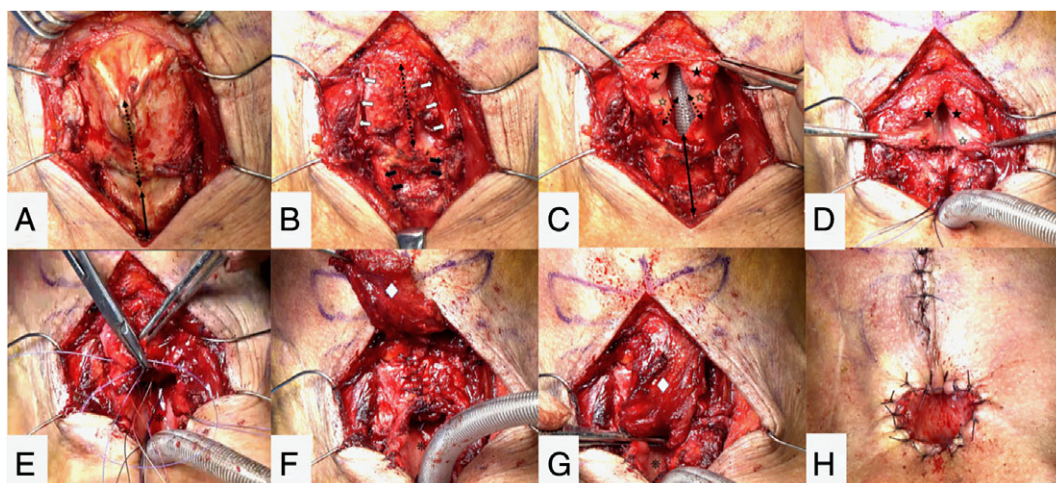


Fig. 1. Surgical Procedure of modified Kano's method. A) dotted line: incision line of the thyroid cartilage; solid line: incision line of the cricoid cartilage; B) white arrows: the edge of the cut surfaces of the thyroid cartilage; black arrows: the edge of the cut surfaces of the cricoid cartilage; dotted line: incision line of the larynx; C) and D) black star: the false vocal cords; white star: the vocal cords; solid line: incision line of the subglottis; dotted line: incision line along the undersurface of the vocal cord; E) and F) asterisk: the submucosal mucosa; white diamond: a sternohyoid muscle flap.

TABLE II.
Operative Results of the Patients.

No.	Surgical Time (min)	Blood loss	Postoperative Complications	Postoperative Status	
				FOIS	Tracheostomy Tube
1	160	40 ml	None	3	Removed
2	156	10 ml	Wound infection	4	Removed
3	166	Little	None	7	Not required
4	241	50 ml	None	3	Removed
5	183	94 ml	Laryngocutaneous fistula	6	Not required
6	160	30 ml	None	5	Not required

FOIS = functional oral intake scale.

(serum albumin and total lymphocyte count), postoperative complications, oral intake status, and a need for a tracheostomy tube. The status of oral food intake was assessed by functional oral intake scale (FOIS).⁷ This study was approved by the Ethical Committee of Kobe University Hospital (No.1589), and written consent was obtained from all patients.

Surgical Procedure of Kano's Method

We carried out Kano's method under general anesthesia, while this surgery was originally performed under local anesthesia.⁶ The patients were kept in the supine position with their necks extended. A vertical skin incision was made from the hyoid bone to the inferior margin of the cricoid cartilage or the existing tracheostoma in the middle of the anterior neck.

The strap muscles were divided along the midline to expose the thyroid and the cricoid cartilages (Fig. 1A). The external and internal perichondrium of the thyroid cartilages were peeled off and preserved to cover over the edge of the cut surfaces. The anterior parts of the thyroid and the cricoid cartilages were widely removed (Fig. 1B). In the case of patients with preoperative tracheostomy, in addition to these cartilages, tracheal cartilage around the tracheostomy tube was also resected. This technique was applicable to all patients who required large tracheostomy. The cricopharyngeal muscles were detached from the cricoid cartilage to improve the pharyngeal passage of a bolus.

A vertical incision was made along the anterior commissure and the pre-epiglottic space to enter the laryngeal cavity (Fig. 1B, 1C).

A horizontal mucosal incision was made along the undersurfaces of the vocal cords (or the upper level of cricoid cartilage) (Fig. 1C). The incised vocal cords and the subglottic mucosal membrane were elevated to make upper and lower mucosal flaps (Fig. 1D). To close the larynx, the right and left vocal cords were sutured with 3-0 or 4-0 absorbable suture (Fig. 1E). Then, a unilateral pedicle sternohyoid muscle flap was elevated (Fig. 1F) to reinforce the glottic closure (Fig. 1G). This muscle flap is helpful for filling the dead space generated between two glottic sutures. The skin flaps were sutured to the

subglottic mucosal membrane to tighten the closure (Fig. 1H). The contralateral sternohyoid muscle was also applied if the amount of muscle flap was insufficient to close the wound.

A draining tube was inserted in the paratracheal space. A large permanent tracheostoma was formed and sutured with 3-0 nylon thread at the level of the cricoid cartilage and the upper tracheal ring to prevent tracheal stenosis and to eliminate the use of tracheostomy tube after surgery (Fig. 1H). Finally, the remaining skin incision was closed. The draining tube and the tracheostomy tube were removed on postoperative day (PO) 2 or PO 3. Oral intake was started after PO 7.

RESULTS

Operating time ranged from 156 to 241 minutes (mean: 180 min). With patient 4, surgical time required about 4 hours due to the severe fibrosis, since he suffered neck abscess after subtotal glossectomy and received postoperative radiotherapy. Bleeding volume was small, and no patients required blood transfusion. Although no major postoperative complications were observed, subcutaneous infection and a small laryngocutaneous fistula were noted in patients 2 and 5, respectively. These complications were successfully managed by local treatment within 1 to 2 weeks without additional surgeries or hospitalization. Oral food intake was achieved without developing aspiration in all patients, and no patients required a tracheostomy tube. Follow-up periods after operation ranged from 5 to 33 months (mean: 15 months). The summaries of surgical results were shown in Table II.

DISCUSSION

In this study, surgical laryngeal closure was successfully performed to prevent chronic aspiration in all six patients with Kano's method. No severe complication, including major laryngocutaneous fistula, postoperative bleeding, or stenosis of permanent tracheostoma, were observed after surgery. The mean surgical time was not shorter compared to previous reports, because fibrous tissues caused by radiotherapy and postoperative abscess, and the mean amount of intraoperative bleeding was acceptable. The patients' postoperative course went smoothly, and all patients recovered within few days after surgery.

Total laryngectomy has been a familiar surgical procedure for head and neck surgeons, but it is relatively invasive and may cause complications, such as pharyngocutaneous fistula. Patients and their families also recognize total laryngectomy as invasive for the treatment of laryngeal cancer and hesitate to accept this surgical procedure for preventing aspiration. In the Radiation Therapy Oncology Group 91-11 trial, Weber et al. reported 129 patients with recurrent laryngeal carcinoma received total laryngectomy as salvage surgery after radiotherapy or concurrent chemoradiotherapy.⁸ Among them, major complications, which were defined as prolonged hospitalization and life threatening, were observed in 28 patients (22%). In a clinical setting,

Theunissen et al. reported higher rates of pharyngocutaneous fistulas were observed in more than 40% of patients.⁹

Between 1970s and 1980s, various surgical techniques, including glottic closure (Montgomery operation),² tracheoesophageal anastomosis (Lindeman operation),³ modified and conservative total laryngectomy (Cannon and Hawthorne)^{5,10} were proposed to treat aspiration.

These surgeries are less invasive than classical total laryngectomy, but also have several shortcomings. In 1975, Montgomery reported a simple method in which bilateral vocal cords were sutured together to eliminate the necessity for a total laryngectomy. However, a small glottic chink may remain posteriorly in this method. Lindemann and Eisele developed laryngotracheal separation and tracheoesophageal diversion. Theoretically, these procedures are reversible, which is the biggest advantage. Most patients and families expected to recover the function of speech, especially in children. However, reverse surgery was indicated only in few limited cases. In addition, these surgeries usually require an approach to the fourth and/or fifth tracheal rings, which are often located in upper mediastinum in an aged male.

In Japan, the number of elderlies has been increasing at an astonishing rate, and patients with dysphagia also continue to increase. To address this issue, several new safe and less invasive surgeries, such as central-part laryngectomy,¹¹ tracheal flap method,¹² and laryngeal closure,⁶ have been developed to prevent aspiration. Among them, laryngeal closure (Kano's method) has been most widely performed, since Kano's methods have several advantages, such as lower rate of leakage, large tracheostoma, operability for patients with lower larynx and/or obesity, and feasibility of simultaneous cricopharyngeal myotomy.¹³ This method also has the merits of cannula-free care and minimizing the risk of developing trachea-innominate artery fistula.¹⁴ In addition, the greatest advantage of this method for patients treated with HNC advanced surgery and/or chemoradiotherapy is a lower rate of laryngocutaneous fistula.

This method, laryngeal closure is secured by three layers, vocal cord flaps, a sternohyoid muscle flap, and a subglottic mucosal flap. Even if the first layer (the vocal cord flaps) is separated, muscle flaps, which are abundant in blood circulation, can block the leakage, and the third layer (the subglottic mucosal flap) will likely reinforce the muscle flaps. While minor leakage was observed around permanent tracheostoma in patient 5, a pin hole had spontaneously closed after 2 weeks without additional surgical procedures. Originally in Kano's method, the vocal cords were separated to the upper layer and lower layer. However, in the present series,

considering the possible impaired condition due to the previous treatments, a horizontal mucosal incision was made relatively caudally; that is, along the undersurfaces of the vocal cords or along the upper level of cricoid cartilage to thicken vocal cord flaps.¹⁵ This modification certainly contributes to the present favorable results in spite of the severe conditions.

We acknowledge that there are several limitations in this study. The number of patients was small, and there was no direct comparison to other methods. Multi-institutional study should be performed to further evaluate the efficacy and safety of this method.

CONCLUSIONS

Kano's method can provide satisfactory functional results with minimal invasion and acceptable minor complications for the treatment of severe aspiration of patients with HNC treated with advanced surgery and/or chemoradiotherapy.

BIBLIOGRAPHY

1. Smith AC, Spalding JM, Ardran G, Livingstone G. Laryngectomy in the management of severe dysphagia in non-malignant conditions. *Lancet* 1965;2(7422):1094-1096.
2. Montgomery WW. Surgery to prevent aspiration. *Arch Otolaryngol* 1975;101(11):679-682.
3. Lindeman RC. Diverting the paralyzed larynx: a reversible procedure for intractable aspiration. *Laryngoscope* 1975;85(1):157-180.
4. Eisele DW, Yarrington CT Jr, Lindeman RC, Larrabee WF Jr. The tracheoesophageal diversion and laryngotracheal separation procedures for treatment of intractable aspiration. *Am J Surg* 1989;157(2):230-236.
5. Cannon CR, McLean WC. Laryngectomy for chronic aspiration. *Am J Otolaryngol* 1982;3(2):145-149.
6. Kano M, Kuwahata N, Takatori T, Kida M. Surgical closure of the larynx with removing cricoid cartilage for intractable aspiration pneumonia in bedridden patients. *Larynx Japan* 2008;20(1):5-12.
7. Cray MA, Mann GD, Groher ME. Initial psychometric assessment of a functional oral intake scale for dysphagia in stroke patients. *Arch Phys Med Rehabil* 2005;86(8):1516-1520.
8. Weber RS, Berkey BA, Forastiere A, et al. Outcome of salvage total laryngectomy following organ preservation therapy: the Radiation Therapy Oncology Group trial 91-11. *Arch Otolaryngol Head Neck Surg* 2003;129(1):44-49.
9. Theunissen EA, Timmermans AJ, Zuur CL, et al. Total laryngectomy for a dysfunctional larynx after (chemo)radiotherapy. *Arch Otolaryngol Head Neck Surg* 2012;138(6):548-555.
10. Hawthorne M, Gray R, Cottam C. Conservative laryngectomy (an effective treatment for severe aspiration in motor neurone disease). *J Laryngol Otol* 1987;101(3):283-285.
11. Kawamoto A, Katori Y, Honkura Y, et al. Central-part laryngectomy is a useful and less invasive surgical procedure for resolution of intractable aspiration. *Eur Arch Otorhinolaryngol* 2014;271(5):1149-1155.
12. Ninomiya H, Yasuoka Y, Inoue Y, et al. Simple and new surgical procedure for laryngotracheal separation in pediatrics. *Laryngoscope* 2008;118(6):958-961.
13. Kanazawa H, Fujishima I. Method and clinical results of a new glottic closure procedure combined with cricopharyngeal myotomy for intractable aspiration with cricopharyngeal dysfunction. *Deglutition* 2012;1(2):374-378.
14. Ise K, Kano M, Yamashita M, et al. Surgical closure of the larynx for intractable aspiration pneumonia: cannula-free care and minimizing the risk of developing trachea-innominate artery fistula. *Pediatr Surg Int* 2015;31(10):987-990.
15. Uchida M, Inuci T, Yamamichi R, Mukudai S, Dejima K. Minimally invasive surgical procedure for the prevention of severe aspiration - laryngectomy of the laryngeal closure in the subglottic area. *Deglutition* 2016;5(1):68-75.