

The role of a novel self-expanding metal stent in variceal bleeding: a multicenter Australian and New Zealand experience ▶

OPEN
ACCESS



Authors

Saad Khan^{1,2}, Rajit Gilhotra², Caroline Di Jiang³, David Rowbotham⁴, Andre Chong⁵, Avik Majumdar⁵, Campbell White⁶, Alex Huelsen⁷, Jim Brooker⁸, James O'Beirne⁹, Cameron Schauer¹⁰, Marios Efthymiou¹, Rhys Vaughan¹, Sujievvan Chandran¹

Institutions

- 1 Department of Gastroenterology and Liver Transplant Unit, Austin Health, Melbourne, Victoria, Australia
- 2 Department of Gastroenterology and Hepatology, Royal Brisbane and Women's Hospital, Brisbane, Queensland, Australia
- 3 Department of Gastroenterology and Hepatology, Auckland District Health Board, Auckland, New Zealand
- 4 Department of Gastroenterology, Fiona Stanley Hospital, Perth, Western Australia
- 5 AW Morrow Gastroenterology and Liver Centre, Royal Prince Alfred Hospital, Sydney, New South Wales, Australia
- 6 Department of Gastroenterology, Taranaki Base Hospital, Taranaki District Health Board, New Zealand
- 7 Department of Gastroenterology, Princess Alexandra Hospital, Brisbane, Queensland, Australia
- 8 Department of Gastroenterology, Waikato District Health Board, Hamilton, New Zealand
- 9 Department of Gastroenterology and Hepatology, Sunshine Coast University Hospital, Sunshine Coast, Queensland, Australia
- 10 Department of Gastroenterology, Middlemore Hospital, Counties Manukau District Health Board, Auckland Hospital, New Zealand

submitted 15.2.2021

accepted after revision 19.10.2021

Bibliography

Endosc Int Open 2022; 10: E238–E245

DOI 10.1055/a-1729-0104

ISSN 2364-3722

© 2022. The Author(s).

This is an open access article published by Thieme under the terms of the Creative Commons Attribution-NonDerivative-NonCommercial License, permitting copying and reproduction so long as the original work is given appropriate credit. Contents may not be used for commercial purposes, or adapted, remixed, transformed or built upon. (<https://creativecommons.org/licenses/by-nc-nd/4.0/>)

Georg Thieme Verlag KG, Rüdigerstraße 14,
70469 Stuttgart, Germany

Corresponding author

Dr. Saad Khan, Department of Gastroenterology and Hepatology, Level 9, Ned Hanlon Building, Royal Brisbane and Women's Hospital, Herston, QLD 4006, Australia
Fax: +61 7 3371 6650
saadkhan2304@gmail.com

ABSTRACT

Background and study aims Refractory variceal bleeding is associated with high mortality in patients with chronic liver disease. A fully-covered self-expanding metal stent (SEMS) has been reported to have excellent rates of technical success and initial bleeding control; however, studies to date are small and limited to Europe and Asia. Our aim was to evaluate the efficacy and safety of this SEMS for control of refractory variceal bleeding (VB).

Patients and methods A retrospective analysis was undertaken of all patients who received the SX-ELLA Danis SEMS for management of VB at 9 tertiary centers across Australia and New Zealand. A total of 32 SEMS had been deployed in 30 patients (median age 53.3).

Results Technical success of SEMS placement was achieved in 100% of cases, resulting in immediate control of bleeding across 31 of 32 cases (96.9%). Re-bleeding with SEMS in situ occurred in three of 32 cases (9.4%). Mean SEMS in-dwelling time was 6.4 days. Delayed SEMS migration occurred in 6.3% of cases. Interventional radiological therapy for management of varices within 6 weeks was performed in 12 of 30 patients (40%). Death with SEMS in situ occurred in seven of 30 patients (23.3%). Seven-day bleeding-related mortality was 16.7%, 14-day mortality 23.3%, and 6-week mortality 33.3%. Three of 30 patients (10%) received orthotopic liver transplantation following SEMS insertion, including two patients within 6 weeks.

Conclusions SX-Danis Ella SEMS is highly effective for immediate control of refractory VB and bridging to definitive therapy because it has excellent technical success rates, appears to be relatively easy to use, and has low rates of serious adverse events.

Introduction

Variceal bleeding (VB) is a serious complication of chronic liver disease (CLD) and portal hypertension, with overall mortality of 12% to 20% [1–3]. The current conventional management of VB includes early hemodynamic stabilization, administration of vasoactive drugs (terlipressin, somatostatin, or analogs) and antibiotic prophylaxis, followed by early esophagogastroduodenoscopy (EGD) and endoscopic band ligation (EBL) [1, 4, 5]. Despite conventional measures failure to control VB occurs in up to 20% of cases [6, 7], and is associated with much higher mortality rates of 30% to 50% [1, 6, 8].

In cases of refractory VB, where bleeding is not controlled with primary endoscopic and pharmacological therapy, management options are limited and usually require rescue therapies such as balloon tamponade (BT) or the insertion of a transjugular intrahepatic portosystemic shunt (TIPS). BT using a Sengstaken-Blakemore tube (SBT) allows for temporary control of VB by direct compression of the variceal column at the gastroesophageal junction, but is recommended to be used for a maximum of 24 hours as a bridge to definitive therapy [1]. While BT is effective for immediate control of bleeding in up to 91% of cases, its use is associated with significant complications, including esophageal tears, perforation, mucosal ischemia, aspiration, and re-bleeding upon deflation of BT [4, 5, 9]. The requirement for ongoing tracheal intubation and delays in commencement of enteral nutrition are also undesirable factors associated with use of BT. Early or rescue TIPS in the setting of refractory VB bleeding provides definitive therapy and has been shown to reduce rates of uncontrolled bleeding, re-bleeding and mortality [4, 10–12]. However, TIPS poses a risk of progressive liver function deterioration, hepatic encephalopathy and acute heart failure, and is associated with a 30-day mortality of 30% when used as a rescue therapy [4, 13]. Importantly, the widespread use of TIPS is limited by technical difficulties as well as the availability of interventional radiological services and expertise.

Recently, a novel fully-covered, self-expanding metal stent (SEMS) (SX-ELLA Danis stent; ELLA-CS, Hradec Kralove, Czech Republic) dedicated for use in the setting of VB has emerged as an alternative to BT. This SEMS has high rates of technical success and hemostasis in cases refractory to conventional medical and endoscopic therapies [14–20]. Published studies to date, however, are small and limited to Europe and Asia. Proposed advantages of the novel SEMS over conventional BT include its ease of insertion, lower rates of adverse events, as well as the ability to extubate patients and commence early enteral feeding. Another advantage is that the SEMS can be left in situ for up to 7 days, allowing adequate time as an effective bridge to subsequent definitive therapy. These potential advantages, however, need to be weighed carefully against the concerns of bleeding associated with SEMS-related ulceration and SEMS migration. A recent small randomized controlled trial comparing this SEMS to SBT in patients with refractory VB showed superior control of bleeding and lower serious adverse events and transfusion requirements in the SEMS group, although there was no difference in survival at 6 weeks [21]. A re-

cent systematic review and meta-analysis showed a high success rate with stent deployment (96.7%) and complete hemostasis (93.9%); however, the data had significant heterogeneity and did not include any studies from the Oceania region [22].

The aim of this international multicenter study was to evaluate the efficacy and safety of this novel SEMS for management of VB in the real world in Australia and New Zealand.

Patients and methods

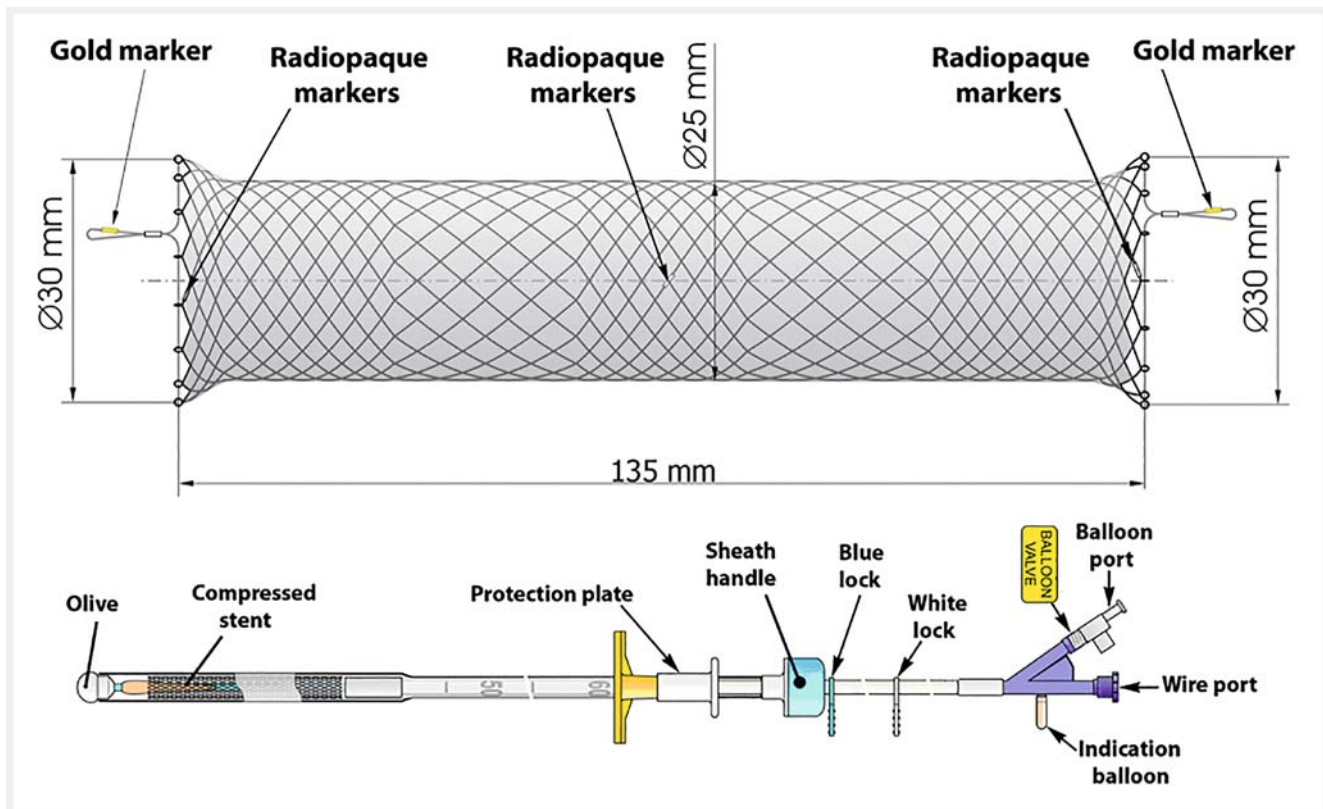
A multicenter retrospective then prospective study was conducted across 9 tertiary therapeutic endoscopy centers in Australia and New Zealand. All patients with CLD who received the SX-Ella Danis SEMS for management of variceal bleeding since its introduction in the Oceania region up to September 2019 were included in the study. Data were collected prospectively upon commencement of the study, while data on all consecutive cases prior to this date were collected retrospectively. The commencement date for prospective data collection and, therefore, the proportion of prospective cases varied between centers. If one patient received a second SEMS due to re-bleeding, this was also included for data analysis. A standardized data spreadsheet capturing patient demographics, clinical details, endoscopic findings, clinical outcomes, and adverse events (AEs) was distributed to all participating centers for data collection from local databases and patient records. The study received ethical approval from our institutional review board (Austin Health Human Research Ethics Committee). The study concept and design were investigator initiated and no financial support was received. Data collection was performed in accordance with the provisions of the Declaration of Helsinki.

Study device

The SX-Ella Danis stent evaluated in this study is a removable, fully-covered, SEMS dedicated for use in the lower esophagus for management of variceal bleeding. The SEMS is 135 mm in length with a 25-mm diameter and is designed to tamponade bleeding varices in the distal esophagus. The SEMS is deployed using a novel insertion system in which a gastric balloon is inflated to anchor the distal end of the SEMS at the gastroesophageal junction when traction is applied, allowing correct positioning in the lower esophagus upon deployment without the requirement for direct endoscopic or fluoroscopic guidance. The stent has gold marked loops at the proximal and distal ends that can be used for repositioning or removal, as well as radiopaque markers to confirm position on radiography (► **Fig. 1**). The SEMS can be left in situ for up to 7 days and is designed to be removed endoscopically using the accompanying stent removal device.

Patient management

All patients with CLD who presented with suspected upper gastrointestinal bleeding received standard-of-care pharmacological therapy according to individual center protocols. All patients underwent index EGD, with the timing of EGD as well as procedural decisions at the discretion of the treating endos-



► **Fig. 1** (top) Self-expanding metal stent and (bottom) novel insertion system. After introduction of the insertion system into the upper gastrointestinal tract, the system is fixed against the mouth guard by removing the blue lock. The remainder of the system is advanced until the white lock meets the sheath handle. The gastric balloon is inflated with 100 mL to 120 mL of air through the balloon port using a large-volume syringe. Traction is applied to the whole delivery system, anchoring it against the gastroesophageal junction and allowing appropriate positioning. To deploy the stent, the white lock is removed and while holding the distal end of the delivery system still, the sheath handle is pulled back until it reaches the distal extend of the delivery system. This deploys the stent and also deflates the gastric balloon. The stent can be deployed without a need for direct endoscopic or fluoroscopic guidance. The balloon port valve is unscrewed and removed to ensure the gastric balloon is deflated before removal of the delivery device. The SEMS has gold marked loops at the distal and proximal ends that can be used to reposition or remove it, as well as radiopaque markers to confirm position on radiography. (Source: ELLA <http://ellacs.cz/en/danis-stent> (Leaflet – Danis Stent))

copist or clinician. VB was deemed to be refractory by the treating endoscopist when conventional therapies failed to control active bleeding during the index endoscopy. At this time, either the SEMS or a SBT was inserted for control of bleeding. If an SBT was inserted for initial control, the SEMS was then inserted electively upon removal of the SBT. All clinical decisions following SEMS insertion were based on treating clinician or individual center preference, including the timing of SEMS removal, requirement for radiological therapies and assessment for orthotopic liver transplantation (OLT).

Outcome measures and definitions

The primary outcome of this study was to evaluate immediate control of bleeding and overall control of bleeding for the duration of SEMS in-dwelling time. Immediate control of bleeding was defined as cessation of active VB as confirmed by endoscopic views. Re-bleeding was defined as per the Baveno V guidelines as hematemesis, melena, or aspiration of >100 mL of fresh blood in patients with a nasogastric tube and/or decrease in hemoglobin of 3 g/dL without blood transfusion [23].

Secondary endpoints included procedural technical success, early and delayed adverse events, AEs associated with SEMS removal, requirement for parenteral nutrition, requirement for definitive radiological therapy with TIPS or balloon-occluded retrograde transvenous obliteration (BRTO), and 6-week bleeding-related mortality. Endoscopists were also asked to subjectively score the ease of insertion and removal of SEMS compared to the use of SBT. A 5-point scoring scale was used, where 1 = much more difficult, 2 = more difficult, 3 = the same, 4 = easier to 5 = much easier. Procedural technical success was defined as successful deployment of the SEMS in the distal esophagus and confirmation of adequate positioning on chest radiography. Bleeding-related mortality was defined as mortality as a direct result of VB, or due to progressive decompensated liver failure following VB.

Statistical analysis

Quantitative descriptive analysis was performed and data were presented in numerical form with a range and standard deviation.

Results

Patients and demographics

A total of 32 SEMS were deployed in 30 patients with CLD for refractory VB during the study period. The mean age of our patient cohort was 53.3 (SD 7.9) (male: 66.6%, female: 33.3%). The etiologies of CLD were predominantly alcohol-related (50%), hepatitis B virus (13.3%), hepatitis C virus (13.3%), and non-alcoholic steatohepatitis (10%). The majority of patients (19/30, 63%) had a history of prior variceal hemorrhage and 23 of 30 patients (76.7%) had previously undergone EBL. The mean Model for End-Stage Liver Disease (MELD) score at presentation was 20.3 points (SD 8.4). Complete patient demographics are summarized in ► **Table 1**.

Endoscopic findings

At index endoscopy, the source of gastrointestinal bleeding was deemed to be from esophageal varices in 24 of 30 patients (80%), gastroesophageal varices type 1 (GOV-1) in two of 30 patients (6.7%), and EBL-induced ulcer in four of 30 patients (13.3%). The SEMS was inserted during index endoscopy for refractory bleeding despite conventional endoscopic therapies in 22 of 32 cases (68.8%). In two of 22 of these cases, SBT placement was attempted but failed to control bleeding and therefore progressed directly to SEMS placement. In two of 32 cases (6.2%), initial control of bleeding was achieved during the index endoscopy with conventional therapies; however, early re-bleeding occurred which could not be controlled with conventional endoscopic therapy, necessitating SEMS insertion at repeat endoscopy. Initial control of bleeding was achieved by SBT placement in eight of 32 cases (25%) and the SEMS was then inserted electively following SBT removal. In five of eight of these cases, patients were deemed poor candidates for TIPS so received the SEMS for ongoing bleeding control. In the remaining three of eight cases, the SEMS was used as a bridge to TIPS.

SEMS insertion

Technical success of SEMS placement was achieved in 32 of 32 cases (100%). There was immediate SEMS migration in one of 32 cases (3.1%) due to rupture of the gastric balloon; however, the stent was successfully re-positioned using forceps. SEMS were inserted by a gastroenterologist in 22 of 32 cases (68.8%), an interventional endoscopist in eight of 32 cases (25%) and a general surgeon in two of 32 cases (6.2%). All cases were performed without fluoroscopy. SEMS were inserted in the operating theater in 18 of 32 cases (56.3%), in the intensive care unit in eight of 32 cases (25%) and in the endoscopy suite in six of 32 cases (18.7%).

Control of bleeding

Initial control of acute bleeding was achieved in 31 of 32 cases (96.9%). In the one case of treatment failure, ongoing bleeding from a band-induced ulcer in the distal esophagus occurred despite successful SEMS placement. A repeat endoscopy was performed the next day, at which point, the initial SEMS was removed and following failed cyanoacrylate injection, a second

► **Table 1** Patient demographics, clinical characteristics and endoscopy details.

Variable	Number	%
Age, years	53.3 (38 – 69) ¹	
Sex		
▪ Male	20/30	66.7
▪ Female	10/30	33.3
Etiology of CLD		
▪ Alcohol	15/30	50
▪ HBV	4/30	13.3
▪ NASH	3/30	10
▪ HCV + alcohol	3/30	10
▪ HCV	1/30	3.3
▪ DILI	1/30	3.3
▪ AD-PCKD	1/30	3.3
▪ Recurrent EPP	1/30	3.3
▪ PBC/AIH overlap	1/30	3.3
Previous variceal hemorrhage	19/30	63.3
Previous variceal banding	23/30	76.7
MELD Score on presentation	20.3 (7–40) ¹	
Cause of variceal hemorrhage		
▪ Esophageal varices	24/30	80
▪ GOV-1 ²	2/30	6.7
▪ Band-induced ulcer	4/30	13.3
Reason for SEMS use		
▪ Refractory bleeding despite conventional endoscopic therapies	22/32	68.8
▪ Electively after SBT removed	8/32	25
▪ Early re-bleeding after initial bleeding control with conventional therapies	2/32	6.2

¹ Variable presented as mean with range in brackets.

² Gastroesophageal varices as per Sarin's classification. CLD, chronic liver disease; HBV, hepatitis-B virus; NASH, non-alcoholic steatohepatitis; HCV, hepatitis-C virus; DILI, drug-induced liver injury; AD-PCKD, autosomal dominant polycystic kidney disease; EPP, erythropoietic protoporphyria; PBC, primary biliary cholangitis; AIH, autoimmune hepatitis; MELD, model for end-stage liver disease; SEMS, self-expanding metal stent; SBT, Sengstaken-Blakemore tube.

SEMS was placed, resulting in control of acute bleeding. Re-bleeding with SEMS in situ occurred in three of 31 cases (9.7%). In one-third of these cases, this was due to delayed stent migration and the patient progressed immediately to rescue TIPS. The remaining two-thirds of patients had their initial SEMS removed and a second SEMS placed following cyanoacrylate injection. Re-bleeding occurred in one patient 4 months following discharge from hospital. Overall, 28 of 32 cases

(87.5%) achieved control of bleeding for the duration of SEMS in-dwelling time.

Clinical outcomes

The mean SEMS in-dwelling time was 6.4 days (SD 3.6). Successful tracheal extubation occurred at a median of 1 day (range 0 to 8) following SEMS insertion (excluding patients who died prior to extubation). Enteral nutrition was able to be commenced with SEMS in situ in 25 of 30 patients (83.3%), at a median of 2 days post SEMS insertion. Total parenteral nutrition was required in four of 30 patients (13.3%). The median intensive care unit (ICU) length of stay was 2.5 days following SEMS insertion (range 0 to 10). The median overall hospital length of stay was 13.5 days (range 1–38); however, the median hospital length of stay following SEMS insertion was 12 days (range 1 to 38). Interventional radiological therapy for management of varices within 6 weeks of SEMS insertion was performed in 12 of 30 patients (40%). Eleven of 12 of those patients (91.7%) received a TIPS alone, while one of 12 (8.3%) received both TIPS + BRTO. One of 12 patients (8.3%) received salvage TIPS, while the remaining 11 of 12 patients (91.7%) received a planned preemptive TIPS. Overall, three of 30 patients (10%) had received OLT at the time of study data evaluation, including two of 30 patients (6.7%) within 6 weeks of SEMS insertion.

Bleeding-related mortality

Death with SEMS in situ occurred in seven of 30 patients (23.3%). Bleeding-related mortality occurred in 10 of 30 patients (33.3%), with a 7-day, 14-day, and 6-week mortality of 16.7% (5/30), 23.3% (7/30), and 33.3% (10/3), respectively. One non-bleeding-related mortality was secondary to a spontaneous intracranial hemorrhage 1 month following SEMS removal, while the other non-bleeding-related mortality occurred 11 months following SEMS removal. Complete clinical outcomes are summarized in ► **Table 2**.

Adverse events

Delayed SEMS migration occurred in two of 32 cases (6.3%), resulting in major bleeding in one case and no adverse outcome in the other. There was oozing from SEMS-related ulcers in two of 32 cases (6.3%) without the requirement for further intervention. AEs associated with SEMS removal included minor self-limited oozing in three of 25 cases (12%) and major bleeding in one of 25 cases (4%), which was successfully managed with EBL.

Ease of use

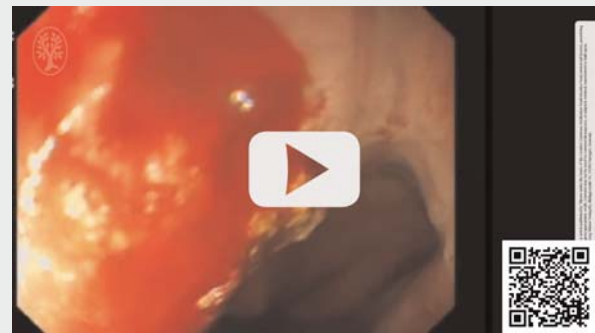
Compared to the ease of SBT insertion, SEMS insertion was felt to be easier or much easier in 15 of 32 cases (46.9%), and the same in eight of 32 cases (25%). There were no cases in which insertion was deemed to be more difficult than SBT insertion. No answer was received in nine of 32 cases (28.1%). Compared to SBT removal, SEMS removal was felt to be easier or much easier in eight of 25 cases (32%), and the same in seven of 25 cases (28%). SEMS removal was deemed to be more difficult in two of 32 cases (6.3%), and no answer was received in eight of 25 cases (32%). (See ► **Video 1**.)

► **Table 2** Clinical outcomes.

Variable	No.	%
Technical success	32/32	100
Control of bleeding		
▪ Immediate	31/32	96.9
▪ For duration of SEMS in-dwelling time	28/32	87.5
▪ Re-bleeding with SEMS in-situ	3/32	9.4
Use of definitive therapies within 6 weeks		
▪ Preemptive TIPS following SEMS success	11/30	36.7
▪ Salvage TIPS following SEMS failure	1/30	3.3
▪ OLT	2/30	6.7
6-week bleeding-related mortality		
▪ Overall	10/30	33.3
▪ With SEMS in situ	7/30	23.3
▪ Without definitive therapy	10/16	62.5
▪ With definitive therapy	0/14	0
Overall mortality	12/30	40

SEMS, self-expanding metal stent; TIPS, transjugular intrahepatic portosystemic shunt; OLT, orthotopic liver transplantation.

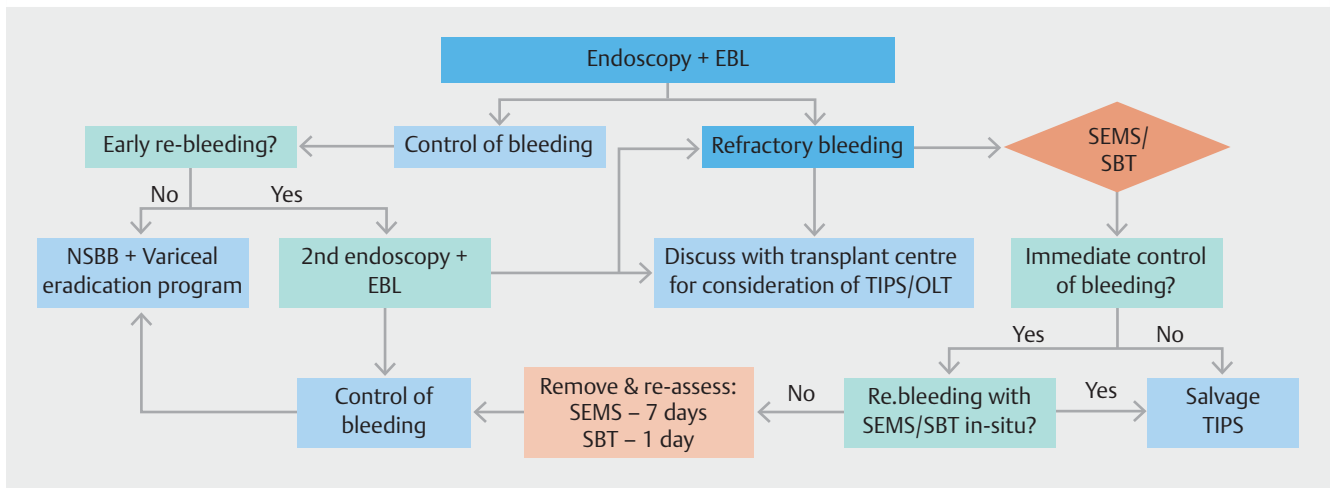
► VIDEO



► **Video 1** Video demonstrating the Endoscopic placement of SEMS for management of variceal bleeding

Discussion

Refractory VB or early re-bleeding in patients with CLD presents a challenging clinical problem with high mortality of 30% to 50% [6]. Definitive therapy of the underlying portal hypertension by TIPS has been shown to reduce rates of uncontrolled bleeding, re-bleeding and mortality; however, its use is limited by complications and availability [10, 11]. Thus, there is a role for endoscopic therapy that effectively temporizes this potentially catastrophic situation, reduces early re-bleeding and provides a bridge to secondary therapies or TIPS. Current guidelines recommend either BT or SEMS for the initial treatment of refrac-



► **Fig. 2** Proposed algorithm for endoscopic management of acute esophageal variceal bleeding. The algorithm incorporates the use of a self-expanding metal stent (SEMS) for refractory bleeding where possible as a bridge to definitive therapy with either transjugular intrahepatic porto-systemic shunt (TIPS) and/or orthotopic liver transplantation (OLT), if required.

tory VB [1]; however, the evidence supporting the use of SEMS in this setting is scarce. Our international, multicenter, observational study describes the real-world first-user experience in Australia and New Zealand. Our findings demonstrated high procedural technical success, excellent immediate control of VB, low rates of re-bleeding with SEMS in situ, and minimal serious AEs, suggesting that the novel SEMS is a feasible alternative to BT for refractory VB.

The procedural technical success rate in our cohort was 100% (32/32). Importantly, this data set includes a substantial number of cases early in the experience of many users as data was collected from the point of introduction of this new device at each center. This is in keeping with the extremely high technical success rates (90%-100%) described in the limited existing literature [16–18, 20, 21, 24–26]. Interestingly, only eight of 32 SEMS (25%) were placed by interventional endoscopists, suggesting that training in advanced endoscopic techniques is not necessarily required for successful deployment of the SEMS. Moreover, 46.9% of endoscopists felt that the SEMS insertion was easier than SBT despite the early-user learning curve, while another 25% felt that it was the same level of difficulty. On the basis of our multicenter experience, the use of this novel SEMS appears highly feasible at most centers capable of emergency endoscopy and by the majority of endoscopists.

Our primary endpoint of immediate control of VB was achieved in 96.9% of cases. This is extremely high and appears at least similarly successful compared to BT in the immediate control of refractory VB which is reported to be 88% to 91% [9]. Additionally, the overall rate of bleeding control for the duration of SEMS in-dwelling time was 87.5%, with a mean in-dwelling time of 6.4 days. While BT also provides excellent initial control of bleeding, current guidelines suggest removal within 24 hours, resulting in re-bleeding upon deflation of BT in up to 50% of cases [9, 21, 27]. Another advantage of the novel SEMS over conventional BT appears to be a low rate of serious adverse events which are reported to occur in 15% [21]. In

our cohort a single case of major bleeding following spontaneous SEMS migration was the only serious adverse event observed. Concerns over SEMS-associated ulceration and resultant bleeding were not validated in our study, where there were only two cases of ulceration with no clinically significant consequences. In contrast, BT has a well-documented high incidence of serious AEs, and is associated with fatal complications in 6% to 20% of cases [28, 29].

Other potential advantages of the SEMS over BT include the ability for earlier tracheal extubation and therefore possible shorter ICU length of stay, as well as earlier introduction of enteral nutrition. Due to the mechanism of BT, ongoing tracheal intubation is a necessity while the gastric balloon is inflated. Our median time to successful extubation was 1 day following SEMS insertion, resulting in the ability to commence enteral feeding in 83.3% of patients at a median of 2 days following SEMS insertion. Given the general inexperience with SEMS use for refractory VB and its yet unproven ability to immediately control bleeding, units were likely to manage patients more conservatively. We, therefore, feel that even earlier extubation and introduction of enteral feeding may be feasible in a subset of patients with immediate control of bleeding and good early clinical progress following SEMS insertion. In addition, as insertion of the SEMS does not require fluoroscopic guidance, it can be inserted in any hospital setting where endoscopy can be performed including ICU and emergency department. This was seen in our study in which no patients required fluoroscopy and only 18.7% of cases were inserted in the endoscopy suite. We believe this significantly expands the usability of the SEMS to all refractory cases of VB.

The SEMS was inserted electively upon removal of SBT in 25% of the cohort. This unique aspect the study allows us to report on the real-world use of the SEMS in the Oceania region, which has a very large geographical distribution in which not all medical centers may offer definitive advanced radiological procedures such as TIPS. In such scenarios, the SEMS allows safe de-

flation of the SBT and enough time to assess the patient's candidacy for TIPS/transplantation, which may involve transfer to a hospital with transplantation services.

While immediate control of VB using the SEMS was extremely effective, it is important to note that overall mortality in our cohort remained high, with a 6-week bleeding-related mortality of 33.3%. Moreover, in the subgroup of patients that did not qualify for TIPS or OLT the 6-week bleeding-related mortality was 62.5% (10/16 patients). In our cohort, 12 patients progressed to radiological therapy with TIPS placement; 11 of these occurring as a planned bridge to definitive therapy following SEMS insertion, while one required salvage therapy in the setting of SEMS treatment failure. Early or rescue TIPS in the setting of acute VB in patients with advanced CLD has been shown in a randomized control trial to reduce the rate of uncontrolled bleeding or re-bleeding (3% vs 45%), ICU length of stay (3.6 vs 8.6 days), and 1-year mortality (14% vs 39%, $P=0.001$) compared to standard medical and endoscopic therapy [10]. Our data support that where possible, SEMS in the setting of refractory VB can be used as a bridge to definitive therapy with either TIPS and/or OLT if required. We propose, therefore, the following treatment algorithm for the management of VB in CLD (► Fig. 2).

Our study has several inherent limitations in its uncontrolled retrospective design. There was variability in endoscopist experience and technique, as well as in procedural practices and clinical decision-making between the participating sites. Our cohort consisted of a heterogeneous group of patients with variation in underlying etiology of CLD as well as severity of pre-existing CLD and clinical course. However, these are limitations that exist across the medical literature, particularly in multicenter retrospective studies. Our study also has a relatively low number of patients; however, given that BT is an effective and familiar technique for the management of refractory VB, it is uncommon for most endoscopists to select a novel SEMS in these highly stressful situations. Despite the small numbers, our cohort is still one of the largest to date evaluating the novel SEMS for the management of refractory VB. Another strength of this study is its multicenter recruitment across nine centers from two countries. This adds considerable generalizability to our results and presents real-world translatable data. In addition, a proportion of our data were collected prospectively (13/32, 40.6%), therefore, potentially reducing sources of bias and confounding.

Conclusions

In conclusion, our data suggest that the SX-Danis Ella SEMS is highly effective for immediate control of refractory VB in patients with CLD. The novel SEMS presents an appealing alternative to the BT as it has an excellent technical success rate, appears to be relatively easy to use and is associated with low rates of serious AEs. While this novel SEMS provides an effective bridge to definitive therapies (TIPS and/or OLT), the overall mortality in our cohort is still high. Further randomized trials and local consensus guidelines are required to clarify best prac-

tice and cost-effectiveness in the endoscopic management of refractory VB.

Competing interests

The authors declare that they have no conflict of interest.

References

- [1] de Franchis R, Faculty BV. Expanding consensus in portal hypertension: Report of the Baveno VI Consensus Workshop: Stratifying risk and individualizing care for portal hypertension. *J Hepatol* 2015; 63: 743–752
- [2] García-Pagán JC, Reverter E, Abraldes JG et al. Acute variceal bleeding. *Semin Respir Crit Care Med* 2012; 33: 46–54
- [3] Jairath V, Rehal S, Logan R et al. Acute variceal haemorrhage in the United Kingdom: patient characteristics, management and outcomes in a nationwide audit. *Dig Liver Dis* 2014; 46: 419–426
- [4] Hogan BJ, O'Beirne JP. Role of self-expanding metal stents in the management of variceal haemorrhage: Hype or hope? *World J Gastrointest Endosc* 2016; 8: 23–29
- [5] Sarin SK, Kumar A, Angus PW et al. Diagnosis and management of acute variceal bleeding: Asian Pacific Association for Study of the Liver recommendations. *Hepatol Int* 2011; 5: 607–624
- [6] D'Amico M, Berzigotti A, Garcia-Pagan JC. Refractory acute variceal bleeding: what to do next? *Clin Liver Dis* 2010; 14: 297–305
- [7] Puente A, Hernández-Gea V, Graupera I et al. Drugs plus ligation to prevent rebleeding in cirrhosis: an updated systematic review. *Liver Int* 2014; 34: 823–833
- [8] D'Amico G, Crisculi V, Fili D et al. Meta-analysis of trials for variceal bleeding. *Hepatology* 2002; 36: 1023–1024; author reply 4–5
- [9] Panés J, Terés J, Bosch J et al. Efficacy of balloon tamponade in treatment of bleeding gastric and esophageal varices. Results in 151 consecutive episodes. *Dig Dis Sci* 1988; 33: 454–459
- [10] García-Pagán JC, Caca K, Bureau C et al. Early use of TIPS in patients with cirrhosis and variceal bleeding. *N Engl J Med* 2010; 362: 2370–2379
- [11] Monesillo A, Martínez-Lagares F, Ruiz-del-Arbol L et al. Influence of portal hypertension and its early decompression by TIPS placement on the outcome of variceal bleeding. *Hepatology* 2004; 40: 793–801
- [12] García-Pagán JC, Di Pascoli M, Caca K et al. Use of early-TIPS for high-risk variceal bleeding: results of a post-RCT surveillance study. *J Hepatol* 2013; 58: 45–50
- [13] Riggio O, Ridola L, Lucidi C et al. Emerging issues in the use of transjugular intrahepatic portosystemic shunt (TIPS) for management of portal hypertension: time to update the guidelines? *Dig Liver Dis* 2010; 42: 462–467
- [14] Escorsell A, Bosch J. Self-expandable metal stents in the treatment of acute esophageal variceal bleeding. *Gastroenterol Res Pract* 2011; 2011: 910986
- [15] Holster IL, Kuipers EJ, van Buuren HR et al. Self-expandable metal stents as definitive treatment for esophageal variceal bleeding. *Endoscopy* 2013; 45: 485–488
- [16] Hubmann R, Bodlaj G, Czompo M et al. The use of self-expanding metal stents to treat acute esophageal variceal bleeding. *Endoscopy* 2006; 38: 896–901
- [17] Zehetner J, Shamiyeh A, Wayand W et al. Results of a new method to stop acute bleeding from esophageal varices: implantation of a self-expanding stent. *Surg Endosc* 2008; 22: 2149

- [18] Wright G, Lewis H, Hogan B et al. A self-expanding metal stent for complicated variceal hemorrhage: experience at a single center. *Gastrointest Endosc* 2010; 71: 71–78
- [19] Dechêne A, El Fouly A, Bechmann L et al. Acute management of refractory variceal bleeding in liver cirrhosis by self-expanding metal stents. *Digestion* 2012; 85: 185–191
- [20] Pfisterer N, Riedl F, Pachofszky T et al. Outcomes after placement of a SX-ELLA oesophageal stent for refractory variceal bleeding-A national multicentre study. *Liver Int* 2019; 39: 290–298
- [21] Escorsell À, Pavel O, Cárdenas A et al. Esophageal balloon tamponade versus esophageal stent in controlling acute refractory variceal bleeding: A multicenter randomized, controlled trial. *Hepatology* 2016; 63: 1957–1967
- [22] Shao XD, Qi XS, Guo XZ. Esophageal stent for refractory variceal bleeding: a systemic review and meta-analysis. *Biomed Res Int* 2016; 2016: 4054513
- [23] de Franchis R, Faculty BV. Revising consensus in portal hypertension: report of the Baveno V consensus workshop on methodology of diagnosis and therapy in portal hypertension. *J Hepatol* 2010; 53: 762–768
- [24] Jain M, Balkrishnan M, Snk C et al. SX-Ella Danis stent in massive upper gastrointestinal bleeding in cirrhosis – a case series. *Clin Exp Hepatol* 2018; 4: 97–99
- [25] Fierz FC, Kistler W, Stenz V et al. Treatment of esophageal variceal hemorrhage with self-expanding metal stents as a rescue maneuver in a swiss multicentric cohort. *Case Rep Gastroenterol* 2013; 7: 97–105
- [26] Zakaria MS, Hamza IM, Mohey MA et al. The first Egyptian experience using new self-expandable metal stents in acute esophageal variceal bleeding: pilot study. *Saudi J Gastroenterol* 2013; 19: 177
- [27] Avgerinos A, Klonis C, Rekoumis G et al. A prospective randomized trial comparing somatostatin, balloon tamponade and the combination of both methods in the management of acute variceal haemorrhage. *J Hepatol* 1991; 13: 78–83
- [28] Haddock G, Garden OJ, McKee RF et al. Esophageal tamponade in the management of acute variceal hemorrhage. *Dig Dis Sci* 1989; 34: 913–918
- [29] Chojkier M, Conn HO. Esophageal tamponade in the treatment of bleeding varices. A decadel progress report. *Dig Dis Sci* 1980; 25: 267–272