



Contents lists available at [ScienceDirect](#)

JPRAS Open

journal homepage: [www.elsevier.com/locate/jpra](http://www.elsevier.com/locate/jpra)



## Original Article

# Is the adipofascial flap the key to regenerative surgery?

Gabriele Delia\*, Fabiana Battaglia, Michele Rosario Colonna, Valeria Barresi, Francesco Stagno d'Alcontres

Plastic Surgery Unit, Department of Human Pathology, University of Messina, Via Consolare Valeria 1, Azienda Ospedaliera Universitaria Policlinico "G. Martino" 98125, Messina, Italy

## ARTICLE INFO

### Article history:

Received 24 February 2018

Revised 13 July 2018

Accepted 18 July 2018

Available online 31 July 2018

## ABSTRACT

**Objectives:** “Form and function restoration” is the ultimate goal of reconstructive surgery, which is oriented toward regeneration rather than reparation. Recently, research in reconstructive surgery has focused on the regenerative potential of the adipose tissue. The aim of the study is to illustrate the surgical methods and show the functional and aesthetic results achieved by the reconstruction of finger soft-tissue defects using homodigital dorsal adipofascial reverse flap (HDARF).

**Materials and methods:** A total of 63 cases (45 acute and 18 elective) were included between September 2010 and August 2016. In each case, we preliminarily performed surgical debridement and then harvested an adipofascial flap from the back of the finger. Nine injured thumbs that were repaired with the flap as emergency cases were also included. The average age of the patients was 46 (range: 4–69) years.

**Results:** All flaps survived without any complications during the 24-month follow-up. Good nail regrowth through the flap and full regeneration were observed in approximately all cases. Sensitivity tests and histological analysis of biopsy samples of the regenerated fingers confirmed full regeneration of the epidermis, dermis, cutaneous adnexa, and nerves. All the patients were satisfied with the hand functionality and aesthetic appearance.

\* Corresponding author.

E-mail address: [gabrieledelia@gmail.com](mailto:gabrieledelia@gmail.com) (G. Delia).

**Conclusion:** The HDARF represents a very useful alternative for the reconstruction of nailbed crushes, achieving regeneration of injured segments in deformities caused by trauma or infection.

© 2018 The Authors. Published by Elsevier Ltd on behalf of British Association of Plastic, Reconstructive and Aesthetic Surgeons. This is an open access article under the CC BY-NC-ND license. (<http://creativecommons.org/licenses/by-nc-nd/4.0/>)

## Introduction

Injury of the digital distal phalanx often causes loss of function (grip and sensory loss) and aesthetic damage, which can be addressed by reconstructive surgery.

Several methods have been proposed for nailbed reconstruction. The choice of method depends on the surgeon's skill level as well as the patient's compliance.<sup>1,2</sup>

We reviewed the previous experiences of complex nailbed reconstruction using regional flaps such as the reverse adipofascial flap as described by Lai et al. (1991)<sup>3</sup> and then by Ozdemir et al. (2001).<sup>4</sup>

Because of their composition, which consists of highly vascularized adipose tissue, adipofascial flaps are commonly used in reconstructive surgery.

In this study, we report our experience using our novel homodigital dorsal adipofascial reverse flap (HDARF) for the reconstruction of soft-tissue defects of the finger. In addition, we analyzed the sensory, functional, and aesthetic outcomes of reconstruction.

## Materials and methods

A total of 63 patients were included in the study, and the following demographic and clinical data were recorded for each patient: age, sex, traumatized hand, injured finger, wound type, time interval from trauma to surgery, healing time, and complete nail regrowth time (46 males, 17 females; age range: 4–69; mean age: 43).

The wound types included crush injuries (46 patients), road accident injuries (six patients), high-energy injury (one patient), sequelae of infections (four patients), dog bite injuries (one patient), avulsion injuries (three patients), and knife blade cut injuries (two patients).

The mean time interval between injury and operation ranged from 0 to 92 days.

Only patients with acute apical injury involving the fingertip and/or nail bed that spared the eponychium with limited germinal matrix lesion and nailbed loss of substance were considered. These factors are critical to ensure HDARF vascular pedicle viability (Fig. 1).

The right hand was affected in 51 patients, whereas the left was affected in 12 patients. In all patients, injury involved the long fingers, with the index finger injured in 16 cases, the third finger in 16 cases, the fourth finger in 17 cases, the fifth finger in five cases, and one double injury involving the third and the fourth fingers.

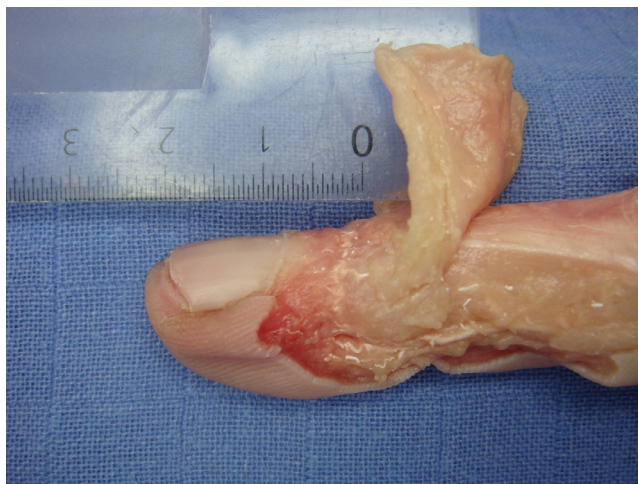We also considered nine patients with crush-avulsion of the distal thumb phalanx.

Forty-five cases were treated with immediate reconstruction (emergency), i.e., in the first seven days after the trauma, whereas the other 18 cases (elective) were operated after the first week (Table 1).

Surgery was carried out in two steps: (1) wound bed preparation through surgical debridement, and (2) projection and raising of the adipofascial flaps, as previously described.<sup>5</sup>

A cutaneous dorsal digital flap was raised under 2.5 or 3.5 loupe magnification to expose the adipofascial tissue. The flap was raised up from the ulnar side of the second, third, and fourth fingers and from the radial side of the fifth finger. Careful knife dissection created a good surgical plane between the deep dermis and adipose tissue, and the skin flap was supplied by the dermal vascular plexus.<sup>6</sup>

Transverse dorsal incision was made following a digital crease at the base of the second phalanx, and a third cutaneous access incision proximal to the eponychium was carried out. An adipofascial flap



**Fig. 1.** Cadaveric studies demonstrate that the flap elevation is limited at 10 mm proximal to the eponychial fold to avoid vascularization of the distal perforators.

was elevated from the back of the proximal interphalangeal (PIP) joint of each finger and extended to the base of the distal phalanx (Fig. 2).

Flap elevation was limited to 10 mm proximal to the eponychial fold.

The adipofascial flaps were turned on themselves at a 180° angle, whereas the skin flaps were turned back to their original position, and the sutures were hidden in nonvisible zones.

Moist dressings were carried out and renewed after 2–3 days during the first week.

Two years after reconstruction, a biopsy sample was taken from a patient's repaired site. The biopsy sample was formalin-fixed for 24 hours at room temperature, paraffin-embedded, and cut into 4- $\mu$ m tissue sections for histological examination with hematoxylin and eosin stain and immunohistochemistry against S100 (prediluted, clone 4c4.9, Ventana, Roche Diagnostics GmbH, Germany).

## Results

In all cases, complete flap survival and healing occurred. We observed that venous congestion and superficial flap necrosis were easily resolved by debridement and advancement of the local flap, with 9 days added to the average healing time in a young manual worker and a heavy smoker. In the first 3 weeks after surgery, we registered a slight bulging at the pivot point. In 58 cases, this bulging recovered spontaneously before the fourth postoperative month. In five cases, it decreased but did not disappear; however, none of the affected patients required revision surgery.

The healing time ranged between 14 and 22 days, but complete regrowth of the nail lamina took 60–100 (average 75) days. The lamina grew and perforated the flap in almost 1 month. The average time of return to work was 60 days.

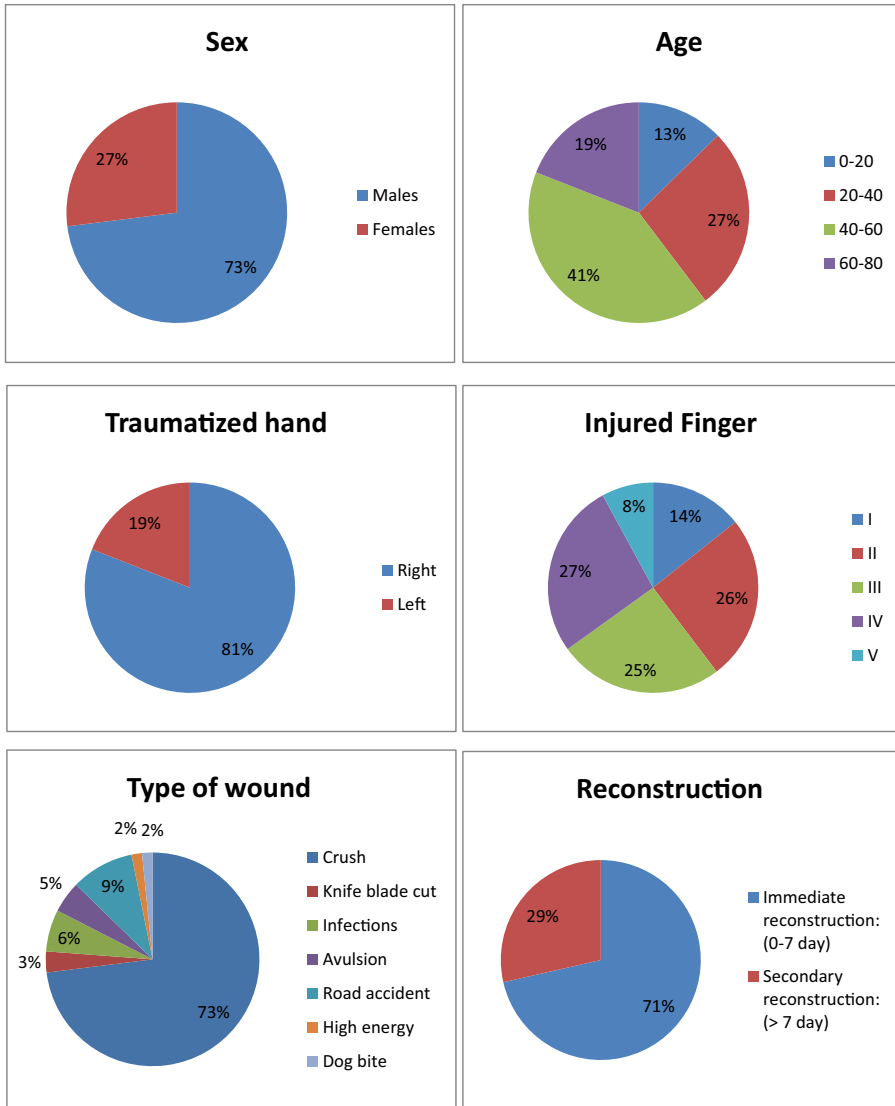
In 18 cases, the nail lamina did not pierce the flap, and surgical opening of the flap was easily done on an outpatient basis.

Long-term results showed regeneration of the rebuilt region, possibly due to the presence of the adipose tissue and stem cells.<sup>7</sup>

Histological examination of the biopsies that were carried out in the repaired sites after 2 years confirmed no difference between the histology of a normal fingertip and that of fingertip reconstructed with the HDARF flap (Fig. 3).

Functional tests on 30 patients showed good sensory and grip recovery (Table 2).

**Table 1**  
Characteristics of the study patients.

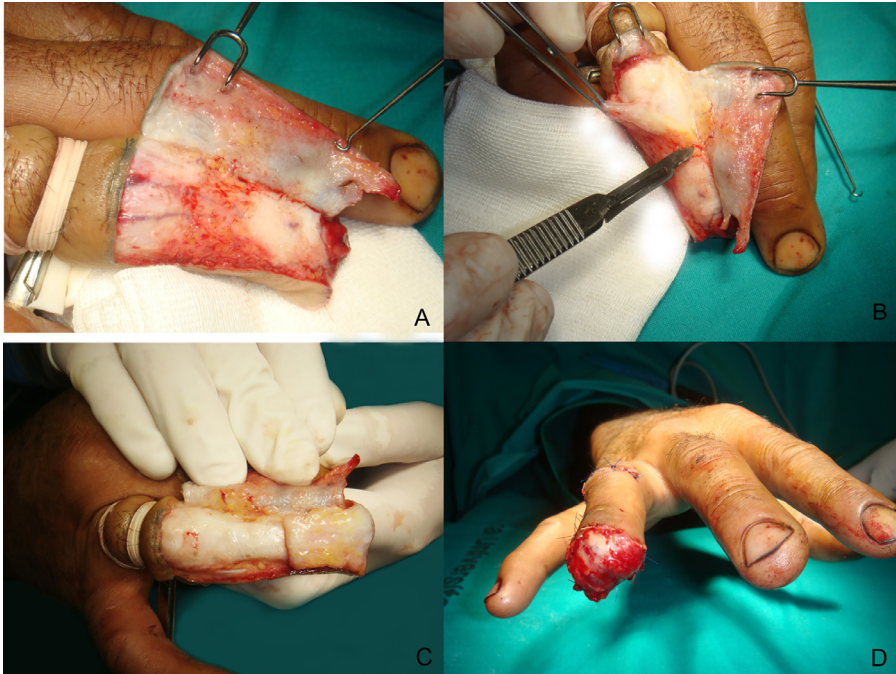


The Semmes-Weinstein monofilament (SWF) test showed excellent results: 21 patients had shallow normal touch, six had reduced superficial tactile sensitivity, and the other three had reduced protective perception.

According to the two-point discrimination (2PD) test performed at postoperative year 1, 18 patients could discriminate two points spaced less than 6 mm apart, whereas 12 patients discriminated two points spaced between 6 and 10 mm apart.

Notably, all of our patients returned to their previous occupational activities within an average time frame of 4 weeks. The regenerative process continued for several more months.

All patients revealed a high satisfaction rate.



**Fig. 2.** A complete sequence is presented: transverse dorsal incision was carried out (A); the adipofascial flap was elevated from the back of the PIP Joint (B) and extended to the base of the distal phalanx. The HDARF is turned on itself in a 180° angle to cover the defect (C); the skin flap was turned into its original position and the suture was hidden in the nonvisible zone (D).

A complete sequence of the preoperative, intraoperative, and immediate postoperative views up to complete healing is shown in Figs. 4, 5, and 6, respectively.

## Discussion and conclusion

Over the years, hand surgeons have improved the process of fingertip reconstruction in the context of complex apical trauma. At present, changes in social and cultural behavior have modified the goals of apical digital reconstruction as well as the classification and indications for treatment.<sup>2-8</sup>

We believe that a good and healthy nailbed should be a priority in fingertip reconstruction, as it leads to the growth of a nearly normal nail lamina and the avoidance of dystrophic results.

Good nailbed repair can be achieved by sparing even the smallest germinal matrix in acute repair<sup>9</sup> and by maintaining nailbed blood supply through the application of well-vascularized soft tissue in an emergency or even in a second procedure.<sup>5-6</sup>

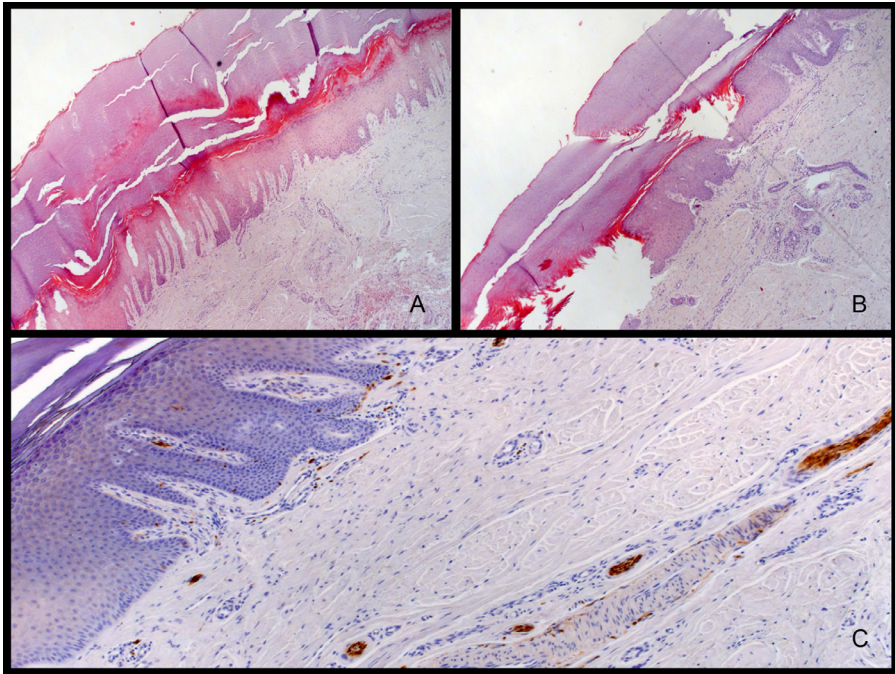
The standard methods of nailbed repair include the use of grafts, which is associated with satisfactory results<sup>10-11</sup>, though success is largely dependent on the vascular supply of the recipient bed. For this reason, their use in scarred beds has been controversial.<sup>12</sup> On the other hand, microsurgical procedures may provide outstanding results, but only in the context of considerable surgical expertise.<sup>13</sup>

The eponychial flap, in combination with flap advancement for fingertip reconstruction, can be considered an effective tool in apical crush lesions when nail length preservation is necessary.<sup>10</sup>

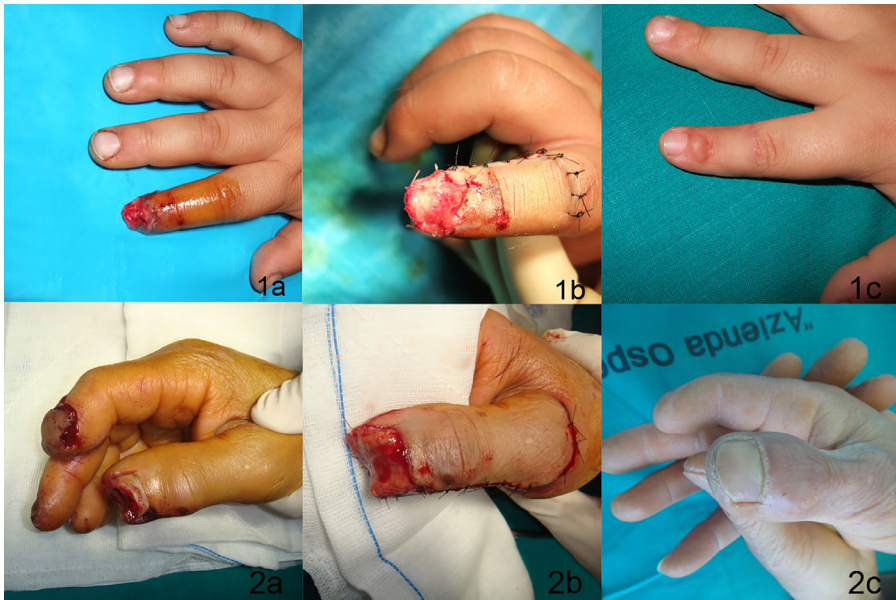Regional flaps include the classical cross-finger flap, which requires a two-stage surgical approach and carries a high risk of joint stiffness, especially in older patients, and the dorsal reverse-pedicled skin flap, which was clearly described by Weeks<sup>14</sup> and subsequently by other authors.<sup>2,15-18</sup>

Recently, surgeons have focused their attention on adipofascial flaps. After Lay's first description in 1991<sup>3</sup>, other methods of obtaining a versatile adipofascial flap have since been proposed.<sup>4,12,19,20</sup>





**Fig. 3.** Histological aspect of normal finger (A) overlapped that of a regenerated finger (B) (hematoxylin and eosin staining; original magnification, 40X). Reconstructed fingertip showed cutaneous adnexa and nerves, as highlighted by S100 immunohistochemistry, demonstrating a complete regenerative process (C) (S100 staining, original magnification, 100X).



**Fig. 4.** A complete sequence of the preop (1a-2a), intraop (1b-2b), and immediate postop (1c-2c) views up to complete healing after 1 year is shown.

**Table 2**  
Sensitivity tests.

N°	SWF		2PD	
	HEALTHY	REGENERATED	HEALTHY	REGENERATED
1	3.22–3.61	3.22–3.61	1–5 mm	1–5 mm
2	3.22–3.61	3.22–3.61	1–5 mm	1–5 mm
3	1.65–2.85	1.65–2.85	1–5 mm	1–5 mm
4	3.22–3.61	3.22–3.61	6–10mm	6–10 mm
5	1.65–2.85	1.65–2.85	1–5 mm	1–5 mm
6	1.65–2.85	1.65–2.85	1–5 mm	6–10 mm
7	3.22–3.61	3.84–4.31	1–5 mm	1–5 mm
8	1.65–2.85	1.65–2.85	1–5 mm	6–10 mm
9	3.22–3.61	3.84–4.31	1–5 mm	1–5 mm
10	1.65–2.85	1.65–2.85	6–10 mm	6–10 mm
11	3.22–3.61	3.22–3.61	1–5 mm	1–5 mm
12	1.65–2.85	1.65–2.85	1–5 mm	1–5 mm
13	1.65–2.85	1.65–2.85	1–5 mm	6–10 mm
14	1.65–2.85	1.65–2.85	1–5 mm	6–10 mm
15	1.65–2.85	1.65–2.85	1–5 mm	1–5 mm
16	1.65–2.85	1.65–2.85	1–5 mm	6–10 mm
17	3.22–3.61	3.22–3.61	1–5 mm	1–5 mm
18	1.65–2.85	1.65–2.85	1–5 mm	1–5 mm
19	1.65–2.85	1.65–2.85	1–5 mm	6–10 mm
20	3.22–3.61	3.84–4.31	1–5 mm	1–5 mm
21	1.65–2.85	1.65–2.85	1–5 mm	1–5 mm
22	1.65–2.85	1.65–2.85	1–5mm	1–5 mm
23	1.65–2.85	1.65–2.85	1–5 mm	6–10 mm
24	1.65–2.85	1.65–2.85	1–5 mm	6–10 mm
25	1.65–2.85	1.65–2.85	1–5 mm	1–5 mm
26	1.65–2.85	1.65–2.85	1–5 mm	1–5 mm
27	1.65–2.85	1.65–2.85	6–10 mm	6–10 mm
28	1.65–2.85	1.65–2.85	1–5 mm	1–5 mm
29	3.22–3.61	3.22–3.61	1–5 mm	1–5 mm
30	1.65–2.85	1.65–2.85	1–5 mm	6–10 mm

**SWF**

Shallow normal touch (1.65–2.83): 21 cases.

Reduction of the superficial tactile sensitivity (3.22–3.61): 6 cases.

Reduction of the protective perception (3.84–4.31): 3 cases.

Loss of the protective perception (4.56–6.65): 0 cases.

Loss of the sensitivity: 0 cases.

**2PD**

Discrimination between 1–5 mm: 18 cases.

Discrimination between 6–10 mm: 12 cases.

Discrimination between 11–15 mm: 0 cases.

Adipofascial flaps represent “vascularized adipose tissue” that can plastically conform to the rebuilt site and differentiate into various cellular types specific to the receiving site.<sup>21</sup>

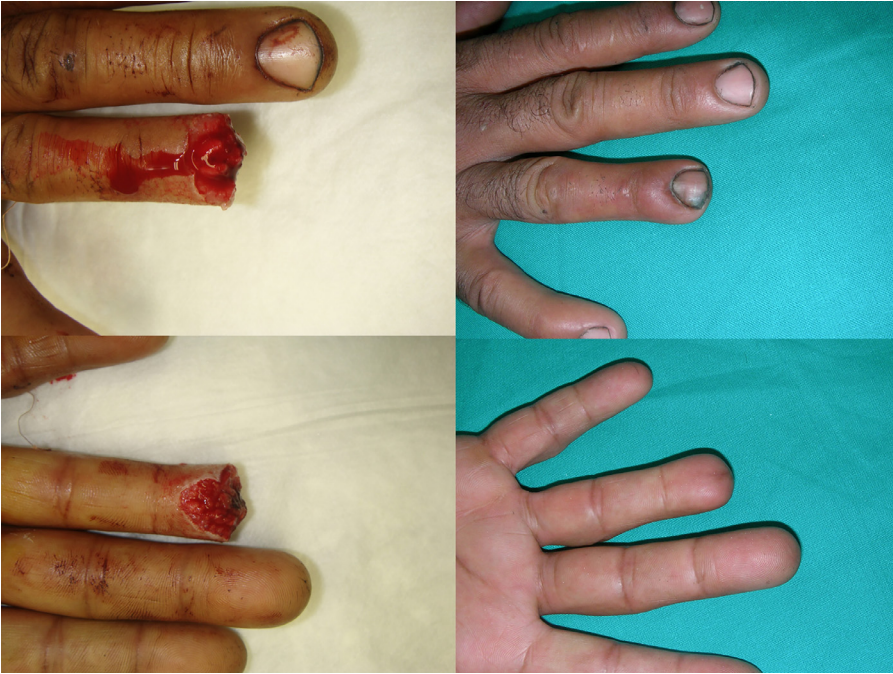Consistent with the results of several studies published in the last few years<sup>22</sup>, the present study confirms the significant regenerative power of vascularized adipose tissue.

In terms of this flap and its application in the long fingers, some core principles of safe dissection have been highlighted previously.<sup>5</sup>

In particular, we recommended that the skin flap be raised on the ulnar side of the digits in order to avoid visible and tender scars and that the distal part of the flap not be undermined, thereby preserving an at least 10-mm cuff of tissue proximal to the eponychial fold.

Later, we began to use the HDARF to revascularize the damaged nailbed in acute apical lesions. After developing the optimal technique for this flap, we extended its indication to post-traumatic deformities.<sup>6</sup>

In the initial years of using this flap, we identified the following disadvantages. First, it can easily become dry, which can lead to necrosis if sufficient rehydration does not occur. Therefore, it is impor-



**Fig. 5.** Results at 1 year of the patient's surgery in Fig. 2.

tant to use moist and frequent medication during the first few days. Second, it is difficult to sculpt the skin flap like a “book page” above the flap, and this surgical procedure has to be performed under loupes magnification. If the skin flap is not perfectly obtained, the following two problems can arise:

- 1) If the skin flap is too thick, the skin and the adipofascial flap are harvested together, leading to an overly thin HDARF flap and very poor tissue for reconstruction.
- 2) If the skin flap is too thin, skin necrosis can occur in the donor site.

Although “healing time” is very long using HDARF as compared with other techniques, and coverage with an advancement pulp flap is easier and quicker than with our flap, that approach is associated with complications such as onychogryphosis and dysesthesia in the pulpar region.

HDARF flap sensitivity restoration is not immediate but appears after a few months. However, we have not observed any cases of significant dysesthesia or cold intolerance. This is probably due to the use of annular medication applicator and our protocol of desensitization and modeling, which involves the rubbing of the reconstructed finger in the palmar region of contralateral hand when the nail lamina begins to perforate the flap.

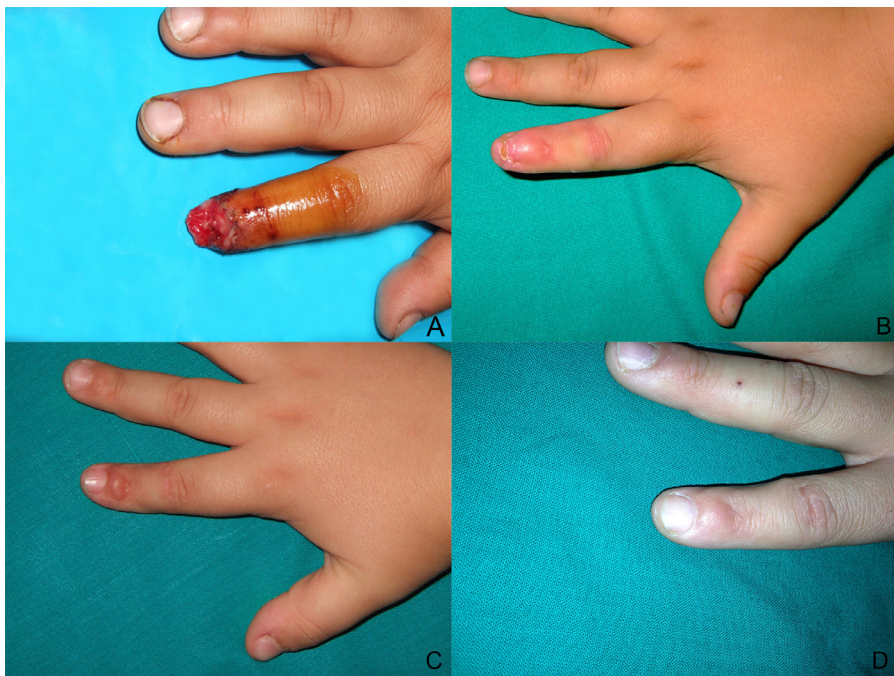The cross-finger flaps are usually used to reconstruct the back of the fingers. Although they confer good aesthetic results, they have the disadvantages of using a healthy finger as a donor site and articular stiffness due to the temporary immobilization of the fingers. Homodigital island flaps provide the advantage of decreased healing time, but the aesthetic results and the sensibility restoration are often less than ideal.

Therefore, despite the increased healing time and delayed return to work, the final outcomes of HDARF seem functionally and aesthetically superior in our experience.

In this study, we presented a series of 63 cases treated using HDARF; of them, 45 were emergency cases, while 18 were elective cases. Moreover, we included nine cases of thumb apical repair.

Interestingly, this flap can be successfully used to cover defects of both the back of the finger and the fingertip if they are present.





**Fig. 6.** A 4-year-old child has his right index finger crushed by an electrical gate, with extensive destruction of the nail-bed (A). A complete sequence is presented: in the first 3 months after surgery, we can see the regenerative phase where the nail lamina is going to perforate the epithelialized flap (B) 1 year postop, regenerative process is completed, and we can see a slight bulging on pivot point of the flap (C). Seven years postop, the bulging decreased spontaneously (D).

As previously outlined in our papers, the flap guided the growth of the nail lamina and provided a new nail bed. The technique appears to be safe and reproducible.

In our surgical technique, skin grafting above the adipofascial flap is prohibited because it can obstruct the regenerative process.

With regard to the aesthetic results, deformity is a rare event, mainly observed in germinal matrix injuries. The bulking of the pivot point of the flap is a common occurrence, but only some patients are disappointed by this aspect of the reconstruction.

In our paper related to anatomy, we showed that a rich vascularization comes from distal perforators, which provide a crown-like anastomosis.<sup>5</sup>

We treated complete and complex defects of the back of the finger and/or fingertip; for this reason, we always used elevated pedicled flaps on both perforators. We could narrow the base of the flap with one pedicle to treat partial (lateral or ulnar) apical defects, while always respecting the 10-mm “safe distance” in distal flap dissection.

Our study demonstrates that the HDARF flap provides an ideal scaffold to promote and support the regenerative process of apical digital defects.

Our flap consists of a vascular network, which is rich in the adipose tissue, and clinical and histological evidence supports the quality of its regenerative power. The presence of newly formed nerves in the biopsies of rebuilt fingertips shows the plasticity of the adipose tissue as well as its capacity to differentiate into a variety of different cell types. On the basis of the final outcomes of soft skin and good recovery of sensibility, we suggest the use of adipofascial flaps for apical digital repair.

In conclusion, although adipofascial flaps are surgically challenging and require delicate postoperative management, they represent an effective reconstructive tool in the plastic surgeon’s arsenal.

## Conflict of Interest

None.

## Funding

None.

## Supplementary materials

Supplementary material associated with this article can be found, in the online version, at doi: [10.1016/j.jpra.2018.07.004](https://doi.org/10.1016/j.jpra.2018.07.004).

## References

- Adani R, Marcoccio I, Tarallo L. Nail lengthening and fingertip amputations. *Plast Reconstruct Surg*. 2003;112:1287–1294 Oct.
- Momeni A, Zajonc H, Kalash Z, et al. Reconstruction of distal phalangeal injuries with the reverse homodigital island flap. *Injury*. 2008;39:1460–1463.
- Lai CS, Lin SD, Yang CC, et al. The adipofascial turn-over flap for complicated dorsal skin defects of the hand and the fingers. *Br J Plast Surg*. 1991;44:165–169.
- Ozdemir R, Kiliñç H, Sensöz O, et al. Innervated dorsal adipofascial turnover flap for fingertip amputations. *Ann Plast Surg*. 2001;46:9–14.
- Delia G, Casoli V, Sommario M, et al. Homodigital dorsal adipofascial reverse flap: anatomical study of distal perforators and key points for safe dissection. *J Hand Surg Eur*. 2010;35:454–458.
- Delia G, Casoli V, Sommario M, et al. Homodigital dorsal adipofascial reverse flap: clinical applications. *PlastReconstrSurg*. 2011;127:162–163.
- Rigotti G, Marchi A, Galie M, et al. Clinical treatment of radiotherapy tissue damage by lipoaspirate transplant: a healing process mediated by adipose-derived adult stem cells. *PlastReconstrSurg*. 2007;119:1409–1422 Apr 15 discussion 1423–4.
- Evans DM, Bernardis CA. A new classification for fingertip injuries. *J Hand Surg*. 2000;25:58–60.
- Netscher DT. Is nail germinal matrix ablation always necessary in a dorsal reverse adipofascial flap procedure for fingertip reconstruction? *PlastReconstr Surg*. 2004;114:1678.
- Bakhach J, Demiri E, Guimberteau JC. Use of the eponychial flap to restore the length of a short nail: a review of 30 cases. *PlastReconstr Surg*. 2005;16:478–483.
- Shepard GH. Perionychial grafts in trauma and reconstruction. *Hand Clin*. 2002;18:595–614.
- Laoulakos DH, Tsetsonis CH, Michail AA, et al. The dorsal reverse adipofascial flap for fingertip reconstruction. *PlastReconstr Surg*. 2003;112:121–125.
- Hirasè Y, Kojima T, Matsui M. Aesthetic fingertip reconstruction with a free vascularized nail graft: a review of 60 flaps involving partial toe transfers. *PlastReconstr Surg*. 1997;99:774–784.
- Weeks PM, Wray RC. *Management of Acute Hand Injuries: A Biological Approach*. St. Louis: Mosby; 1973:140.
- Alagoz MS, Uysal CA, Kerem M, et al. Reverse homodigital artery flap coverage bone and nailbed grafts in finger amputations. *Ann Plast Surg*. 2006;56:279–283.
- Kojima T, Tsuchida Y, Hirasè Y, et al. Reverse vascular pedicle digital island flap. *Br J PlastSurg*. 1990;43:290–295.
- Lai CS, Lin SD, Yang CC. The reverse digital artery flap for fingertip reconstruction. *Ann PlastSurg*. 1989;22:495–500.
- Lai CS, Lin SD, Chou CK, et al. A versatile method for reconstruction of finger defects: Reverse digital artery flap. *Br J Plast Surg*. 1992;45:443–453.
- Braga-Silva J, Kuyven CR, Albertoni W, et al. The adipofascial turn-over flap for coverage of the dorsum of the finger: a modified surgical technique. *J Hand Surg*. 2004;29:1039–1043.
- Rampazzo A, Gharb BB, Basetto F. Exteriorized pedicle technique in dorsal reverse adipofascial flap for nail complex reconstruction. *PlastReconstr Surg*. 2007;119:1388–1390.
- Coleman SR. Structural fat grafting: more than a permanent filler. *PlastReconstr Surg*. 2006 Sep;118(3 Suppl):108S–120S.
- Pu LL, Yoshimura K, Coleman SR. Fat grafting: current concept, clinical application, and regenerative potential, part 2. *Clin-Plast Surg*. 2015;42:xiii–xxiv Jul. doi:10.1016/j.cps.2015.05.001.