

CASE REPORT

Successful Management of a Type B Gutter Related Endoleak after Chimney EVAR by Coil Assisted Onyx Embolisation

Marta Ballesteros-Pomar ^{a,*}, Gergana T. Taneva ^b, Martin Austermann ^b, Rafael Fernández-Samos ^a, Giovanni Torsello ^b, Konstantinos P. Donas ^b

^a Department of Vascular and Endovascular Surgery, University Hospital of Leon, Leon, Spain

^b Department of Vascular Surgery, St. Franziskus Hospital Münster, Clinic of Vascular and Endovascular Surgery, University of Münster, Germany

Introduction: The aim was to describe possible management of a persistent gutter related type Ia endoleak after treatment of a symptomatic pararenal aortic aneurysm with the chimney endovascular technique.

Report: A 77 year old man with a symptomatic 6 cm pararenal aortic aneurysm was referred. Computed tomography angiography (CTA) showed a pararenal aortic aneurysm with involvement of both renal arteries and extension up to the superior mesenteric artery. The patient underwent treatment by placement of triple chimney grafts and an abdominal stent graft. Completion angiography showed a gutter related type Ia endoleak. As the type Ia endoleak persisted at the three month CTA follow up and according to the PERICLES registry classification of endoleaks, a type B causative mechanism was detected. Embolization of the gutters was performed with coils and onyx, leading to complete resolution of the gutters on completion angiography. The 10 month post-operative magnetic resonance angiogram showed no further evidence of any endoleak and complete exclusion of the aneurysm.

Conclusion: Treatment of persistent type B gutter related endoleaks after triple chimney endovascular aneurysm repair can be performed with the placement of coils and adjunctive use of fluid agents.

© 2019 The Author(s). Published by Elsevier Ltd on behalf of European Society for Vascular Surgery. This is an open access article under the CC BY-NC-ND license (<http://creativecommons.org/licenses/by-nc-nd/4.0/>).

Article history: Received 6 October 2018, Revised 19 December 2018, Accepted 20 December 2018,

Keywords: Chimney stent graft, Computed tomographic angiography, Endoleak, Endovascular aneurysm repair, Pararenal aneurysm

INTRODUCTION

The use of chimney grafts for the treatment of pararenal aortic aneurysms is gaining popularity and ever greater acceptance as a feasible and effective endovascular alternative.¹ However, the “Achilles heel” of this technique remains the possible development and persistence of “gutters” leading to type Ia endoleaks. In this report a case of type Ia endoleak after triple chimney endovascular aneurysm repair (Ch-EVAR; chimney stents for both renal arteries and superior mesenteric artery) which resolved successfully with coil assisted onyx embolization is described. To the authors’ knowledge, this is the first case of triple chimney EVAR with a gutter related endoleak treated with by this strategy.

* Corresponding author. Department of Vascular Surgery, St. Franziskus Hospital Münster, Clinic of Vascular and Endovascular Surgery, University of Münster, Wiener Str. 8 48145, Münster, Germany.

E-mail address: m.ballesterospomar@hotmail.com (Marta Ballesteros-Pomar).

2405-6553/© 2019 The Author(s). Published by Elsevier Ltd on behalf of European Society for Vascular Surgery. This is an open access article under the CC BY-NC-ND license (<http://creativecommons.org/licenses/by-nc-nd/4.0/>).

<https://doi.org/10.1016/j.ejvssr.2018.12.002>

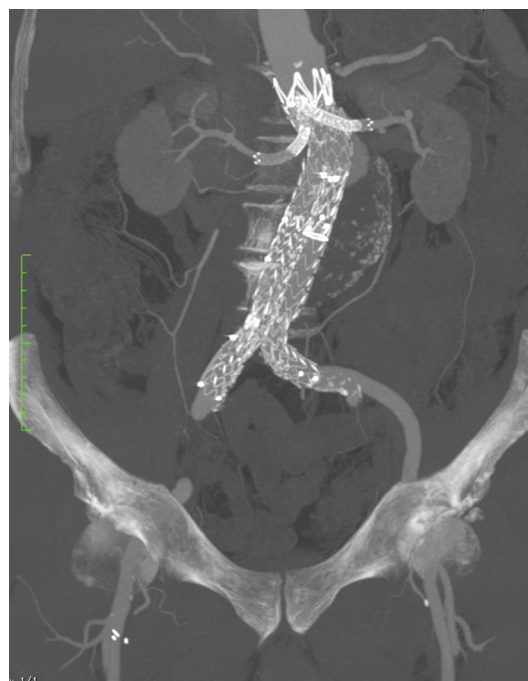

Figure 1. Computed tomography angiogram three months after chimney endovascular aneurysm repair demonstrating a persistent type Ia endoleak.

CASE REPORT

A 77 year old man with a symptomatic 6 cm diameter pararenal aortic aneurysm (PAA) was referred. The patient had severe comorbidities, including chronic obstructive pulmonary disease, hypertension, previous myocardial infarction, and a hostile abdomen after perforated duodenal ulcer. A detailed cardiopulmonary assessment could not be done given the high risk of aneurysm rupture. Computed tomography angiography (CTA) showed a PAA with involvement of both renal arteries and extension up to the superior mesenteric artery (SMA). The aortic diameter in the visceral segment was 28 mm. Owing to the symptoms

and the risk of aneurysm rupture, use of fenestrated endografting was excluded.

The patient underwent triple chimney EVAR repair in order to create a sufficient new sealing length of 20 mm. Briefly, a cutdown of the left axillary artery was performed for advancement of two 7 Fr Shuttle (Cook, Bloomington, IN, USA) sheaths into the renal arteries with, additionally, a cutdown of the right axillary artery to advance a 7 Fr sheath in the SMA. A bilateral percutaneous transfemoral approach was used and a 36mm diameter Endurant II bifurcated endograft (Medtronic, Santa Rosa, CA, USA) was advanced and deployed at the orifice of the coeliac trunk. Two balloon

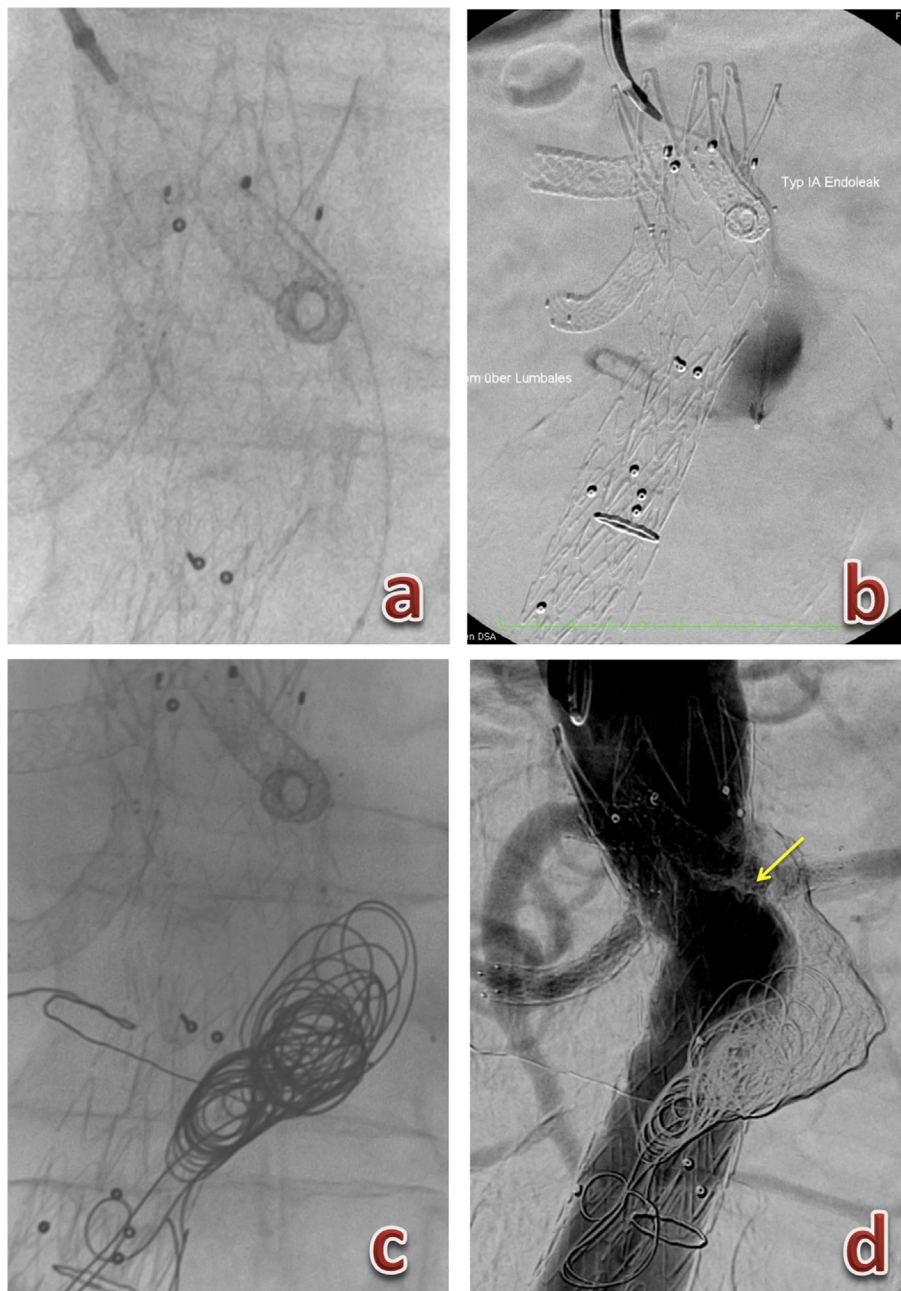


Figure 2. Sequence of technical steps during the embolization procedure. (A) Advance of the 0.014'' wire in the gutter. (B) Confirmation of the combined type Ia endoleak and type II endoleak via lumbar arteries. (C) Use of coils (Axium) to fill the gap and occlude the type II endoleak. (D) Additional use of Onyx Liquid Embolic System (arrow) for the small gutters and completion angiography showing no evidence of endoleak.

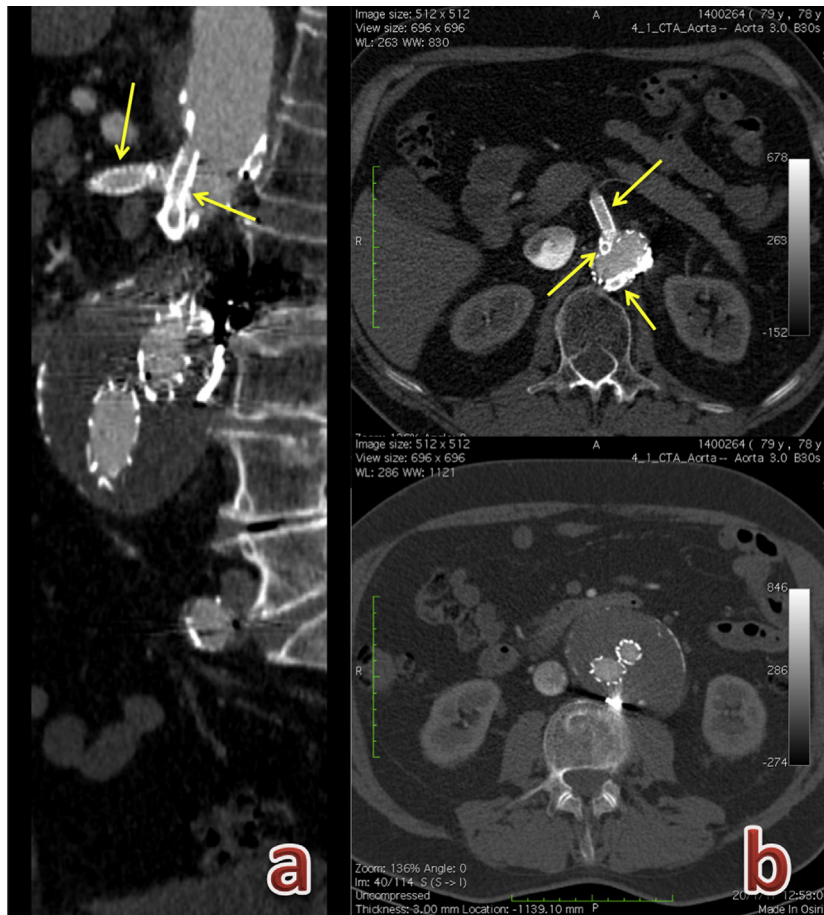


Figure 3. Computed tomography angiography after coil assisted Onyx embolization showing no evidence of endoleak, in the (A) sagittal and (B) axial projections; arrows point to chimney grafts.

expandable covered stents (Advanta/iCast V12 -Atrium/Maquet, Hudson, NH, USA) 6 mm in diameter and 38 mm in length were deployed in each renal artery, and one 7 mm diameter stent in the SMA. Finally, a prolonged kissing balloon of chimney stents and the Endurant stent graft was performed to minimize the risk of gutters and improve the conformability of the devices. However, completion angiography showed a type Ia endoleak with immediate post-injection appearance of contrast, requiring a repeat kissing balloon manoeuvre. Despite the achievement of 20 mm of new proximal sealing length and the 30% oversizing of the aortic endograft, the patient suffered from a gutter related type IA endoleak. Hence the low flow nature of the observed endoleak conservative management was preferred with imaging follow up at three months. The patient was discharged on the fourth post-operative day.

The CTA at three months showed a persistent gutter related type Ia endoleak connected with lumbar arteries without additional aneurysmal sac enlargement (Fig. 1). Treatment with coil assisted onyx embolization was indicated to avoid possible future complications.

From a left brachial approach, over a 6 Fr sheath (Flexor Shuttle Guiding Sheath; Cook), a microcatheter was advanced into the gutter over a 0.014" wire. Then, several 6 mm coils (Axium coils; Medtronic) were deployed in the

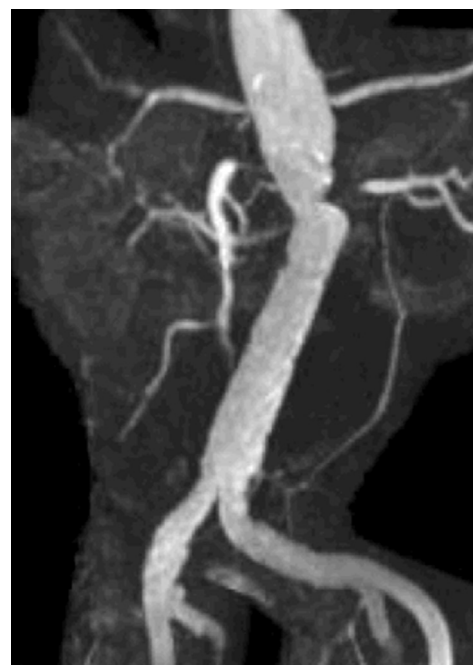

Figure 4. Magnetic resonance angiography at 10 months demonstrating absence of endoleak.

aneurysm sac and the lumbar arteries, which were responsible for the outflow of the endoleak. Finally, the gutters between the left chimney graft and the aortic endograft were filled with Onyx Liquid Embolic System (Medtronic) (Fig. 2). On completion angiography the type Ia endoleak had disappeared. The post-operative CTA confirmed this successful result (Fig. 3). A 10 month magnetic resonance angiogram showed no evidence of endoleak, and the aneurysm diameter remained stable (Fig. 4).

DISCUSSION

To date, the chimney technique has shown promising results in terms of technical success, significant aneurysm sac regression, and a low incidence of type I endoleak requiring re-intervention during the follow up period.^{2,3} A significant advantage of the Ch-EVAR technique is its applicability in

most emergency settings, when a custom made endograft cannot be used and the patient is at high risk for open repair. In this case open surgery by means of a retroperitoneal approach was ruled out because of his comorbidities, including chronic obstructive pulmonary disease and coronary artery disease. The latter made the suprarenal clamping required for a PAA inadvisable.

Although open surgery remains the gold standard for PAAs the only comparison between Ch-EVAR and open repair stated there was no difference in 30 day mortality between the two treatment groups (4.8%). A significant reduction in estimated blood loss, transfusion requirements, and length of stay were also noted in the Ch-EVAR group.⁴

However, the main concern remains the inevitable development of gutters that can lead to a type Ia endoleak,

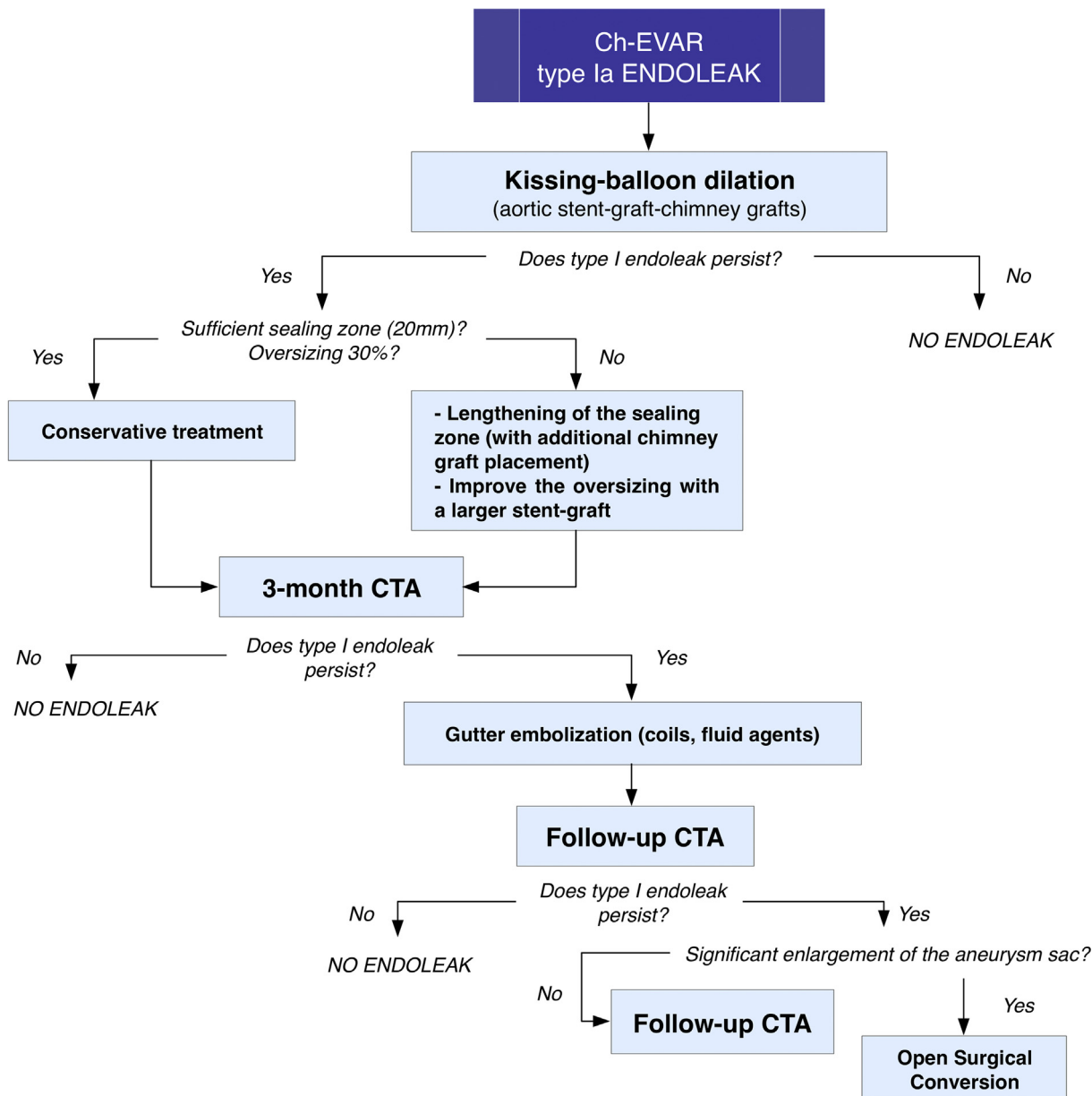


Figure 5. Management algorithm for gutter related type Ia endoleaks during chimney endovascular aneurysm repair.

with current reports indicating a relatively wide ranging incidence (0–13%), including both temporary and persistent type Ia endoleaks.^{1,5,6} This remarkable variability can be explained by the inclusion in these reports of type Ia endoleaks at all phases of treatment and follow up, including the time of the completion angiography, first post-operative CTA, or new onset in case of a CTA during follow up. In order to overcome this diversity, the PERICLES investigators recently published a classification that attempted to identify all causative mechanisms for this phenomenon.⁷ Based on this classification, the presented case represents a type B gutter related endoleak due to the absence of fabric material to wrap the three chimney grafts.

As the natural history of gutter related endoleaks seems to be more benign than expected, only a few cases will require treatment.⁸ When an intra-operative type Ia endoleak appears after Ch-EVAR, it is reasonable to follow conservative treatment with close follow up, as most of these endoleaks will resolve in the first few months. This is especially so following creation of a sufficient new sealing zone of >15 mm, 30% oversizing of the aortic stent graft, and use of a combination of the Endurant (Medtronic) with balloon expandable covered stents or Excluder (Gore, Flagstaff, AZ, USA) with self expanding chimney grafts. In the present case the type Ia endoleak persisted for three months post-operatively, with outflow via the lumbar arteries. CTA reconstruction showed malapposition of the endograft around the chimney graft deployed in the left renal artery. Therefore, it was decided to treat it even though the aneurysm sac showed no evidence of increasing diameter. The suggested treatment consisted of a combination of coils and Onyx Liquid Embolic System (Medtronic), allowing filling of the gap with large coils and completion with Onyx.⁹ To date, a very limited number of gutter embolizations after Ch-EVAR combining coils and onyx have been reported previously,¹⁰ and to the authors' knowledge this is the first case reported for a triple Ch-EVAR.

From this experience, an algorithm to manage gutter related type Ia endoleaks in Ch-EVAR is suggested (Fig. 5); however, confirmation and inclusion of large series is necessary to evaluate the utility of the suggested algorithm.

CONCLUSION

With a sufficient sealing zone of 20 mm and oversizing of the aortic stent graft of 30%, use of onyx in combination with coils can be a successful therapeutic option for a

persistent type B gutter related Ia endoleak after chimney EVAR.

CONFLICT OF INTEREST

None.

FUNDING

None.

REFERENCES

- 1 Donas KP, Lee JT, Lachat M, Torsello G, Veith FJ. Collected world experience about the performance of the snorkel/chimney endovascular technique in the treatment of complex aortic pathologies: the PERICLES registry. *Ann Surg* 2015;**262**:546–53.
- 2 Donas KP, Torsello G, Bisdas T, Osada N, Schönefeld E, Pitoulias GA. Early outcomes for fenestrated and chimney endografts in the treatment of pararenal aortic pathologies are not significantly different: a systematic review with pooled data analysis. *J Endovasc Ther* 2012;**19**:723–8.
- 3 Lee JT, Lee GK, Chandra V, Dalman RL. Comparison of fenestrated endografts and the snorkel/chimney technique. *J Vasc Surg* 2014;**60**:849–56.
- 4 Bruen KJ, Feezor RJ, Daniels MJ, Beck AW, Lee WA. Endovascular chimney technique versus open repair of juxtarenal and suprarenal aneurysms. *J Vasc Surg* 2011;**53**:895–905.
- 5 Donas KP, Torsello GB, Piccoli G, Pitoulias GA, Torsello GF, Bisdas T, et al. The PROTAGORAS study to evaluate the performance of the Endurant stent graft for patients with pararenal pathologic processes treated by the chimney/snorkel endovascular technique. *J Vasc Surg* 2016;**63**:1–7.
- 6 Mestres G, Uribe JP, Garcia Madrid C, Miret E, Alomar X, Burrell M, et al. The best conditions for parallel stenting during EVAR: an in vitro study. *Eur J Vasc Endovasc Surg* 2012;**44**:468–73.
- 7 Donas K, Criado FJ, Torsello G, Veith FJ, Minion DJ. Classification of chimney EVAR-related endoleaks: insights from the pericles registry. *J Endovasc Ther* 2017;**24**:299–300.
- 8 Ullery BW, Tran K, Itoga NK, Dalman RL, Lee JT. Natural history of gutter-related type Ia endoleaks after snorkel/chimney endovascular aneurysm repair. *J Vasc Surg* 2017;**65**:981–90.
- 9 Maeda K, Ohki T, Kanaoka Y, Baba T, Tezuka M, Nakagawa. Concomitant coil embolization for gutter leak during endovascular aortic repair with the snorkel technique. *Ann Vasc Surg* 2017;**45**:265.
- 10 Marcelin C, Le Bras Y, Petitpierre F, Midy D, Grenier N, Ducasse E, et al. Embolization for persistent type Ia endoleaks after chimney endovascular aneurysm repair with Onyx. *Diagn Interv Imag* 2017;**98**:849–55.