

## CASE REPORT

# Warfarin treatment and antifungal agent caspofungin for severe fungal infection in a patient previously treated with radiotherapy for oropharyngeal cancer

Thomas Vedtofte, Camilla Heyn Thisted & Lennart Friis-Hansen

Department of Clinical Biochemistry, Naestved Hospital, University of Copenhagen, Copenhagen, Denmark

### Correspondence

Thomas Vedtofte, Naestved Hospital,  
Ringstedgade, DK4700 Naestved, Denmark.  
Tel: +45 56514545; Fax: +45 56513781;  
E-mail: vedtofte@yahoo.dk

### Funding Information

No sources of funding were declared for this study.

Received: 5 June 2015; Revised: 15  
September 2015; Accepted: 30 October  
2015

*Clinical Case Reports* 2016; 4(2): 143–146

doi: 10.1002/ccr3.469

## Introduction

Current treatment of head and neck cancer combines chemotherapy with radiotherapy [1]. Although this combination regime has improved survival, one of the side effects of radiation treatment is mucosal damage which predisposes to recurrent fungal infections [2]. The initial empiric treatment is often an azole drug [3] for patients with fever and neutropenia secondary to cancer treatment. In adult patients whose disease is refractory to, or who are intolerant of, other antifungal agents (i.e., conventional or lipid formulations of amphotericin B and/or itraconazole) one of the newer drugs used is caspofungin which is effective in treating fungal infections caused by *Aspergillus* and *Candida* species [4]. Caspofungin is a lipopeptide antifungal drug and is a member of a new class of antifungals termed the echinocandins [5]. Caspofungin inhibits the enzyme UDP-glucose- (1, 3)-D-glucan-(3)-D-glucosyltransferase involved in the formation of the cell wall in yeast and molds [6]. Caspofungin, was approved by the United States Food and Drug administration and became available at the United States marked in 2001 [7]. Caspofungin was in general well-tolerated [8] and compared to amphotericin B, appears to have a

### Key Clinical Message

Drug–Drug interactions is important when caring for warfarin-treated patients. We examined the impact on INR with coadministration of warfarin and caspofungin and showed no affect on the INR. Coadministrations of fluconazole lead to a marked increase in INR. We concluded that administration of caspofungin and warfarin was safe.

### Keywords

Caspofungin, fluconazole, INR, interactions, oral mucositis, warfarin.

relatively low incidence of side effects [4]. The side effects to caspofungin used to treat invasive *Aspergillus* were mainly increase in liver enzymes and no serious adverse reactions were recorded [6], even though casuistic reports indicate that there might be more serious adverse reactions [9].

In general cancer predisposes to the development of thromboembolic disease [10, 11] even though occurring less frequent in patients with head and neck cancer [12] compared to high thrombogenic cancers such as pancreatic, stomach, bladder, uterine, renal, and lung cancer [11]. Low-molecular-weight heparin and vitamin K antagonists (VKA) are used to treatment and prevention of thrombosis [13]. One of the disadvantages of using VKA is the multitude of clinical significant drug–drug interactions [14]. Warfarin interacts azoles antifungal therapy [15] and the combination treatment is only indicated if the potential benefit for the patient outweighs the potential risk. To our knowledge, no publications exists on how concurrent administration of caspofungin affects warfarin treatment. We therefore closely monitored INR during caspofungin treatment in order to elucidate any possible interaction between warfarin treatment and the antifungal agent caspofungin.

## Case

Fourteen months before admission to the AC center, at the age of 65 years, the patient was diagnosed with oropharyngeal cancer. He was never smoker, and had an alcohol consumption of approximately 15–20 units per week. The diagnosis was established after diagnostic tonsillectomy removing both tonsils and revealing a tumor in the left palatine tonsil. Pathology examination of the left tonsil revealed a small stage T1, moderate differentiated p16-positive squamous-cell carcinoma with noncohesive invasion. Clinical examinations and PET-CT revealed ipsilateral lymph-node metastases stage N2, but no other sign of further spread of the cancer and TNM classification was (T1N2M0). After establishment of diagnosis, treatment continued with chemoradiotherapy with in total 66 Gray distributed over 33 treatments (6 fractions/week) and weekly concomitant intravenous 70 mg cisplatin infusions. Side effects from the treatment was severe mucosal damage and a profuse weight loss from 116 to 97 kg. In order to prevent further weight loss food was administered by nasogastric tube. The patient was also suffering with-type 2 diabetes for which he was treated with metforminhydrochlorid and gliclazid.

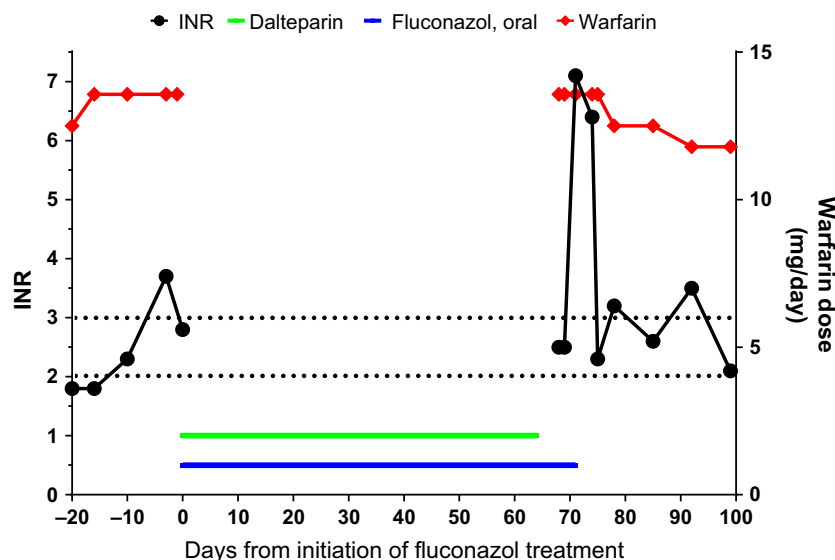
During irradiation therapy, the patient was diagnosed with pulmonary embolism and treated with low-molecular weight heparin for 3 months after which the treatment was discontinued. The reason for discontinuing the therapy was not detailed, and it was not investigated from where the embolus originated. Five months after end of chemoradiotherapy the patient was admitted a local hospital and was diagnosed with an ultrasound confirmed deep vein thrombosis in left popliteal and superficial femoral vein. The event

had been preceded by a period with gastroenteritis and dehydration as well as immobilization. The patient was initially treated with low-molecular-weight heparin (LMWH) and subsequent warfarin as there was no sign of the initial cancer. The warfarin dose (5.0–13.57 mg/day) was adjusted so that the INR intended was between 2.0 and 3.0.

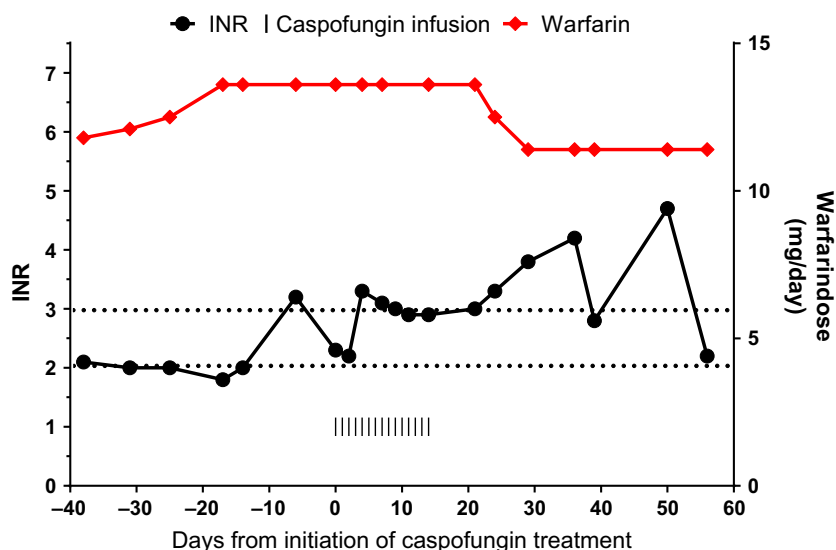
During the postirradiation period, the patient suffered from recurrent fungal infections and treated several times with antifungal medication. He was first diagnosed with *Candida parapsilosis* localized on the tongue treated with fluconazole. From spring, 2013 to winter 2014 the patient suffered from new symptoms of fungal infections and was, during this period, treated multiple times with acetylcysteine, fluconazole, and itraconazole most cures lasting 7–14 days. The antifungal treatment was initiated both by the patient's general practitioner as well as physicians at the hospital. A treatment monitoring throat swap in June 2013 showed no *Candida*.

Due to recurrence of symptoms, the patient underwent longer lasting treatment for 8 weeks with fluconazole from December to January 2014, but sadly without a pre-treatment throat swap. Due to the interactions with warfarin and fluconazole, warfarin treatment was substituted with LMWH.

In the final days of the fluconazole treatment the patient was, due to miscommunication, reintroduced to warfarin treatment and as expected this interacted with the fluconazole treatment and caused a rapid increase in INR reaching a level of 2.5 4 days after reintroduction of warfarin treatment and a further increase during the next days. (Fig. 1). A throat swap in March 2014 showed growth of *Candida Krusei* sensitive to caspofungin and



**Figure 1.** Fluconazole treatment influence on warfarin treatment. The given dose of warfarin and the resulting INR. The figure shows how adding fluconazole leads to an increase in INR.



**Figure 2.** Caspofungin treatment influence on warfarin treatment. The given dose of warfarin and the resulting INR. The figure shows that concomitant administration of caspofungin and warfarin does not affect INR.

treatment was initiated with once a day I.V administration for 14 days concomitant with warfarin without affecting the VKA treatment (Fig. 2).

## Discussion

Posttreatment oropharyngeal mycosis due long-term radiation sequelae is a common condition in patients who have undergone chemoradiotherapy for head and neck cancers [16]. Patients with diabetes are more often colonized with the opportunistic pathogen *Candida* in the oral cavity [17]. Fluconazole is often-used as first-line antimycotic agent for oropharyngeal mycosis after treatment for head and neck cancer [18] and it seem appropriate to do so given the resistance patterns of the most frequently involved yeasts [19].

Cancer increases the risk of deep venous thrombosis [20] even though it seems to be at lesser extent for head and neck cancers [21]. The preferred treatment of cancer associated thromboembolism is low molecular weight heparin which has been shown more effective than vitamin K antagonists [22] but for long-term AC treatment, oral anticoagulant therapy were preferred for patients without active cancer [23]. As we observed concomitant treatment with warfarin and fluconazole may be difficult due to the interactions caused by the inhibition of the p 450 liver enzyme by fluconazole [24]. The elimination of caspofungin follow a different pathway mainly by peptide hydrolysis and/or *N*-acetylation [25] which is not involved in the elimination of warfarin [26]. Previous publications state that caspofungin may be an inhibitor of

P450 3A4 In vitro [27] this in contrary with our findings In vivo, where we found no interaction between caspofungin and warfarin treatment. Although it is too early to issue a general recommendation our data suggest that coadministration of caspofungin and warfarin is safe.

## Materials and Methods

The INR measurements were drawn from the lab system at the AC (anticoagulation) Center. INR was analyzed using Stago's STA-R Evolution, reagent STA<sup>®</sup> – SPA +. The Coefficient of variation was in that period less than 3%.

The patient was referred to the AC –center in order to optimize the AC treatment after the second thrombus.

## Conflict of Interest

None declared.

## References

1. Syrigos, K. N., D. Karachalios, E. M. Karapanagiotou, C. M. Nutting, L. Manolopoulos, and K. J. Harrington. 2009. Head and neck cancer in the elderly: an overview on the treatment modalities. *Cancer Treat. Rev.* 35:237–245.
2. Bensadoun, R. J., L. L. Patton, R. V. Lalla, and J. B. Epstein. 2011. Oropharyngeal candidiasis in head and neck cancer patients treated with radiation: update 2011. *Support. Care Cancer* 19:737–744.
3. Yu, D. T., D. L. Seger, J. F. Peterson, R. N. Kumar, and D. W. Bates. 2006. Fluconazole for empiric antifungal therapy

- in cancer patients with fever and neutropenia. *BMC Infect. Dis.* 6:173.
4. Walsh, T. J., H. Tepler, G. R. Donowitz, J. A. Maertens, L. R. Baden, A. Dmoszynska, et al. 2004. Caspofungin versus liposomal amphotericin B for empirical antifungal therapy in patients with persistent fever and neutropenia. *N. Engl. J. Med.* 351:1391–1402.
  5. Balkovec, J. M., D. L. Hughes, P. S. Masurekar, C. A. Sable, R. E. Schwartz, and S. B. Singh. 2014. Discovery and development of first in class antifungal caspofungin (CANCIDAS(R))—a case study. *Nat. Prod. Rep.* 31:15–34.
  6. Traunmuller, F., M. Popovic, K. H. Konz, F. M. Smolle-Juttner, and C. Joukhadar. 2011. Efficacy and safety of current drug therapies for invasive aspergillosis. *Pharmacology* 88:213–224.
  7. Ascioğlu, S., and K. A. Chan. 2014. Utilization and comparative effectiveness of caspofungin and voriconazole early after market approval in the U.S. *PLoS ONE* 9: e83658.
  8. Herbrecht, R., J. Maertens, L. Baila, M. Aoun, W. Heinz, R. Martino, et al. 2010. Caspofungin first-line therapy for invasive aspergillosis in allogeneic hematopoietic stem cell transplant patients: an European Organisation for Research and Treatment of Cancer study. *Bone Marrow Transplant.* 45:1227–1233.
  9. Biswal, S. 2012. Complete heart block in a neutropenic patient with aspergillosis: an unusual adverse effect of caspofungins. *J. Pharmacol. Pharmacother.* 3:342–344.
  10. Heit, J. A. 2003. Risk factors for venous thromboembolism. *Clin. Chest Med.* 24:1–12.
  11. Chew, H. K., T. Wun, D. Harvey, H. Zhou, and R. H. White. 2006. Incidence of venous thromboembolism and its effect on survival among patients with common cancers. *Arch. Intern. Med.* 166:458–464.
  12. Hennessey, P., Y. R. Semenov, and C. G. Gourin. 2012. The effect of deep venous thrombosis on short-term outcomes and cost of care after head and neck cancer surgery. *Laryngoscope* 122:2199–2204.
  13. Chappelle, C., N. Rosencher, Z. P. Jacques, P. Mismetti, M. Cucherat, and S. Laporte. 2014. Prevention of venous thromboembolic events with low-molecular-weight heparin in the non-major orthopaedic setting: meta-analysis of randomized controlled trials. *Arthroscopy* 30:987–996.
  14. Cropp, J. S., and H. I. Bussey. 1997. A review of enzyme induction of warfarin metabolism with recommendations for patient management. *Pharmacotherapy* 17:917–928.
  15. Yu, D. T., J. F. Peterson, D. L. Seger, W. C. Gerth, and D. W. Bates. 2005. Frequency of potential azole drug-drug interactions and consequences of potential fluconazole drug interactions. *Pharmacoepidemiol. Drug Saf.* 14:755–767.
  16. Busetto, M., V. Fusco, F. Corbella, M. Bolzan, G. Pavanato, B. Bonetti, et al. 2013. Predictive factors for oropharyngeal mycosis during radiochemotherapy for head and neck carcinoma and consequences on treatment duration. Results of mycosis in radiotherapy (MIR): a prospective longitudinal study. *Radiother. Oncol.* 109:303–310.
  17. Pallavan, B., V. Ramesh, B. P. Dhanasekaran, N. Oza, S. Indu, and V. Govindarajan. 2014. Comparison and correlation of candidal colonization in diabetic patients and normal individuals. *J. Diabetes Metab. Disord.* 13:66.
  18. Rao, N. G., G. Han, J. N. Greene, T. Tanvetyanon, J. A. Kish, R. C. De Conti, et al. 2013. Effect of prophylactic fluconazole on oral mucositis and candidiasis during radiation therapy for head-and-neck cancer. *Pract. Radiat. Oncol.* 3:229–233.
  19. Bulacio, L., M. Paz, S. Ramadan, L. Ramos, C. Pairoba, M. Sortino, et al. 2012. Oral infections caused by yeasts in patients with head and neck cancer undergoing radiotherapy. Identification of the yeasts and evaluation of their antifungal susceptibility. *J. Mycol. Med.* 22:348–353.
  20. Levitan, N., A. Dowlati, S. C. Remick, H. I. Tahsildar, L. D. Sivinski, R. Beyth, et al. 1999. Rates of initial and recurrent thromboembolic disease among patients with malignancy versus those without malignancy. Risk analysis using Medicare claims data. *Medicine (Baltimore)* 78:285–291.
  21. Gavriel, H., E. Thompson, S. Kleid, S. Chan, and A. Sizeland. 2013. Safety of thromboprophylaxis after oncologic head and neck surgery. Study of 1018 patients. *Head Neck* 35: 1410–1414.
  22. Frere, C., P. Debourdeau, A. Hij, F. Cajfinger, M. N. Onan, L. Panicot-Dubois, et al. 2014. Therapy for cancer-related thromboembolism. *Semin. Oncol.* 41:319–338.
  23. Kearon, C., and E. A. Akl. 2014. Duration of anticoagulant therapy for deep vein thrombosis and pulmonary embolism. *Blood* 123:1794–1801.
  24. Bavisotto, L. M., D. J. Ellis, P. G. Milner, D. L. Combs, I. Irwin, and D. M. Canafax. 2011. Tecarfarin, a novel vitamin K reductase antagonist, is not affected by CYP2C9 and CYP3A4 inhibition following concomitant administration of fluconazole in healthy participants. *J. Clin. Pharmacol.* 51:561–574.
  25. Balani, S. K., X. Xu, B. H. Arison, M. V. Silva, A. Gries, F. A. DeLuna, et al. 2000. Metabolites of caspofungin acetate, a potent antifungal agent, in human plasma and urine. *Drug Metab. Dispos.* 28:1274–1278.
  26. Stehle, S., J. Kirchheiner, A. Lazar, and U. Fuhr. 2008. Pharmacogenetics of oral anticoagulants: a basis for dose individualization. *Clin. Pharmacokinet.* 47:565–594.
  27. Colburn, D. E., F. J. Giles, D. Oladovich, and J. A. Smith. 2004. In vitro evaluation of cytochrome P450-mediated drug interactions between cytarabine, idarubicin, itraconazole and caspofungin. *Hematology* 9:217–221.