

Pseudoaneurysm of the Second Dorsal Metatarsal Artery: Case Report and Literature Review

Christopher W Kinter¹  and Christopher W Hodgkins²

¹School of Medicine, Emory University, Atlanta, GA, USA. ²Miami Orthopedics & Sports Medicine Institute, Baptist Health South Florida, Miami, FL, USA.

Clinical Medicine Insights: Arthritis and Musculoskeletal Disorders
Volume 12: 1–4
© The Author(s) 2019
Article reuse guidelines:
sagepub.com/journals-permissions
DOI: 10.1177/1179544119849886



ABSTRACT: Pseudoaneurysms are a rare complication of foot and ankle surgeries that can potentially lead to serious sequelae, especially when there is delay in the diagnosis. Due to the rarity of this occurrence, guidelines for management are limited for orthopedic surgeons. Once diagnosed, the surgeon has to decide quickly on many options for how to best manage the patient. In this case report, we present the occurrence of a dorsal second metatarsal artery pseudoaneurysm that occurred after removal of hardware. We also discuss the most current literature on the subject to help guide other surgeons in the diagnosis and management of this condition.

KEYWORDS: vascular disease, surgical complications, arthritis and joint disease, soft tissue repair / trauma, diagnostic vascular testing, foot surgery techniques, ultrasound, proximal procedures of the first ray

RECEIVED: March 6, 2019. **ACCEPTED:** April 17, 2019.

TYPE: Case Report

FUNDING: The author(s) received no financial support for the research, authorship, and/or publication of this article.

DECLARATION OF CONFLICTING INTERESTS: The author(s) declared no potential conflicts of interest with respect to the research, authorship, and/or publication of this article.

CORRESPONDING AUTHOR: Christopher W Kinter, Department of Orthopaedics, School of Medicine, Emory University, Executive Park South, Suite 120, Atlanta, GA, 30329, USA. Email: ckinter@emory.edu

Introduction

A pseudoaneurysm is a permanent focal dilation of a blood vessel more than 50% larger than normal for that artery with vessel wall disruption that expands into surrounding tissues and is encapsulated by less than all 3 layers of the vessel wall.^{1,2} A pseudoaneurysm in the foot is a rare event, usually caused by trauma or iatrogenic insult which can result in morbidity such as hemorrhage, compression of surrounding nerves, thromboembolism, thrombosis, hemorrhage, or distal emboli.^{2,3} Here we demonstrate a case of a pseudoaneurysm of the second dorsal metatarsal artery of the foot following removal of hardware from the lateral naviculocuneiform (NC) joint to highlight the potential of this rare event and discuss its diagnosis and management.

Case Report

We present the case of a 67-year-old female who had undergone an extended medial column and NC joint arthrodesis. The patient made an uncomplicated recovery; however, she was symptomatic of the prominent hardware due to a lateral NC joint screw. Twelve months following the index procedure, the hardware was removed percutaneously (see Figure 1). In both cases, the patient was prescribed 325 mg aspirin to be taken daily for 10 days for deep vein thrombosis (DVT) prophylaxis.

One month following this, she presented with increased pain and swelling in the dorsal midfoot. On careful examination, she had a pulsatile mass underneath the lateral percutaneous incision. Initial investigation with a Doppler ultrasound demonstrated a pulsatile aneurysm measuring 2.5×1.7 cm. A computed tomography (CT) angiogram confirmed this to be a branch of the dorsal metatarsal artery (see Figures 2 and 3). Vascular surgery was consulted and agreed with our decision to excise the pseudoaneurysm.

The patient was taken back to the operating room for exploration, excision, and ligation of the pseudoaneurysm. Preoperative CT angiography confirmed adequate collateral flow. The pseudoaneurysm was located so close to the second metatarsal artery and vein that there was not sufficient length of the branch to ligate it individually. Therefore, the second dorsal metatarsal artery and vein were ligated. The tourniquet was deflated with a total time of 18 minutes at 300 mm Hg, and hemostasis was observed. The incision was closed in standard fashion, and a sterile compression dressing was applied. Of note, we did not use heparin at any point during this surgery. Postoperatively she was admitted to the hospital and observed. She was commenced on DVT prophylaxis with 325 mg aspirin per day for 10 days starting on day 1. The dressing was removed on day 1 without evidence of pseudoaneurysm or postoperative bleeding.

At 2-week follow-up, she was full weight bearing in a postoperative shoe. Her incision was healing well without recurrence of the pseudoaneurysm.

Discussion

Arterial injuries are rare in elective orthopedic surgeries in general, with an estimated incidence of 0.005%.⁴ Pseudoaneurysms are potentially dangerous lesions that are secondary to vascular damage. They can cause fatal bleeding if left untreated or can cause clots resulting in distal ischemia. They can affect surrounding structures when they enlarge, causing compressive symptoms and pain. Dorsalis pedis pseudoaneurysms have been noted to cause neuropathy secondary to compression that is relieved by operative removal of the pseudoaneurysm.^{5,6}

Pseudoaneurysms typically occur in the acute period after the insult, and they are usually diagnosed clinically as a pulsatile, expansile mass. Patients with collagen vascular conditions may be predisposed to pseudoaneurysm formation. Other



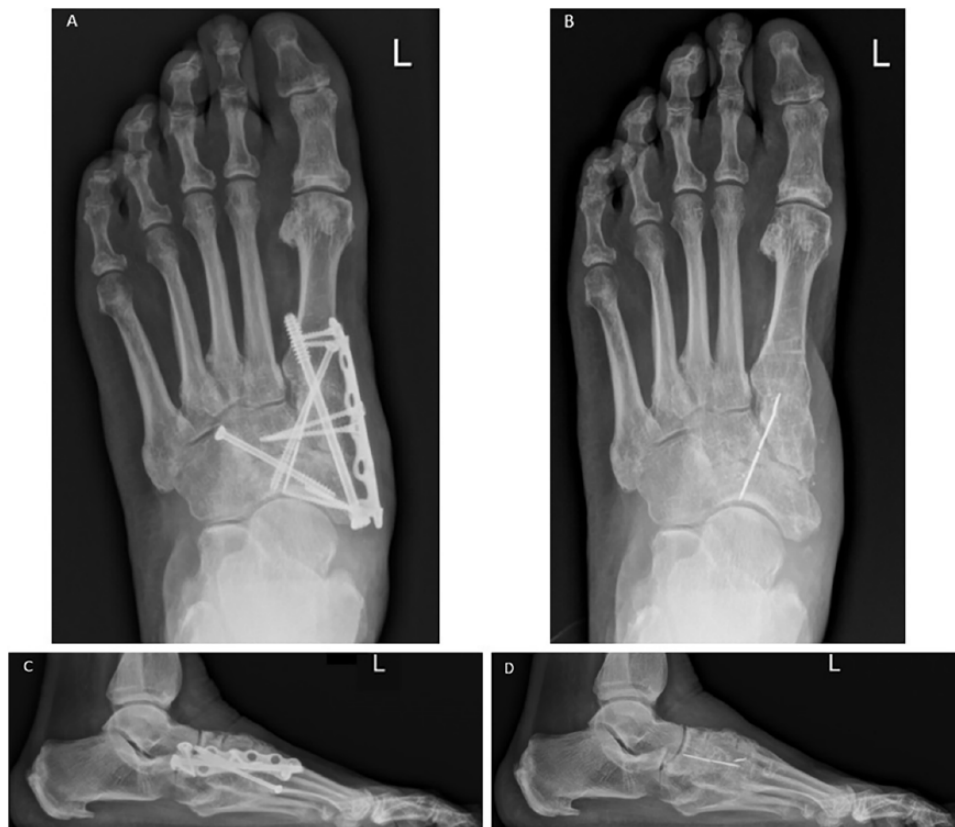

Figure 1. (A) Anteroposterior (AP) radiograph of the foot before removal of hardware; (B) AP radiograph after removal of hardware; (C) lateral radiograph of the foot before removal of hardware; (D) lateral radiograph after removal of hardware.

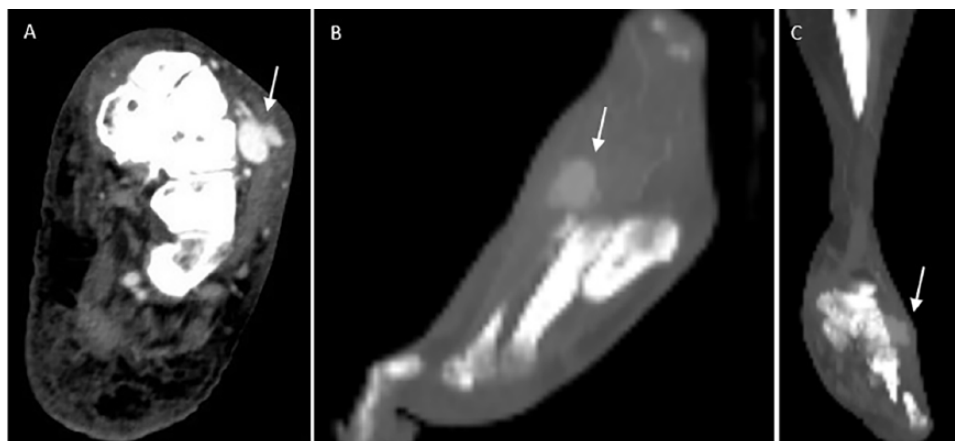


Figure 2. Computed tomography angiogram demonstrating a pseudoaneurysm of the second dorsal metatarsal artery in axial (A), sagittal (B), and coronal (C) planes.

conditions such as infection, hypoxia, and diabetes have also been described as risk factors.⁷ Diagnosis can be confirmed by Doppler ultrasound, with a sensitivity and specificity of 94% and 97%, respectively.³ Other techniques include CT angiography, magnetic resonance (MR) angiography, or conventional angiography. Doppler ultrasound is a simple test to confirm the diagnosis; however, angiography offers the additional benefit of allowing for presurgical planning of the case.⁷

Of all of the vessels of the foot and ankle to be affected by pseudoaneurysms, the anterior tibial artery is the most common. In a literature review, 17 of 33 foot and ankle cases involved

the anterior tibial artery. Other commonly affected vessels were the dorsalis pedis (9 of 33) and peroneal branches (5 of 33).² Wollstein et al⁸ found 19 reported cases of pseudoaneurysm in the foot, including 8 cases affecting the dorsalis pedis artery, 6 affecting the plantar artery, and 5 affecting the posterior tibial artery. In our review of the literature, only 1 metatarsal artery pseudoaneurysm has been published as occurring in man, and 1 in a horse.^{9,10} The equine case was a pseudoaneurysm of a dorsal metatarsal artery that was secondary to trauma, and it spontaneously resolved after diagnosis. The human case was secondary to proximal chevron osteotomy and Akin phalangeal osteotomy,

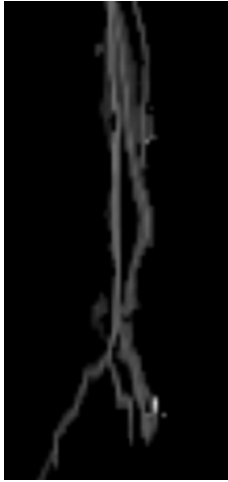

Figure 3. Three-dimensional reconstruction of the vasculature showing the pseudoaneurysm in relation to a small retained piece of hardware.

and it occurred at the division of the dorsalis pedis artery into the first metatarsal branch and arcuate artery. Symptoms of swelling and pain began on the dorsum of the foot 3 days after operation. Doppler ultrasound imaging revealed a dorsal first metatarsal artery pseudoaneurysm that housed a mural thrombus. The authors were able to excise and ligate the lesion with good results at 6-month follow-up.

Treatment options for pseudoaneurysms include operative removal, vein patch angioplasty, ultrasound guided compression, ultrasound guided thrombin injection, and endoluminal management via stent or embolization. It is recommended to treat any symptomatic or enlarging pseudoaneurysm.

Operative treatment is well suited for lesions with mass effect causing symptoms such as neuropathy or ischemia, infected pseudoaneurysms, or when minimally invasive techniques have failed.^{3,11} Operative treatment specifically includes ligation with aneurysmectomy and repair or reconstruction either with or end-to-end anastomosis or grafting. Most pseudoaneurysms in the foot are treated operatively because it offers a more immediate solution than other options where the resolution is more gradual.^{2,12} The foot is an area with very limited space available for an expansile mass and, therefore, is often problematic and in need of a quick solution. In 16 operatively treated cases of dorsalis pedis artery pseudoaneurysm repair, all but 2 used operative ligation without reanastomosis. None of the 16 cases had distal ischemia or other complications.¹²

Another surgical option that may be especially helpful for those who require perfusion distal to the affected artery is the vein patch angioplasty. This technique involves using a portion of autologous vein tissue to patch over an area of injured artery.¹³ In a case report of dorsalis pedis pseudoaneurysm after ankle arthroscopy, the authors successfully used vein patch angioplasty to repair the pseudoaneurysm.¹⁴ This technique can be useful in those with diminished peripheral perfusion such as elderly or diabetic patients.

The vascular anatomy of the foot is highly variable and the surgeon often has to take each surgery on a case-by-case basis.

“Textbook normal” arterial network anatomy is a rare finding. The second dorsal metatarsal artery, which was affected in our case, is most often a continuation of the dorsalis pedis artery along with the first dorsal metatarsal artery. However, this anatomy was only noted 37.5% of cases in a study of 32 cadaveric feet.¹⁵ Therefore, preoperative planning with MR angiography or CT angiography is advisable.⁷

There are inherent risks involved in operative removal, so many now choose minimally invasive techniques for removal of symptomatic pseudoaneurysms. Without treatment, there are noted cases of spontaneous regression of pseudoaneurysms.^{6,16,17} Ultrasound compression is a feasible option for readily accessible locations with minimal risk of complication. This technique is typically used for pseudoaneurysms of the femoral artery after percutaneous procedures, and it is most successful for lesions with a long and narrow neck. The downside to this technique is that it fails to treat the lesion in 15% to 38% of cases, and they have 20% to 30% recurrence if the patient is on anticoagulants.³

Thrombin injection is another technique that is effective in 94% of postcatheterization pseudoaneurysms.¹⁸ This is a technique that can be useful when ultrasound compression fails, and its success rate is not dependent on use of anticoagulants.¹⁹ However, like compression, thrombin injection is best suited for pseudoaneurysms with long, narrow necks.

Finally, endovascular management can be performed with stents or coil embolization.²⁰ One problem with stents distal to the popliteal artery is that they are known to reocclude in atherosclerotic patients.²¹ Also, the placement of stents in small arteries of the foot may not be anatomically possible when so distal, and small enough stents to reach such sites may not be available. Alternatively, endovascular coils can be inserted into the pseudoaneurysm to cause embolus formation in the pseudoaneurysm. In the foot and ankle, distal and proximal embolization can be performed so long as adequate collateral flow is present. Younger patients are more likely to have good perfusion via collateral flow, and embolization is a viable option for these patients.²²

In our case, it is likely that the removal of hardware operation resulted in the complication of a pseudoaneurysm of the second dorsal metatarsal artery. Due to her age and increasing symptoms, we felt operative ligation was an option that would most likely lead to success in her case. The literature supports this option for high rates of success and low risks.⁷ The operation was simple due to the superficial location and preoperative planning with CT angiogram. The operation allowed for her to have definitive treatment from which she has healed well without complication.

Conclusions

In conclusion, pseudoaneurysms are rare complications that can arise from trauma or from any operation in which blood vessels are manipulated. It is important for the surgeon to be able to recognize this complication. When a pseudoaneurysm is noted, the clinician should consult vascular surgery or interventional

radiology to assist with management. The literature is sparse pertaining to pseudoaneurysms in the foot, and this is the only noted case of a pseudoaneurysm of the second metatarsal artery.

The best diagnostic tests available are Doppler ultrasound and CT angiogram. Treatments include observation, thrombin injections, ultrasound compression, intraluminal manipulation, and operative excision and ligation. Surgery offers the most definitive solution and is best suited for lesions of increasing size and those that are continually symptomatic. Open operative treatment is both safe and effective in treating pseudoaneurysms such as this, and we recommend it for similar cases.⁷

Treatment should be done on a case-by-case basis. Lesions that are likely to have complications such as bleeding or those found to have a thrombus should be handled quickly to avoid known complications.

Author Contributions

CWH managed the care of the patient throughout the case. CWK saw the patient in clinic and wrote the manuscript.

ORCID iD

Christopher W Kinter  <https://orcid.org/0000-0002-5417-1185>

REFERENCES

1. Navarro TP, Dardik A, Junqueira D, Cisneros L, eds. *Vascular Diseases for the Non-Specialist*. Cham, Switzerland: Springer International; 2017.
2. Yu JL, Ho E, Wines AP. Pseudoaneurysms around the foot and ankle: case report and literature review. *Foot Ankle Surg*. 2013;19:194–198. doi:10.1016/j.fas.2012.08.003.
3. Saad NEA, Saad WEA, Davies MG, Waldman DL, Fultz PJ, Rubens DJ. Pseudoaneurysms and the role of minimally invasive techniques in their management. *Radiographics*. 2005;25:S173–S189. doi:10.1148/rg.25si055503.
4. Wilson JS, Miranda A, Johnson BL, Shames ML, Back MR, Bandyk DF. Vascular injuries associated with elective orthopedic procedures. *Ann Vasc Surg*. 2003;17:641–644. doi:10.1007/s10016-003-0074-2.
5. Nishi H, Miyamoto S, Minamimura H, Ishikawa T, Katoh Y, Shimizu Y. Pseudoaneurysm of the dorsalis pedis artery causing neurological deficit. *Ann Vasc Surg*. 2004;18:487–489. doi:10.1007/s10016-004-0065-y.
6. Wooster BM, Grimm NL, DeOrto JK, Mithani SK. Iatrogenic arteriovenous fistula with associated pseudoaneurysm of posterior tibial artery after revision total ankle arthroplasty: a case report. *J Foot Ankle Surg*. 2017;56:75–77. doi:10.1053/j.fas.2016.09.014.
7. Vlachovsky R, Staffa R, Novotny T. Pseudoaneurysm of the dorsalis pedis artery: case report and literature review. *J Foot Ankle Surg*. 2017;56:398–400. doi:10.1053/j.fas.2016.10.009.
8. Wollstein R, Wolf Y, Sklair-Levy M, Matan Y, London E, Nyska M. Obliteration of a late traumatic posterior tibial artery pseudoaneurysm by duplex compression. *J Trauma*. 2000;48:1156.
9. Lee KT, Park Y, Jegal H, Tae Roh Y, Yong Hong K. Pseudoaneurysm after proximal metatarsal osteotomy for hallux valgus correction: a case report. *J Korean Foot Ankle Soc*. 2014;18:80–82. doi:10.14193/jkfas.2014.18.2.80.
10. Watrous BJ, Riebold TW, Wagner PC, Hultgren BD. Spontaneous resolution of a pseudoaneurysm in a horse following angiographic diagnosis. *Veter Radiol Ultr*. 2005;28:49–52. doi:10.1111/j.1740-8261.1987.tb01723.x.
11. Arata MA, Cope C. Principles used in the management of visceral aneurysms. *Tech Vasc Intervent Radiol*. 2000;3:124–129. doi:10.1053/tvir.2000.9147.
12. Kolber MK, Shukla PA, Kumar A, Berkowitz E. Endovascular treatment of a dorsalis pedis artery pseudoaneurysm. *Vasc Endovascular Surg*. 2016;50:283–285. doi:10.1177/1538574416638761.
13. Keen RR, Meyer JP, Durham JR, et al. Autogenous vein graft repair of injured extremity arteries: early and late results with 134 consecutive patients. *J Vasc Surg*. 1991;13:664–668.
14. Kwon JN, Lee SY, Kim YM. Pseudoaneurysm of the dorsalis pedis artery following ankle arthroscopy. *Vascular Medicine*. 2014;19:510–511. doi:10.1177/135863X14557153.
15. Lee JH, Dauber W. Anatomic study of the dorsalis pedis–first dorsal metatarsal artery. *Ann Plast Surg*. 1997;38:50–55.
16. Soudack M, Epelman M, Gaitini D. Spontaneous thrombosis of hepatic post-traumatic pseudoaneurysms: sonographic and computed tomographic features. *J Ultrasound Med*. 2003;22:99–103. doi:10.7863/jum.2003.22.1.99.
17. Malghem J, Abdalkader M, Lecouvet F, Goffette P, Hammer F, Vande Berg B. Pseudoaneurysms after ankle sprain: report of three cases successfully cured by nonsurgical treatment. *Ann Vasc Surg*. 2017;40:296.e5–296.e13. doi:10.1016/j.avsg.2016.07.103.
18. La Perna L, Olin JW, Goines D, Childs MB, Ouriel K. Ultrasound-guided thrombin injection for the treatment of postcatheterization pseudoaneurysms. *Circulation*. 2000;102:2391–2395.
19. Brophy DP, Sheiman RG, Amatulle P, Akbari CM. Iatrogenic femoral pseudoaneurysms: thrombin injection after failed US-guided compression. *Radiology*. 2000;214:278–282. doi:10.1148/radiology.214.1.r00ja10278.
20. Rosa P, O'Donnell SD, Goff JM, Gillespie DL, Starnes B. Endovascular management of a peroneal artery injury due to a military fragment wound. *Ann Vasc Surg*. 2003;17:678–681.
21. Spirito R, Trabattoni P, Pompilio G, Zoli S, Agrifoglio M, Biglioli P. Endovascular treatment of a post-traumatic tibial pseudoaneurysm and arteriovenous fistula: case report and review of the literature. *J Vasc Surg*. 2007;45:1076–1079. doi:10.1016/j.jvs.2006.12.038.
22. Singh D, Ferero A. Traumatic pseudoaneurysm of the posterior tibial artery treated by endovascular coil embolization. *Foot Ankle Spec*. 2013;6:54–58. doi:10.1177/1938640012463053.