

Endogenous Nocardial Endophthalmitis in an Immunosuppressed Patient: A Serious Warning of an Underlying Life Threatening and Blinding Disorder

Hemant Trehan¹, MS; Jaya Kaushik^{1,2}, MS; Vaibhav Kumar Jain³, MD; Jitendra Kumar Singh Parihar¹, MS
Abhijit Avasthi¹, MS

¹Department of Ophthalmology, Army Hospital Research and Referral, Delhi Cantonment, India

²Department of Ophthalmology, Post Graduate Institute of Medical Education and Research, Chandigarh, India

³Department of Ophthalmology, Uttar Pradesh Rural Institute of Medical Sciences, Saifai, Etawah, Uttar Pradesh, India

Abstract

Purpose: To report a case of bilateral endogenous nocardial endophthalmitis with central nervous system involvement in an immunocompromised individual with an extremely poor outcome.

Case Report: A 35-year-old man with a history of long-term, prescribed oral steroid use for membranoproliferative glomerulonephritis presented with profound bilateral vision loss. Patient's diagnosis of bilateral endogenous nocardial endophthalmitis was delayed. Nocardia was finally isolated from a brain biopsy after a repeat magnetic resonance imaging revealed a brain abscess. With anti-nocardia therapy, patient improved systemically, but the visual outcome was poor, with no light perception in both eyes.

Conclusion: Ocular nocardiosis is a serious vision and life threatening disorder, particularly in patients on immunosuppressive therapy. A high index of suspicion is required for successful treatment.

Keywords: Ahmed Glaucoma Valve; Bilateral Endogenous Nocardial Endophthalmitis; Brain Abscess; Glomerulonephritis; Membranoproliferative Glomerulonephritis; Ocular Nocardiosis

J Ophthalmic Vis Res 2017; 12 (1): 113-116

INTRODUCTION

Ocular nocardiosis is uncommon, difficult to diagnose disorder, and encountered primarily in immunocompromised patients. It is typically caused by *Nocardia asteroides*.^[1] This is an aerobic, gram positive, partially acid fast organism belonging

to order Actinomycetales. Initially this bacterium was classified as a fungus; however its cell wall structure and intracellular organelles resemble those of bacteria, and it is now classified as a bacterium. Historically, nocardial infections in humans are very rare and often self-limiting. However, their frequency and severity are increasing, particularly as immunosuppressive and chemotherapeutic agents are used more frequently for systemic diseases. We present a case of an immunocompromised patient presenting with bilateral endogenous nocardial endophthalmitis along with central nervous system involvement that resulted in an extremely poor outcome.

This is an open access article distributed under the terms of the Creative Commons Attribution-NonCommercial-ShareAlike 3.0 License, which allows others to remix, tweak, and build upon the work non-commercially, as long as the author is credited and the new creations are licensed under the identical terms.

For reprints contact: reprints@medknow.com

How to cite this article: Trehan H, Kaushik J, Jain VK, Parihar JKS, Avasthi A. Endogenous nocardial endophthalmitis in an immunosuppressed patient: A serious warning of an underlying life threatening and blinding disorder. *J Ophthalmic Vis Res* 2017;12:113-6.

Correspondence to:

Jaya Kaushik, MS. Advanced Eye Center, Post Graduate Institute of Medical Education and Research, Sector-12, Chandigarh 160 012, India.

E-mail: arnavjaya@gmail.com

Received: 22-04-2015

Accepted: 18-08-2015

Access this article online

Quick Response Code:



Website:
www.jovr.org

DOI:
10.4103/2008-322X.200172

CASE REPORT

A 35-year-old-male patient presented with sudden loss of vision associated with periorbital swelling in both eyes (OU). He had systemic complaints of fever and pedal edema. The patient was already undergoing treatment for membranoproliferative glomerulonephritis, and for the previous seven months was taking oral prednisone (pg. mg/day) and Angiotensin converting enzyme inhibitor. Ocular examination revealed visual acuity of light perception (LP) with inaccurate ray projection in OU.

Slit lamp biomicroscopic examination revealed 2+ cells in anterior chamber and pigments over the anterior lens surface in OU. Fundus examination revealed hazy media along with retinal detachment in the inferotemporal area in OU. Sub-retinal exudates, intraretinal hemorrhages along with dilated veins and narrowed arteries were visible. Intraocular pressure (IOP) was 16 mmHg in OU. The patient had blood pressure of 160/100 mmHg and bradycardia. Hence, the initial diagnosis was hypertension related exudative retinal detachment, although both atypical central serous chorioretinopathy and Vogt-Koyanagi Harada syndrome were also considered in differential diagnosis. After receiving a nephrologist's opinion, the patient was stabilized with an injection of hydrocortisone 200 mg OD, frusemide

40 mg OD, cefixime 200 mg BD along with amlodipine 5 mg OD as a hypertensive drug.

After two days, the patient developed generalized hypotony, a staggering gait, truncal ataxia, and buccal and proximal weakness with decreased plantar reflexes. After neurology consultation, a pontomedullary lesion or cytomegalovirus meningitis was considered as an initial cause. A cerebrospinal fluid tap was performed to rule out meningitis; the results were normal. Magnetic resonance imaging (MRI) of the brain [Figure 1a and b] showed multiple cystic-enhancing lesions over both cerebral hemispheres, suggestive of tuberculomas or neurocysticercosis.

The patient was started on anti-tubercular treatment (ATT) along with oral steroids. Four days after starting ATT, the patient had a generalized tonic-clonic seizure. A contrast MRI showed disseminated parenchymal lesions. At the beginning of anti-epileptic treatment, patient showed signs of improvement over the next two weeks; however after this period the patient started worsening. The patient had restricted abduction, sluggishly reacting pupils, 3+ cells in the anterior chamber OU with IOP of 66 and 52 mmHg in the right and left eyes, respectively. Fundus examination revealed increased exudates, increased height of retinal detachment and vitreous cells OU. A diagnosis of disseminated toxoplasma or malignancy was

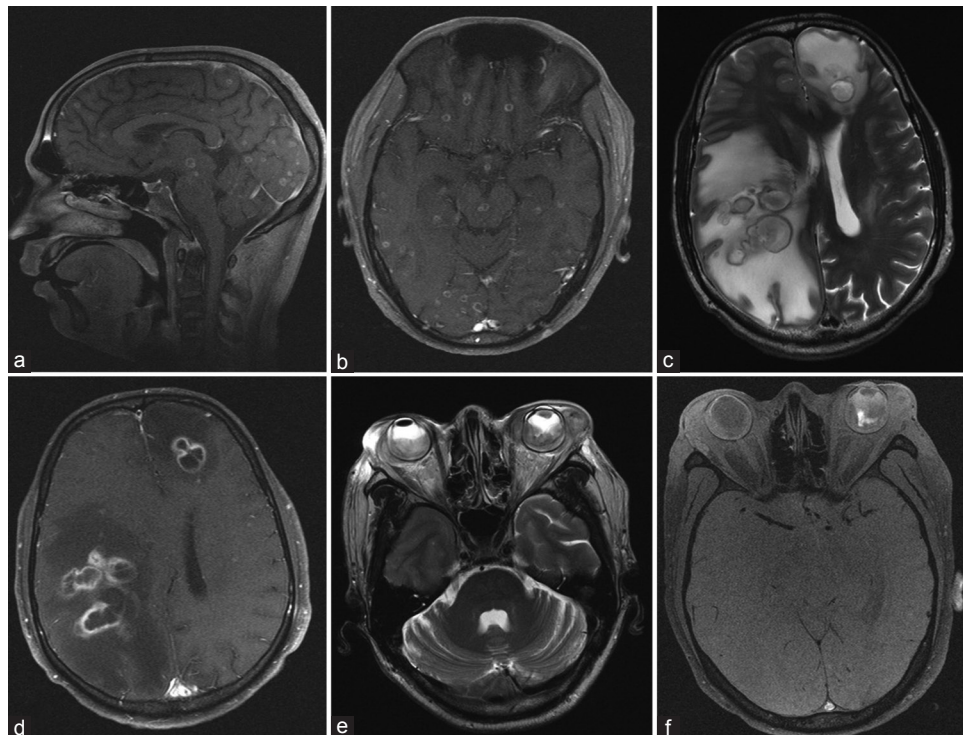


Figure 1. Magnetic resonance images brain and orbit. (a) Sagittal and (b) axial scans showing multiple sub-centimeter discrete ring enhancing lesions scattered in bilateral cerebral hemispheres; (c), T2W axial image after six weeks of initial MRI showing enlarged cerebral lesion with accompanying significant edema and mass effect; (d), with post contrast irregular enhancement; (e), axial orbit sections show the deformed globes with associated inflammatory changes in retro-orbital fat as patchy T2 hyper intensity; (f), T1W image shows the evidence of hemorrhage within the left globe.

considered. Analysis of an aqueous tap via polymerase chain reaction (PCR) was negative for malignant cells, tuberculosis, cytomegalovirus (CMV), herpes simplex virus (HSV), varicella zoster virus (VZV), and toxoplasma.

An Ahmed glaucoma valve was implanted in the left eye subsequent to failure of IOP control with maximum medical therapy. Postoperatively, the left eye was stony hard with severe conjunctival chemosis and a shallow anterior chamber [Figure 2].

Due to suspicion of metastatic endophthalmitis, five weeks after initial presentation, a vitreous biopsy was performed through pars plana vitrectomy. Intravitreal vancomycin (1 mg/0.1 ml), ceftazidime (2.5 mg/0.1 ml), and voriconazole (1 mg/0.1 ml) were instilled at the end of the procedure and the patient was started on fortified cefazolin 5% and tobramycin 1.4% every hour and Natamycin 5% (every six hours) for presumptive fungal endophthalmitis. All tissue sample smears and cultures that were tested for bacterial and fungal organisms were negative.

Subsequently, the patient had no LP along with severe conjunctival chemosis, exposure keratopathy, and conjunctival abscesses. Cerebrospinal fluid was negative for CMV and *Cryptococcus sp.* Blood tests were negative for HIV and TORCH (*Toxoplasma gondii*, other viruses [HIV, measles, and so on), rubella [German measles]), CMV, and herpes simplex. Blood culture showed no evidence of bacterial and fungal organism growth. A bone marrow biopsy was performed to rule out blood cell malignancy but results were normal.

Due to the progressive worsening of patients' systemic status and severe cachexia, a repeat MRI of the brain was done, and revealed a large right parieto-occipital mass lesion [Figure 1c and d]. The orbital region showed bilateral globe deformities, intraocular hemorrhages, and extraocular soft-tissue inflammation [Figure 1e and f].

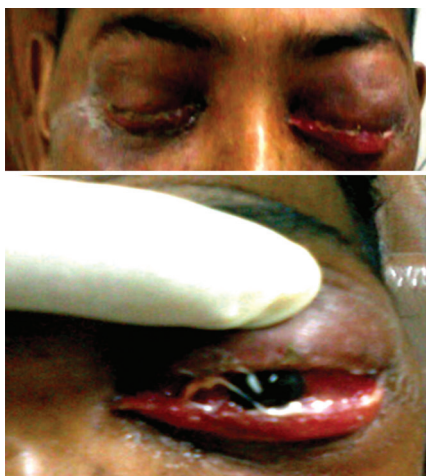

Figure 2. Clinical photographs of the patient after Ahmed glaucoma valve implantation showing severe conjunctival chemosis and mechanical complete ptosis of both eyes.

A multiloculated intracerebral abscess was drained, and a brain biopsy was performed, revealing the presence of the *Nocardia* organism along with granulomatous reactions [Figure 3a-d]. The patient was administered intravenous imipenem for two weeks, amikacin for four weeks, and later, oral cotrimoxazole and trimethoprim. However, the patient had no LP in both eyes despite anti-nocardial treatment, probably because of delayed diagnosis and severity of involvement. Although the patient improved systemically over next two weeks, he subsequently developed phthisis of both eyes.

DISCUSSION

Ocular nocardiosis usually presents with insidious, painless vision loss caused by chorioretinal infiltrates or a mass lesion with overlying hemorrhage in the macular region with mild inflammatory reaction.^[2] Nocardial infections in the eye manifests as keratitis, scleritis, and endophthalmitis. Keratitis and scleritis are mostly associated with exposure to soil and plant matter.^[1] In various case reports and case series, endogenous nocardial endophthalmitis is described in association with immunosuppression therapy^[3] used for cardiac transplants,^[4] renal transplants,^[5] systemic lupus erythematosus,^[6] chronic lymphocytic leukemia,^[7] Behcet's disease,^[8] and glomerulonephritis.^[3]

The current case was unique in the level of difficulty and consequent delay of final diagnosis. There was a six-week delay in reaching the final diagnosis and definitive treatment. The patient recovered well, but unfortunately lost his sight.

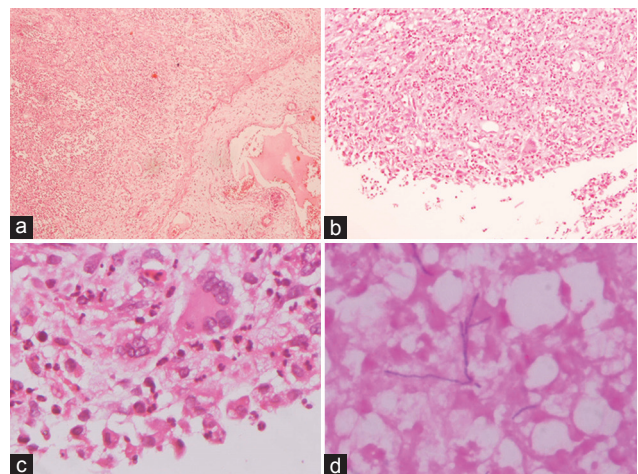


Figure 3. (a) Scanner view of necrotic area (H and E $\times 40$) and high power view (b) (H and E $\times 100$) of the same area showing granulomatous response with giant cells; (c), high power view of the same area showing granulomatous response with multinucleate giant cells (H and E $\times 400$); (d), Gram stain of the same area showing gram positive filamentous hyphae of *Nocardia* (Gram $\times 400$). H and E, hematoxylin and eosin staining.

Endogenous *Nocardia asteroides* endophthalmitis is associated with dismal outcomes, with many cases leading to blindness despite prolonged and aggressive treatment. Currently, amikacin is the drug of choice for treating nocardiosis.^[9,10] *Nocardia* sp. also shows susceptibility to some of the second and third generation cephalosporins. Therapy duration is poorly standardized, but should be prolonged because relapse is common. In immunosuppressed patients, the treatment should be administered for at least one year.^[11] In this case, although the brain abscess responded to the treatment, the ocular lesion continued to demonstrate disease progression.

Endogenous nocardial endophthalmitis is a rare disease that can cause severe patient morbidity and mortality. Successful treatment requires a high index of suspicion, particularly in an immunocompromised patient.

Acknowledgements

Authors wish to express their sincere gratitude and thanks to the Office of Director General Armed Forces Medical Services India (DGAFMS) and Commandant, Army hospital (research and referral, Delhi Cantonment for support for this work).

Financial Support and Sponsorship

Nil.

Conflicts of Interest

There are no conflicts of interest.

REFERENCES

1. DeCroos FC, Garg P, Reddy AK, Sharma A, Krishnaiah S, Mungale M, et al. Optimizing diagnosis and management of *Nocardia* keratitis, scleritis, and endophthalmitis: 11-year microbial and clinical overview. *Ophthalmology* 2011;118:1193-1200.
2. Eschle-Meniconi ME, Guex-Crosier Y, Wolfensberger TJ. Endogenous ocular nocardiosis: An interventional case report with a review of the literature. *Surv Ophthalmol* 2011;56:383-415.
3. Ng EW, Zimmer-Galler IE, Green WR. Endogenous *Nocardia asteroides* endophthalmitis. *Arch Ophthalmol* 2002;120:210-213.
4. Scott M, Mehta S, Rahman HT, Grossniklaus HE, Yeh S. *Nocardia veterana* endogenous endophthalmitis in a cardiac transplant patient. *J Ophthalmic Inflamm Infect* 2013;3:44.
5. Giuliani GP, Sadaka A, Eagle R, Gonzalez VH. Ocular nocardiosis in a renal transplant patient: A warning of life-threatening underlying systemic disease. *Retin Cases Brief Rep* 2012;6:245-248.
6. Yap EY, Fam HB, Leong KP, Buettner H. *Nocardia* choroidal abscess in a patient with systemic lupus erythematosus. *Aust N Z J Ophthalmol* 1998;26:337-338.
7. Phillips WB, Shields CL, Shields JA, Eagle RC Jr, Masciulli L, Yarian DL. *Nocardia* choroidal abscess. *Br J Ophthalmol* 1992;76:694-696.
8. Korkmaz C, Aydinli A, Erol N, Yildirim N, Akgün Y, İnci R, et al. Widespread nocardiosis in two patients with Behçet's disease. *Clin Exp Rheumatol* 2001;19:459-462.
9. Reddy AK, Garg P, Kaur I. Speciation and susceptibility of *Nocardia* isolated from ocular infections. *Clin Microbiol Infect* 2010;16:1168-1171.
10. Lalitha P, Tiwari M, Prajna NV, Gilpin C, Prakash K, Srinivasan M. *Nocardia* keratitis: Species, drug sensitivities, and clinical correlation. *Cornea* 2007;26:255-259.
11. Ambrosioni J, Lew D, Garbino J. Nocardiosis: Updated clinical review and experience at a tertiary center. *Infection* 2010;38:89-97.