

## IN-VIVO ASSESSMENT OF BARBED SUTURING THREAD WITH REGARD TO TISSUE REACTION AND MATERIAL ABSORPTION IN A RAT MODEL

BOGDAN PETRUT<sup>1</sup>, MAXIMILIAM HOGEA<sup>1</sup>, BOGDAN FETICA<sup>1</sup>,  
ANDREI KOZAN<sup>1</sup>, DRAGOS FEFLEA<sup>1</sup>, GABRIEL SERERMAN<sup>1</sup>,  
ALI SERDAR GOEZEN<sup>2</sup>, JENS RASSWEILER<sup>2</sup>

<sup>1</sup>Department of Urology, Oncological Institute Cluj Napoca, Romania

<sup>2</sup>SLK Klinikum Heilbronn, affiliated to the University of Heidelberg, Germany

**Aim.** The laparoscopic approach in urological surgery demands a high degree of skill in intracorporeal suturing and knot tying. In an effort to reduce the amount of time required to perform a suture, new materials have been developed that through self-anchorage distribute tension more evenly across the suture and also eliminate the need of knot tying. The goal of this study was to assess the in vivo tissue response to a novel material (V-Loc tm; Covidien) in comparison to established materials (Vicryl, PDS II), in the case of bladder suturing, in a rat model.

**Methods.** The study included 48 male Wistar rats. All underwent a median abdominal incision, with a 1cm cystotomy, followed by a running suture. The suture material used was either V-Loc absorbable self anchoring thread, Vicryl threaded absorbable suture or monofilament absorbable suture. The abdominal cavity and the bladder suture were macroscopically evaluated at the rats' scheduled death at 3 and 6 weeks. The bladder wall was microscopically assessed by a pathologist, with regard to tissue reaction and suture material degradation.

**Results.** All rats survived the procedure, with the abdominal scar fully healed at week 2. There were no signs of infection or lithiasis during the observation. Macroscopically, at 3 weeks, the suture material was recognizable and visible in all cases, with special mention that the V-Loc thread was considerably more rigid, retaining its shape almost entirely, and provoked more adhesion of the surrounding tissue. At 6 weeks, the suture was indistinguishable in the bladder wall in the case of monofilament absorbable material, barely visible in the case of Vicryl, while the aspect of the V-Loc suture resembled the one at 3 weeks, with the material still clearly visible in the bladder wall, shape almost entirely maintained, and surrounding tissue adherence.

Microscopically, at 3 weeks and 6 weeks, all bladder walls examined had regained their structure. At 3 weeks, the monofilament absorbable suture showed intense tissue reaction, with the material already in phagocytosis; at 6 weeks, no clear evidence of leftover material was observed. At 3 weeks, the Vicryl material showed moderate tissue reaction, with phagocytosis initiated between the strands of the material; at 6 weeks, the material was almost entirely absorbed, but with a clear leftover tissue reaction. In the case of the V-Loc suture, due to the hardness of the thread, the material itself could not be cut for analysis with the bladder wall, and the examination could only involve the bladder wall and marks of the thread. Thus, the tissue reaction was minimal, as was the presence of phagocytes at the suture site. The material showed little, if any, signs of absorption after 6 weeks.

**Conclusion.** The materials tested all proved equally effective in suturing the bladder wall in a rat model. However, the novel barbed thread proved a consistently low in-vivo absorption rate, while maintaining its rigidity over time. More research is needed to assess the possible clinical implications of these findings.

**Keywords:** barbed suture, V-lok suture, wound healing

**Introduction**

Closure of the urinary collective system is an important step in many urologic procedures, and is one of the most technically demanding steps in minimally invasive surgery, be it robotic or laparoscopic. The main challenge is to obtain a watertight closure in an efficient manner, both from the point of view of the procedure time as well as the surgeon's comfort. In an effort to provide a dependable and simple means to achieve such a suture, various materials for closure have been proposed, including barbs for unidirectional advance. The initial use of these materials was in cosmetic surgery, where an evenly tensioned and minimally inflaming suture was needed [1,2], but had been used in other specialties [3]. Following in these footsteps, the suture material was used with success in vitro in urological scenarios [4], as well as in vivo, as described in several studies, in laparoscopic and robotically assisted procedures, ranging from radical prostatectomies [3,4] to nephroraphy following nephron sparing surgery [5]. However, while there have been results published about the effectiveness of these closure devices in operative situations, the histological response is less documented. It is not documented whether or not the design of the material itself might cause more inflammation around the thread because of the increased surface due to the barbs, or subsequent physiological movement postoperatively that may dislodge the thread and

cause more reaction due to uncontrolled advancement. It was decided that a simple animal model might suffice in providing basic clues to answering these questions.

**Materials and Method**

This study was performed on an animal model. After approval from the Ethics board for Animal research, 48 adult male Wistar rats were chosen. These were of approximately equal size and weight. All were examined by a veterinarian before the experiment to certify to their overall health. Under anesthesia (using a Xylazine/Ketamine combination, as per protocol), all animals underwent the same procedure.

In a sterile manner, a lower abdominal incision was performed, the bladder was exposed, emptied, and then a cystotomy was made. The cold incision was 1 cm in length. The bladder wall was then closed using one of the proposed suture materials. The abdomen wall was closed in anatomical layers, using separate sutures. All animals survived the procedure, and no postoperative complications were noted.

The animals were thus randomized according to the material used for cystoraphy into 3 groups: V-loc group (VLG), Vicryl group (VG) and PDS II group (PG), each consisting of 16 rats.

Half of the animals in each group were sacrificed at 3 weeks, and the rest at 6 weeks. The time to death was decided in concordance with previous studies of suture materials

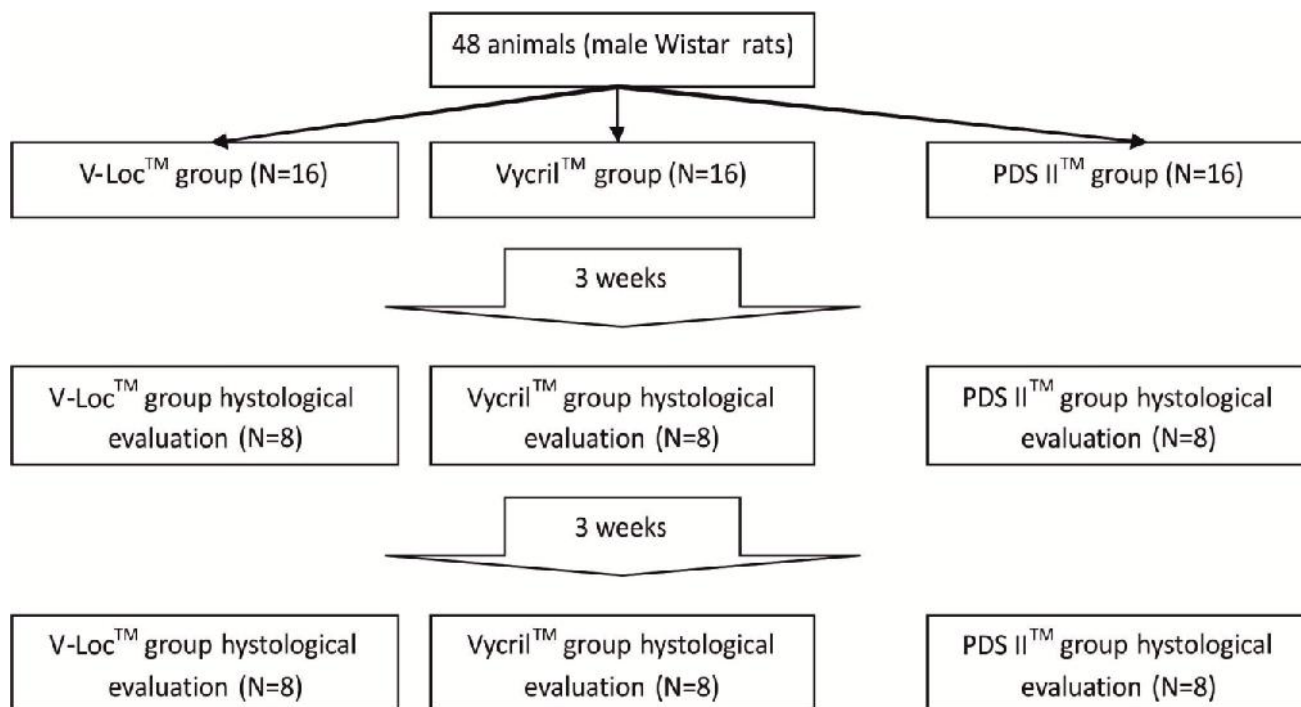



Figure 1. The design of the study.

[6,7,8]. At the scheduled time, the organs were harvested whole, with fixation in formaldehyde, and then processed (hematoxylin – eosin staining).

Notes were gathered during the harvesting procedure regarding the macroscopic aspect of the surgical wounds and suture, as well as subjective observations of the surrounding tissue adherence.

The samples were microscopically analyzed by the same pathologist (Dr B.F.). Foreign body tissue reaction and inflammation were each given a score in each examined case. A scale from 1 through 10 was used, with 1 for absence of tissue reaction, no inflammation, and 10 being very intense reaction, with macrophage cells present in the entirety of the microscopic field at 40x magnification. The degree of thread dissolution was also evaluated, with a percentage given where possible to the amount of material that was not yet absorbed. The results were compared among groups using a Student's t-test (significance set at  $p < 0.05$ ).

Suture material: the V-Loc 180 barbed suture was used. The 3-0 thread is made of an absorbable mixture of a copolymer of glycolic acid and trimethylene carbonate; it comes equipped with a surgical needle at one end and a loop at the other, designed to quickly secure the first suture point. The commercial data available suggest a tensile strength of the suture of 80% after 7 days, 65% after 21 days, and full absorption after 180 days. The unidirectional barbs are spaced at 0.025 inches (40 barbs per inch). These prevent suture slippage and evenly distribute closure forces so that tearing and ischemic changes in the suture live are avoided.



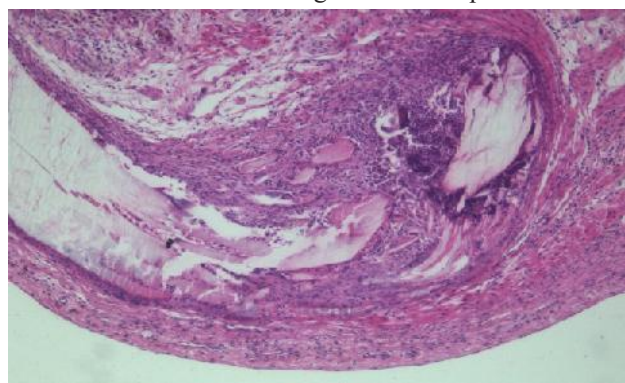
**Figure 2.** Example of V-Loc thread showing barbs that are unidirectional

The other suture materials used were Vicryl™ (Ethicon). Made of polyglactin 910 this 3-0, coated, braided suture is used for soft tissue approximation. The third type of material was PDS II™ (Ethicon). Also 3-0, but fabricated from polydioxanone, this monofilament long lasting absorbable suture is also used for soft tissue approximation, and is the preferred material for vesico-urethral anastomosis following radical prostatectomies.

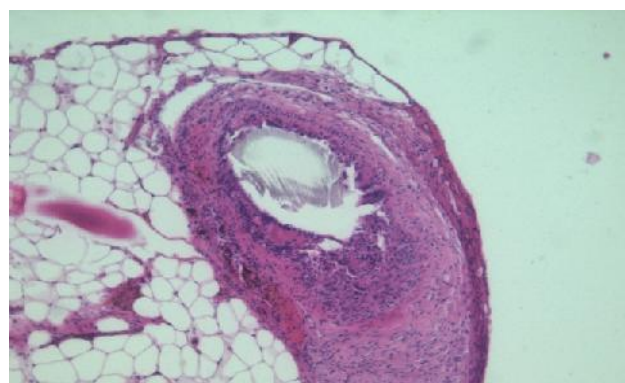
## Results

There was no significant difference between the mean weights of the animals in each group (mean weight 253.2g,

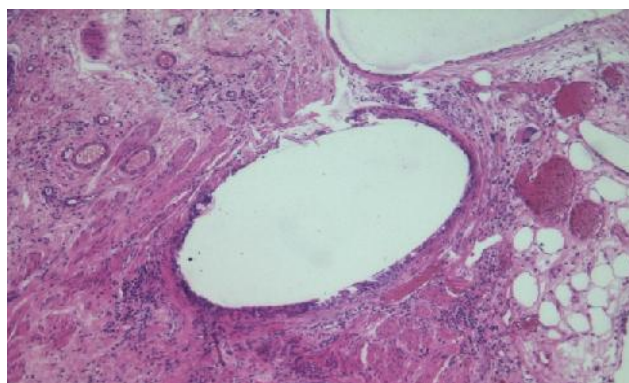
SD 32.1g). Tissue reactions were evaluated by the same pathologist (B.F.) At 3 weeks each group had the following characteristics: during organ harvest, while the abdominal wall was completely healed in all cases, a difference in bladder suture aspect was noted. In the PG rats, the suture was supple, with the thread nimble and no adjacent adherence. The VG rats' suture was similar in appearance, with the difference of a more notable maintained strength of the thread. The sutures in the VLG rats showed significant adjacent tissue reaction, with adherence to the abdominal wall in some cases. The V-Loc thread was also more rigid than all others and maintaining the initial shape.



**Fig. 3A**



**Fig. 3B**



**Fig. 3C**

**Figure 3.** Histopathological view of tissue reaction at 3 weeks (40x magnification): A. PDS thread; B. Vicryl thread; C. V-Loc thread



Microscopically:

Vicryl group – foreign body reaction to the thread was moderate, with macrophage reaction present around the material. The absorption process was limited to the periphery. The bladder wall's structure was regained.

PDS group – very intense reaction to the thread material, with many macrophages present at the suture site. Absorption of the material was more advanced, with an average estimated loss of material of ~20%. The structure of the bladder wall was recovered completely.

V-Loc group – minimal granulomatous reaction, very rare macrophages around the suture site. No sign of absorption of the material. The bladder wall was of recovered structure. To note, the thread was not present on the inspected samples, as it could not be sectioned during the preparation process.

The average scores for tissue reaction, inflammation and material absorption at 3 weeks are presented in table 1.

Unpaired t-test calculated for the groups showed a p value of clinical significance ( $p < 0.01$ ).

At 6 weeks the following were observed:

Macroscopically, all abdominal incisions were fully healed. The harvested organs showed similar reactions to the material as was noted at 3 weeks, with the mention that in the VLG rats, while the rigidity of the thread was maintained, the adherence to the surrounding tissue was reduced (but still present).

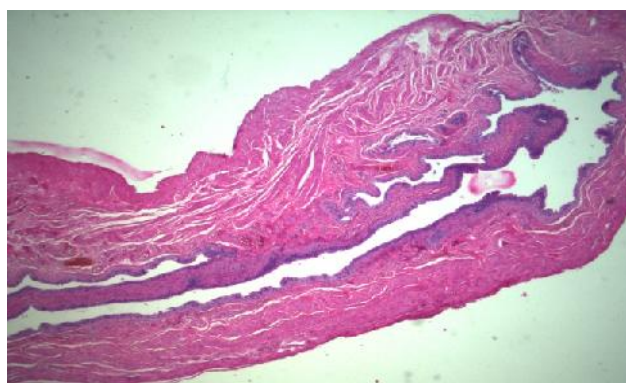Microscopically:

Vicryl group – foreign body reaction to the thread is intense, with macrophage reaction present around the material, as well as between the individual filaments. The absorption process is thus extended in the whole of the material, evaluated loss of substance in the thread of ~75%. The bladder wall structure was normal.

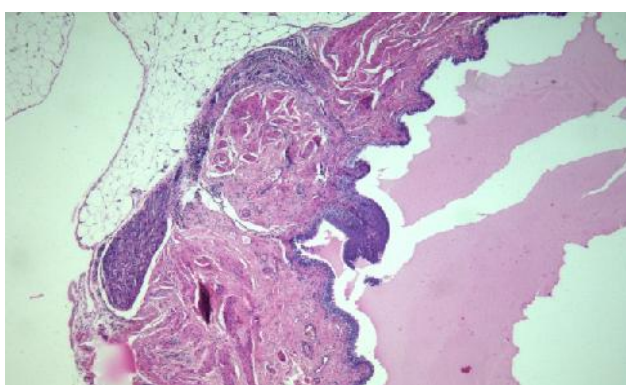
PDS group – The bladder walls showed little sign of previous trauma except moderate fibrosis at the suture site. There was no clear evidence of leftover foreign material in the samples examined

V-Loc group – The bladder walls' structure was normal. Again, the thread was not present in the observed samples due to the maintained toughness of the material that stayed on the unsectioned blocks. The macrophage reaction was limited to the periphery of the material, and there were scarce signs of loss of substance.

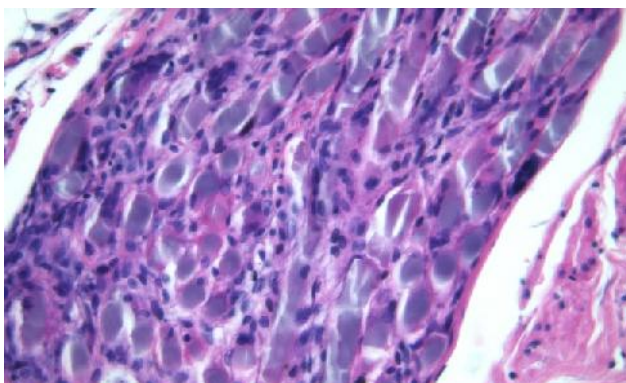
These aspects can be observed in figure 4, 5 and 6.



**Figure 4.** Histopathological view of tissue reaction at 6 weeks (25x magnification) in the PDS thread; the bladder wall with structure recovered completely and minimal fibrosis



**Fig. 5A**



**Fig. 5B**

**Figure 5.** Histopathological view of tissue reaction at 6 weeks in the Vicryl group. A. 25x magnification; B. 40x magnification – thread material can be seen between individual macrophages

**Table 1.** Scores for tissue reaction, inflammation and material dissolution at 3 weeks

	PG	VG	VLG
Tissue reaction	5.12 (SD 0.64)	3.00 (SD 0.53)	2.25 (SD 0.463)
Inflammation	6.38 (SD 1.06)	3 (SD 0.5)	2.12 (SD 0.99)
Material absorption	24.5% (SD 12.1%)	11.2% (SD 6.41%)	N/A

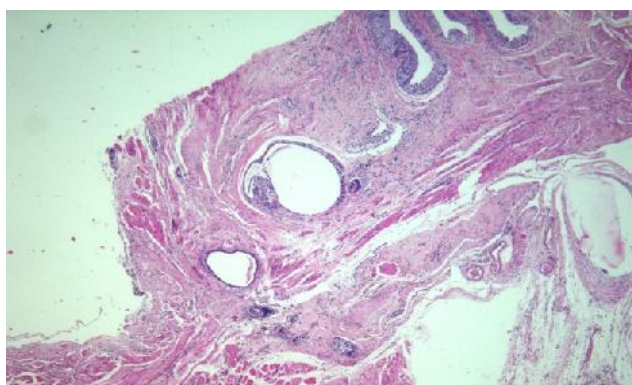


Fig. 6A

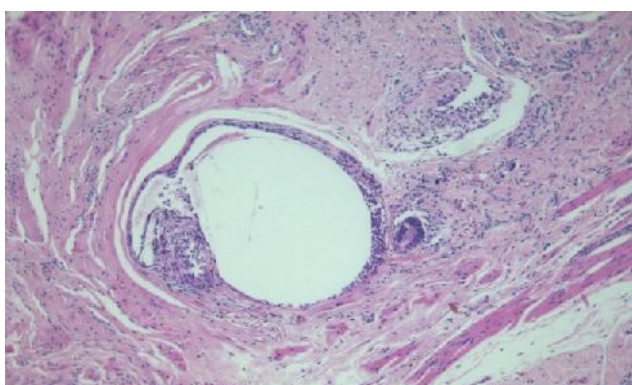


Fig. 6B

Figure 6. Histopathological view of tissue reaction at 6 weeks in the V-Loc group. A. 25x magnification; B. 40x magnification

The average scores for tissue reaction, inflammation and material absorption at 6 weeks are presented in table 2.

P value was clinically significant ( $p < 0.03$ ).

There were no instances of urolithiasis in the cases observed.

### Discussion

The popularity of minimally invasive techniques is increasing, and the efficacy of these approaches is at least equal to the open one in relation to both functional and oncological outcomes [9,10], in spite of their increased respective costs [11]. But while the debate about the best surgical technique continues, medical companies are putting forward novel devices designed to further improve and facilitate the minimally invasive approach. As such, barbed suture threads were created to allow soft tissue

approximation with evenly distributed tension and less foreign body reaction, which is thought to lead to better wound healing [12]. Whether or not this is a cost effective approach is also discussed in literature, with questions raised whether the barbed thread is worth the extra cost and care necessary during suture manipulation [13].

Previous studies comparing various suture materials [7,13] have proved that polydioxanone (PDS), chromic catgut and polyglactin are all equally effective in sutures of the bladder, with similar absorption rates between polyglactin and PDS. However, there were differences in absorption time, as the barbed suture maintained its strength while the other absorbable materials lost theirs. This was also noted subjectively in our tests, including the fact that the thread was strong enough to resist the blade of the microtome during histological preparation. However, it would be interesting to see whether or not this maintained rigidity has any impact clinically.

There is evidence that maintenance of suture material in place, as in penetrating suture material, at the site of a vesico-urethral anastomosis might be the cause of irreversible urinary incontinence [14], and there are some voices advocating early endoscopic removal of the material in such selected cases. Also to note, this persistence of material might increase the potential for early extravasation of urine following an anastomosis using barbed threads [15].

With little information available on the histological reaction to barbed sutures in urology, we had to look to other specialties for reference. Studies performed by plastic surgery specialists [1,2], as well as general surgery and gynecology [16], have shown the V-loc suture to be consistently the lowest scoring in regard to tissue reaction. Our results support this finding, as in all sutures with the barbed thread the tissue response had the least inflammatory response, and least number of macrophages located near the suture site. It is interesting to note that the suture material had kept its strength after 6 weeks, and it could not be evaluated for absorption rate. We suppose that the loss of material was thus minimal.

Regarding the urolithiasis genesis potential, previous studies [17,18] have shown similar stone incidence regardless of suture material. Our results are consistent with these results, as in our group there was no instance of stone formation.

While not the direct object of this investigation, we

**Table 2.** Scores for tissue reaction, inflammation and material dissolution at 6 weeks

	PG	VG	VLG
Tissue reaction	1.25 (SD 0.46)	7.62 (SD 1.06)	1.38 (SD 0.51)
Inflammation	1.5 (SD 0.53)	8 (SD 0.92)	2.38 (SD 1.51)
Material absorption	87.5% (SD 7.07%)	77.5% (SD 9.64%)	N/A



noted no cases of urinary infection regardless of the suture material used. There were no cases of other non-urological complications either.

There are limitations to our study. Lacking proper tools, the exact tensile strength of the suture material at harvest was not measured. Also, the experiment might have benefited from a longer observation period to allow the suture material, especially the V-Loc thread, to be fully observed. We are currently looking into extending the observation time to 9 and 12 weeks, and using the newer, more absorbable V-Loc 90 in the comparison.

### **Conclusion**

All the suturing materials tested proved equally effective at closing the bladder wall in a rat model. The V-loc barbed suture device showed consistently low inflammation and tissue reaction scores.

However, the barbed suture had a relatively low in-vivo dissolution rate, while maintaining its rigidity over time.

More research is needed to assess the possible clinical implications of these findings.

### **References**

1. Warner JP, Gutowski KA. Abdominoplasty with progressive tension closure using a barbed suture technique. *Aesthet Surg J*, 2009; 29(3):221-225.
2. Murtha AP, Kaplan AL, Paglia MJ, Mills BB, Feldstein ML, Ruff GL. Evaluation of a novel technique for wound closure using a barbed suture. *Plast Reconstr Surg*, 2006; 117(6):1769-1780.
3. Trocchia A. M., Aho H. N., Sobol G., A re-exploration of the use of barbed sutures in flexor tendon repairs. *Orthopedics*. In press. doi:10.3928/01477447-20090818-12
4. Trocchia AM, Aho HN, Sobol G. A re-exploration of the use of barbed sutures in flexor tendon repairs. *Orthopedics*. 2009;32(10):731. doi: 10.3928/01477447-20090818-12.
5. Gözen AS, Arslan M, Schulze M, Rassweiler J. Comparison of Laparoscopic Closure of the Bladder with Barbed Polyglyconate Versus Polyglactin Suture Material in the Pig Bladder Model: An Experimental In Vitro Study. *J Endourol*, 2012; 26(6):732-736.
6. Sammon J, Petros F, Sukumar S, Bhandari A, Kaul S, Menon M, Rogers C. Barbed suture for renorrhaphy during robot-assisted partial nephrectomy. *J Endourol*, 2011; 25(3):529-533.
7. Kosan M, Gonulalan U, Ozturk B, Kulacoglu S, Erguder I, Akdemir O, Cetinkaya M. Tissue reactions of suture materials (polyglactine 910, chromed catgut and polydioxanone) on rat bladder wall and their role in bladder stone formation. *Urol Res*, 2008; 36(1):43-49.
8. Osterhage HR, Grün BR, Judmann G, Wünsch HP. Experimental

comparison of Maxon and chromic catgut in suturing of the urinary bladder. *Urologe A*, 1988; 27(1):61-67.

9. Stewart DW, Buffington PJ, Wacksman J. Suture material in bladder surgery: a comparison of polydioxanone, polyglactin, and chromic catgut. *J Urol*, 1990; 143(6):1261-1263.

10. Tewari A. K., Sooriakumaran P., Bloch A. D., Usha Seshadri-Kreaden, Hebert A. E., Wiklund P. Positive Surgical Margin and Perioperative Complication Rates of Primary Surgical Treatments for Prostate Cancer: A Systematic Review and Meta-Analysis Comparing Retropubic, Laparoscopic, and Robotic Prostatectomy. *Eur Urol*, 2012; 62(1): 1-15.

11. Magheli A, Gonzalgo ML, Su LM, et al. Impact of surgical technique (open vs laparoscopic vs robotic-assisted) on pathological and biochemical outcomes following radical prostatectomy: an analysis using propensity score matching. *BJU Int*, 2011; 107(12):1956-1962. doi: 10.1111/j.1464-410X.2010.09795.x. Epub 2010 Nov 2.

12. Bolenz C, Gupta A, Hotze T, et al. Cost Comparison of Robotic, Laparoscopic, and Open Radical Prostatectomy for Prostate Cancer. *Eur Urol*, 2010; 57(3):453-458.

13. Ruff G. Technique and uses for absorbable barbed sutures. *Aesthet Surg J*, 2006; 26(5):620-628.

14. Williams SB, Alemozaffar M, Lei Y, Hevelone N, Lipsitz SR, Plaster BA, Hu JC. Randomized controlled trial of barbed polyglyconate versus polyglactin suture for robot-assisted laparoscopic prostatectomy anastomosis: technique and outcomes. *Eur Urol*, 2010; 58(6):875-881. doi: 10.1016/j.eururo.2010.07.021.

15. Gerullis H, Georgas E, Quast S, et al. Early endoscopic detection and subsequent removal of sphincter penetrating anastomotic sutures may prevent irreversible urinary incontinence after radical prostatectomy. *J Endourol*. 2012 Jul;26(7):889-94. doi: 10.1089/end.2011.0643.

16. Zorn KC, Widmer H, Lattouf JB et al. Novel method of knotless vesicourethral anastomosis during robot-assisted radical prostatectomy: feasibility study and early outcomes in 30 patients using the interlocked barbed unidirectional V-LOC180 suture. *Can Urol Assoc J*, 2011; 5(3):188-194.

17. Zaruby J, Gingras K, Taylor J, Maul D. An In Vivo Comparison of Barbed Suture Devices and Conventional Monofilament Sutures for Cosmetic Skin Closure Biomechanical Wound Strength and Histology. *Aesthet Surg J*, 2011; 31(2):232-240, doi:10.1177/1090820X10395010.

18. Hanke PR, Timm P, Falk G, Kramer W. Behavior of different suture materials in the urinary bladder of the rabbit with special reference to wound healing, epithelization and crystallization. *Urol Int*, 1994; 52(1):26-33.

19. Tewari AK, Srivastava A, Sooriakumaran P, Slevin A, Grover S, Waldman O., Rajan S., Herman M., Berryhill R., Leung R. Jr., Use of a Novel Absorbable Barbed Plastic Surgical Suture Enables a "Self-Cinching" Technique of Vesicourethral Anastomosis During Robot-Assisted Prostatectomy and Improves Anastomotic Times. *J Endourol*, 2010; 24(10):1645-1650. doi:10.1089/end.2010.0316.