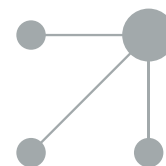




Since January 2020 Elsevier has created a COVID-19 resource centre with free information in English and Mandarin on the novel coronavirus COVID-19. The COVID-19 resource centre is hosted on Elsevier Connect, the company's public news and information website.

Elsevier hereby grants permission to make all its COVID-19-related research that is available on the COVID-19 resource centre - including this research content - immediately available in PubMed Central and other publicly funded repositories, such as the WHO COVID database with rights for unrestricted research re-use and analyses in any form or by any means with acknowledgement of the original source. These permissions are granted for free by Elsevier for as long as the COVID-19 resource centre remains active.



BRIEF REPORT

Extreme reactive thrombocytosis in a healthy 6 year-old child[☆]



G. de Lama Caro-Patón^a, A. García-Salido^{a,b,*}, M.I. Iglesias-Bouzas^a, M. Guillén^c,
E. Cañedo-Villaroya^c, I. Martínez-Romera^d, A. Serrano-González^a, J. Casado-Flores^a

^a Unidad de Cuidados Intensivos Pediátricos, Hospital Infantil Universitario Niño Jesús, Madrid, Spain

^b Unidad de Cuidados Paliativos Pediátricos, Hospital Infantil Universitario Niño Jesús, Madrid, Spain

^c Unidad de Pediatría, Hospital Infantil Universitario Niño Jesús, Madrid, Spain

^d Unidad de Oncohematología Pediátrica, Hospital Infantil Universitario Niño Jesús, Madrid, Spain

Received 27 August 2013; accepted 7 October 2013

Available online 25 October 2014

KEYWORDS

Paediatrics;
Critical care;
Pneumonia;
Thrombocytosis;
Thrombosis

PALABRAS CLAVE

Pediatría;
Cuidados intensivos;
Neumonía;
Trombocitosis;
Trombosis

Abstract Thrombocytosis is usually found by chance in children. Reactive or secondary thrombocytosis is the more common form, with infectious diseases being the most prevalent cause of it. Regarding the number of platelets there are four degrees of thrombocytosis; in its extreme degree the number of platelets exceeds 1,000,000/mm³. We describe a case of extreme reactive thrombocytosis in a healthy 6-year-old child. He required critical care admission for diagnosis and treatment (maximum number of platelets 7,283,000/mm³). We review the different causes of thrombocytosis in childhood, the differential diagnosis, and the available treatments in case of extreme thrombocytosis.

© 2013 Asociación Española de Pediatría. Published by Elsevier España, S.L.U. All rights reserved.

Trombocitosis extrema reactiva en un niño sano de 6 años

Resumen La trombocitosis es un hallazgo casual frecuente en pediatría. En niños, predominan las formas secundarias, siendo las infecciones su causa más prevalente. Se distinguen 4 grados de trombocitosis en función del número de plaquetas; en la forma extrema, se supera el 1.000.000/mm³. Se presenta un caso de trombocitosis extrema reactiva en un niño sano de 6 años, que requirió ingreso en cuidados intensivos para tratamiento y diagnóstico (cifra máxima

[☆] Please cite this article as: de Lama Caro-Patón G, García-Salido A, Iglesias-Bouzas MI, Guillén M, Cañedo-Villaroya E, Martínez-Romera I, et al. Trombocitosis extrema reactiva en un niño sano de 6 años. An Pediatr (Barc). 2014;81:318–321.

* Corresponding author.

E-mail address: citopenis@yahoo.es (A. García-Salido).

de plaquetas de 7.283.000/mm³). Se revisan las diferentes causas de trombocitosis en la infancia, se describe el diagnóstico diferencial y se discute sobre los diferentes tratamientos disponibles ante un caso como el descrito.

© 2013 Asociación Española de Pediatría. Publicado por Elsevier España, S.L.U. Todos los derechos reservados.

Introduction

Thrombocytosis is defined as a platelet count of more than two standard deviations higher than the upper limit of normal values ($0.5 \times 10^9/L$).^{1,2} It is frequently found by chance in paediatrics. We present a case of extreme thrombocytosis in a healthy child. We describe the treatment, the differential diagnosis and the complications that occurred during its evolution.

Case study

Admission to hospital: A 6-year-old boy attended the emergency department with fever for 12 days, cough, pain in the left side and asthenia. He had no personal or family history of interest. His general condition was fair, with oxygen saturation at 92–93%, tachypnea and left basal hypoventilation. Oxygen therapy was initiated through nasal cannula and the following were requested: (a) complete blood count (CBC): haemoglobin 9.1 g/dL, white blood cells 32,850/mm³ (70% neutrophils) and platelets 5,301,000/mm³; (b) coagulation test: normal; (c) biochemistry: normal with C-reactive protein 9.1 mg/dL and procalcitonin 0.36 ng/mL; (d) chest X-ray: left basilar infiltrate and small associated effusion, and (e) blood culture.

With a presumptive diagnosis of pneumonia, he was admitted with oxygen therapy and intravenous treatment with amoxicillin/clavulanic acid (100 mg/kg/day). The thrombocytosis was confirmed and considered to be possibly reactive.

Second day of hospitalisation: owing to an increase in pleural effusion, the patient was transferred. At the receiving hospital, following another chest scan, a watchful waiting approach was maintained, replacing the amoxicillin/clavulanic acid with intravenous cefotaxime (200 mg/kg/day). In addition, a new CBC was performed and increased thrombocytosis was observed. The haematology service was consulted and recommended carrying out further diagnostic tests, which were normal: (a) red blood cell morphology; (b) coagulation study with protein C and antithrombin III; (c) autoimmunity: antinuclear antibodies, antineutrophil cytoplasmic antibodies and perinuclear antineutrophil antibodies, rheumatoid factor, serum immunoglobulins, immune reconstitution, and (d) paraneoplastic phenomena: alpha-foetoprotein and chorionic gonadotropin.

Third day of hospitalisation: in a further ultrasound scan a new consolidation with pleural effusion was found in the right lung base. It was decided not to modify the treatment and to wait to see how the patient evolved.

Fifth day of hospitalisation: the patient had headache, more severe abdominal pain, a worsening of the right pleural effusion and increasing thrombocytosis. Treatment with aspirin (5 mg/kg/day) was initiated, since the headache and abdominal pain were considered to be vasomotor phenomena. Clarithromycin (10 mg/kg/day) was added to treat atypical pathogens. Further supplementary tests were also performed, and these too were negative: (a) blood tests for *Chlamydomphila pneumoniae*, *Chlamydomphila psittaci*, *Chlamydia trachomatis*, *Coxiella burnetii*, influenza A virus and influenza virus; (b) polymerase chain reaction (PCR) for adenovirus, *Mycoplasma pneumoniae* and respiratory syncytial virus; (c) *Francisella tularensis* antibodies, *Legionella pneumophila* serogroup 1, immunoglobulin M (IgM) for *Legionella pneumophila* serogroup 1 and cytomegalovirus; (d) stool culture for adenovirus, rotavirus and faecal parasites; (e) hidden blood in stool, faecal calprotectin; (f) echocardiogram; (g) cranial computed tomography (CT) (normal), and (h) chest and abdomen CT (pleural effusion and consolidation without associated masses).

Sixth day of hospitalisation: the effusion was drained, yielding 820 mL of exuded pleural fluid. An adenosine deaminase not indicative of tuberculosis was detected, the pneumococcal capsular antigen assay (BinaxNOW[®]) was negative, with no microorganisms in the Gram stain and negative Zielh-Neelsen stain. The pleural fluid analysis also included a culture of mycobacteria, fungi and bacteria, PCR for mycobacteria and an anatomical pathology examination.

At the same time as the pleural drainage, suction and biopsy of bone marrow were carried out together with flexible fibre optic bronchoscopy and bronchoalveolar lavage. In the bone marrow analysis a culture of mycobacteria, fungi and bacteria was requested together with PCR for cytomegalovirus and Epstein–Barr virus, in addition to JAK II and BCR-ABL hybrid genetic testing. The bronchoalveolar lavage analysis included an anatomical pathology study and a culture of mycobacteria, fungi and bacteria, immune reconstitution, PCR for enterovirus, rhinovirus, coronavirus, parainfluenza virus and influenza A, B and C viruses. All these tests were normal or negative.

Seventh and eighth days of hospitalisation: the pleural effusion, the fever and the abdominal pain decreased and the laboratory values normalised.

Ninth day of hospitalisation: in the laboratory tests performed before removing the drainage an increased platelet count was confirmed (7,283,000/mm³). It was decided to carry out a platelet apheresis to avoid a possible thrombosis. The right femoral vein was cannulated for this purpose and the platelet count was successfully reduced (2,252,000/mm³).

Tenth day of hospitalisation: the patient had oedema of the right lower extremity. Partial thrombosis of the right external iliac vein was detected and low molecular weight heparin (LMWH) was started (20 mg/12 h).

Twelfth day of hospitalisation up to discharge: the patient remained free of fever, headache, and abdominal pain. He showed a gradual reduction in platelet numbers and blood flow in the thrombosed area normalised. After 22 days he was discharged on treatment with aspirin (5 mg/kg/day) and a prophylactic dose of LMWH. All the tests performed were negative or normal. A primary cause of thrombocytosis was ruled out, and it was considered to be related to the respiratory infection, with no aetiological diagnosis, which caused his hospitalisation.

He is currently in follow-up with the haematology service and his platelet count is normal without treatment.

Discussion

A chance finding of thrombocytosis is common in paediatrics. It must always be confirmed with a further CBC, since there are situations that can give rise to a false increase in platelet count (mixed cryoglobulinaemia or cellular lysis).^{1,4,5}

Four degrees of thrombocytosis have been described: mild (500,000–700,000/mm³), moderate (700,000–900,000/mm³), severe (>900,000/mm³) and extreme or massive (>1,000,000/mm³).^{2,6} The aim must be to stabilise and treat the patient so as to determine subsequently whether the thrombocytosis is secondary

Table 1 Causes of secondary thrombocytosis in paediatrics in order of prevalence.

Infections	Infections of respiratory origin are the most common cause of thrombocytosis, followed by gastrointestinal and genitourinary infections Some degree of thrombocytosis in up to 48% of cases
Anaemias	Haemolytic anaemia Ferropenic anaemia Acute or chronic bleeding
Inflammatory diseases of non-infectious origin	Autoimmune diseases Kawasaki disease
Haematopoietic disease	Chronic myeloid leukaemia, polycythaemia vera, primary myelofibrosis, myelodysplastic syndromes, acute myeloid leukaemia, essential thrombocythemia
Miscellaneous	Asplenia Neoplasms Stress-induced catabolism Treatment with corticoids, vinca alkaloids, all-trans retinoic acid, meropenem, imipenem and zidovudine Noonan syndrome

Table 2 Data of interest in the medical history of patients with thrombocytosis.

Recent surgery or trauma
Absence of spleen
Signs or symptoms suggestive of infection or inflammation
Current or past history of bleeding, thrombosis or iron deficiency
Previous diagnosis of a chronic haematological disorder
Weight loss, tiredness, asthenia, anorexia or signs or symptoms suggestive of malignancy
Use of medications

(Table 1) or whether it is primary or clonal. In this respect, directed history taking (Table 2), proper interpretation of the diagnostic tests (Table 3) and a thorough physical examination (ruling out the presence of visceromegaly or adenopathy), as soon as the patient is admitted, help to guide the diagnosis.^{1,3,4}

The differential diagnosis must be made step-by-step, based on the patient's signs and symptoms.³ The diagnostic tests indicated will be those that provide useful information with an appropriate risk–benefit ratio. Bearing in mind the most prevalent causes of thrombocytosis in childhood, the following tests could be considered: (a) sterile body fluid cultures, blood tests and molecular biology techniques

Table 3 Interpretation of diagnostic tests in the emergency department.

	Assess...	Related to...
White blood cells	Leukocytosis Neutrophilia	Inflammatory or infectious processes
Acute phase reactants	C-reactive protein and procalcitonin Globular sedimentation velocity Fibrinogen	Generally normal in primary thrombocytosis
Ferritin	Iron deficiency	Anaemia as a cause of thrombocytosis May be high as an acute phase reactant
Blood biochemistry	Lactate dehydrogenase Uric acid Potassium	Rule out increase; related to cell rupture through hypercytosis
Blood smear	Nuclear fragments (Howell-Jolly bodies) Target cells Typical deformed red blood cells	Spleen disorder

Table 4 Complications and treatment of thrombocytosis.

Complication	Treatment
Vasomotor phenomena	Aspirin in non-anti-aggregating doses
Bleeding	Suspend aggregation inhibitors (aspirin or non-steroidal anti-inflammatory drugs) Rule out platelet consumption disorders (disseminated intravascular coagulation) or deficiency of coagulation factors Type II or acquired von Willebrand disease: reduction of platelet count through apheresis and initiation of a platelet cytoréductive agent
Thrombosis	Platelet apheresis if count is 800,000 platelets/mm ³ or more In primary causes: treatment with hydroxyurea to maintain platelet count below 400,000 platelets/mm ³ Rule out other risk factors for thrombosis Anticoagulant treatment with low molecular weight heparin for three months in the absence of thrombophilia and for six months or more otherwise

for viruses, bacteria and parasites; (b) rule out anaemia, of any cause, alterations in red blood cell morphology and blood clotting disorders; (c) consider autoimmune diseases; (d) perform imaging tests aimed at ruling out neoplasms, visceromegaly, adenopathy and Kawasaki disease (echocardiogram), and (e) assess the need to carry out suction and biopsy of bone marrow.^{1-4,6}

Most patients will remain asymptomatic. Regardless of the cause of thrombocytosis, a high platelet count can be associated with vasomotor phenomena (headache, visual symptoms, nausea, chest pain, dysaesthesia, aphasia, dysarthria, vertigo, instability, shivering or erythromelalgia), thrombotic phenomena or haemorrhagic complications (Table 4).^{1,5} The vasomotor phenomena arise from intravascular platelet activation. Normally, reactive thrombocytosis does not entail a greater risk of thromboembolic events or haemorrhagic complications.⁷ On the other hand, in primary forms, this activation is symptomatic in up to 25–40% of patients.^{2,5} In our patient, the episodes of headache and abdominal pain may have been related to the extreme thrombocytosis.

Starting any treatment is controversial. Aspirin seems to be the most suitable drug. It suppresses thromboxane

A2 production, lessening platelet activation but without reducing the risk of thrombosis. Nor is it clear that a prophylactic anticoagulant (LMWH) is indicated, even with extreme thrombocytosis counts in asymptomatic children.^{1,2,6} Initiating it must be considered on an individual basis in patients with other associated prothrombotic factors, such as thalassaemia, reduction in protein C or antithrombin III or the presence of a central venous catheter.¹ Cytoréductive therapy of any kind (drugs or platelet apheresis) is not recommended in patients with a low risk of thrombosis, but can be considered when the symptoms prove refractory despite appropriate treatment (Table 3).^{1,3} In our case, aspirin treatment produced a modest improvement in the patient's clinical condition, and platelet apheresis, given the large number of platelets and their state of activation, could have given rise to thrombosis of the external iliac vein.

To sum up, we here present a case of massive thrombocytosis secondary to a probable respiratory infection.⁶ The aim must be to treat the underlying infection and rule out a primary cause of thrombocytosis.^{3,4,7} Apart from antimicrobial drugs, the treatment will essentially consist of supportive measures. The appearance of vasomotor phenomena must be monitored to initiate aspirin treatment. In the event of complications such as bleeding or thrombosis, acute platelet apheresis will be carried out in order to achieve rapid platelet reduction.¹

Conflicts of interest

The authors have no conflicts of interest to declare.

References

- Chiarello P, Magnolia M, Rubino M, Liguori SA, Miniero R. Thrombocytosis in children. *Minerva Pediatr.* 2011;63:507–13.
- Yadav D, Chandra J, Sharma S, Singh V. Clinicohematological study of thrombocytosis. *Indian J Pediatr.* 2010;77:643–7.
- Cecinati V, Brescia L, Esposito S. Thrombocytosis and infections in childhood. *Pediatr Infect Dis J.* 2012;31:80–1.
- Haidopoulou K, Goutaki M, Lemonaki M, Kavga M, Papa A. Reactive thrombocytosis in children with viral respiratory tract infections. *Minerva Pediatr.* 2011;63:257–62.
- Indolfi G, Catania P, Bartolini E, Azzari C, Massai C, Poggi GM, et al. Incidence and clinical significance of reactive thrombocytosis in children aged 1 to 24 months, hospitalized for community-acquired infections. *Platelets.* 2008;19:409–14.
- Wiwantkit V. Extreme thrombocytosis: what are the etiologies? Clinical and applied thrombosis/hemostasis. *Clin Appl Thromb/Hemost.* 2006;12:85–7.
- Wang JL, Huang LT, Wu KH, Lin HW, Ho MY, Liu HE. Associations of reactive thrombocytosis with clinical characteristics in pediatric diseases. *Pediatr Neonatol.* 2011;52:261–6.