

Case report

<https://doi.org/10.6065/apem.2142002.001>
Ann Pediatr Endocrinol Metab 2022;27:69-72



Hyperosmolar hyperglycemic state as the first manifestation of type 1 diabetes mellitus in an adolescent male: a case report

Sang Hoon Chun,
Hae Sang Lee,
Jin Soon Hwang

Department of Pediatrics, Ajou University Hospital, Ajou University School of Medicine, Suwon, Korea

A hyperosmolar hyperglycemic state (HHS) is a life-threatening complication rarely seen in children and adolescents with type 1 diabetes mellitus (T1DM). However, early diagnosis and proper treatment are vital to reduce the high morbidity and mortality rates associated with HHS. We describe a male patient who presented with polydipsia, polyuria, and a drowsy mental status. His initial biochemistry results demonstrated severe hyperglycemia (1,456 mg/dL), hyperosmolarity of 359 mOsm/kg (effective osmolarity, 323 mOsm/kg), and mild acidosis (venous pH, 7.327). The patient was diagnosed with HHS and T1DM based on the presence of hyperosmolarity, hyperglycemia, and positivity for antiglutamic acid antibodies. Intensive intravenous fluid and regular insulin (0.025 units/kg/hr) were administered. After hydration and insulin treatment, the patient's mental status and serum glucose and sodium levels improved, and no neurological complications were observed. In summary, most cases of HHS are observed in adult patients with type 2 diabetes. However, occurrences in children and adolescents with T1DM have also been reported. Therefore, HHS should be considered in the differential diagnosis of hyperglycemic emergencies.

Keywords: Hyperosmolar hyperglycemic state, Type 1 diabetes mellitus, Insulin

Highlights

- Early diagnosis and appropriate treatment are important for HHS management. Pediatric endocrinologists should consider HHS as differential diagnosis in hyperglycemic crisis in children and adolescents.

Introduction

Acute hyperglycemic crises, including a hyperosmolar hyperglycemic state (HHS) and diabetic ketoacidosis (DKA), are severe metabolic complications occurring in patients with diabetes.¹⁾ HHS is characterized by severe hyperglycemia and hyperosmolarity without evidence of severe ketosis or acidosis. Due to the similarity of clinical features between DKA and HHS, including fatigue, malaise, polyuria, nausea, and changes in consciousness, distinguishing between these 2 conditions based on patient medical history alone is challenging. However, their diagnostic criteria differ from one another.²⁾ The biochemical criteria for the diagnosis of DKA (Table 1) include hyperglycemia (blood glucose > 200 mg/dL), a venous pH of <7.3, or a serum bicarbonate concentration of <15 mmol/L with ketonemia or ketonuria. The criteria for HHS include hyperglycemia (blood glucose > 600 mg/dL), an arterial pH of >7.30, a venous pH of >7.25, a serum bicarbonate concentration of >15 mmol/L, small ketonuria, small (or absent) ketonemia, effective serum osmolarity of

Received: 14 December, 2020
Revised: 31 March, 2021
Accepted: 30 June, 2021

Address for correspondence:

Hae Sang Lee
Department of Pediatrics, Ajou University School of Medicine, San 5, Wonchon-dong, Yeongtong-gu, Suwon 16499, Korea
Email: seon98@ajou.ac.kr
<https://orcid.org/0000-0002-9684-4042>

This is an Open Access article distributed under the terms of the Creative Commons Attribution Non-Commercial License (<http://creativecommons.org/licenses/by-nc/4.0>) which permits unrestricted non-commercial use, distribution, and reproduction in any medium, provided the original work is properly cited.

ISSN: 2287-1012(Print)
ISSN: 2287-1292(Online)

>320 mOsm/kg, obtundation, combativeness, or seizures (in approximately 50% of cases).

HHS is mainly diagnosed in elderly patients with type 2 diabetes mellitus (T2DM) and has a higher mortality rate (10%–50%) compared to that for DKA.²⁾ Although HHS is rarely the first presentation of type 1 diabetes mellitus (T1DM), there have been several reports of its occurrence in T1DM.^{3–6)} However, HHS rarely occurs in children and adolescents with T1DM, and early diagnosis and proper treatment are important because of its high mortality rate.⁷⁾ Here, we report the case of a 17-year-old adolescent male patient with T1DM who presented with HHS. Furthermore, we briefly reviewed the most recent pediatric cases of HHS in T1DM patients.

Case report

A 17-year-old boy presented to the Emergency Department with severe polydipsia and lethargy. He had a 7-day history of anorexia and a 3-day history of polyuria and polydipsia. His weight had decreased from 55 kg to 44 kg in the past month. He was previously healthy and had no past admissions or serious illnesses. There was no personal or family history of endocrine diseases, including diabetes mellitus.

Table 1. Differential diagnosis and treatment of DKA and HHS

Variable	DKA	HHS
Blood glucose (mg/dL)	>200	>600
Venous pH	<7.3	> 7.25
Serum HCO ₃ ⁻ (mmol/L)	<15	> 15
Effective serum osmolarity (mOsm/kg)	Variable	>320
Ketonuria	(+)	Small or absent
Ketonemia	(+)	Small or absent
Estimated fluid deficit (%)	6	12–15
Fluid deficit correction (hr)	24	>48
Initial insulin therapy	0.1 unit/kg/hr	0.025–0.05 unit/kg/hr

DKA, diabetic ketoacidosis; HHS, hyperosmolar hyperglycemic state.

Adapted from Wolfsdorf et al. *Pediatr Diabetes* 2018;19 Suppl 27:155-77.¹¹⁾

Table 2. Laboratory results of the case

Variable	References	Initial	8 Hours	20 Hours	40 Hours	72 Hours
pH	7.35–7.45	7.327	7.360	7.359	7.372	7.503
PCO ₂ (mmHg)	35.0–45.0	31.0	39.5	35.6	35.9	33.0
HCO ₃ ⁻ (mmol/L)	23.0–29.0	16.4	21.8	19.6	20.4	25.3
Base excess (mM)	-3.0 to 3.0	-7.6	-3.3	-4.8	-4.1	2.6
Corrected Na ⁺ (mEq/L)	135–145	161	160	165	157	149
Serum K ⁺ (mEq/L)	3.5–5.5	5.7	4.2	4.3	5.0	4.8
Serum Cl ⁻ (mEq/L)	98–107	94	113	127	124	116
Serum glucose (mg/dL)	74–106	1456	583	111	187	170
Serum BUN (mg/dL)	5.0–18.0	67.9	59.8	55.8	41.1	29.7
Serum creatinine (mg/dL)	0.40–0.60	2.93	2.81	2.4	1.76	1.17
Plasma osmolarity (mOsm/L)	275–295	359	-	364	349	363

BUN, blood urea nitrogen.

On admission, the patient's height was 173.2 cm, which was a 0.15 standard deviation score (SDS) based on the Korean normal reference. His weight was 43.6 kg (-3.13 SDS) and his body mass index was 14.57 kg/m² (-3.43 SDS).⁸⁾ His temperature was 37.0 °C, heart rate was 96 bpm, respiratory rate was 22 breaths/min, and blood pressure was 118/70 mmHg, respectively. A physical examination revealed mild drowsiness (Glasgow Coma Scale score, 13 points) but intact sensation and normal motor strength.

Initial laboratory data on admission revealed a serum glucose level of 1,456 mg/dL, serum osmolarity of 359 mOsm/kg (effective osmolarity, 323 mOsm/kg), serum urea nitrogen level of 67.9 mg/dL, and creatinine level of 2.93 mg/dL. In addition, his initial serum sodium level was 143 mmol/L, with a corrected sodium level of 156.6 mmol/L (Table 2). Venous blood gas analysis revealed a pH of 7.327, base excess of -7.65, and serum bicarbonate level of 16.4 mmol/L. Urine analysis revealed a glucose level of 3+, with a 1+ result for ketones.

The patient was diagnosed with HHS due to T1DM and was admitted to the intensive care unit. He was managed with cautious fluid replacement for an estimated 20% deficit over 72 hours with a 500-mL 0.9% normal saline bolus for 1 hour to correct his circulating volume. After normal saline loading, we began intravenous insulin infusion (regular insulin, 0.1 U/kg/hr), which was reduced to 0.025 U/kg/hr within 4 hours after confirmation of the diagnosis of HHS. The recommended dosage of continuous insulin in HHS is 0.025–0.05 units/kg/hr compared to that of 0.1 unit/kg/hr used in DKA. In addition, since our patient had neurological symptoms, including headache and drowsiness, mannitol was administered intravenously owing to the possibility of cerebral edema. After 34 hours of fluid administration, the patient's mental status became alert and his headache had subsided. Moreover, his serum glucose and corrected sodium levels had gradually improved (Fig. 1).

Finally, laboratory results confirmed T1DM. The patient's glycated hemoglobin level was 10.2% (reference, <5.6%) and his serum C-peptide level was 0.11 ng/mL (reference, 1.06–3.53 ng/mL). Additionally, his antigliutamic acid antibody level was 8.09 U/mL (reference, 4.9 U/mL), his insulin antibody level was 5.6%

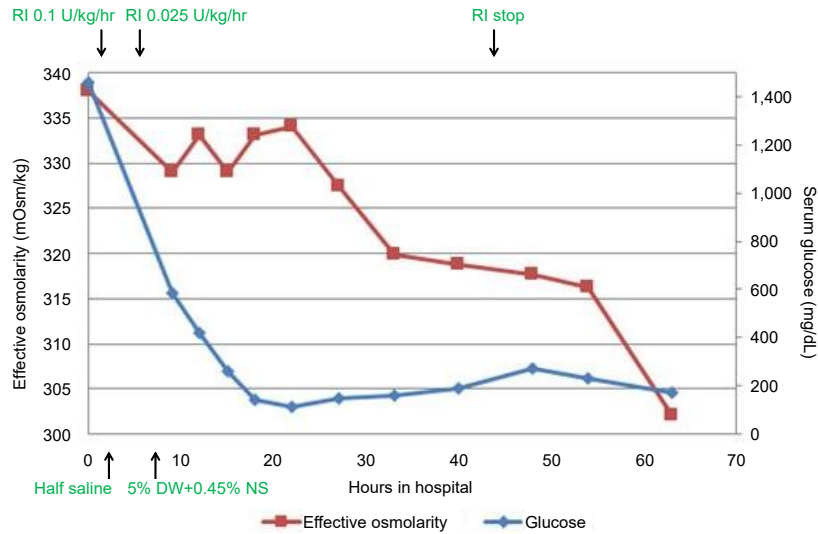


Fig. 1. Time course of laboratory findings from hospital admission to 60 hours. DW, dextrose water; NS, normal saline.

(reference, 7.0%), and he was negative for islet cell antibodies. His 24-hr urine C-peptide rate was 0.42 µg/day (reference, 17.2–181.0 mg/day). The patient and his family members were educated on intensive insulin therapy and carbohydrate counting. The patient's blood glucose levels were controlled with intensive insulin therapy (regular insulin, 0.1 U/kg/hr) and carbohydrate counting (0.8 U/kg/day). He was discharged without any neurological complications 6 days after admission.

Discussion

HHS is a life-threatening endocrine emergency that most commonly affects adults with T2DM.⁷ The incidence of HHS in pediatric patients is unclear but is estimated to account for <1% of hospital admissions in patients with diabetes.¹ Rosenbloom⁹ reviewed 97 published cases of HHS in children and adolescents from 1966–2008, finding that 33 had been diagnosed with T1DM. In addition, Agrawal et al.¹⁰ reported HHS at first presentation in 2 pediatric patients with T1DM among 411 hyperglycemic emergencies. Very rarely, cases of mixed HHS and DKA in T1DM patients have been reported. For HHS, the rate of fluid and electrolyte administration exceeds that required for the typical case of DKA to maintain an adequate circulatory volume.¹⁰

Hyperglycemia in patients with DKA leads to osmotic diuresis and electrolyte imbalance due to increased glucose production by the liver and kidneys and peripheral glucose utilization disorders. Ketonemia and metabolic acidosis result from increased lipolysis and increased ketoacid production.¹ Both DKA and HHS result from a deficiency of circulating insulin and increased levels of the counter-regulatory hormones catecholamines, glucagon, cortisol, and growth hormone. HHS is characterized by extreme elevations in serum glucose

concentrations and hyperosmolarity without significant ketosis. Higher hepatic and circulating insulin concentrations with relatively lower glucagon are present in patients with HHS compared to those with DKA. The higher circulating insulin/glucagon ratio in patients with HHS prevents ketogenesis and the development of ketoacidosis.¹¹

It is important to understand the differences between the treatments available for DKA and HHS. Prompt diagnosis and proper treatment are essential to prevent serious complications of HHS. The treatment goal in HHS is to expand intravascular and extravascular volumes and restore normal kidney perfusion. The rate of fluid treatment in HHS is faster than that recommended for DKA. In addition, isotonic fluid is more effective in maintaining the circulating volume. Unlike DKA, hypernatremia can occur in HHS patients. Mortality is mostly associated with a failure to reduce the corrected serum sodium concentration, which can be an indication for dialysis in some cases. The corrected sodium concentration was frequently measured in this case to monitor its gradual decrease. There are no data that suggest the appropriate speed for adjusting serum sodium concentration; however, a dose of 0.5 mmol/L/hr is recommended for hypernatremic dehydration.¹¹ In our case, hypernatremia was detected during initial laboratory testing. If hypernatremia occurs with severe hyperglycemia, clinicians should consider the possibility of HHS and more attention should be paid to fluid treatment.

Continuous insulin therapy may not be required for the treatment of HHS; however, insulin therapy can be considered when serum glucose levels do not decline adequately with fluid hydration alone or in children with significant ketosis and acidosis. The recommended dosage of continuous insulin in HHS is 0.025–0.05 units/kg/hr compared to that of 0.1 units/kg/hr generally used in DKA; a dose reduction should be

considered if the serum glucose concentration decreases below 50–75 mg/dL/hr.²⁾

The reported mortality rate of HHS is 50%–60%, with a recent cohort study reporting a 30-day mortality rate of 16%.¹²⁾ Therefore, clinicians should consider a diagnosis of HHS in children and adolescents experiencing hyperglycemic emergencies. In addition, cautious therapy, such as hydration and insulin supplementation, is critical for reducing morbidity and mortality rates in HHS.

In conclusion, we reported a case of HHS with hypernatremia in T1DM in an adolescent patient who was initially suspected to have DKA. Our patient was diagnosed with T1DM that evolved into HHS with hypernatremia. We initially considered DKA instead of HHS, given its prevalence in pediatric patients, but our patient's diagnosis was later confirmed to be HHS based on his serum glucose level, hyperosmolarity, and hypernatremia. The occurrence of HHS in T1DM is very rare; however, the morbidity and mortality rates due to HHS are approximately 10 times higher than those seen with DKA.¹³⁾

Ethical statement

Our study adhered to the ethical guidelines for medical and health research involving human subjects. Consent for publication was obtained from the patient and patient's parents for the preparation and publication of this report.

Notes

Conflicts of interest: No potential conflict of interest relevant to this article was reported.

Funding: This study received no specific grant from any funding agency in the public, commercial, or not-for-profit sectors.

Acknowledgments: The authors wish to thank the patient and his parents for their kind collaboration and their contribution to this report.

Author contribution: Conceptualization: HSL; Data curation: SHC, HSL, JSH; Methodology: JSH; Visualization: SHC; Writing - original draft: SHC; Writing - review & editing: HSL, JSH

ORCID

Sang Hoon Chun: 0000-0002-7990-455X

Hae Sang Lee: 0000-0002-9684-4042

Jin Soon Hwang: 0000-0002-2666-3801

References

1. Umpierrez G, Korytkowski M. Diabetic emergencies - ketoacidosis, hyperglycaemic hyperosmolar state and hypoglycaemia. *Nat Rev Endocrinol* 2016;12:222-32.
2. Dhatariya KK, Vellanki P. Treatment of diabetic ketoacidosis (DKA)/hyperglycemic hyperosmolar state (HHS): novel advances in the management of hyperglycemic crises (UK versus USA). *Curr Diab Rep* 2017;17:33.
3. Watanabe S, Kido J, Ogata M, Nakamura K, Mizukami T. Hyperglycemic hyperosmolar state in an adolescent with type 1 diabetes mellitus. *Endocrinol Diabetes Metab Case Rep* 2019;2019:18-0131.
4. Cho YM, Park BS, Kang MJ. A case report of hyperosmolar hyperglycemic state in a 7-year-old child: an unusual presentation of first appearance of type 1 diabetes mellitus. *Medicine (Baltimore)* 2017;96:e7369.
5. Alharfi IM, Singh R, Clarson C, Foster JR. Hyperosmolar hyperglycemic state without ketosis in a toddler with type 1 diabetes. *Pediatr Emerg Care* 2014;30:485-7.
6. Kershaw MJ, Newton T, Barrett TG, Berry K, Kirk J. Childhood diabetes presenting with hyperosmolar dehydration but without ketoacidosis: a report of three cases. *Diabet Med* 2005;22:645-7.
7. Pasquel FJ, Umpierrez GE. Hyperosmolar hyperglycemic state: a historic review of the clinical presentation, diagnosis, and treatment. *Diabetes Care* 2014;37:3124-31.
8. Kim JH, Yun S, Hwang SS, Shim JO, Chae HW, Lee YJ, et al. The 2017 Korean National Growth Charts for children and adolescents: development, improvement, and prospects. *Korean J Pediatr* 2018;61:135-49.
9. Rosenbloom AL. Hyperglycemic hyperosmolar state: an emerging pediatric problem. *J Pediatr* 2010;156:180-4.
10. Agrawal S, Baird GL, Quintos JB, Reinert SE, Gopalakrishnan G, Boney CM, et al. Pediatric diabetic ketoacidosis with hyperosmolarity: clinical characteristics and outcomes. *Endocr Pract* 2018;24:726-32.
11. Wolfsdorf JI, Glaser N, Agus M, Fritsch M, Hanas R, Rewers A, et al. ISPAD clinical practice consensus guidelines 2018: diabetic ketoacidosis and the hyperglycemic hyperosmolar state. *Pediatr Diabetes* 2018;19 Suppl 27:155-77.
12. Fadini GP, de Kreutzenberg SV, Rigato M, Brocco S, Marchesan M, Tiengo A, et al. Characteristics and outcomes of the hyperglycemic hyperosmolar non-ketotic syndrome in a cohort of 51 consecutive cases at a single center. *Diabetes Res Clin Pract* 2011;94:172-9.
13. Zeitler P, Haqq A, Rosenbloom A, Glaser N. Hyperglycemic hyperosmolar syndrome in children: pathophysiological considerations and suggested guidelines for treatment. *J Pediatr* 2011;158:9-14, 14.e1-2.