

# Diagnosis and management of inadvertently placed pacemaker lead in the left ventricle following sinus venosus atrial septal defect repair surgery



Meron Teshome, MD,\* Ikechukwu Ifedili, MD,\* Mannu Nayyar, MD,\*  
Yehoshua Levine, MD, FHRS,\* Anthony Holden, MD,<sup>†</sup> Neeraja Yedlapati, MD,\*  
Rajesh Kabra, MD, FHRS\*

From the \*Division of Cardiology, University of Tennessee Health Science Center, Memphis, Tennessee, and  
<sup>†</sup>Division of Cardiothoracic Surgery, Methodist University Hospital, Memphis, Tennessee.

## Introduction

Inadvertent placement of a ventricular lead into the left ventricle (LV) is a rare complication during cardiovascular implantable electronic device (CIED) implantation. In a retrospective study of 2579 patients undergoing CIED implantation, 6 patients (0.34%) had inadvertent lead malposition in the left heart—4 in the LV and 1 each in left atrium and coronary sinus.<sup>1</sup> Lead malposition in the LV can lead to serious cardiovascular complications including mitral valve damage, mitral regurgitation, left ventricular thrombus, and stroke.<sup>2,3</sup> This malposition may occur if the lead directly enters the left heart through the subclavian artery, or from the right to left heart chamber through an atrial septal defect (ASD), ventricular septal defect (VSD), or patent foramen ovale (PFO). A surgical correction of these septal defects may decrease this risk of lead malposition but may not eliminate it. We report a case of erroneous placement of a pacemaker lead in the LV of a patient with a history of sinus venosus ASD repair surgery, where 12-lead electrocardiogram (ECG) and cardiac imaging were instrumental in leading to the correct diagnosis and management.

## Case report

A 46-year-old woman with history of hypertension, chronic obstructive pulmonary disease on home oxygen, cardiomyopathy (left ventricular ejection fraction 45%), permanent atrial fibrillation on chronic warfarin therapy, and atrioventricular node ablation status post single-chamber pacemaker implantation 3 years prior to presentation presented to our hospital with a second episode of transient left-sided vision loss and left-sided numbness. She underwent surgery for sinus venosus ASD 5 years prior to presentation, during

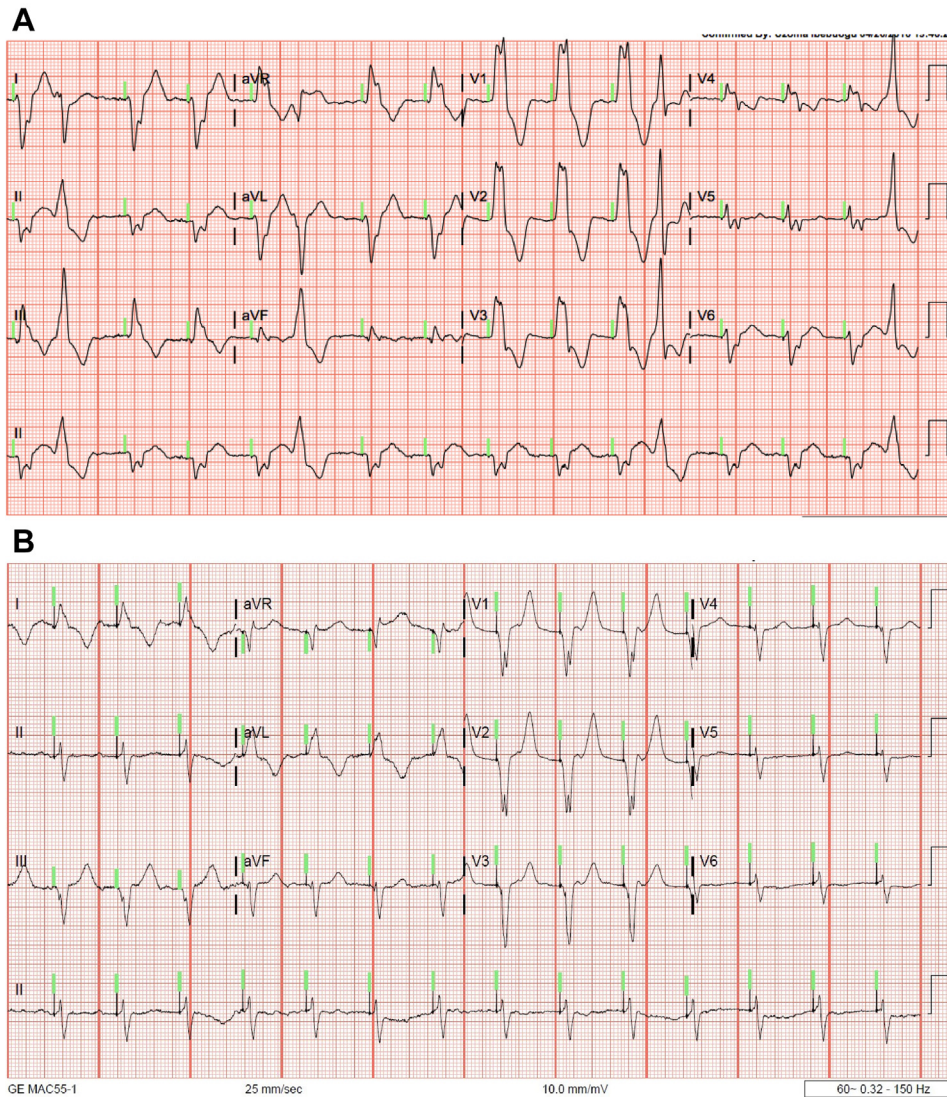
## KEY TEACHING POINTS

- Pacemaker/implantable cardioverter-defibrillator lead deployment in the left ventricle is a rare complication, which can occur especially in the presence of atrial septal defect, patent foramen ovale, and ventricular septal defect—even after surgical repair.
- Morphology of the ventricular paced rhythm on 12-lead electrocardiogram patterns and postprocedural posteroanterior/lateral chest radiographs are helpful in confirming ventricular lead position.
- Chest computed tomography scan and echocardiogram (transthoracic and transesophageal) may further clarify the lead position and course in entirety.
- Presence of lead in left ventricle may be associated with complications including thromboembolism, necessitating urgent lead extraction and appropriate lead placement.

which a pericardial patch repair of ASD and patch angioplasty of superior vena cava–right atrial (SVC-RA) junction was performed. Besides warfarin, her home medications included carvedilol, lisinopril, torsemide, pregabalin, zolpidem, albuterol, pantoprazole, and multivitamin. Physical examination was normal except for increased body mass index of 40 kg/m<sup>2</sup>. Her left-sided pacemaker pocket was normal, without any swelling or erythema. Laboratory workup was normal, including a therapeutic international normalized ratio. Computed tomography (CT) scan of the brain was negative for any intracranial bleeding. Magnetic resonance imaging could not be done, as the patient's pacemaker was not magnetic resonance imaging compatible.

**KEYWORDS** ASD; Lead extraction; Left ventricle; Paced 12-lead EKG; Pacemaker lead malposition; TIA  
(Heart Rhythm Case Reports 2020;6:279–282)

**Address reprint requests and correspondence:** Dr Rajesh Kabra, Cardiac Electrophysiology, University of Tennessee Health Sciences Center, 956 Court Avenue, Memphis, TN 38163. E-mail address: [rkabra@uthsc.edu](mailto:rkabra@uthsc.edu).



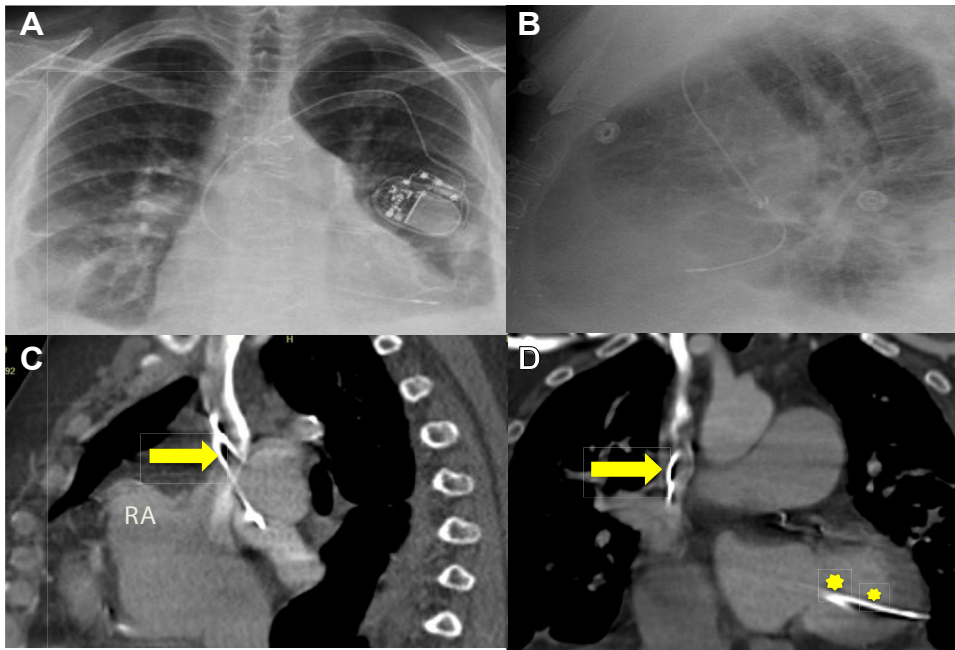
**Figure 1** A: Twelve-lead electrocardiogram (ECG) showing ventricular paced rhythm with right bundle branch block pattern and frequent premature ventricular complexes. B: Twelve-lead ECG post left ventricular lead extraction and lead placement in right ventricle.

Her visual and left-sided symptoms resolved within 3 hours. The patient was diagnosed with transient ischemic attack (TIA) and started on aspirin and atorvastatin. Cardiac electrophysiology consult was requested for pacemaker interrogation and atrial fibrillation management.

A 12-lead ECG (Figure 1A) revealed ventricular paced rhythm with right bundle branch block pattern, rightward axis, and premature ventricular complexes. This was not typical for right ventricular pacing and was suggestive of pacing from the lateral left ventricular wall. Single-chamber pacemaker interrogation demonstrated normal ventricular lead parameters. The patient was pacemaker dependent with no underlying ventricular escape rhythm. A posteroanterior (PA) and lateral chest radiograph (Figure 2A and B) showed the ventricular lead in leftward position concerning for left ventricular placement. To further clarify pacemaker lead position, CT scan of the chest was performed. It showed that the pacemaker lead

entered the left atrium around the ASD repair patch and was positioned in the LV through the mitral valve (Figure 2C and D). Transthoracic and transesophageal echocardiography confirmed these findings and showed that the lead entered the left atrium above the superior aspect of the ASD repair patch at the SVC-RA junction (Figure 3). There was no left atrial appendage thrombus or thrombus in the LV lead. After discussing all the management options, a shared decision-making with the patient was performed. The patient underwent successful extraction of the pacemaker lead using a laser sheath with the aid of fluoroscopy and transesophageal echocardiography, a new pacemaker lead was subsequently placed in the right ventricle. The laser sheath was not advanced beyond the superior vena cava to prevent damage to the ASD repair patch. Repeat 12-lead ECG post procedure showed paced rhythm with expected left bundle branch morphology (Figure 1B).



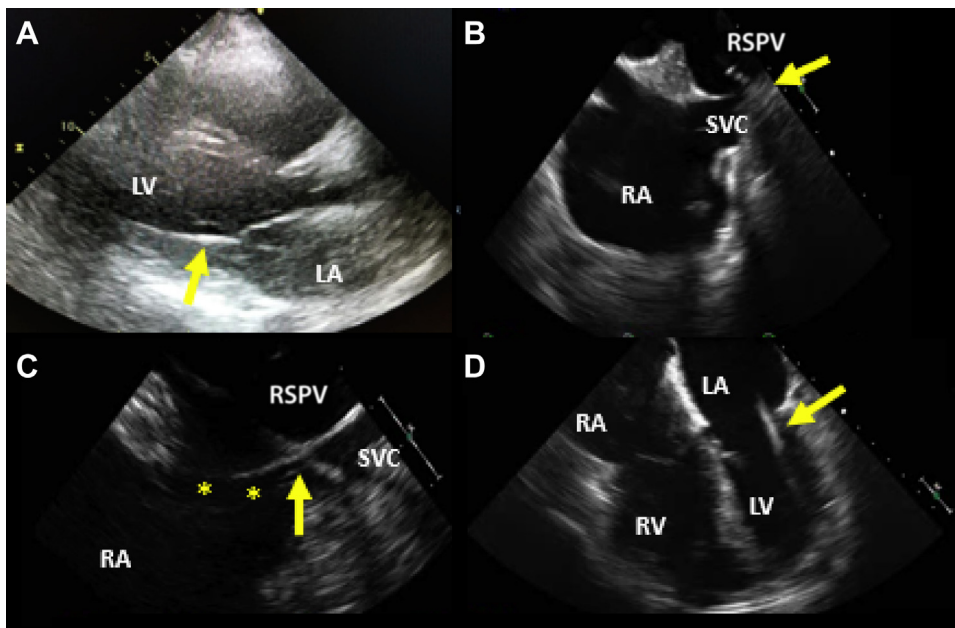


**Figure 2** Chest radiographs, **A**: posteroanterior and **B**: lateral, showing a single-chamber pacemaker lead with ventricular lead in a leftward position within the left ventricle (LV). **C**: Sagittal computed tomography (CT) scan of the chest showing pacemaker lead (*arrow*) passing through the superior vena cava (SVC) and into the left atrium (LA). **D**: Coronal section of chest CT scan showing pacemaker lead (*arrow*) going through the SVC and passing through the LA into the LV (*asterisks*).

## Discussion

Our case report demonstrates several learning points. During implantation of CIED leads, it is extremely important to be aware of inadvertent placement of the ventricular lead into the LV, especially in the presence of ASD, PFO, or VSD. In our patient, this happened even after sinus

venous ASD repair surgery, likely through the gap above the patch in the SVC-RA junction. Routine advancement of the guide wire into the inferior vena cava and advancement of the ventricular lead into the pulmonary artery prior to final lead deployment, attention to the morphology of 12-lead ECG of the ventricular paced rhythm can



**Figure 3** **A**: Transthoracic echocardiography parasternal long-axis view showing pacemaker lead (*arrow*) crossing the mitral valve from the left atrium (LA) into the left ventricle (LV). **B**, **C**: Transesophageal echocardiography (TEE) bicaval view showing pacemaker lead (*arrow*) going from superior vena cava (SVC)/right atrium (RA) junction into LA around patch repair (*asterisks*). **D**: TEE 4-chamber view showing pacemaker lead (*arrow*) in the LA and LV. RSPV = right superior pulmonary vein; RV = right ventricle.

prevent this complication,<sup>4</sup> while postprocedural PA and lateral chest radiograph, echocardiography, and computed tomography can help to diagnose this complication earlier if there is a clinical suspicion.<sup>5</sup> From [Figure 2](#), the patient's PA chest radiograph shows the lead in the leftward position close to the LV apex but the lateral view shows an anteriorly directed lead distal segment; this reflects its course from the left atrium to the LV. This contrasts with a lead located in the coronary sinus, which will be posteriorly located.

Implantation of a pacemaker lead in the LV can be complicated by thromboembolic events, endocarditis, and trauma to the LV wall and/or mitral valve.<sup>3</sup> In our patient, the recurrent TIA was most likely the result of embolism of microthrombi formed in the LV lead because she had a consistent therapeutic anticoagulation level for atrial fibrillation, and she has not had a repeat TIA episode since LV lead extraction was done. Her premature ventricular complexes also improved post procedure ([Figure 1](#)).

Cardiac imaging with CT scan of the chest and transthoracic and transesophageal echocardiography play an important role in confirming the diagnosis of ventricular lead malposition and to trace the lead in its entirety. Both were complementary in our patient to demonstrate the site where the lead crossed from the SVC-RA junction to the left atrium. Knowledge of this site was helpful in planning the lead extraction procedure.<sup>6</sup> The laser sheath was not advanced beyond the SVC to avoid damage to the ASD repair patch. Her postprocedure 12-lead ECG showed the expected left

bundle branch block ECG morphology of appropriately paced right ventricular lead.

## Conclusion

Inadvertent deployment of a ventricular lead into the LV during CIED implantation is a rare complication, which can occur in the presence of ASD, PFO, or VSD, even after surgical repair. Attention to fluoroscopy during lead placement, use of 12-lead ECG to assess the paced rhythm morphology, and postprocedural chest radiograph and other appropriate imaging in patients with equivocal findings should be pursued, to enable early diagnosis and management of lead malposition to avoid complications.

## References

1. Ohlow MA, Roos M, Lauer B, Von Korn H, Geller JC. Incidence, predictors, and outcome of inadvertent malposition of transvenous pacing or defibrillation lead in the left heart. *Europace* 2016;18:1049–1054.
2. Van Gelder BM, Bracke FA, Oto A, et al. Diagnosis and management of inadvertently placed pacing and ICD leads in the left ventricle: a multicenter experience and review of the literature. *Pacing Clin Electrophysiol* 2000;23:877–883.
3. Seki H, Fukui T, Shimokawa T, et al. Malpositioning of a pacemaker lead to the left ventricle accompanied by posterior mitral leaflet injury. *Interact Cardiovasc Thorac Surg* 2009;8:235–237.
4. Velibey Y, Yaylak B, Guven TS, et al. Inadvertent left ventricle endocardial or uncomplicated right ventricular pacing: how to differentiate in the emergency department. *J Emerg Med* 2018;54:e91–e95.
5. Trohman RG, Sharma PS. Detecting and managing device leads inadvertently placed in the left ventricle. *Cleve Clin J Med* 2018;85:69–75.
6. Kancharla K, Acker NG, Li Z, et al. Efficacy and safety of transvenous lead extraction in the device laboratory and operating room guided by a novel risk stratification scheme. *JACC Clin Electrophysiol* 2019;5:174–182.