

# Filum Terminale Arteriovenous Fistula Coexisting with a Large L2–L3 Disc Sequestration and Associated Diffuse Lumbar Arachnoiditis

## Abstract

The authors describe a case of filum terminale arteriovenous fistula (FTAVF) in association with a large L2–L3 disc sequestration and diffuse lumbar arachnoiditis. A 64-year-old male manifested with chronic back pain and gait difficulty. Magnetic resonance imaging (MRI) of the thoracic and lumbosacral spine revealed spinal cord congestion extending from the conus medullaris to the level of T9. There was a large disc sequestration came from L2–L3 disc herniation. In addition, thickening, clumping, and enhancement of the entire cauda equina were noted, probably representing arachnoiditis. MR angiography (MRA) and spinal angiography confirmed FTAVF at the level of L5. The patient underwent laminectomy with lysis adhesions and obliteration of the fistula. His postoperative course was uneventful. MRI and MRA of the thoracolumbar spine obtained 4 months after surgery revealed complete obliteration of the fistula and significant resolution of spinal cord congestion. Enhancement of the cauda equina roots was no longer visible. Interestingly, the significant resorption of the sequestered disc was documented on MRI. The formation of the FTAVF in the present study may result from severe spinal canal stenosis caused by a large disc sequestration blocking the rostral venous drainage of the fistula, or chronic inflammation, and adhesions of the caudal nerve roots from lumbar arachnoiditis. It seems that FTAVF may be of acquired origin by this evidence.

**Keywords:** *Acquired in origin, disc sequestration, filum terminale arteriovenous fistula, lumbar arachnoiditis, spinal canal stenosis*

## Introduction

Filum terminale arteriovenous fistulas (FTAVFs) are rare and characterized by a single direct communication between the artery of the filum terminale, the distal termination of the anterior spinal artery (ASA), and the vein of the filum terminale without intervening nidus. The pathogenesis of FTAVFs remains controversial. They may be either congenital or acquired in origin. These arteriovenous fistulas (AVFs) usually affect middle-aged men. The common presentation of FTAVFs is a slowly progressive myelopathy secondary to venous congestion resulting from retrograde arterialization of the draining vein into the spinal cord. The most common location of the fistulous point is the level of L3 to L5.<sup>[1,2]</sup>

Lumbar arachnoiditis is an inflammatory process of the arachnoid membrane within the lumbar spinal canal involving the cauda equina nerve roots resulting in

thickening of the arachnoid membrane and adhesions of the nerve roots each other and to the pia-arachnoid.<sup>[3]</sup> The etiology of spinal arachnoiditis may result from spinal surgery, trauma, infection, tumor, agents (anesthetic agents, contrast media during myelography, and antibiotic) into subarachnoid space, intrathecal hemorrhage, spinal canal stenosis, disc herniation, and idiopathy.<sup>[4-7]</sup> In addition, adhesive arachnoiditis may follow lumbar epidural steroid injection, one of the most performed procedures for managing low back pain.<sup>[8]</sup> Arachnoiditis is diagnosed by myelography, magnetic resonance imaging (MRI), or direct surgical observation.<sup>[3,9]</sup> The imaging features of lumbar arachnoiditis mainly include clumping and adhesions of nerve roots, thickened nerve roots, and enhancing nerve roots in studies using contrast. It may involve either single or multiple level.<sup>[10]</sup>

This is an open access journal, and articles are distributed under the terms of the Creative Commons Attribution-NonCommercial-ShareAlike 4.0 License, which allows others to remix, tweak, and build upon the work non-commercially, as long as appropriate credit is given and the new creations are licensed under the identical terms.

For reprints contact: WKHLRPMedknow\_reprints@wolterskluwer.com

**Prasert  
Iampreechakul,  
Ekkapot Jitpun,  
Korrapak  
Wangtanaphat,  
Punjama  
Lertbutsayanukul<sup>1</sup>,  
Sirirat  
Khunvutthidee<sup>1</sup>,  
Somkiet  
Siriwimonmas<sup>2</sup>**

*Departments of Neurosurgery and <sup>1</sup>Neuroradiology, Prasat Neurological Institute, <sup>2</sup>Department of Radiology, Bumrungrad International Hospital, Bangkok, Thailand*

**Address for correspondence:**  
*Dr. Prasert Iampreechakul,  
312 Rachawithi Road,  
Khwaeng Thung Phaya Thai,  
Bangkok 10400, Thailand.  
E-mail: bangruad@hotmail.com*

### Access this article online

**Website:** [www.asianjns.org](http://www.asianjns.org)

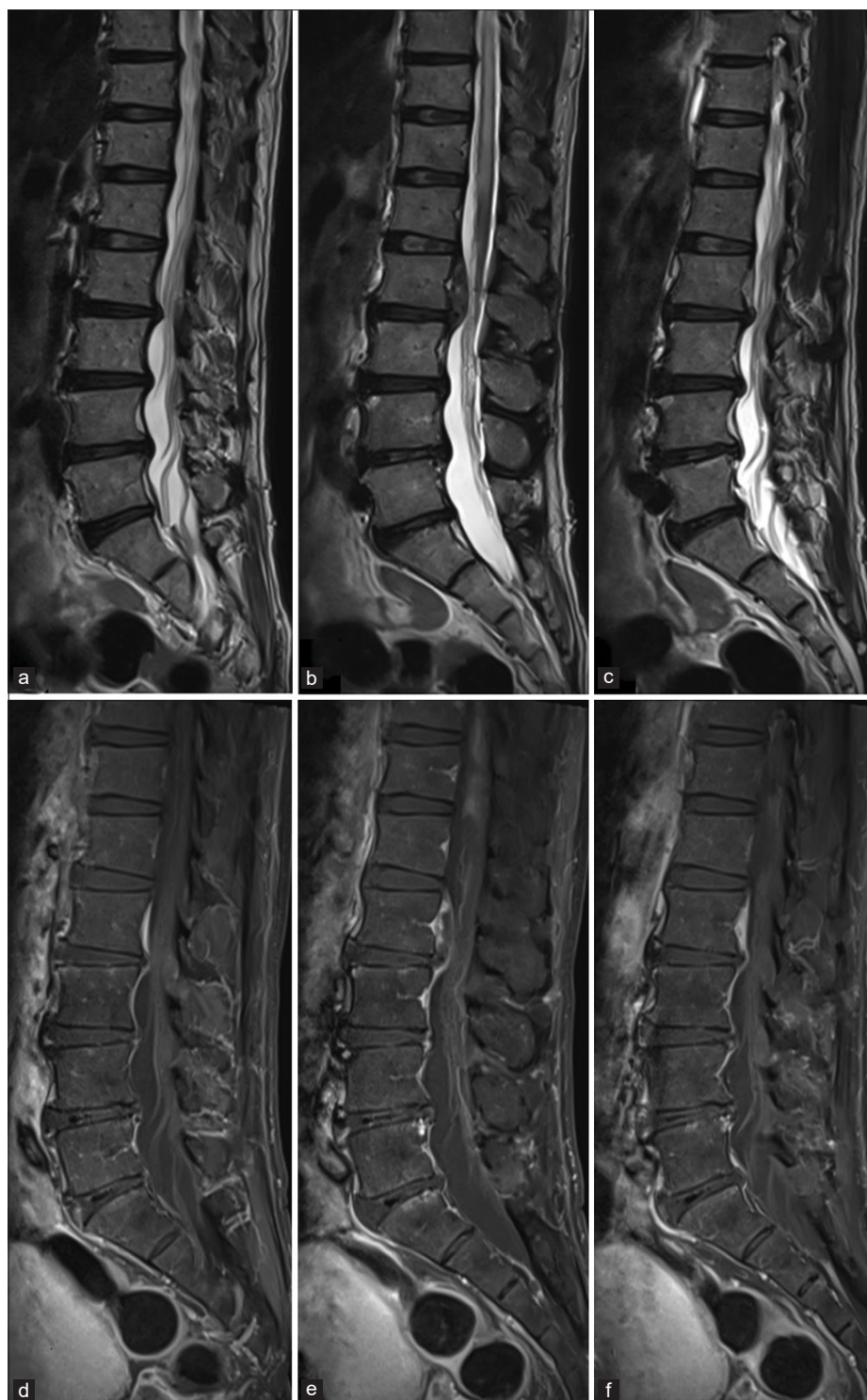**DOI:** 10.4103/ajns.AJNS\_489\_20

### Quick Response Code:



**How to cite this article:** Iampreechakul P, Jitpun E, Wangtanaphat K, Lertbutsayanukul P, Khunvutthidee S, Siriwimonmas S. Filum terminale arteriovenous fistula coexisting with a large L2–L3 disc sequestration and associated diffuse lumbar arachnoiditis. *Asian J Neurosurg* 2021;16:412-7.

**Submitted:** 01-Nov-2020    **Revised:** 03-Dec-2020  
**Accepted:** 28-Dec-2020    **Published:** 28-May-2021

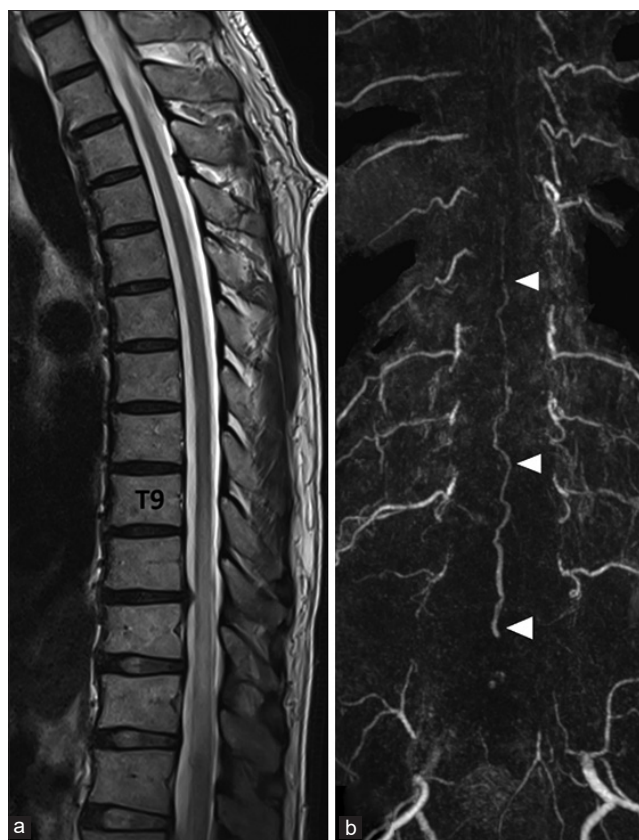

**Figure 1:** Magnetic resonance imaging of the lumbosacral spine. Sequential sagittal T2-weighted (a-c), and gadolinium-enhanced T1-weighted with fat saturation (d-f) images reveal abnormal hyperintense T2 signal with patchy enhancement representing spinal cord congestion extending from the conus medullaris to the thoracic level. There is a large L2–L3 disc sequestration with superior migration along the posterior aspect of the L2 vertebral body, compressing dura resulting in moderate spinal canal stenosis. This sequestered disc appears isointense T1, slight hyperintense T2 to disc space with peripheral enhancement. In addition, associated diffuse thickening, clumping with enhancement of the cauda equina roots are noted, probably representing arachnoiditis.

We described a case of FTAVF in association with a large lumbar sequestered disc and arachnoiditis. The pathogenesis of the fistula in this situation was discussed.

### Case Report

A 64-year-old male with a 2-year history of intermittent back pain complained of gait difficulty for 6 months. He



**Figure 2:** (a) Sagittal T2-weighted image of the thoracic spine demonstrates spinal congestion extending from the conus medullaris to the level of T9. (b) Contrast-enhanced magnetic resonance angiography of the thoracolumbar spine shows tortuous and enlarged intradural vessels (arrowheads) in the midline location extending from the lower lumbar level to the mid-thoracic level

had no history of any injury. The patient went to the local medical center and was treated with some medicines and physiotherapy. One month before hospitalization, he was only able to walk approximately 100 m before needing to stop. Two weeks before admission, he developed urination incontinence requiring diapers. The patient was transferred to our institute and admitted for further investigation. On physical examination, his gait was slightly wide based. The straight leg raise test was negative. The neurological examination revealed the evidence of spastic paraparesis (muscle strength 4/5), impairment of proprioception, hyperreflexia, and presence of Babinski sign in the lower extremities. MRI of the lumbosacral spine revealed abnormal hyperintense T2 signal with patchy enhancement representing spinal cord congestion extending from the conus medullaris to the level of T9. There was a large, sequestered disc fragment came from L2-L3 disc herniation migrated cranially along the posterior aspect of the L2 vertebral body, compressing dura resulting in moderate spinal canal stenosis. This sequestered disc appeared isointense T1, slight hyperintense T2 to disc space with peripheral enhancement. In addition, associated diffuse thickening, clumping, and enhancement of the cauda equina roots were noted, probably representing arachnoiditis [Figures 1a-f and 2a]. Contrast-enhanced

MR angiography (MRA) of the thoracolumbar spine demonstrated tortuous and enlarged intradural vessels in the midline location extending from the lower lumbar level to the mid-thoracic level [Figure 2b]. Spinal angiography demonstrated the FTAVF at the level of L5, which is supplied by the artery of the filum terminale continuing from the ASA originating from the right L1 segmental artery with cranial drainage through the dilated vein of the filum terminale into the tortuous perimedullary veins up to the mid-thoracic level [Figure 3a and b]. Three-dimensional reconstruction of angiographic computed tomography of the right L1 segmental artery clearly illustrated the fistula and its location [Figure 3c].

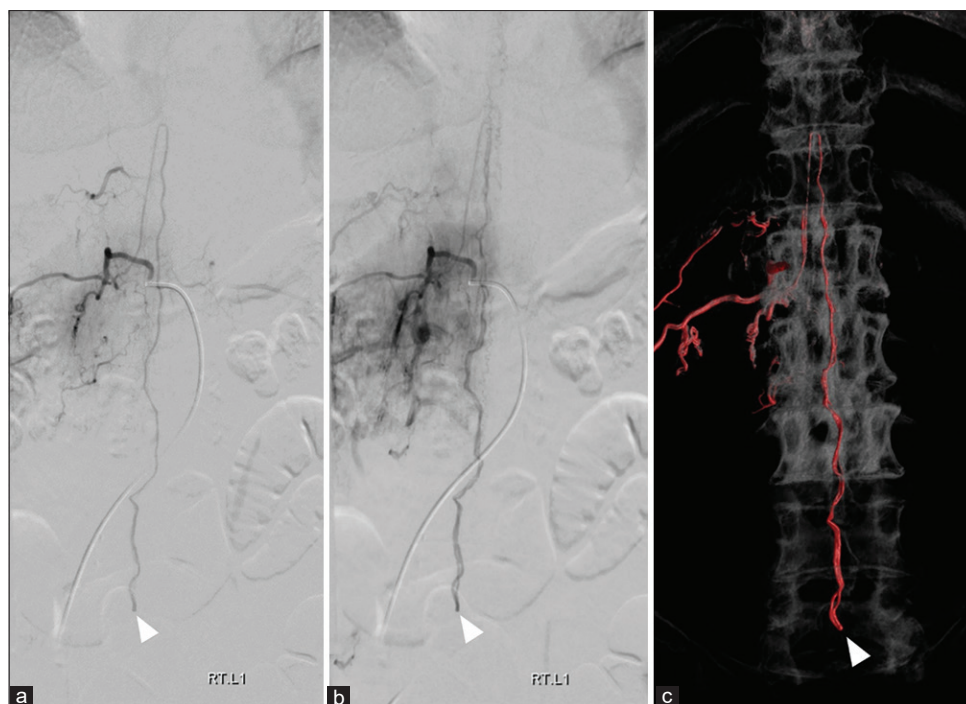
The patient underwent surgical treatment. Laminectomy was performed at the level of L5. After durotomy, the arachnoid membrane was found to be thickened and opaque. The arachnoid was gently separated. The roots of the cauda equina were swollen and matted together with fine adhesions. The filum terminale was adhered within the clumping of the cauda equina. Lysis of adhesions between the nerve roots was performed. FTAVF was identified and obliterated with small silver vessel clips [Figure 4]. Complete obliteration of the fistula was confirmed using indocyanine green fluorescence imaging. His postoperative course was uneventful.

At the 2-month clinical follow-up examination, the patient continued to improve clinically with the resolution of his urinary incontinence and marked improvement in gait. At the 4-month follow-up, he had completely recovered without urinary incontinence and regained normal walking ability. MRI and MRA of the thoracolumbar spine obtained 4 months after surgery revealed complete obliteration of the fistula and significant resolution of spinal cord congestion [Figure 5]. Enhancement of the cauda equina roots was no longer visible. Interestingly, the large sequestered L2-L3 disc had spontaneously resolved.

## Discussion

The pathogenesis of lumbar arachnoiditis in the absence of the other risk factors remains unknown. According to the study about the possible relationships between arachnoiditis and degenerative disease of the lumbar spine in 165 patients by Jackson and Isherwood,<sup>[5]</sup> they suggested that adhesive lumbar arachnoiditis may occur in association with spinal stenosis. Furthermore, lumbar arachnoiditis due to spinal canal stenosis rarely extends over more than one vertebral level unless spinal stenosis is also present at multiple levels. They reviewed the literature and found that there was no evidence of a relationship between arachnoiditis and lumbar disc degeneration or herniation.

In contrast, some authors suggested that repeated minor persistent trauma due to disc protrusion may cause localized arachnoiditis.<sup>[4]</sup> Epstein *et al.*<sup>[7]</sup> reported a case of a large midline extruded disc from L2-L3 disc herniation with obliterative localized arachnoiditis diagnosed by direct



**Figure 3:** Anteroposterior views of the right L1 segmental artery angiography in arterial (a) and venous (b) phases show an arteriovenous fistula of the filum terminale (arrowheads) at the level of L5, which is supplied by the artery of the filum terminale continuing from the anterior spinal artery with cranial drainage into the dilated vein of the filum terminale connecting to the medullary veins. (c) Three-dimensional reconstructed coronal image of rotational spinal angiogram of the right L1 segmental artery clearly demonstrates the fistula (arrowhead) and its location

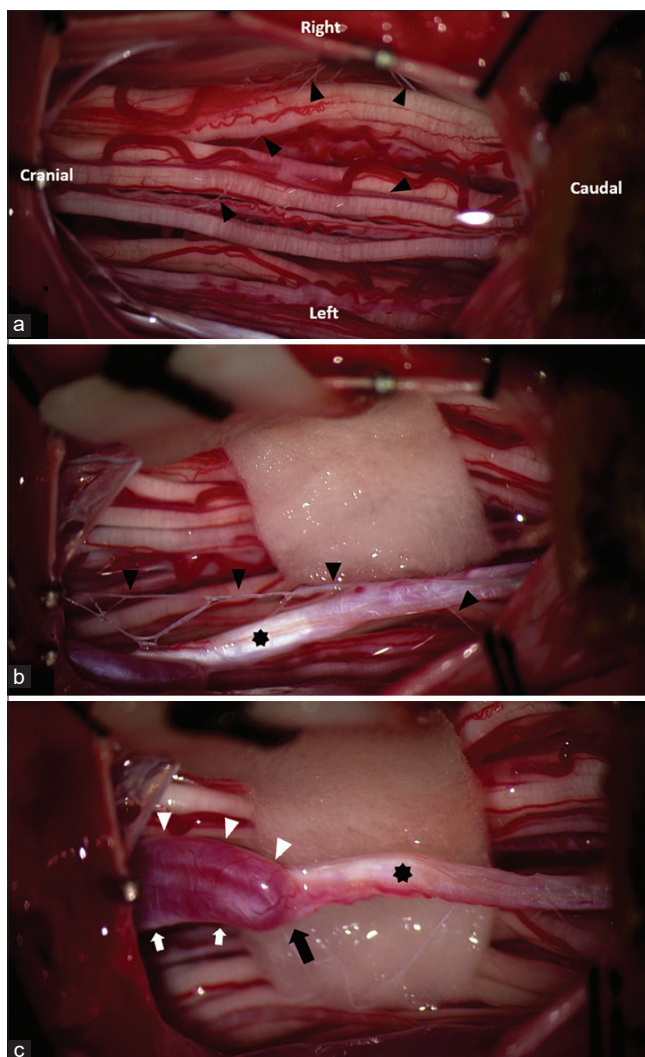
surgical observation. They speculated that arachnoiditis may cause by the focal nature of severe spinal canal stenosis representing a complete block on myelography. Furthermore, Crisi *et al.*<sup>[11]</sup> studied contrast-enhanced features on MRI of intrathecal nerve roots in patients harboring lumbar disc herniation without prior surgery. They found that 30% of patients had enhancement of ipsilateral intradural roots affected with large disc herniation along their whole length from the site of compression to the root-medullary junction. They speculated that this enhancement may cause by the breakdown of the blood-nerve barrier with edema in the compressed roots and subsequent crossing of gadolinium from vessels to endoneurium. In addition, the disruption of the annulus fibrosus and posterior longitudinal ligament may permit leakage of chemical or immunological irritant from the nucleus pulposus, producing inflammatory response in the surrounding tissues including the dural and nerve roots sleeves, probably inducing arachnoiditis.<sup>[12,13]</sup> In the present case, it is possible that diffuse lumbar arachnoiditis may result from leakage of chemical substance into the epidural space of the spinal canal caused by the sequestered nucleus pulposus from L2-L3 disc herniation.

According to the theory about the formation of intracranial DAVFs proposed by Miyachi *et al.*,<sup>[14]</sup> neovascularization and vessel dilatation were induced by local inflammation near the area of the emissary draining veins, and subsequent arteriovenous connection occurred on the arteriole level. In addition, the maturation of the fistula subsequently

developed after the occlusive change of the venous draining system. They hypothesized that the pathogenesis of the AVF in the spine can be explained by this same mechanism. In addition, Tender *et al.*<sup>[15]</sup> suggested that FTAVFs, which mainly present in adults, may not be the congenital cause as had previously been assumed. They believed that the pathogenesis of FTAVFs caused by the absence or loss of functional medullary veins, that normally drain blood from the perimedullary veins to the epidural venous system.

Due to a high association between FTAVFs and lumbar stenosis, Scullen *et al.*<sup>[16]</sup> speculated that chronic inflammation, the development of adhesions, and repetitive microtrauma caused by long-standing severe lumbar stenosis may result in hyalinization with fibrosis, limited physiological motion, and increased tension within the filum terminale, inducing the fistula formation.

Previously, we reported the first case of spinal sparganosis coexisting with an acquired FTAVF, which may have resulted from severe canal stenosis caused by lumbar spondylosis and spinal sparganosis, inducing chronic inflammation and severe adhesion of spinal nerve roots. The patient underwent surgical removal of the granulation tissues with lysis adhesions and obliteration of the FTAVF simultaneously in the same surgical session with good recovery.<sup>[17]</sup> Subsequently, we reported another three cases with acquired FTAVFs, probably secondary to the severe spinal canal stenosis, and reviewed the literature about this condition in another 17 patients.<sup>[18]</sup> We found that the level of the fistulas in most patients is correlated with the



**Figure 4:** Intraoperative photograph of the patient in the prone position after the opening of the dura. (a) The cauda equina nerve roots are swollen and matted together with fine adhesions (black arrowheads). (b) Adhesions (black arrowheads) between the filum terminale (asterisk) and the arachnoid. (c) The fistula (black arrow) is located on the filum (asterisk) with the dilated artery of the filum (white arrowheads) and cranial drainage into the dilated vein of the filum (white arrows)

level of spinal canal stenosis that may induce local injury or inflammation of the filum terminale and produce fistula formation. However, there were few cases with FTAVFs located below the level of spinal stenosis. The mechanism of the fistulous formation in these cases may be induced from blocked or impaired venous drainage due to severe spinal stenosis rostral to the fistula.

In our case, there are two possibilities which can lead to the formation of FTAVF. First, severe spinal stenosis caused by L2–L3 disc sequestration may block venous drainage of the filum terminale rostral to the fistula at the level of L5. Second, the fistulous formation may result from chronic inflammatory reaction and adhesions within the cauda nerve roots caused by diffuse lumbar arachnoiditis. The latter possibility seems to be the preferred opinion.

FTAVFs can be treated by surgery, endovascular treatment, or both. The goal of treatment is the complete obliteration of the fistula with preservation of normal arterial supply to the spinal cord. The key to complete occlusion is obliteration of the proximal vein. Surgical treatment has been the preferred method of treatment with higher complete obliteration rates and low rate of recurrence. Endovascular treatment should be considered as second-line choice because of the difficulty in navigating a microcatheter through the long and tortuous course of the thin ASA; the possibility of reflux of the liquid embolic material into the ASA; the risk of tearing, dissecting, thrombosis, or vasospasm of the ASA during embolization; concerning about recanalization of the fistula; and requiring expertise and experience in neurointerventional procedure.<sup>[1,2,19]</sup>

Interestingly, the significant resorption of the sequestered disc was documented on MRI in our case following obliteration of the FTAVF. Recently, Elkholy *et al.*<sup>[20]</sup> demonstrated that large and/or sequestered discs, extruding into the epidural space, are essential predictors for rapid spontaneous resorption caused by an inflammatory reaction resulting in neovascularization, enzymatic degradation, and macrophage phagocytosis of the disc fragment, recognized as foreign. Significant rim enhancement of the sequestered fragment on MRI with gadolinium is associated with rapid spontaneous resorption. In addition, gradual dehydration, shrinkage, and retraction of herniated nucleus pulposus may be other mechanisms of spontaneous resorption of herniated disc.<sup>[13]</sup> In the present study, the large sequestered fragment from L2–L3 disc herniation may contribute the inflammatory reaction which is crucial to its spontaneous regression. However, the inflammatory response may cause harmful effects into the epidural space, inducing diffuse lumbar arachnoiditis as mentioned earlier.

## Conclusions

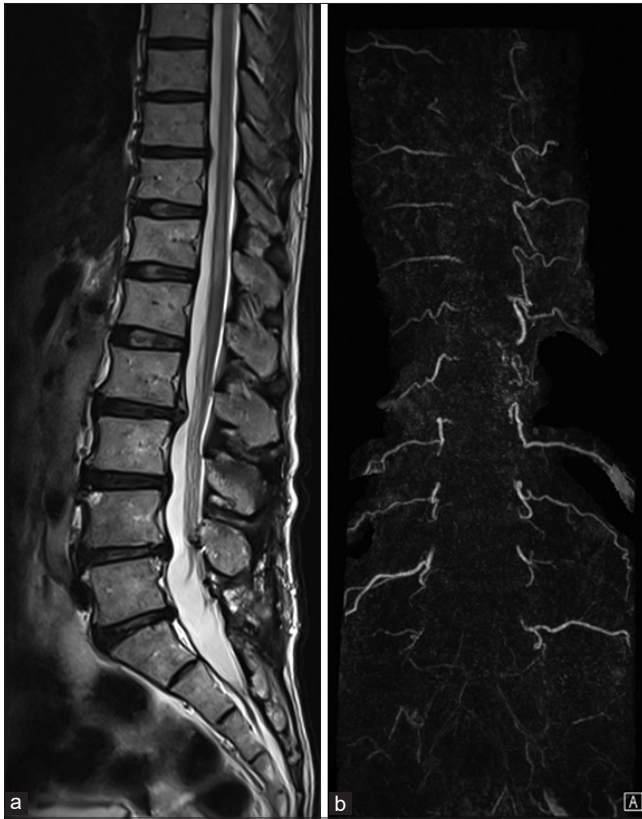The formation of the FTAVF in the present study may result from severe spinal canal stenosis caused by a large disc sequestration blocking the rostral venous drainage of the fistula, or chronic inflammation, and adhesions of the caudal nerve roots from lumbar arachnoiditis. It seems that FTAVF may be of acquired origin by this evidence.

## Consent

The patient has given consent to be enrolled and has his data published.

## Declaration of patient consent

The authors certify that they have obtained all appropriate patient consent forms. In the form, the patient has given his consent for his images and other clinical information to be reported in the journal. The patient understands that name and initials will not be published, and due efforts will be made to conceal the identity, but anonymity cannot be guaranteed.



**Figure 5:** (a) Sagittal T2-weighted image of the thoracolumbar spine obtained 4 months after the operation reveals significant resolution of spinal cord congestion. Spontaneous resorption of the large sequestered L2–3 is noted. (b) Contrast-enhanced magnetic resonance angiography of the thoracolumbar spine confirms complete obliteration of the fistula

### Financial support and sponsorship

Nil.

### Conflicts of interest

There are no conflicts of interest.

### References

- Giordan E, Brinjikji W, Ciceri E, Lanzino G. Arteriovenous fistulae of the filum terminale. *J Neurointerv Surg* 2018;10:191-7.
- Hong T, Park JE, Ling F, terBrugge KG, Tymianski M, Zhang HQ, et al. Comparison of 3 different types of spinal arteriovenous shunts below the conus in clinical presentation, radiologic findings, and outcomes. *AJNR Am J Neuroradiol* 2017;38:403-9.
- Burton CV. Lumbosacral arachnoiditis. *Spine (Phila Pa 1976)* 1978;3:24-30.
- Ransford AO, Harries BJ. Localised arachnoiditis complicating lumbar disc lesions. *J Bone Joint Surg Br* 1972;54:656-65.
- Jackson A, Isherwood I. Does degenerative disease of the lumbar spine cause arachnoiditis? A magnetic resonance study and review of the literature. *Br J Radiol* 1994;67:840-7.
- Quiles M, Marchisello PJ, Tsairis P. Lumbar adhesive arachnoiditis. Etiologic and pathologic aspects. *Spine (Phila Pa 1976)* 1978;3:45-50.
- Epstein JA, Epstein BS, Lavine LS, Rosenthal AD, Decker RE, Carras R. Obliterative arachnoiditis complicating lumbar spinal stenosis. *J Neurosurg* 1978;48:252-8.
- Eisenberg E, Goldman R, Schlag-Eisenberg D, Grinfeld A. Adhesive arachnoiditis following lumbar epidural steroid injections: A report of two cases and review of the literature. *J Pain Res* 2019;12:513-8.
- Delamarter RB, Ross JS, Masaryk TJ, Modic MT, Bohlman HH. Diagnosis of lumbar arachnoiditis by magnetic resonance imaging. *Spine (Phila Pa 1976)* 1990;15:304-10.
- Parenti V, Huda F, Richardson PK, Brown D, Aulakh M, Taheri MR. Lumbar arachnoiditis: Does imaging associate with clinical features? *Clin Neurol Neurosurg* 2020;192:105717.
- Crisi G, Carpeggiani P, Trevisan C. Gadolinium-enhanced nerve roots in lumbar disk herniation. *AJNR Am J Neuroradiol* 1993;14:1379-92.
- McCarron RF, Wimpee MW, Hudkins PG, Laros GS. The inflammatory effect of nucleus pulposus. A possible element in the pathogenesis of low-back pain. *Spine (Phila Pa 1976)* 1987;12:760-4.
- Cunha C, Silva AJ, Pereira P, Vaz R, Gonçalves RM, Barbosa MA. The inflammatory response in the regression of lumbar disc herniation. *Arthritis Res Ther* 2018;20:251.
- S Miyachi E, Izumi T, Matsubara N, Naito T, Haraguchi K, Wakabayashi T. Mechanism of the formation of dural arteriovenous fistula: The role of the emissary vein. *Interv Neuroradiol* 2011;17:195-202.
- Tender GC, Vortmeyer AO, Oldfield EH. Spinal intradural arteriovenous fistulas acquired in late adulthood: Absent spinal venous drainage in pathogenesis and pathophysiology. Report of two cases. *J Neurosurg Spine* 2005;3:488-94.
- Scullen T, Mathkour M, Amenta PS, Dallapiazza RF. Arteriovenous fistula of the filum terminale: A case report and review of the literature. *World Neurosurg* 2019;130:42-9.
- Iampreechakul P, Tirakotai W, Lertbutsayanukul P, Khunvutthidee S, Thammachantha S, Siriwiwimonmas S. Spinal sparganosis coexisting with acquired arteriovenous fistula of the filum terminale. *World Neurosurg* 2020;136:341-7.
- Iampreechakul P, Tirakotai W, Wangtanaphat K, Lertbutsayanukul P, Siriwiwimonmas S. Filum terminale arteriovenous fistula in association with degenerative lumbosacral spinal canal stenosis: Report of 3 cases and review of the literature. *World Neurosurg* 2020;138:231-41.
- Fischer S, Aguilar Perez M, Bassiouni H, Hopf N, Bänzner H, Henkes H. Arteriovenous fistula of the filum terminale: Diagnosis, treatment, and literature review. *Clin Neuroradiol* 2013;23:309-14.
- Elkholy AR, Farid AM, Shanhoot EA. Spontaneous resorption of herniated lumbar disk: Observational retrospective study in 9 patients. *World Neurosurg* 2019;124:E453-9.