

# Sentinel node biopsy in clinical stage I testicular cancer enables early detection of occult metastatic disease

Joost M. Blok\*<sup>†</sup> , J. Martijn Kerst<sup>‡</sup>, Erik Vegt<sup>§</sup>, Oscar R. Brouwer<sup>†</sup> , Richard P. Meijer\*<sup>†</sup> , J.L.H. Ruud Bosch\*, Axel Bex<sup>†</sup>, Henk G. van der Poel<sup>†</sup>  and Simon Horenblas\*<sup>†</sup>

\*Department of Oncological Urology, UMC Utrecht Cancer Center, University Medical Center Utrecht, Utrecht,

<sup>†</sup>Department of Urology, <sup>‡</sup>Department of Medical Oncology, and <sup>§</sup>Department of Nuclear Medicine, The Netherlands Cancer Institute, Amsterdam, The Netherlands

## Objectives

To report the long-term results of the sentinel node (SN) approach in patients with clinical stage I testicular tumours in our facility.

## Patients and Methods

We conducted an analysis of 27 consecutive patients suspected of clinical stage I testicular germ cell tumour (TGCT) and treated with an SN procedure at our tertiary referral centre. SNs were identified using lymphoscintigraphy with or without single-photo-emission computed tomography with CT (SPECT/CT). Patients underwent laparoscopic retroperitoneal SN excision with inguinal orchiectomy. Patients with a tumour-positive SN underwent adjuvant treatment. Follow-up was conducted according to then-current guidelines.

## Results

In two patients, no SNs were visualized on scintigraphy. In the remaining 25 patients, a median (range) of 3 (1–4)

SNs per patient were removed. Two patients showed no malignancy on histopathological examination of the testis. Of the 23 patients diagnosed with TGCT (16 seminomas, seven non-seminomas), three (13.0%) had occult metastatic disease. All 23 patients were without evidence of disease at a median (range) follow-up of 63.9 (29.0–143.4) months.

## Conclusion

The SN procedure allows early identification of patients with occult metastatic disease in clinical stage I TGCT, enabling early treatment.

## Keywords

non-seminomatous germ cell tumour, seminoma, sentinel lymph node biopsy, sentinel lymph node, testicular germ cell tumour, testicular neoplasms, #Testicular Cancer, #tscsm, #uroonc

## Introduction

The majority of patients with testicular germ cell tumours (TGCTs) present with clinical stage I [1]. The predominant management for clinical stage I disease in Europe is inguinal orchiectomy followed by active surveillance [2]; however, a substantial number of patients with clinical stage I tumours have occult metastatic disease at time of presentation, mostly in the retroperitoneal lymph nodes, and will relapse under surveillance. This is the case in ~15–20% of seminomas and 30% of non-seminomatous germ cell tumours (NSGCTs) [2–4]. Risk-adapted strategies, based on risk prognosticators, have been developed to anticipate occult metastatic disease and to decide about adjuvant treatment strategies [5–8]. Nevertheless, considerable over- and undertreatment still exists [2].

A major limitation to diagnose occult metastatic disease is the inability of standard imaging techniques to detect microscopic nodal tumour spread. TGCTs have a strong tendency for lymphatic dissemination [8–10]. The sentinel node (SN) concept is based on the assumption of a sequential dissemination of metastases through the lymphatic system: from tumour to first-echelon lymph nodes (SNs) and subsequently to other regional nodes (higher-echelon nodes). The hypothesis underlying the SN procedure is that patients without metastases in the SNs have no metastases in the rest of the lymphatic basin. SN procedures are routinely used in several types of cancer, such as breast cancer, penile cancer and melanoma [11].

The feasibility of the SN procedure in TGCTs has already been established in several smaller series [12–15], including a

prospective study from our institution [15]. In the present paper, we report the long-term results of this approach, with additional data from a patient registry.

## Patients and Methods

The first 10 patients were included in a feasibility study (study number M00LMT), with appropriate institutional ethics approval. Subsequent patients were included in a patient registry to expand the safety data. The feasibility study received ethical approval and patients signed informed consent. All patients with clinical stage I testicular tumours referred to the Netherlands Cancer Institute between September 2001 and February 2015 were asked to participate.

### Lymphoscintigraphy Procedure

After local anaesthesia by means of a funicular block with lidocaine 2%, a single dose of  $^{99m}\text{Tc}$ -nanocolloid (Amersham Cygne, Eindhoven, the Netherlands) was injected with a fine needle into the affected testicular parenchyma. The mean (range) administered dose was 78.9 (54.0–109.8) MBq in a volume of 0.10–0.20 mL.

Immediately after injection, anterior and lateral dynamic images were obtained with a dual-head gamma camera to visualize the lymphatic flow and identify early draining lymph nodes. After the dynamic scan, static planar images were acquired to differentiate SNs from higher-echelon nodes. Two hours after tracer injection, additional planar images were acquired to identify slower draining SNs and unexpected drainage patterns. In patients treated from 2006 onwards (patients 6–25) additional single-photo-emission CT with CT (SPECT/CT) was performed in the same session.

The first node(s) in each nodal basin appearing on early planar imaging were considered to be the SN(s). Nodes appearing later in the same basin were considered to be higher-echelon nodes. An additional first node in another basin was also considered to be an SN.

### Surgical Procedure

The surgical procedure was performed by one of four urological surgeons. Each surgeon had > 10 years' experience in laparoscopic retroperitoneal surgery. Laparoscopic sentinel node excision and open inguinal orchiectomy were performed in the same surgical setting, within 6 h after injection of the radioactive tracer. SNs were intra-operatively localized using a laparoscopic gamma probe. In addition, a portable gamma camera (Sentinella, Oncovision) was used in a number of patients (patients 10 and 12–22).

After resection of the SNs, the gamma probe and gamma camera were used to make sure that no relevant nodes were

overlooked and left behind. A remaining radioactive node at the side of an SN was considered to be part of a cluster of SNs and was resected. If no clear distinction between first- and second-echelon nodes could be made, all potential SNs were resected. After removal of the SN(s), an open inguinal orchiectomy was performed.

Resected lymph nodes were fixed in formalin, bisected, paraffin-embedded and cut at a minimum of six levels at 50–150- $\mu\text{m}$  intervals. They were then pathologically examined, which included haematoxylin and eosin staining, and immunohistochemistry staining.

### Follow-up

Any next step in the management of the patient was discussed at a multidisciplinary board meeting, consisting of a urologist, medical oncologist, pathologist, radiation oncologist, nuclear medicine physician and radiologist. Follow-up was carried out according to the then-current European Association of Urology guidelines and did not differ from that of patients with clinical stage I TGCTs treated with active surveillance [16]. Follow-up included clinical examination, measurement of serum tumour markers ( $\alpha$ -fetoprotein, HCG and lactate dehydrogenase), abdominal/thoracic CT scanning, or chest X-rays. Tumour markers were measured every month in the first year, every 2 months in the second year, every 3–4 months in the third year and biannually in the fourth and fifth year. CT imaging and chest X-rays were performed at least biannually in the first and second year, and yearly thereafter. After 5 years, the follow-up was at the discretion of the clinician, but patients were encouraged to participate for at least 10 years. Follow-up duration was measured as time between surgery and last follow-up visit.

## Results

Between September 2001 and February 2015, 27 consecutive patients with clinical stage I testicular tumours were included. The median (range) age was 33.1 (20.8–52.4) years. Sixteen patients (59.3%) had a left-sided tumour and 11 (40.7%) had a right-sided tumour. Study results are shown in Table 1.

Six patients (22.2%) had a history of contralateral testicular tumour. Two of these patients (patients 3 and 25) had had a stage I NSGCT and had been treated with active surveillance after orchiectomy. Two patients (patients 13 and 14) had had a stage I seminoma and had been treated with adjuvant radiotherapy. In both patients, the radiation field did not include the localization of the SN of their current testicular tumour. One patient (patient 10, stage Is) had received three cycles of bleomycin, etoposide, cisplatin (BEP) and one patient (patient 22, stage I) had been treated with a modified-template laparoscopic retroperitoneal lymph node dissection

Table 1 Study results.

Patient	Age, years	Tumour side	S-stage	pT-stage	Pathology	Risk factors	Number of resected SNs	SN metastasis	Adjuvant treatment	Lymph node recurrence	Follow-up, months
1	44.6	Left	0	N/A	Benign Leydig cell	N/A	2	–	–	–	99.4
2	26.4	Left	1	1	SGCT	>4 cm	3	–	–	–	143.4
3	33.2	Left	1	1	NSGCT	>4 cm; EC >50%; RTI	4	+	BEP ×4	–	121.1
4	48.6	Left	0	1	SGCT	RTI	1	–	–	–	89.7
5	44.0	Right	1	N/A	Infarction	N/A	1	–	–	–	3.0
6	46.4	Left	0	1	SGCT	None	1	–	–	–	59.5
7	25.9	Right	1	1	SGCT	>4 cm; RTI	2	–	–	–	113.6
8	30.9	Right	0	2	SGCT	LVI	2	–	–	–	63.9
9	30.6	Left	1	1	SGCT	>4 cm	2	–	–	–	119.3
10	33.1	Right	1	2	NSGCT	RTI; LVI	3	–	–	–	100.1
11	40.3	Left	0	1	SGCT	>4 cm	1	–	Carbo ×1	–	62.8
12	47.6	Right	0	3	SGCT	RTI; LVI	3	+	CEB ×4	–	88.7
13	46.8	Right	0	1	SGCT	RTI	2	–	–	–	62.0
14	35.1	Left	0	1	SGCT	None	4	–	–	–	71.5
15	25.5	Left	1	2	NSGCT	LVI	3	–	–	–	66.1
16	32.6	Right	1	1	NSGCT	None	3	–	–	–	62.2
17	52.4	Left	0	1	SGCT	None	2	–	–	–	65.4
18	42.2	Right	0	1	SGCT	RTI	2	–	–	–	66.1
19	27.8	Left	0	1	NSGCT	EC >50%; RTI	3	–	–	–	60.2
20	32.4	Left	0	1	NSGCT	None	3	–	–	–	58.3
21	32.5	Right	0	1	NSGCT	>4 cm; EC >50%	4	–	–	–	60.4
22	30.7	Left	0	1	SGCT	None	3	–	–	–	58.5
23	39.1	Right	0	1	SGCT	>4 cm; RTI	4	–	–	–	55.3
24	35.1	Left	0	1	SGCT	None	3	–	–	–	29.0
25	32.7	Left	0	1	SGCT	RTI	2	+	Carbo ×2	–	30.9

BEP ×4, 4 cycles of bleomycin, etoposide, cisplatin; Carbo ×1, 1 cycle of carboplatin; CEB ×4, 4 cycles of carboplatin, etoposide, bleomycin; EC, embryonal carcinoma; LVI, lymphovascular invasion; N/A, not applicable; NSGCT, non-seminomatous germ cell tumor; RTI, rete testis invasion; SN, sentinel node; SGCT, seminoma germ cell tumour; +, positive; –, negative.

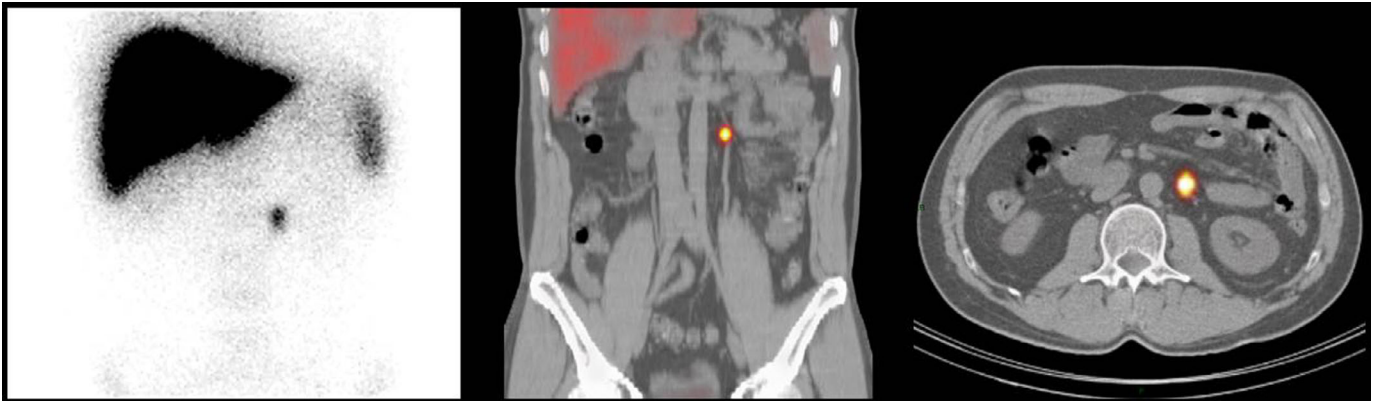
(RPLND), not including the site of the SN of his current tumour.

In two patients an SN was not shown on scintigraphy. One of these patients showed immediate flow of the radiocolloid on the dynamic scan, with high accumulation in the liver, suggesting venous drainage from a hyperaemic tumour. Because the urologist expected to be able to find the SN intra-operatively with the gamma probe, a laparoscopic procedure was initiated; however, no SN was found and a laparoscopic modified-template lymph node dissection was performed. All excised lymph nodes were free of microscopic disease and the patient showed no evidence of disease after 10 years of follow-up. The second patient showed no lymphatic flow of the radiocolloid at all; therefore, laparoscopic SN detection was not deemed feasible and he was treated with orchiectomy only. This patient was lost to follow-up after 33 months without evidence of disease. Both patients were excluded from further analysis.

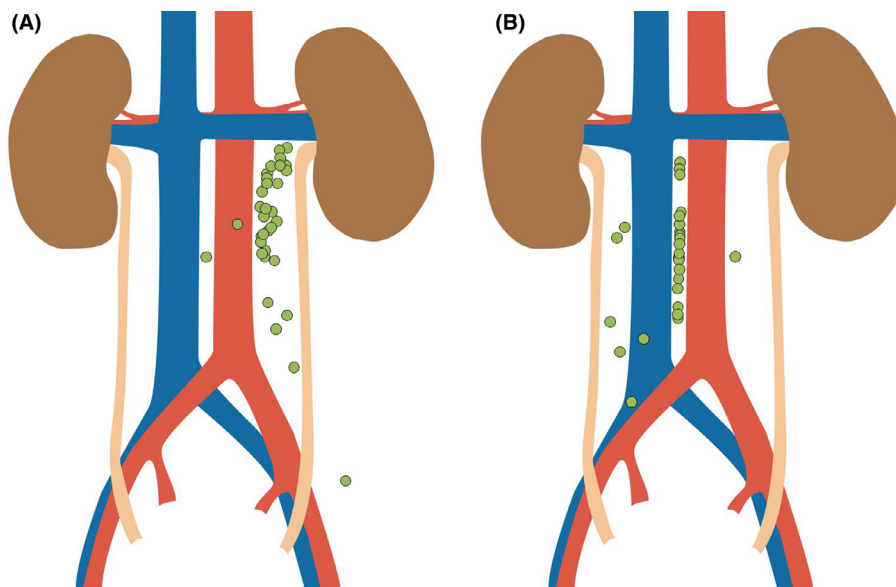
The remaining 25 patients showed one or more SN(s) on scintigraphy and/or SPECT/CT (Fig. 1), and underwent

laparoscopic SN resection with synchronous inguinal orchiectomy. Patient characteristics and study results are presented in Table 1. A median (range) of 3 (1–4) SNs per patient were removed and histologically examined. In the 15 patients with a left-sided tumour, a total of 37 SNs were removed from the left para-aortic (34 nodes), pre-aortic (one node) interaortocaval (one node) and inguinal (one node, patient with history of orchidopexy) regions. In the 10 patients with a right-sided tumour, a total of 26 SNs were removed from the interaortocaval (19 nodes), right paracaval (four nodes), precaval (one node), left para-aortic (one node) and pre-iliac (one node) regions. The distribution of resected SNs is shown in Fig. 2. In addition to the 63 definite SNs, 19 higher-echelon nodes were resected in 11 patients and histologically examined. In seven of these patients (14 nodes) these nodes were merely resected in the same surgical specimen as the SNs. In four patients (five nodes) the nodes were resected because it could not be determined whether they were SNs or higher-echelon nodes; thus, a total of 82 lymph nodes were resected and histologically examined (median of 3 per patient, range 1–6).

**Fig. 1** Lymphoscintigraphy with planar (left) and single-photon-emission CT with CT (middle and right) images of a single sentinel node in the left para-aortic region.



**Fig. 2** Fusion image of sentinel node localizations of left-sided (A) and right-sided (B) testicular tumour.



Pathological examination of the testicular specimen showed seminoma in 16 patients (64.0%) and non-seminoma in seven patients (28.0%). In two patients (8.0%), pathology showed no malignancy: one patient had a benign Leydig cell tumour and another patient showed infarction without any signs of malignancy. The primary tumour was radically resected in all patients except one (patient 12). This patient had spermatic cord invasion of the tumour (T3 tumour) with tumour cells in the surgical margin. Of the 23 patients with TGCTs, three (13.0%) showed occult metastases in a total of six SNs.

All patients with a positive SN received adjuvant systemic treatment with either four cycles of BEP, four cycles of carboplatin, etoposide, bleomycin (CEB; microscopically irradical resection of primary tumour), or two cycles of

carboplatin. One patient without occult metastatic disease received one cycle of carboplatin at his own request.

Three Clavien–Dindo grade I complications were reported. Two patients had postoperative pain for which they received additional analgesic medication. One patient had urinary retention after removal of his Foley catheter for which he was in-and-out-catheterized twice. No other complications were noted.

All 23 patients with TGCTs were without evidence of disease at a median (range) follow-up of 63.9 (29.0–143.4) months.

## Discussion

We report the long-term results of a series of patients undergoing a laparoscopic SN procedure for testicular tumour



in clinical stage I. Thirteen percent (3/23) of patients with TGCTs showed occult metastatic disease in at least one SN. No patient relapsed after a median follow-up of 63.9 months.

This study shows that an SN procedure enables early identification of patients with occult metastatic disease in clinical stage I TGCT. With no false-negative procedures, no serious complications or side effects so far, the procedure is safe and well tolerated.

The prognosis of clinical stage I TGCT is very favourable and cancer-specific survival rates as high as 100% have been reported [17–19]; however, there is no international consensus on how to best manage these patients. In contrast to US guidelines, RPLND is not recommended for clinical stage I patients in Europe [2,20]. European guidelines currently recommend active surveillance for most patients, as it minimizes the morbidity associated with lymphadenectomy [21,22]; however, up to 20% of patients with seminomas and 30% of patients with NSGCTs have occult metastatic disease and will relapse during active surveillance [2,3,23]. In case of relapse, patients are treated with three to four cycles of BEP or radiotherapy. These treatment regimens cause serious short- and long-term side effects. For example, patients with TGCTs treated with chemotherapy have a 1.5–1.9-fold higher chance of cardiovascular disease and a 2.1-fold higher chance of a secondary malignancy [24,25]. Because of these late effects, the relative survival of patients with localized disease keeps declining even beyond 30 years of follow-up [26].

To overcome this problem, a risk-adapted strategy, in which only high-risk patients are treated with adjuvant chemotherapy, has been advocated in European guidelines [2]. Patients with a seminoma >4 cm and rete testis invasion have a 5-year risk of relapsing of 31.5%, compared to 12.2% in patients without risk factors [5]. This means that using this risk-adapted strategy, 68.5% of high-risk patients unnecessarily receive adjuvant chemotherapy, while 12.2% of low-risk patients may need adjuvant treatment, but do not receive it.

Patients with NSGCTs with lymphovascular invasion have a 48% chance of developing metastatic disease, whereas patients without lymphovascular invasion have a 14–22% chance of relapsing [6–8,23,27]. As with seminoma, ~52% of patients with high-risk NSGCT receive adjuvant treatment without any benefit, while 14–22% of low-risk patients are undertreated. These rates of over- and under-treatment show that there is room for improvement in the selection of patients who need adjuvant therapy.

With an SN approach, candidates for adjuvant treatment for seminoma and non-seminoma could be identified based on objective histopathological findings; however, it is unknown how to best manage patients with occult metastatic disease in their SN. The present study did not involve performing a

complete RPLND; therefore, the SN approach for testicular cancer is currently a non-validated diagnostic procedure. Several management strategies can be discussed and would require confirmation in clinical trials.

Considering the microscopic nature of the disease stage, one option would be to regard SN-positive patients as having high-risk stage I disease which may be treated adequately with a lower dose of adjuvant treatment: one cycle of carboplatin for patients with seminomas and one cycle of BEP for patients with NSGCTs [2,28]. Adjuvant treatment at this early stage might prevent relapse in SN-positive patients, thereby avoiding the necessity of multiple cycles of chemotherapy and reducing short- and long-term side effects [29,30].

Alternatively, patients who had removal of early nodal disease in their SN may be candidates for active surveillance, while those with negative SN may benefit from a potential reduction of follow-up visits and costly investigations. Since no relapses were observed in patients without tumour-positive SNs, the need for intensive follow-up protocols in this group may be reduced and retroperitoneal imaging might no longer be necessary. This requires a larger study, however, with additional RPLND to confirm absence of further nodal involvement. False-negative SN procedures (patients who relapse in the retroperitoneum after a tumour-negative SN procedure) may be the limiting factor for this technique. Despite the fact that no false-negative procedures were observed in the present series, much larger studies are needed to determine precisely the risk of false-negative procedures.

No serious complications occurred in the present series, although the safety of the procedure needs to be investigated within a larger study population. It is unlikely, however, that side effects would differ from what is generally known from recent primary laparoscopic RPLND series (postoperative complication rate 0–9.8%) [31]. In a large series by Nicolai *et al.* [32] only 8/221 patients (3.6%) who underwent laparoscopic RPLND had a complication with Clavien–Dindo grade >2. Nevertheless, patients with a suspicion of TGCT but without evidence of TGCT on testicular pathology (two patients in our series) were unnecessarily subjected to an invasive procedure.

The SN approach is well established for several other malignancies, but there is very little literature on the use in TGCT. The feasibility of the procedure was first demonstrated in 2002 by Tanis *et al.* [12]. Two studies have described the follow-up results of this approach. Satoh *et al.* [14] reported on a series of 22 patients with clinical stage I testicular tumours of whom two had a tumour-positive SN and were treated with two cycles of BEP without relapse at 31 and 29 months follow-up; however, two patients without metastases on histopathological examination showed relapse

at 10 and 20 months of follow-up. The authors attributed this to an intra-operative detection error and an aberrant route of lymphatic dissemination [14]. That study from 2005 used preoperative planar lymphoscintigraphy with intra-operative gamma probe detection, but no SPECT/CT imaging. SPECT/CT enables more exact preoperative localization of the SNs, making it easier to find the SNs and potentially decreasing the false-negative rate. In a case series of 10 patients by Brouwer et al. [15] one patient with seminoma had a positive SN and was treated with four cycles of CEB. During a median (range) follow-up of 21 (2–50) months, no patient relapsed. Results in our updated series are in line with this early report from our institution.

In five patients with TGCTs, follow-up was <5 years and the minimum duration of follow-up was 29.0 months. As the chance of relapse after 2 years of negative follow-up is < 6%, we believe that the follow-up duration in the present study was sufficient [33,34].

The inconsistency in adjuvant chemotherapy courses for node-positive patients can be explained by the limited experience with the SN procedure in TGCTs. As the exact significance of an occult metastasis is still unclear, the best treatment approach is undetermined; therefore, throughout the duration of the study, oncologists preferred different chemotherapy regimens. The present study was, however, focused on the long-term outcomes of patients with SN-negative disease.

The relatively long period needed to include this number of patients and the high proportion of patients with a history of contralateral TGCTs is attributable to the referral system of our institute. The Netherlands Cancer Institute is a tertiary referral centre and mostly treats large-volume disease. In addition, orchidectomies are often performed at diagnosis in the referring hospitals.

The next step in the development of this procedure is to investigate whether patients with a negative SN have no risk of relapsing, with a larger sample size and in a prospective study design. To achieve this goal, we have initiated a prospective clinical trial (www.clinicaltrials.gov identifier: NCT03448822).

We conclude that the SN procedure is feasible and safe for clinical stage I TGCT, and enables detection of microscopic lymph node invasion at an early stage. This approach could potentially lead to less intensive follow-up protocols in node-negative patients and reduced systemic treatment of microscopic disease. Larger prospective studies are needed to further substantiate these findings.

## Acknowledgements

We thank Sjoerd Blok for his help in creating Fig. 2.

## Conflict of Interest

None declared.

## References

- Rajpert-De Meyts E, McGlynn KA, Okamoto K, Jewett MAS, Bokemeyer C. Testicular germ cell tumours. *Lancet* 2016; 10029: 1762–74
- Albers P, Albrecht W, Algaba F et al. Guidelines on testicular cancer: 2015 update. *Eur Urol* 2015; 6: 1054–68
- Kollmannsberger C, Tandstad T, Bedard PL et al. Patterns of relapse in patients with clinical stage I testicular cancer managed with active surveillance. *J Clin Oncol* 2015; 1: 51–7
- Pierorazio PM, Albers P, Black PC et al. Non-risk-adapted surveillance for stage I testicular cancer: critical review and summary. *Eur Urol* 2018; 6: 899–907
- Warde P, Specht L, Horwich A et al. Prognostic factors for relapse in stage I seminoma managed by surveillance: a pooled analysis. *J Clin Oncol* 2002; 22: 4448–52
- Albers P, Siener R, Kliesch S et al. Risk factors for relapse in clinical stage I nonseminomatous testicular germ cell tumors: results of the German testicular cancer study group trial. *J Clin Oncol* 2003; 8: 1505–12
- Klepp O, Dahl O, Flodgren P et al. Risk-adapted treatment of clinical stage I non-seminoma testis cancer. *Eur J Cancer* 1997; 7: 1038–44
- Krege S, Beyer J, Souchon R et al. European Consensus Conference on diagnosis and treatment of germ cell cancer: a report of the second meeting of the European Germ Cell Cancer Consensus group (EGCCCG): part I. *Eur Urol* 2008; 3: 478–96.
- Spermon JR, Roeleveld TA, van der Poel HG et al. Comparison of surveillance and retroperitoneal lymph node dissection in stage I nonseminomatous germ cell tumors. *Urology* 2002; 6: 923–9
- von der Maase H, Specht L, Jacobsen GK et al. Surveillance following orchidectomy for stage I seminoma of the testis. *Eur J Cancer* 1993; 14: 1931–4
- Jakobsen JK. Sentinel node biopsy in uro-oncology: a history of the development of a promising concept. *Urol Oncol*. 2015; 11: 486–93
- Tanis PJ, Horenblas S, Olmos RA, Hoefnagel CA, Nieweg OE. Feasibility of sentinel node lymphoscintigraphy in stage I testicular cancer. *Eur J Nucl Med Mol Imaging* 2002; 5: 670–3
- Ohshima C, Chiba Y, Yamazaki T, Endoh M, Hoshi S, Arai Y. Lymphatic mapping and gamma probe guided laparoscopic biopsy of sentinel lymph node in patients with clinical stage I testicular tumor. *J Urol* 2002; 4(Pt 1): 1390–5
- Satoh M, Ito A, Kaiho Y et al. Intraoperative, radio-guided sentinel lymph node mapping in laparoscopic lymph node dissection for Stage I testicular carcinoma. *Cancer* 2005; 10: 2067–72
- Brouwer OR, Valdes Olmos RA, Vermeeren L, Hoefnagel CA, Nieweg OE, Horenblas S. SPECT/CT and a portable -camera for image-guided laparoscopic sentinel node biopsy in testicular cancer. *J Nucl Med* 2011; 4: 551–4
- Laguna MP, Pizzocaro G, Klepp O et al. EAU guidelines on testicular cancer. *Eur Urol* 2001; 2: 102–10
- Tandstad T, Smaaland R, Solberg A et al. Management of seminomatous testicular cancer: a binational prospective population-based study from the Swedish Norwegian testicular cancer study group. *J Clin Oncol* 2011; 6: 719–25
- Aparicio J. Multicenter study evaluating a dual policy of postorchidectomy surveillance and selective adjuvant single-agent carboplatin for patients with clinical stage I seminoma. *Ann Oncol* 2003; 6: 867–72
- Kollmannsberger C, Moore C, Chi KN et al. Non-risk-adapted surveillance for patients with stage I nonseminomatous testicular germ-cell tumors: diminishing treatment-related morbidity while maintaining efficacy. *Ann Oncol* 2010; 6: 1296–301

- 20 Motzer RJ, Jonasch E, Agarwal N et al. Testicular cancer, version 2.2015. *J Natl Compr Canc Netw* 2015; 6: 772–99
- 21 Nichols CR, Roth B, Albers P et al. Active surveillance is the preferred approach to clinical stage I testicular cancer. *J Clin Oncol* 2013; 28: 3490–3
- 22 Oldenburg J, Fossa SD, Nuver J et al. Testicular seminoma and non-seminoma: ESMO Clinical Practice Guidelines for diagnosis, treatment and follow-up. *Ann Oncol* 2013; 24(suppl 6): vi125–32
- 23 Read G, Stenning SP, Cullen MH et al. Medical Research Council prospective study of surveillance for stage I testicular teratoma. Medical Research Council Testicular Tumors Working Party. *J Clin Oncol* 1992; 11: 1762–8
- 24 van den Belt-Dusebout AW, de Wit R, Gietema JA et al. Treatment-specific risks of second malignancies and cardiovascular disease in 5-year survivors of testicular cancer. *J Clin Oncol* 2007; 28: 4370–8
- 25 van den Belt-Dusebout AW, Nuver J, de Wit R et al. Long-term risk of cardiovascular disease in 5-year survivors of testicular cancer. *J Clin Oncol* 2006; 3: 467–75
- 26 Kvammen O, Myklebust TA, Solberg A et al. Long-term relative survival after diagnosis of testicular germ cell tumor. *Cancer Epidemiol Biomarkers Prev* 2016; 5: 773–9
- 27 Fung CY, Kalish LA, Brodsky GL, Richie JP, Garnick MB. Stage I nonseminomatous germ cell testicular tumor: prediction of metastatic potential by primary histopathology. *J Clin Oncol* 1988; 9: 1467–73
- 28 Westermann DH, Schefer H, Thalmann GN, Karamitopoulou-Diamantis E, Fey MF, Studer UE. Long-term followup results of 1 cycle of adjuvant bleomycin, etoposide and cisplatin chemotherapy for high risk clinical stage I nonseminomatous germ cell tumors of the testis. *J Urol* 2008; 1: 163–6
- 29 Powles T, Robinson D, Shamash J, Moller H, Tranter N, Oliver T. The long-term risks of adjuvant carboplatin treatment for stage I seminoma of the testis. *Ann Oncol* 2007; 3: 443–7
- 30 Vidal AD, Thalmann GN, Karamitopoulou-Diamantis E, Fey MF, Studer UE. Long-term outcome of patients with clinical stage I high-risk nonseminomatous germ-cell tumors 15 years after one adjuvant cycle of bleomycin, etoposide, and cisplatin chemotherapy. *Ann Oncol* 2015; 2: 374–7
- 31 Chalfin HJ, Ludwig W, Pierorazio PM, Allaf ME. Robotic primary RPLND for stage I testicular cancer: a review of indications and outcomes. *Curr Urol Rep.* 2016; 5: 41
- 32 Nicolai N, Tarabelloni N, Gasperoni F et al. Laparoscopic retroperitoneal lymph node dissection for clinical stage I nonseminomatous germ cell tumors of the testis: safety and efficacy analyses at a high volume center. *J Urol* 2018; 3: 741–7
- 33 Mortensen MS, Lauritsen J, Kier MGG et al. Late relapses in stage I testicular cancer patients on surveillance. *Eur Urol* 2016; 2: 365–71
- 34 Nayan M, Jewett MAS, Hosni A et al. Conditional risk of relapse in surveillance for clinical stage I testicular cancer. *Eur Urol* 2017; 1: 120–7

**Correspondence:** Simon Horenblas, Netherlands Cancer Institute, Post box 90203, 1006 BE Amsterdam, The Netherlands.

**e-mail:** s.horenblas@nki.nl

**Abbreviations:** BEP, bleomycin, etoposide, cisplatin; CEB, carboplatin, etoposide, bleomycin; NSGCT, non-seminomatous germ cell tumour; RPLND, retroperitoneal lymph node dissection; SN, sentinel node; SPECT, single-photo-emission CT; TGCT, testicular germ cell tumour.