

CASE IMAGE

Unilateral silent sinus syndrome: A case report

Michele Gaffuri^{1,2}  | Domenico di Furia^{1,2} | Ludovica Battilocchi^{1,2} | Sara Torretta^{1,2} | Remo Accorona¹ | Lorenzo Pignataro^{1,2}

¹Department of Otolaryngology and Head and Neck Surgery, Fondazione IRCCS Ca' Granda Ospedale Maggiore Policlinico, Milan, Italy

²Department of Clinical Sciences and Community Health, Università degli Studi di Milano, Milan, Italy

Correspondence

Michele Gaffuri, Department of Otolaryngology and Head and Neck Surgery, Fondazione IRCCS Ca' Granda Ospedale Maggiore Policlinico, Milan, Italy, Via Francesco Sforza 35, Milan, 20122, Italy.

Email: michele.gaffuri@policlinico.mi.it

Funding information

This research did not receive any specific grant from funding agencies in the public, commercial, or not-for-profit sectors

Abstract

Silent sinus syndrome (SSS) is a rare clinical condition, commonly unilateral, secondary to the obstruction of the osteomeatal complex, subsequent negative pressure in the maxillary sinus, and collapse of the orbit floor and sinus walls. We describe a case of unilateral SSS treated by means of functional endoscopic sinus surgery.

KEYWORDS

ear, nose and throat, ophthalmology

1 | CASE REPORT

A 48-year-old male patient was referred to our department due to a slowly progressing left hypoglobus with enophthalmos and facial asymmetry (Figure 1A,B). No other nasal or ophthalmological symptoms were reported. Clinical history was negative for trauma or previous surgery. Nasal endoscopy showed a remodeled middle turbinate, lateralization of the medial wall of the maxillary sinus, the

ostium closed by a fibrous membrane (Figures 2A,B,C). A computed tomography (CT) scan showed opacification of the left maxillary sinus with collapsed walls and orbital floor (Figure 3A,B). A magnetic resonance imaging ruled out any orbital or meningeal pathology. Diagnosis of SSS was made,^{1,2} and a unilateral FESS was performed: After medialization of the middle turbinate, an enlarged antrostomy was performed; the sinus was occupied by hyperplastic mucosa and thick mucus (Figure 4), and

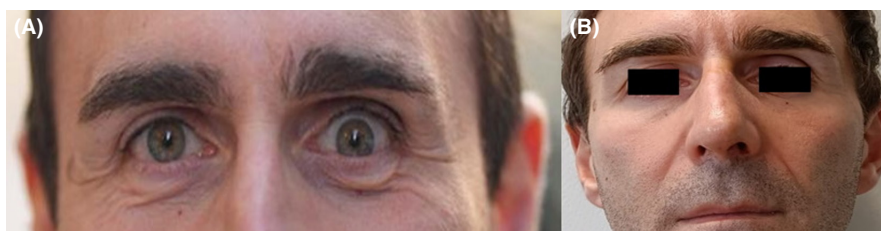


FIGURE 1 Patient presented a left hypoglobus with enophthalmos (A) and facial asymmetry (B)

This is an open access article under the terms of the [Creative Commons Attribution-NonCommercial-NoDerivs](https://creativecommons.org/licenses/by-nc-nd/4.0/) License, which permits use and distribution in any medium, provided the original work is properly cited, the use is non-commercial and no modifications or adaptations are made.

© 2022 The Authors. *Clinical Case Reports* published by John Wiley & Sons Ltd.

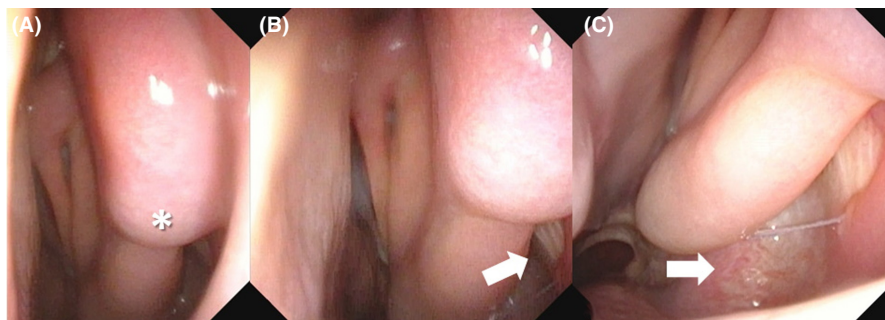


FIGURE 2 Nasal endoscopy showed a remodeled (*asterisk*) middle turbinate (A), the maxillary ostium (B) closed by a fibrous membrane (*arrow*), lateralization (*arrow*) of the medial wall of the maxillary sinus (C) secondary to sinus negative pressure

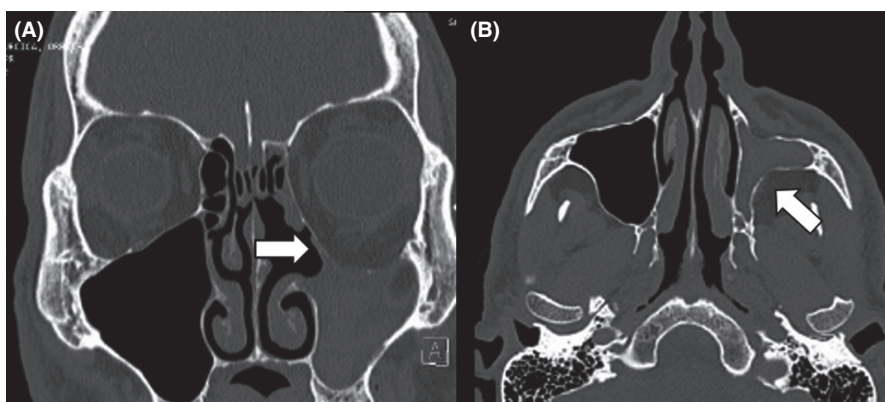


FIGURE 3 Coronal (A) CT scan showed opacification of the left maxillary sinus with collapsed orbital floor (*arrow*); an axial CT scan showed maxillary sinus hypoplasia (B) with collapsed bony walls (*arrow*)

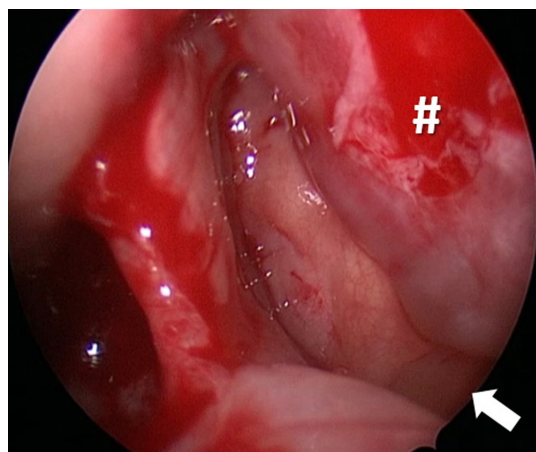


FIGURE 4 Intraoperative visualization of the left maxillary sinus through an enlarged antrostomy: the orbital floor was collapsed into the sinus that was occupied by hyperplastic mucosa (*hash mark*) and thick mucus (*arrow*)

removed by means of gentle aspiration. The collapsed orbital floor was covered by a layer of sinus mucosa: Considering the integrity of the orbital floor, a simultaneous orbital reconstruction was not performed. No complications occurred, and the patient was dismissed the day after surgery. Nasal endoscopy, performed one week and three months after surgery, showed a restored patency of the antrum, associated with an improvement of hypoglobus and enophthalmos.

CONFLICT OF INTEREST

The authors have no conflicts of interest to declare.

AUTHOR CONTRIBUTIONS

MG, and DdF contributed to clinical management of the patient, study conception, acquisition and analysis of data, and manuscript draft. RA and LB: contributed to clinical management of the patient, acquisition and analysis of data, and manuscript draft. MG, LP, and ST: critically revised the manuscript. All the authors involved in the review of the final draft of the manuscript and the approval of the manuscript's submission.

ETHICAL APPROVAL

Written informed consent was obtained from the patient at the time of admission. The described procedure was in accordance with the ethical standards of the institutional and national research committee, and with the 1964 Helsinki declaration and its later amendments or comparable ethical standards.

CONSENT

Written informed consent was obtained from the patient for the publication of this case report and the accompanying images.

DATA AVAILABILITY STATEMENT

The data that support the findings of this study are available on request from the corresponding author. The

data are not publicly available due to privacy or ethical restrictions.

ORCID

Michele Gaffuri  <https://orcid.org/0000-0002-5435-685X>

REFERENCES

1. Fiorenza UD, Spoldi C, Nekrasova L, et al. Prevalence of maxillary sinus hypoplasia and silent sinus syndrome: a radiological cross-sectional retrospective cohort study. *Am J Rhinol Allergy*. 2022;36(1):123-128. doi: [10.1177/19458924211029418](https://doi.org/10.1177/19458924211029418)

2. Stryjewska-Makuch G, Goroszkiewicz K, Szymocha J, Lisowska G, Misiołek M. Etiology, early diagnosis and proper treatment of silent sinus syndrome based on review of the literature and own experience. *J Oral Maxillofac Surg*. 2022;80(1):113.e1-113.e8. doi: [10.1016/j.joms.2021.08.166](https://doi.org/10.1016/j.joms.2021.08.166)

How to cite this article: Gaffuri M, di Furia D, Battilocchi L, Torretta S, Accorona R, Pignataro L. Unilateral silent sinus syndrome: A case report. *Clin Case Rep*. 2022;10:e05794. doi:[10.1002/ccr3.5794](https://doi.org/10.1002/ccr3.5794)