

Endoscopic submucosal dissection with ductotomy for the resection of a gastric duplication cyst with a communicating duct

Cem Simsek, MD, Marvin Ryou, MD, Christopher C. Thompson, MD, Hiroyuki Aihara, MD, PhD



CASE PRESENTATION

A 40-year-old otherwise healthy woman with persistent upper abdominal pain was found to have a 3-cm subepithelial lesion in the prepyloric area and was referred to our center (Fig. 1). EUS showed an anechoic cyst in the submucosa with well-defined outer sonographic borders suggesting a gastric duplication cyst (GDC) (Fig. 2). The cyst was completely aspirated and yielded 40 mL of serous fluid with negative cytology for malignancy. The patient's symptoms resolved for 3 weeks but then recurred. A CT scan showed the cystic lesion with diameters of $3.2 \times 1.2 \times 1.1$ cm. Therefore, the decision was made to remove the cyst with endoscopic submucosal dissection (ESD).

ESD was performed with the patient under general anesthesia (Video 1, available online at www.giejournal.org). A single-channel gastroscope (EG-760Z, Fujifilm, Tokyo, Japan), an electrocautery generator (VIO 300D, Erbe, Tübingen, Germany), and a 2-mm needle-knife (OR-ISE ProKnife, Boston Scientific, Marlborough, Mass, USA) were used. First, the lesion's borders were demarcated

with closed needle-knife under soft-coagulation mode and a submucosal injection was performed (Fig. 3). Then, 2 mucosal incisions were made at the pyloric and oral sides of the lesion. This was followed by submucosal tunneling dissection to expose the cyst wall (Fig. 4). While the dissection plane was being extended underneath the cyst, we encountered a 2-mm vessel-like structure that appeared to originate from the cyst and enter into the muscularis propria. The dissection was continued until the ductular structure was completely visualized (Fig. 5A and B). After achieving complete skeletonization of the duct, two 11-mm DuraClips (ConMed, Utica, NY, USA) were deployed at its distal and proximal sides, and the duct was then cut through by using a HookKnife (Olympus America, Center Valley, Pa, USA) (Fig. 6A and B). Finally, the lesion was completely dissected in an en bloc fashion (Fig. 7A and B). The total procedure time was 73 minutes. Histologic examination of the samples revealed a cyst with an inner gastric mucosal lining and an outer muscle layer, and a duct communicating with the cyst and extending to the deeper layer toward the muscularis propria, with the

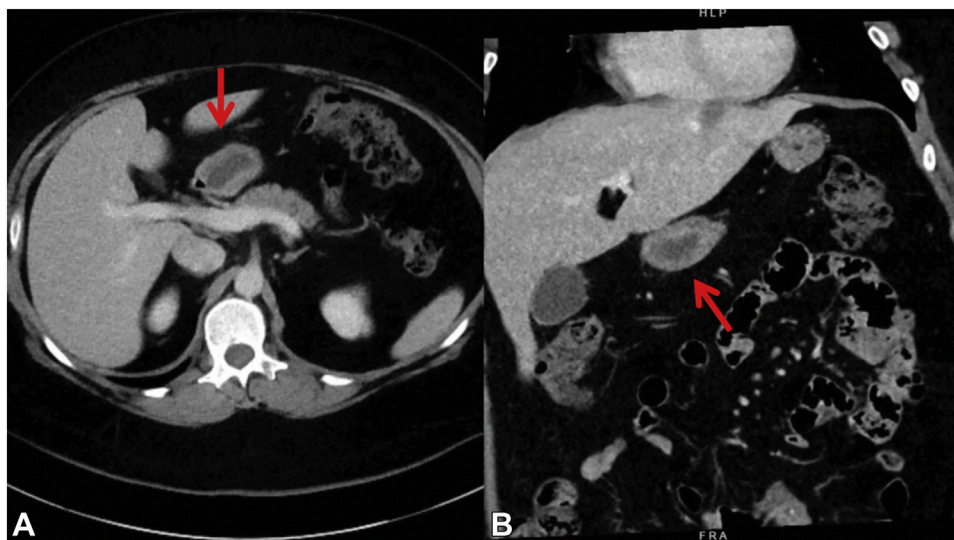


Figure 1. Sagittal (A) and coronal (B) sections of the abdominal CT scan with contrast demonstrating the cystic lesion (arrows) with diameters of $3.2 \times 1.2 \times 1.1$ cm in close proximity to the pancreatic body but without any pancreatic abnormalities.

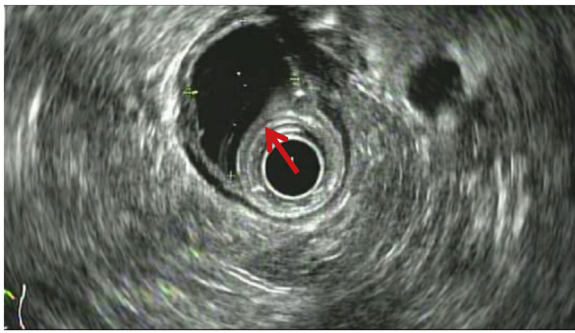


Figure 2. Endosonographic appearance of the anechoic cystic lesion (arrow) in the submucosal layer with well-defined outer sonographic borders.

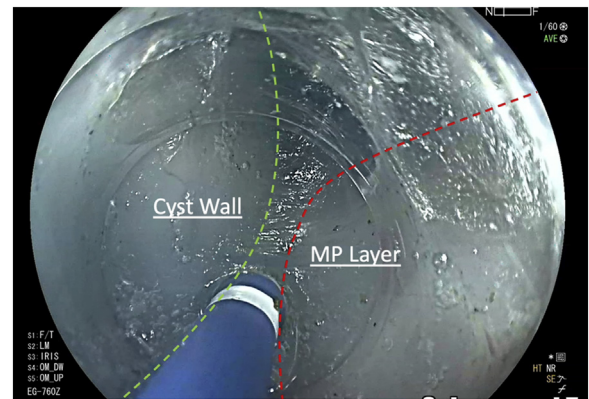


Figure 4. Submucosal tunneling dissection to expose the cyst's wall and muscularis propria.

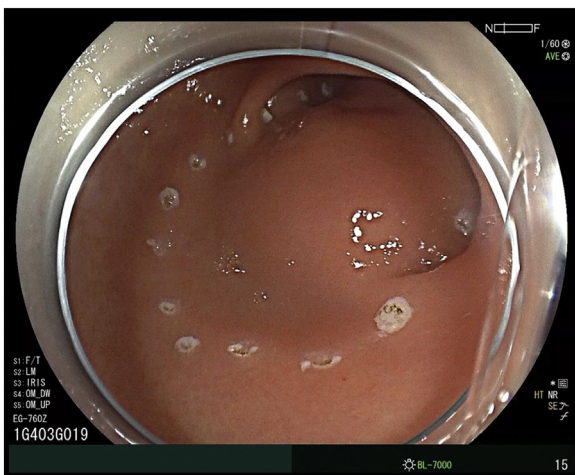

Figure 3. Endoscopic appearance of the prepyloric subepithelial lesion and placement of thermal markings.

documented phenomenon, with 25 reported cases in the literature.¹ This connection could be to a bifurcated pancreatic duct, or more commonly, to the duct of an accessory pancreatic lobe, and recurrent pancreatitis can be seen in 60% of these cases.^{1,4} EUS demonstrates a “gut signature” of layers with external muscle lining.⁵ Magnetic resonance imaging, CT, and EUS can reveal a connection with the pancreatic ductal system; however, it may not always be visible.¹

In most cases, surgery is preferred because it resolves the symptoms and eliminates the carcinoma risk.¹ Unroofing is an alternative strategy; however, there is a concern for the reaccumulation of cystic fluid owing to the remaining cystic wall and a communicating duct underneath the gastric mucosa. ESD has emerged as an alternative approach with the recent developments in endoscopic surgery.⁶ To the authors’ knowledge, this is the first report demonstrating a successful removal of GDC with ESD and endoscopic ductotomy.

final report confirming gastric duplication cyst (Fig. 8). The patient did well and was discharged on the same day with no adverse events, and no recurrent symptoms were reported during the 12-month follow-up.

DISCUSSION

Gastrointestinal duplication cysts are cystic lesions with mucosal lining that share a muscular wall with the gastrointestinal tract. They are seen in 1 out of 4500 live births; among 2% to 9% are GDC. In adults, GDC are mostly asymptomatic, but abdominal pain, fullness, and nausea-vomiting have been reported. Adverse events such as adenocarcinoma, bleeding, perforation, and obstruction are also possible.¹ The most persuasive theory for their pathogenesis postulates the persistence of embryonic endodermal adhesion bands causing traction of the primitive gastrointestinal tract and pancreatic bud.^{2,3} The connection of GDC to pancreatic ducts is a rare but well-

DISCLOSURE

Dr Ryou is a consultant for Olympus America, Medtronic, Boston Scientific, and Fujifilm Medical Systems. Dr Thompson is a consultant for and received research support from Apollo Endosurgery, Boston Scientific, Fujifilm Medical Systems, GI Dynamics, Lumendi, Olympus America, and USGI Medical; is a consultant for Medtronic and Fractyl; receives institutional research grants from Aspire Bariatrics and Erbe USA; is a general partner for BlueFlame Healthcare; and is a founder, consultant, and board member for Envision Endoscopy, Enterasense, and GI Windows. Dr Aibara is a consultant for Olympus America, Fujifilm Medical Systems, Boston Scientific, ConMed, Medtronic, and 3D-Matrix. Dr Simsek disclosed no financial relationships.

Abbreviations: GDC, gastric duplication cyst; ESD, endoscopic submucosal dissection.

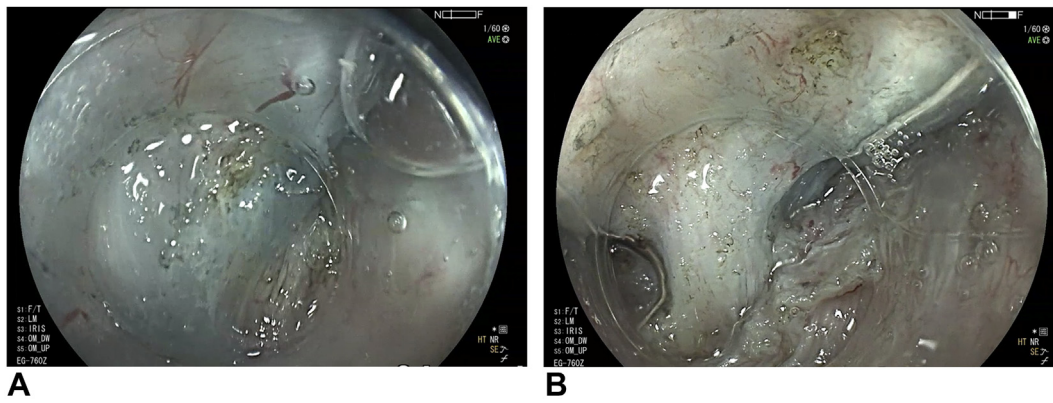


Figure 5. **A**, Area of submucosal fibrosis underneath the cyst. **B**, Appearance of the underlying duct after skeletonization.

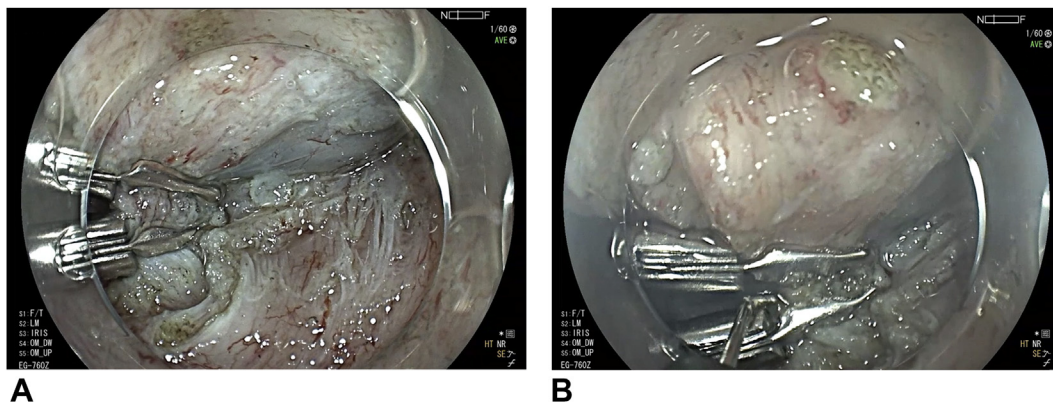


Figure 6. **A**, Two hemoclips were deployed on the communicating duct. **B**, Ductotomy was performed using HookKnife (Olympus America, Center Valley, Penn, USA).

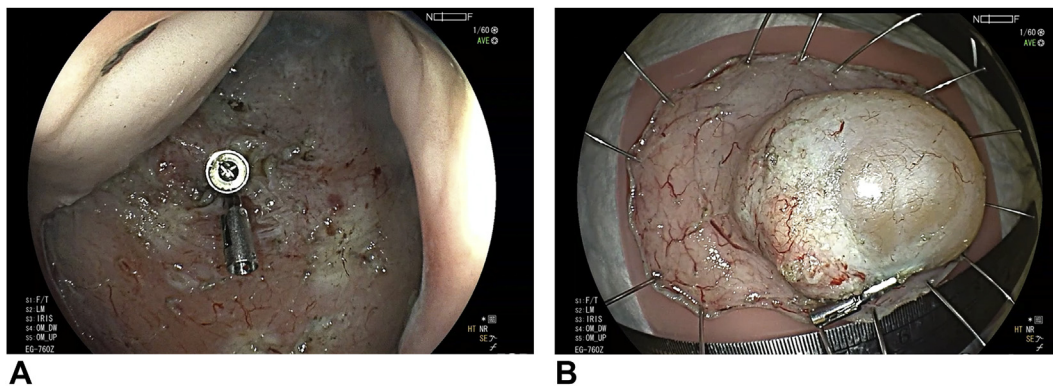


Figure 7. **A**, Resection defect with deployed clips on the duct's stump. **B**, Final specimen demonstrating smooth surface of the cyst and origin of the duct with the clip.

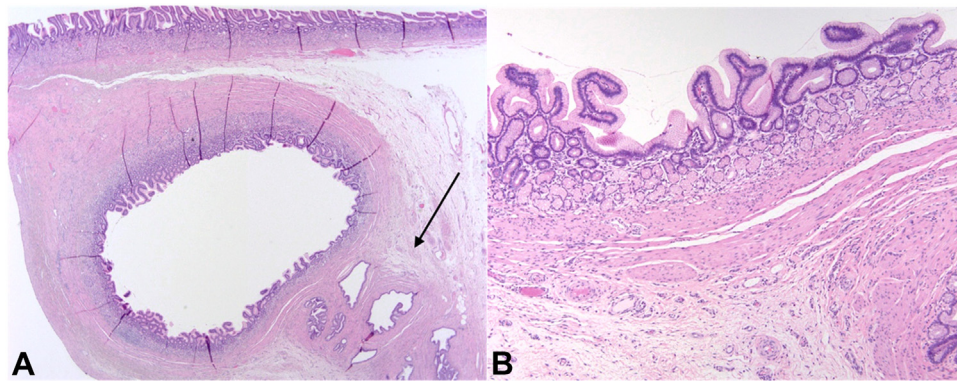


Figure 8. **A**, Histologic section showing a submucosal cyst lined by gastric mucosa. The communicating duct is seen in the deep aspect of the specimen (*arrow*) (H&E, orig. mag. $\times 20$). **B**, Histologic section showing the cyst lined by gastric antral-type mucosa (H&E, orig. mag. $\times 100$).

REFERENCES

1. Rousek M, Kachlik D, Nikov A, et al. Gastric duplication cyst communicating to accessory pancreatic lobe: a case report and review of the literature. *World J Clin Cases* 2018;6:1182-8.
2. McLetchie N, Purves J, Saunders R. The genesis of gastric and certain intestinal diverticula and enterogenous cysts. *Surg Gynecol Obstet* 1954;99:135-41.
3. Tabrisky J, Szalay GC, Meade WS. Duplication of the stomach: a cause of anemia. *Am J Gastroenterol* 1973;59:327-31.
4. Christians KK, Pappas S, Pilgrim C, et al. Duplicate pancreas meets gastric duplication cyst: a tale of two anomalies. *Int J Surg Case Rep* 2013;4:735-9.
5. Liu R, Adler DG. Duplication cysts: diagnosis, management, and the role of endoscopic ultrasound. *Endosc Ultrasound* 2014;3: 152-60.
6. Chavan R, Nabi Z, Basha J, et al. Endoscopic resection of a complex gastric duplication cyst using a submucosal tunneling technique. *Endoscopy* 2022;54:E168-9.

Division of Gastroenterology Hepatology and Endoscopy, Brigham and Women's Hospital, Boston, Massachusetts.

If you would like to chat with an author of this article, you may contact Dr Aihara at haihara@bwh.harvard.edu.

Copyright © 2022 American Society for Gastrointestinal Endoscopy. Published by Elsevier Inc. This is an open access article under the CC BY-NC-ND license (<http://creativecommons.org/licenses/by-nc-nd/4.0/>).

<https://doi.org/10.1016/j.vgje.2022.04.003>

Twitter

Become a follower of *VideoGIE* on Twitter. Learn when new articles are posted and receive up-to-the-minute news as well as links to our latest videos. Search @VideoGIE on Twitter.