



## Case report

# Indocyanine green fluorescent lymphography during open inguinal hernia repair in a patient who developed postoperative ultrasonic hydrocele: A case report

Yuichi Nakaseko<sup>\*</sup>, Masashi Yoshida, Teppei Kamada, Keigo Nakashima, Hironori Ohdaira, Yutaka Suzuki

Department of Surgery, International University of Health and Welfare Hospital, Japan

## ARTICLE INFO

**Keywords:**  
Case report  
Lymphography  
Inguinal hernia  
Hydrocele

## ABSTRACT

**Background:** To our knowledge, no reports of indocyanine green (ICG) fluorescent lymphography during inguinal hernia repair currently exist. We report the case of a patient who underwent ICG fluorescent lymphography during open inguinal hernia repair.

**Case presentation:** A 63-year-old man was referred to our department for treatment of a right inguinal hernia, during which an ICG lymphography was performed. The patient had a history of robot-assisted radical prostatectomy for prostate cancer. Following induction of general anesthesia, 0.25 mg of ICG was injected into the right testicle and the scrotum was gently massaged, after which an open inguinal hernia repair was performed. During the operation, fluorescence from the ICG was observed in two lymphatic vessels in the spermatic cord. The ICG fluorescent vessels were resected due to the strong adhesion between the lymphatic vessels and the hernia sac. ICG leakage was observed in the resected vessels. An open tension-free technique was performed using an open mesh plug. The patient was discharged one day postoperatively. The histological diagnosis of the resected vessel was a lymphatic vessel. He had a slight postoperative hydrocele that was detected at the follow-up clinic 10 days postoperatively during ultrasonic examination (ultrasonic hydrocele).

**Conclusion:** We report the use of ICG fluorescent lymphography during open inguinal hernia repair in a patient who developed postoperative ultrasonic hydrocele. This case may indicate a relationship between lymphatic vessel injury and hydrocele.

## 1. Introduction and importance

No reports of indocyanine green (ICG) fluorescent lymphography being performed during inguinal hernia repair were found in the PubMed database when publications containing the terms “inguinal hernia” and “lymphography” were searched for.

ICG fluorescent lymphography is reportedly a safe and effective method used during lymphatic-sparing laparoscopic Palomo varicocelelectomy in children and adolescents with high degree varicocele [1,11–13]. Using this method results in a significantly reduced incidence of postoperative hydroceles.

Seroma formation may not have received much attention, but have been reported as a common early postoperative complication of inguinal hernia [2,15]. Several techniques that reduce the development of postoperative hydrocele during laparoscopic repair have been reported

[2,7–9,15]. These techniques require additional operation like suture for closure of a hernia defect.

ICG fluorescent lymphography may be useful to prevent postoperative hydrocele without additional operation, we performed ICG fluorescent lymphography during open inguinal hernia repair.

This work has been reported in line with SCARE 2020 criteria [14].

## 2. Case presentation

A 63-year-old man with a chief complaint of right inguinal swelling was referred to our department for treatment of a right indirect inguinal hernia. The patient had a history of robot-assisted radical prostatectomy for prostate cancer. Computed tomography revealed a prolapsed sigmoid colon, which caused a right inguinal hernia (Fig. 1). ICG fluorescent lymphography was performed during open inguinal hernia repair.

<sup>\*</sup> Corresponding author at: International University of Health and Welfare Hospital, 537-3, Iguchi, Nasushiobara city, Tochigi 329-2763, Japan.

E-mail addresses: [jaguar.u1-0325@jikei.ac.jp](mailto:jaguar.u1-0325@jikei.ac.jp) (Y. Nakaseko), [masashi@iuhw.ac.jp](mailto:masashi@iuhw.ac.jp) (M. Yoshida), [yutaka@iuhw.ac.jp](mailto:yutaka@iuhw.ac.jp) (Y. Suzuki).

Following induction of general anesthesia, 1 ml of 2.5 mg/ml (0.25 mg) ICG was directly injected into the right testicle and the scrotum was gently massaged. Fluorescence from the ICG appeared in two lymphatic vessels in the spermatic cord during the operation (Fig. 2). The ICG fluorescent vessels were resected due to the strong adhesion between the lymphatic vessels and the hernia sac (Fig. 3). ICG leakage was observed in the resected vessels (Fig. 4). After separating the hernial sac from the spermatic cord, the hernia sac returned to the preperitoneal cavity. An open tension-free technique with mesh plug was performed. The duration of the procedure was 91 min, and the estimated blood loss was 1 g.

The patient was discharged one day postoperatively. No allergies or other adverse events induced by ICG were observed. The histological diagnosis of the resected vessel with fluorescence was a lymphatic vessel. He had slight postoperative hydrocele, which was observed during ultrasonic examination (ultrasonic hydrocele) (Fig. 5), but he exhibited no postoperative clinical symptoms of the groin at the follow-up clinic on the 10th day postoperatively.

No postoperative ultrasonic hydrocele was observed at one-month follow-up. He had not experienced any testicular pain secondary to intratesticular injection, short- or long-term postoperatively.

### 3. Clinical discussion

We performed ICG fluorescent lymphography during open inguinal hernia repair. This procedure is safe and feasible to perform in this case.

Over 20 million patients worldwide undergo inguinal hernia repair annually [3]. Primary unilateral inguinal hernias account for 75% of abdominal wall hernias, with a lifetime risk of 27% in men and 3% in women [4]. Operative techniques have evolved recently to provide the best management for inguinal hernias [5]. The open tension-free Lichtenstein technique is the most commonly performed procedure worldwide, with optimal outcomes and a low recurrence rate [3].

Seroma formation is a common early postoperative complication encountered in inguinal hernia, and the most appropriate technique for distal sac management remains controversial. The main problem posed by a postoperative hydrocele is the misconception by patients and their general practitioners that they represent persistent or recurring hernias [6]. Furthermore, postoperative hydrocele cause symptoms such as discomfort, swelling, and infection. Preventing postoperative hydrocele during open inguinal hernia repair will substantially improve the outcomes of people worldwide.

Several techniques that reduce the development of postoperative hydrocele during laparoscopic repair have been reported [2,7–9,15]. Although an open procedure is most commonly used, no techniques using open repair were found in the PubMed database when publications

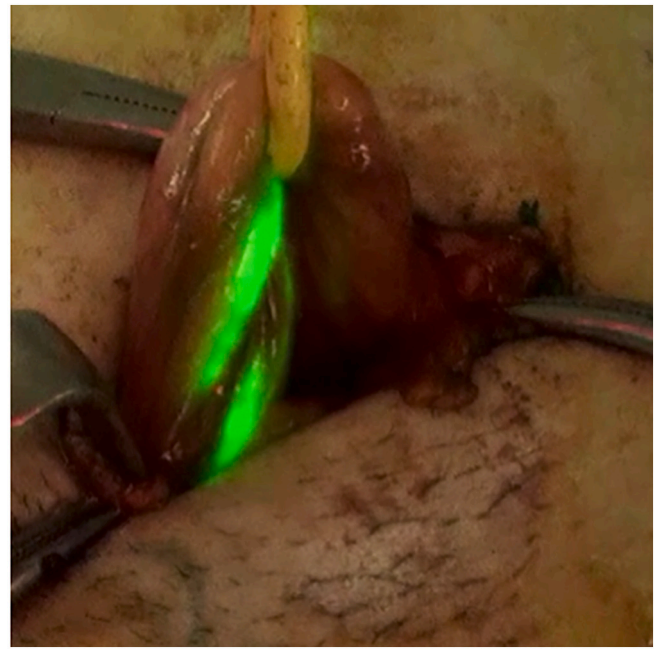


Fig. 2. Figure showing intraoperative findings. Fluorescence from ICG revealed two lymphatic vessels in the spermatic cord.

with titles containing the terms “inguinal hernia” and “hydrocele” were searched for.

To date, no data regarding lymphography during inguinal hernia repair have been reported.

Chiarenza et al. reported that blue patent lymphography prevented hydrocele after laparoscopic varicocelectomy [10]. In this method, the internal spermatic vessels are identified and ligated by clips that separate them from the lymphatics, which are stained with isosulfan blue. This method results in the significant reduction of postoperative hydroceles. For this reason, lymphatic-sparing procedures have been used during varicocele repair in recent years to reduce the incidence of secondary hydrocele and ensure improved andrological outcomes in children [6–8].

Esposito et al. reported a new technique that employs ICG fluorescence lymphography during lymphatic-sparing laparoscopic Palomo varicocelectomy in children [1]. They suggested two main differences between the use of isosulfan blue and ICG. First, isosulfan blue is metabolized by the kidney; and the urine consequently appears blue for

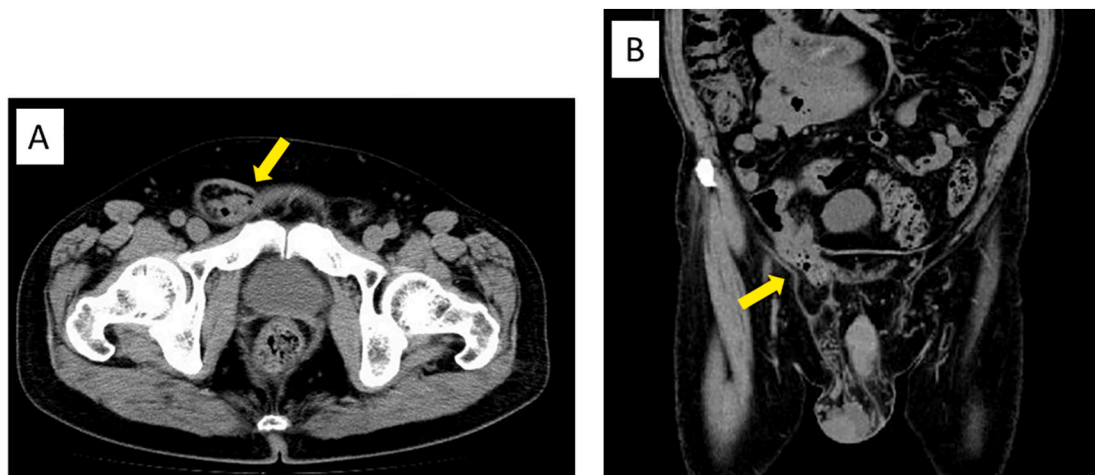
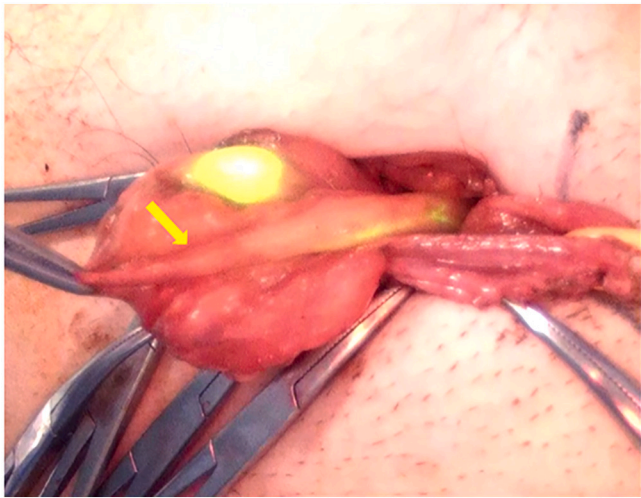
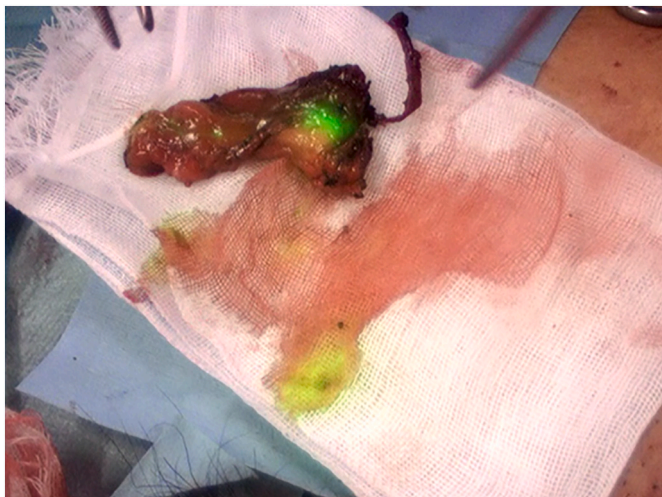

Fig. 1. Computed tomography showing the following: (A) a right inguinal hernia (arrow) and (B) prolapse of the sigmoid colon into the hernia (arrow).





**Fig. 3.** Strong adhesion between the lymphatic vessels and the hernia sac (arrow).



**Fig. 4.** ICG leakage from the resected vessels.

1–2 days postoperatively, whereas ICG is taken up by the liver and the urine appears normal postoperatively. Second, the isosulfan blue injection leaves a blue slick on the scrotum for approximately 1–2 weeks postoperatively, whereas the scrotum appears normally colored after ICG injection.

The two reports described the relationship between lymphatic vessel injury and hydrocele in children. However, inguinal hernia about adults regarding, not only the relationship between lymphatic vessel damage and hydrocele, but also the existence of lymphatic vessels during open inguinal hernia repair is unknown.

We performed ICG fluorescent lymphography using their procedure as a reference during inguinal hernia repair in an adult.

In our case, ICG leakage was observed from the resected vessels when using the near-infrared mode; however, ICG leakage from the resected vessels was invisible when the standard white-light mode was used (Fig. 6).

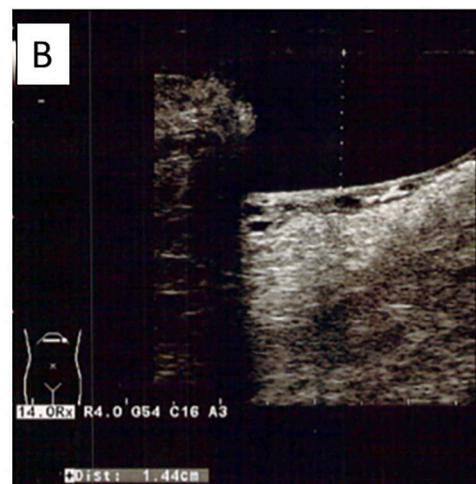
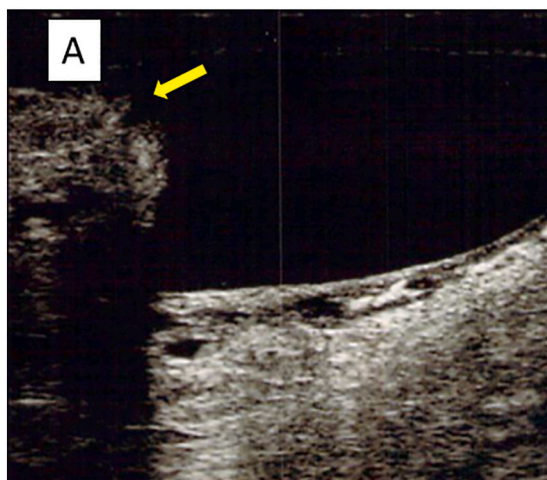
Esposito et al. reported that the lymphatics were clearly visible since they appeared green when the standard white-light mode was used. They injected a vial of ICG (5 mg/dl) into the body of the left testicle. We used 0.25 mg ICG (2.5 mg/dl), which was a lower concentration; and therefore, invisible in the standard white-light mode. Additionally, ICG fluorescent lymphography was good for deep tissue penetration. For this reason, we used ICG instead of isosulfan blue.

The patient developed postoperative ultrasonic hydrocele despite the ICG fluorescent lymphatic vessels not being preserved, which may indicate a relationship between lymphatic vessel injury and hydroceles.

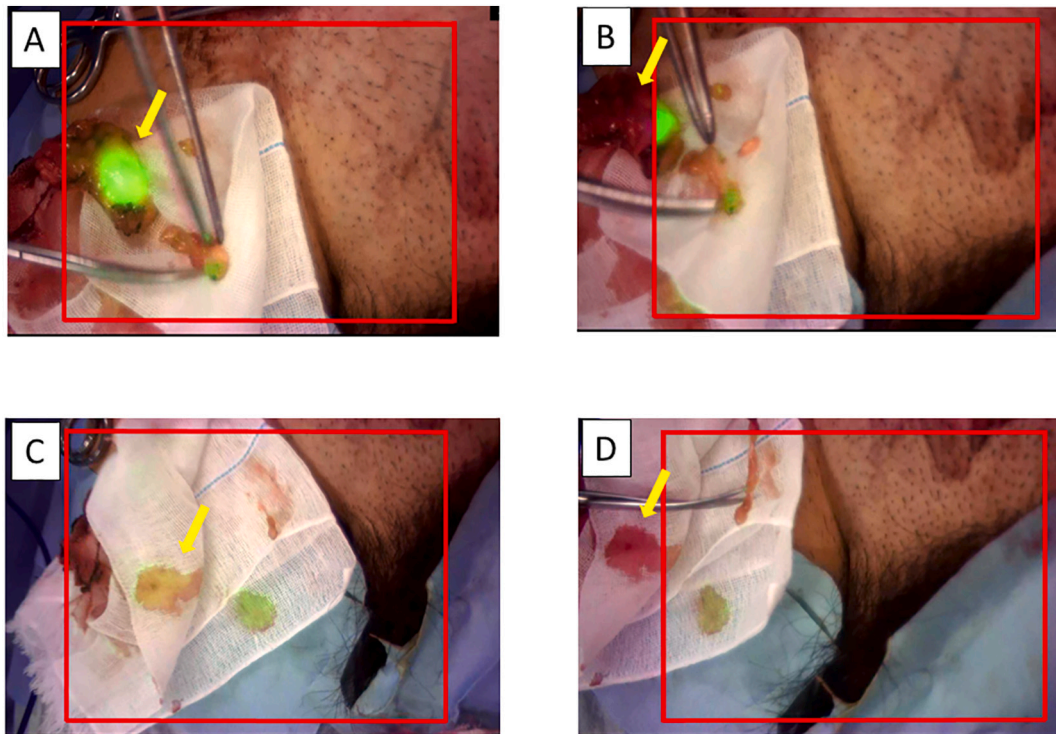
Although it was visualized in our case, the lymphatic vessels had to be cut because of the strong adhesion. In the uncomplicated hernia cases, there is usually no difficulty separating the spermatic cord from the hernial sac as to procedure injury to the lymphatics. However, in cases with strong hernia sac adhesions, such as this case, it is difficult to remove the hernia sac and there is a possibility of deep cutting into the spermatic cord.

This is the first case of confirmation of the indocyanine green fluorescence labelled lymphatic vessels in the spermatic cord, which had not been demonstrated until now, and it may be possible to prevent the onset of postoperative ultrasonic hydrocele by preserving it in the future.

In limitations, our report is a case report in a patient who developed postoperative ultrasonic hydrocele. A case series of ICG fluorescent lymphography during open inguinal hernia repair should be conducted as the next step to elucidate the relationship between lymphatic vessel injury and hydrocele.



**Fig. 5.** Ultrasonic findings. (A) Slight postoperative hydrocele was detected. The yellow arrow indicates the right testicle. (B) The depth of postoperative hydrocele was 1.44 cm. (For interpretation of the references to color in this figure legend, the reader is referred to the web version of this article.)



**Fig. 6.** Fluorescence only emerges inside the red frame in images obtained using the Hyper Eye Medical system. White-light images are shown outside the red frame. (A) Fluorescence from ICG appeared from the resected vessels in the spermatic cord using the near-infrared mode (inside the red frame). (B) ICG color was invisible when the standard white-light mode was used (outside the red frame). (C) ICG leakage appeared on the gauze when the near-infrared mode was used (inside the red frame). (D) ICG leakage was invisible using the standard white-light mode (outside the red frame). (For interpretation of the references to color in this figure legend, the reader is referred to the web version of this article.)

#### 4. Conclusion

We report performing ICG fluorescent lymphography during open inguinal hernia repair in a patient who developed postoperative ultrasonic hydrocele. This case may indicate a relationship between lymphatic vessel injury and hydrocele during open inguinal hernia repair.

#### Sources of funding

Yuichi Nakaseko and co-authors have no conflict of interest. We received no funding or grant support for this study.

#### Ethical approval

This study was approved (Approval No. Approval No. 13-B-60) by the Clinical Ethics Committee of International University of Health and Welfare, Tochigi, Japan.

#### Consent

Written informed consent was obtained from the patient for publication of this case report and accompanying images. A copy of the written consent is available for review by the Editor-in-Chief of this journal on request".

#### Research registration

This paper is case report. The authors don't need to register this work.

#### Guarantor

Yuichi Nakaseko, the corresponding author of this manuscript accept full responsibility for the work and the conduct of the study, access to the data and controlled the decision to publish.

#### Provenance and peer review

Not commissioned, externally peer-reviewed.

#### CRediT authorship contribution statement

The study conception and design were made by Nakaseko Y, Yoshida M and Suzuki Y.

Acquisition of data was done by Nakaseko Y, Kamada T, Wataru K, Yoshinobu F, Takahashi J, Nakashima K and Suzuk N.

Drafting of the manuscript was done by Nakaseko Y.

Critical revision of the manuscript was done by Yoshida M, Ohdaira H and Suzuki Y.

#### Declaration of competing interest

The authors declare that they have no competing interests.

#### References

- [1] C. Esposito, F. Turrà, F. Del Conte, S. Izzo, F. Gargiulo, A. Farina, et al., Indocyanine green fluorescence lymphography: a new technique to perform lymphatic sparing laparoscopic palmo varicocelectomy in children, *J. Laparoendosc. Adv. Surg. Tech. A* 29 (2019) 564–567, <https://doi.org/10.1089/lap.2018.0624>.
- [2] V.M. Reddy, C.D. Sutton, L. Bloxham, G. Garcea, S.S. Ubhi, G.S. Robertson, Laparoscopic repair of direct inguinal hernia: a new technique that reduces the development of postoperative seroma, *Hernia* 11 (2007) 393–396, <https://doi.org/10.1007/s10029-007-0233-4>.

- [3] HerniaSurge Group, International guidelines for groin hernia management, *Hernia* 22 (2018) 1–165, <https://doi.org/10.1007/s10029-017-1668-x>.
- [4] A. Kingsnorth, K. LeBlanc, Hernias: inguinal and incisional, *Lancet* 362 (2003) 1561–1571, [https://doi.org/10.1016/S0140-6736\(03\)14746-0](https://doi.org/10.1016/S0140-6736(03)14746-0).
- [5] J.J. Wu, J.A. Way, G.D. Eslick, M.R. Cox, Transabdominal pre-peritoneal versus open repair for primary unilateral inguinal hernia: a meta-analysis, *World J. Surg.* 42 (2018) 1304–1311, <https://doi.org/10.1007/s00268-017-4288-9>.
- [6] S.A. Kapisris, W.A. Brough, C.M. Royston, C. O'Boyle, P.C. Sedman, Laparoscopic transabdominal preperitoneal (TAPP) hernia repair. A 7-year two-center experience in 3017 patients, *Surg. Endosc.* 15 (2001) 972–975, <https://doi.org/10.1007/s004640080090>.
- [7] M. Ismail, M. Garg, M. Rajagopal, P. Garg, Impact of closed-suction drain in preperitoneal space on the incidence of seroma formation after laparoscopic total extraperitoneal inguinal hernia repair, *Surg. Laparosc. Endosc. Percutan. Tech.* 19 (2009) 263–266, <https://doi.org/10.1097/SLE.0b013e3181a4d0e1>.
- [8] J. Li, W. Zhang, Closure of a direct inguinal hernia defect in laparoscopic repair with barbed suture: a simple method to prevent seroma formation? *Surg. Endosc.* 32 (2018) 1082–1086, <https://doi.org/10.1007/s00464-017-5760-1>.
- [9] Y. Zhu, M. Liu, J. Li, M. Wang, Closure of direct inguinal hernia defect in laparoscopic hernioplasty to prevent seroma formation: a prospective double-blind randomized controlled trial, *Surg. Laparosc. Endosc. Percutan. Tech.* 29 (2019) 18–21, <https://doi.org/10.1097/SLE.0000000000000619>.
- [10] S.F. Chiarenza, I. Giurin, L. Costa, F. Alicchio, A. Carabaich, T. De Pascale, et al., Blue patent lymphography prevents hydrocele after laparoscopic varicocelectomy: 10 years of experience, *J. Laparoendosc. Adv. Surg. Tech. A* 22 (2012) 930–933, <https://doi.org/10.1089/lap.2012.0060>.
- [11] Z. Liang, J. Guo, H. Zhang, C. Yang, J. Pu, H. Mei, et al., Lymphatic sparing versus lymphatic non-sparing laparoscopic varicocelectomy in children and adolescents: a systematic review and meta-analysis, *Eur. J. Pediatr. Surg.* 21 (2011) 147–153, <https://doi.org/10.1055/s-0031-1271733>.
- [12] R. Lisle, A. Mahomed, Lymphatic sparing laparoscopic palomo varicocelectomy, *J. Pediatr. Surg.* 45 (2010) 285, <https://doi.org/10.1016/j.jpedsurg.2009.09.034>.
- [13] Q. Tong, L. Zheng, S. Tang, Z. Du, Z. Wu, H. Mei, et al., Lymphatic sparing laparoscopic palomo varicocelectomy for varicoceles in children: intermediate results, *J. Pediatr. Surg.* 44 (2009) 1509–1513, <https://doi.org/10.1016/j.jpedsurg.2008.10.049>.
- [14] R.A. Agha, T. Franchi, C. Sohrabi, G. Mathew, for the SCARE Group, The SCARE 2020 guideline: updating consensus Surgical CAse REport (SCARE) guidelines, *Int. J. Surg.* 84 (2020) 226–230, <https://doi.org/10.1016/j.ijvs.2020.10.034>.
- [15] J. Li, W. Gong, Q. Liu, Intraoperative adjunctive techniques to reduce seroma formation in laparoscopic inguinal hernioplasty: a systematic review, *Hernia* 23 (2019) 723–731, <https://doi.org/10.1007/s10029-019-01903-1>.