



CASE REPORT

Brain cavernous hemangioma mimicking radiation-induced necrosis in a patient with non-small cell lung cancer

Shinkichi Takamori¹ , Takashi Seto¹ , Mikako Jinnouchi², Taichi Matsubara¹, Naoki Haratake¹, Naoko Miura¹, Ryo Toyozawa¹, Masafumi Yamaguchi¹ & Mitsuhiro Takenoyama¹

¹ Department of Thoracic Oncology, National Hospital Organization Kyushu Cancer Center, Fukuoka, Japan

² Department of Radiology, National Hospital Organization Kyushu Cancer Center, Fukuoka, Japan

Keywords

Cavernous hemangioma; non-small cell lung cancer; radiation-induced necrosis.

Correspondence

Takashi Seto, Department of Thoracic Oncology, National Hospital Organization Kyushu Cancer Center, 3-1-1 Notame, Minami-ku, Fukuoka 811-1395, Japan.
Tel: +81 92 541 3231
Fax: +81 92 551 4585
Email: setocruise@gmail.com

Received: 26 March 2020;

Accepted: 29 April 2020.

doi: 10.1111/1759-7714.13494

Thoracic Cancer **11** (2020) 2056–2058

Abstract

In patients with non-small cell lung cancer (NSCLC), stereotactic radiotherapy (SRT) is one of the standard therapies for those suffering with intracranial metastatic NSCLC. Radiation-induced necrosis (RIN) sometimes occurs as the result of the delayed effects of SRT. The magnetic resonance imaging (MRI) of RIN typically shows hypointense and hyperintense lesions on T1- and T2-weighted images, respectively. We herein report a patient with a growing brain cystic lesion mimicking RIN adjacent to a post-radiation brain metastasis from NSCLC harboring anaplastic lymphoma kinase rearrangement. The patient underwent surgical resection of the brain tumor because of the symptoms. The pathological diagnosis was cavernous hemangioma, and the pathological findings were an encapsulated nodular mass composed of dilated, cavernous vascular spaces with no residual tumor or recurrence. Clinicians should be aware of the possibility for the development of a brain cavernous hemangioma following SRT in NSCLC patients.

Introduction

Lung cancer is one of the most fatal malignancies worldwide, and non-small cell lung cancer (NSCLC) accounts for approximately 85% of all lung cancer cases.¹ In patients with NSCLC, brain metastases are diagnosed in approximately 40% cases during the course of the disease.² Patients with brain metastases from NSCLC often develop in-field and/or out-of-field progression. Nardone *et al.*³ reported that 9% of patients with brain metastases from NSCLC showed in-field progression and 22% developed new out-of-field brain metastases. Stereotactic radiotherapy (SRT) is one of the standard treatments for patients suffering with a limited number of intracranial metastatic NSCLC,⁴ and radiation-induced necrosis (RIN) sometimes occurs as the result of the delayed effects of SRT.⁵ Magnetic resonance imaging (MRI) is a sensitive screening test for brain RIN, typically indicating lesions which are hypointense on T1 and hyperintense on T2.

Cavernous hemangiomas are one of the vascular benign tumors composed of abnormally enlarged vascular structures,

and it has been suggested that the growth is caused by the surrounding hemorrhagic cyst cavity and/or endothelial cell hyperplasia.^{6,7} Cavernous hemangiomas are commonly observed in skin, liver, and soft tissues, and reported to be rare in the brain in adulthood.^{8,9} Although there are several known causes for cavernous hemangioma, including radiation therapy and gene mutations or deletions, the pathogenesis of the disease is still not fully understood.^{10–13} Cavernous hemangiomas are diagnosed by MRI scan which typically shows hypointense and hyperintense lesions on T1- and T2-weighted images, respectively,¹⁴ similar to that of brain RIN. We herein report a NSCLC patient with a growing cavernous hemangioma in the brain mimicking RIN.

Case report

A 36-year-old man was diagnosed with primary lung adenocarcinoma in the right lower lobe (cT2aN1M0, cStage IIB). He underwent right middle and lower lobectomy in November 2011, and anaplastic lymphoma kinase (ALK) rearrangement was detected by fluorescence in situ hybridization. The patient

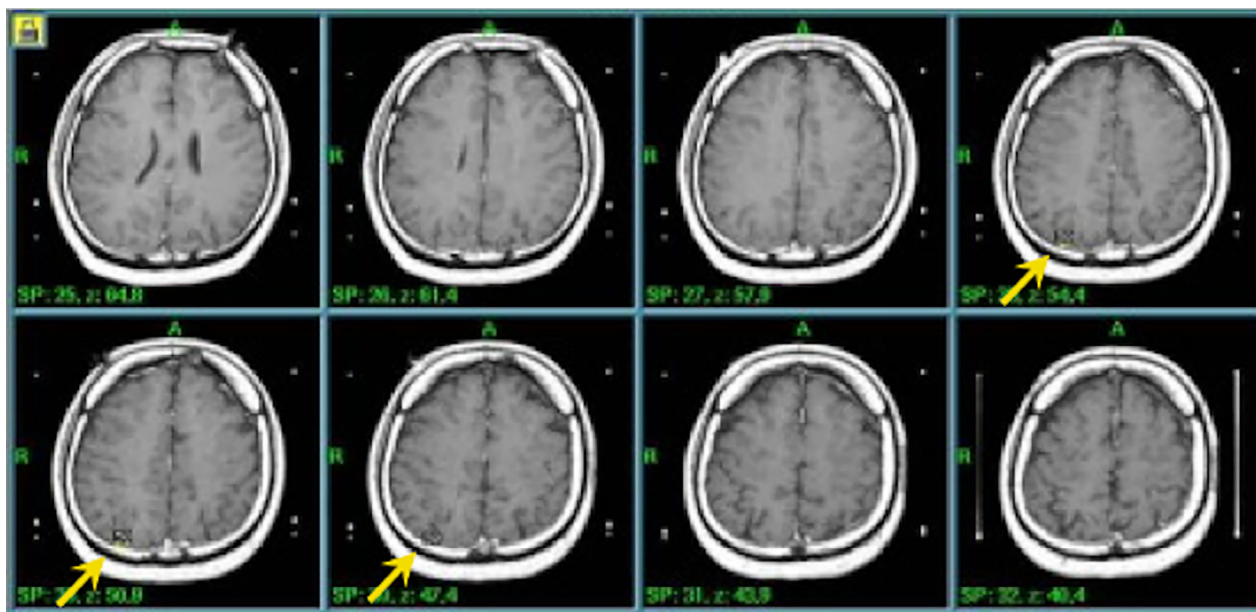


Figure 1 Planning computed tomography (CT) images of stereotactic radiotherapy with isodose distributions.

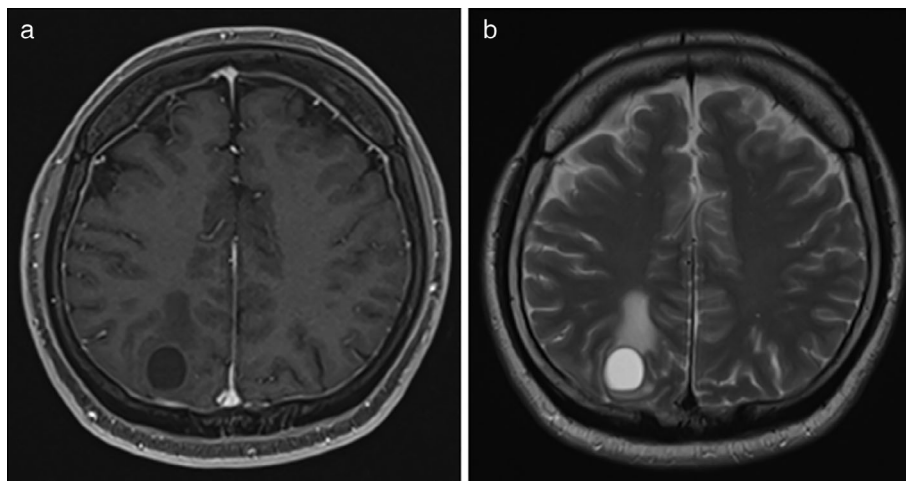
participated in a clinical trial and alectinib 600 mg/day was administered from April 2011. In April 2018, brain MRI scan showed a brain metastasis in the right lobe of the brain. Stereotactic radiotherapy (SRT) (30 Gy/3 Fr) with prescribed 50% isodose line of maximum dose fitting to planning target volume (PTV) was performed for the single brain metastasis in May 2018 (Fig 1). The brain MRI scan showed that a cystic lesion had appeared adjacent to the post-radiation brain metastasis, and the lesion was hypointense and hyperintense on T1- and T2-weighted images, respectively (Fig 2). We consulted with a neurosurgeon, and the brain lesion was diagnosed as brain necrosis based on the radiological findings. After four months, the cystic lesion and the surrounding

edema had increased in size. The patient had an epileptic seizure caused by optical stimulation. Therefore, we again consulted a neurosurgeon, and surgical resection was indicated. In January 2019, he underwent surgical resection of the growing brain lesion, and the pathological diagnosis was cavernous hemangioma. The specimen showed no residual tumor or recurrence. The patient had a favorable postoperative course, and has been attending to our hospital for one year.

Discussion

Cavernous hemangiomas are one of the vascular benign tumors composed of abnormally enlarged vascular structures,

Figure 2 Magnetic resonance imaging (MRI) of brain cavernous hemangiomas mimicking radiation-induced necrosis. The lesion was hypointense on (a) T1-weighted image and hyperintense on (b) T2-weighted image.



and rare in the brain.^{6–9} Approximately 86% of cavernous hemangiomas have been reported to be located supratentorially.⁸ With regard to the lesion growth of cavernous hemangioma, several articles have previously suggested that the growth is caused by the surrounding hemorrhagic cyst cavity and/or endothelial cell hyperplasia and/or the budding of capillaries.^{6,15} Of note, the MRI findings are similar between cavernous hemangioma and RIN.¹⁶ Regarding the cause of cavernous hemangiomas, radiation treatment used for other medical conditions has been reported to be one of the causes of the disease.¹⁰ Gastelum *et al.*¹⁰ reported that the median latency time for detection of the brain cavernous hemangioma after cranial radiation therapy was 12 years, and that the cumulative incidence was 3% at 10 years post cranial radiation therapy and 14% at 15 years. In our case, the latency time was only 0.5 year, which is very rare. In patients with NSCLC harboring *ALK* rearrangement, it is also notable that cystic brain metastases have been reported.¹⁷ Given that cystic brain metastases usually show as hypointense lesions on T1-weighted images and hyperintense on T2-weighted images, it is difficult to diagnose cavernous hemangiomas as the clinical course of brain lesions have similarities with those of brain metastases from NSCLC.^{18,19}

In conclusion, we present a case of a brain cavernous hemangioma mimicking RIN. Physicians should be aware of the possibility for the development of brain cavernous hemangioma following SRT in patients with NSCLC.

Acknowledgments

None.

Disclosure

All the authors declare no conflicts of interest in association with the present report.

References

- Torre LA, Bray F, Siegel RL, Ferlay J, Lortet-Tieulent J, Jemal A. Global cancer statistics, 2012. *CA Cancer J Clin* 2015; **65**: 87–108.
- Peters S, Bexelius C, Munk V, Leighl N. The impact of brain metastasis on quality of life, resource utilization and survival in patients with non-small-cell lung cancer. *Cancer Treat Rev* 2016; **45**: 139–62.
- Nardone V, Nanni S, Pastina P *et al.* Role of perilesional edema and tumor volume in the prognosis of non-small cell lung cancer (NSCLC) undergoing radiosurgery (SRS) for brain metastases. *Strahlenther Onkol* 2019; **195**: 734–44.
- Alexander E 3rd, Moriarty TM, Davis RB *et al.* Stereotactic radiosurgery for the definitive, noninvasive treatment of brain metastases. *J Natl Cancer Inst* 1995; **87**: 34–40.
- Vellayappan B, Tan CL, Yong C *et al.* Diagnosis and management of radiation necrosis in patients with brain metastases. *Front Oncol* 2018; **8**: 395.
- Harris GJ, Jakobiec FA. Cavernous hemangioma of the orbit. *J Neurosurg* 1979; **51**: 219–28.
- George A, Mani V, Noufal A. Update on the classification of hemangioma. *J Oral Maxillofac Pathol* 2014; **18**: S117–20.
- Del Curling O Jr, Kelly DL Jr, Elster AD, Craven TE. An analysis of the natural history of cavernous angiomas. *J Neurosurg* 1991; **75**: 702–8.
- Agrawal A, Banode P, Shukla S. Giant cavernous hemangiomas of the brain. *Asian J Neurosurg* 2012; **7**: 220–2.
- Gastelum E, Sear K, Hills N *et al.* Rates and characteristics of radiographically detected intracerebral cavernous malformations after cranial radiation therapy in pediatric cancer patients. *J Child Neurol* 2015; **30**: 842–9.
- Marchuk DA. Pathogenesis of hemangioma. *J Clin Invest* 2001; **107**: 665–6.
- Maish WN. Developmental venous anomalies and brainstem cavernous malformations: A proposed physiological mechanism for haemorrhage. *Neurosurg Rev* 2019; **42**: 663–70.
- Mouchtouris N, Chalouhi N, Chitale A *et al.* Management of cerebral cavernous malformations: From diagnosis to treatment. *Sci World J* 2015; **2015**: 808314.
- Fink KR, Fink JR. Imaging of brain metastases. *Surg Neurol Int* 2013; **4**: S209–19.
- Pozzati E, Giuliani G, Nuzzo G, Poppi M. The growth of cerebral cavernous angiomas. *Neurosurgery* 1989; **25**: 92–7.
- Terada T. Occult very small lung carcinoma with a solitary brain metastasis that is clinically diagnosed as cavernous hemangioma: A case report. *Cases J* 2009; **2**: 7475.
- Hayashi H, Okamoto I, Tanizaki J *et al.* Cystic brain metastasis in non-small-cell lung cancer with *ALK* rearrangement. *J Clin Oncol* 2014; **32**: e122–4.
- Voide C, Zimmermann S, Adjei AA *et al.* Cerebral nocardiosis mimicking multiple brain metastases in a patient with locally advanced non-small-cell lung cancer. *J Thorac Oncol* 2014; **9**: e24–6.
- Vanfleteren M, Dingemans AC, Surmont VF *et al.* Invasive aspergillosis mimicking metastatic lung cancer. *Front Oncol* 2018; **8**: 188.