



## Case Report

## An unusual case of perforated stump appendicitis: A case report

Sunil Basukala<sup>a</sup>, Bishnu Deep Pathak<sup>b</sup>, Soumya Pahari<sup>b,\*</sup>, Suman Gurung<sup>c</sup>, Bikram Basukala<sup>a</sup>, Bikash Bahadur Rayamajhi<sup>a</sup>, Narayan Thapa<sup>a</sup>

<sup>a</sup> Department of Surgery, Shree Birendra Hospital, Chhauni, Kathmandu, 44600, Nepal

<sup>b</sup> Nepalese Army Institute of Health Sciences (NAIHS), Sanobharyang, 44600, Kathmandu, Nepal

<sup>c</sup> Department of Pathology, Shree Birendra Hospital, Chhauni, Kathmandu, 44600, Nepal

## ARTICLE INFO

## Keywords:

Stump appendicitis  
Abdominal pain  
Right iliac fossa  
Septic shock

## ABSTRACT

**Introduction and importance:** The stump appendicitis is a rare complication with incidence of 1 in 50,000 appendectomy cases.

**Case presentation:** Patient with a history of emergency open appendectomy one year back presented with symptoms as that of acute appendicitis like pain abdomen localized in right iliac fossa, nausea, vomiting and anorexia. Complete blood count showed leukocytosis.

**Clinical discussion:** Aside from classical clinical symptoms similar to acute appendicitis other causes of acute abdominal pain were ruled out with clinical laboratory and radiological investigations. This creates a dilemma and delay in diagnosis if investigations are not done promptly.

**Conclusion:** Due to prior surgical history of appendectomy and low index of suspicion, the diagnosis of stump appendicitis is often delayed which may result in serious complications like stump gangrene, perforation and peritonitis.

## 1. Introduction

Appendectomy is one of the most commonly performed surgical procedures worldwide [1]. The stump appendicitis is a rare complication with an incidence of 1 in 50,000 appendectomy cases [2]. It is characterized by obstruction and inflammation of residual appendiceal tissue after appendectomy [3]. It is said that this complication develops more often after laparoscopic surgery due to incomplete resection of appendix. It may occur at variable time after initial surgery, ranging from two months to 50 years [4]. Patients present with symptoms such as that of acute appendicitis like pain abdomen, nausea, vomiting and anorexia. Complete blood count may show leukocytosis. This creates a dilemma and delay in diagnosis [1]. The rate of perforation has been reported to be around 70% [4]. Computerized Tomography of Abdomen is the most commonly used diagnostic modality [5]. Completion appendectomy is the treatment of choice [6,7]. This case report is being reported in line with the SCARE 2020 criteria [8].

## 2. Method

We reported this case following the updated consensus-based Surgical Case Report (SCARE) guidelines [8].

## 3. Case presentation

A 28-year-old male presented to the Emergency Room with complaints of right lower abdominal pain for 12 hours, which was insidious in onset, continuous, non-radiating, dull aching type with no exacerbating and relieving factors. It was associated with nausea and anorexia as well. His past surgical history included open appendectomy for acute appendicitis one year back with an uneventful postoperative period. No current medication use, family history was insignificant and the patient is a non-smoker. The patient was afebrile and the vitals were within normal limits. Abdominal examination showed scar of previous gridiron incision. There was tenderness and rebound tenderness in the right iliac fossa. Mild guarding was present with no other peritoneal signs.

The routine laboratory tests were unremarkable except for leukocytosis of 14,500 cells per cubic mm with neutrophilic predominance

\* Corresponding author. Shree Birendra Hospital, Chhauni, 106, The Comfort Housing, Sitapaila, Kathmandu, 44600, Nepal.

E-mail addresses: [anyurysm@gmail.com](mailto:anyurysm@gmail.com) (S. Basukala), [bishnupathak433@gmail.com](mailto:bishnupathak433@gmail.com) (B.D. Pathak), [paharisoumya2@gmail.com](mailto:paharisoumya2@gmail.com) (S. Pahari), [kathmandu38@gmail.com](mailto:kathmandu38@gmail.com) (S. Gurung), [markibbasu@gmail.com](mailto:markibbasu@gmail.com) (B. Basukala), [bikash.rayamajhi@naihs.edu.np](mailto:bikash.rayamajhi@naihs.edu.np) (B.B. Rayamajhi), [snthapa2061@gmail.com](mailto:snthapa2061@gmail.com) (N. Thapa).

<https://doi.org/10.1016/j.amsu.2022.103447>

Received 25 January 2022; Received in revised form 25 February 2022; Accepted 28 February 2022

Available online 9 March 2022

2049-0801/© 2022 The Authors. Published by Elsevier Ltd on behalf of IJS Publishing Group Ltd. This is an open access article under the CC BY license

(<http://creativecommons.org/licenses/by/4.0/>).

(90%). Transabdominal ultrasonography showed evidence of fluid collection in the right paracolic gutter with no other abnormalities. However, Contrast Enhanced Computerized Tomography (CECT) of abdomen and pelvis revealed a small structure at the base of caecum with enhancing walls along with stranded surrounding fat, suggestive of inflamed appendiceal stump. This confirmed the diagnosis of stump appendicitis Fig. 1.

The patient was immediately shifted to the operation room. A consultant general surgeon with prior experience performed the surgery. Abdomen was opened via gridiron incision. The paracolic gutter was packed with purulent fluid. The caecum and ascending colon were mobilized, and taenia coli were traced up to the base of the appendiceal stump. There was evidence of perforated abscess at the site of the stump. The purulent fluid (Fig. 2.) was drained and the residual appendiceal tissue was resected.

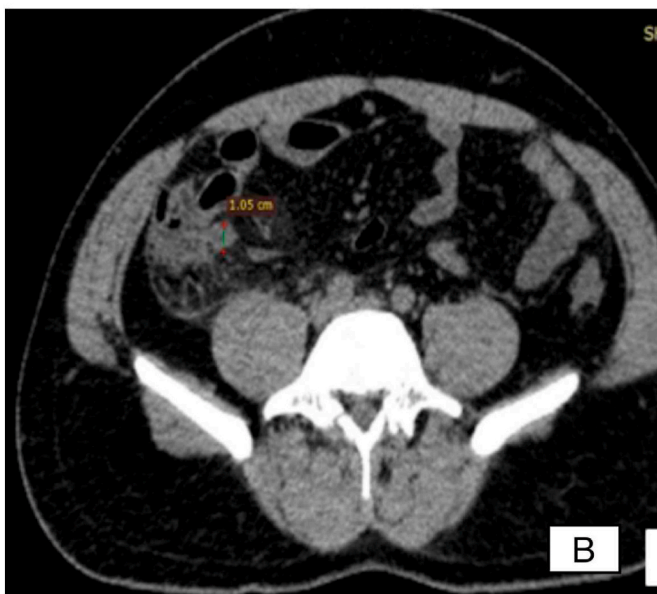
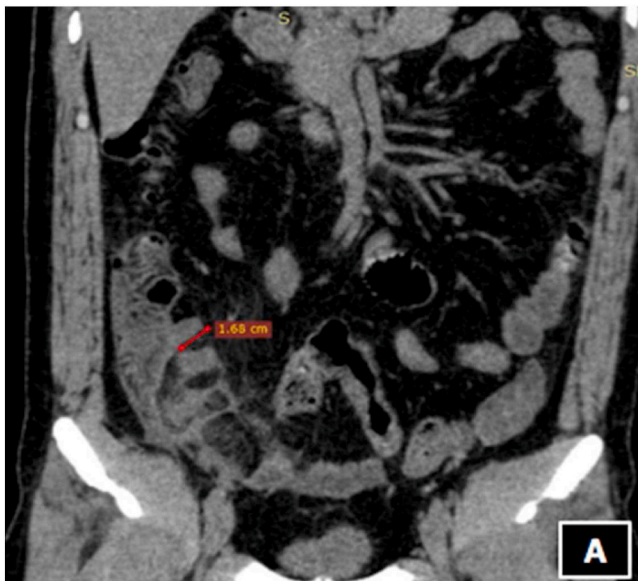

Fig. 1. Contrast Enhanced Computerized Tomography (CECT) of abdomen and pelvis A. Coronal Section B. Axial section showing stump appendix (Arrow indicating appendiceal stump with inflammatory changes).

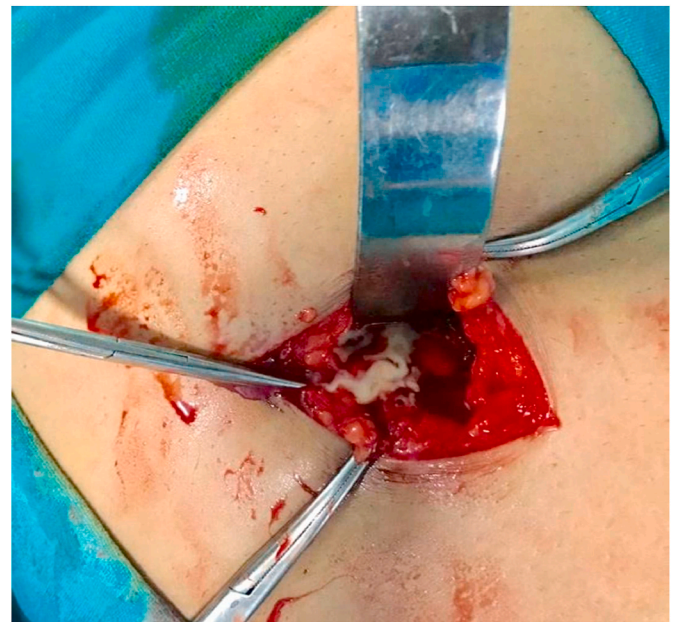


Fig. 2. Intraoperative abscess on exploration of perforated stump appendix.

The peritoneal cavity was thoroughly washed with normal saline. The tissue sample was sent for histopathological examination Fig. 3 which confirmed the diagnosis of appendicitis, making the final diagnosis as perforated stump appendicitis. Fig. 4.

Following surgery, the patient was transferred to post-operative room. He was put on parenteral antibiotics and analgesics. He did well during the postoperative period, and was discharged on day five. On follow up after two weeks, the patient was stable and healthy.

#### 4. Clinical Discussion

Stump appendicitis is a well-recognized entity [1] though its occurrence is rare [9] with incidence being 1 in 50,000 appendectomies. It is defined as the interval development of obstruction and inflammation of any remaining appendix after an appendectomy [10]. Due to prior surgical history of appendectomy and low index of suspicion, the diagnosis of stump appendicitis is often delayed which may result in serious complications like stump gangrene, perforation and peritonitis [9]. Rate of perforation, which was also seen in our case, is extremely high, approaching 70% [11]. A literature review by R. Hendahewa et al.

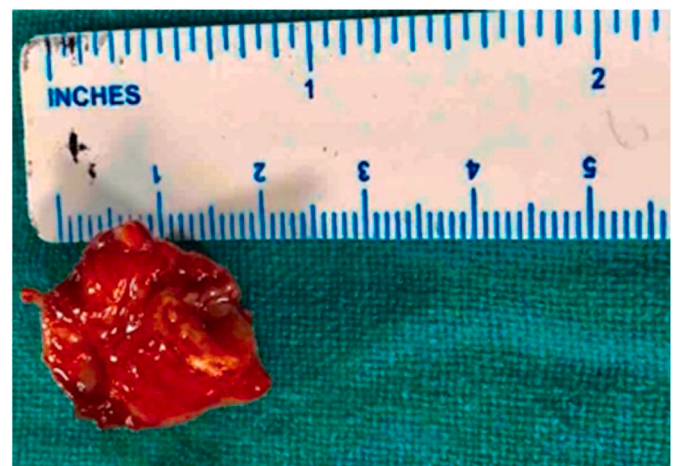


Fig. 3. Gross specimen of Stump appendix postoperatively.

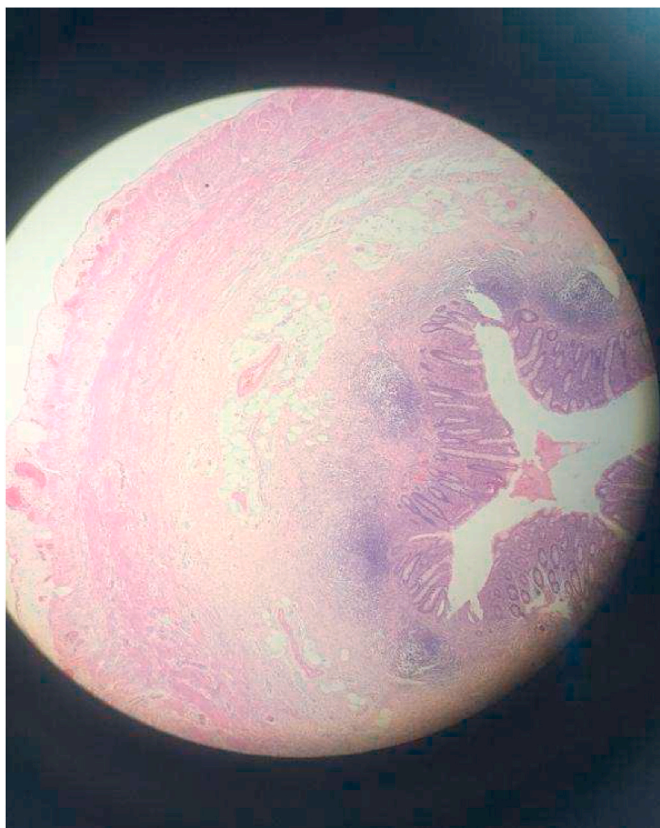

Fig. 4. H&E section of Appendix (40X & 100X).

showed that SA was frequently misdiagnosed as constipation, gastroenteritis or right sided diverticulitis, therefore leading to a significant delay to surgery [2].

The age of patients presenting with stump appendicitis ranges from 8 to 80 years and male to female ratio is 1.1:1 [4]. It may present as acute or subacute appendicitis. It is recognized that long appendiceal stump and improper identification of stump during appendectomy is the main risk factor for residual appendix [9]. The risk factors are divided into anatomical and surgical related factors. Inappropriate identification of appendiceal base or appendico-cecal junction is a common denominator to both. Retrocecal appendix or subserosal appendix, a duplicated appendix or diverticulum at the base of appendix are some of the contributing anatomical factors. Surgery related factors include inadequate identification of the appendiceal base because of severe local inflammation, leaving a long stump due to fear of cecal injury or difficult dissection and local ulcerations due to presence of a faecolith. Both of the surgical techniques for dealing with the stump i.e., inversion of stump or simple ligation of stump do not prevent the possibility of stump appendicitis [2]. Increase in incidence of SA has been attributed to introduction of laparoscopic appendectomy [9]. Lack of three-dimensional vision and absence of tactile feedback in laparoscopy has been suggested by some authors to increase the chance of leaving behind a longer stump [2]. However, a review by Liang et al. revealed that incidence of stump appendicitis after standardized laparoscopic appendectomy is less than half as compared to open technique [9–11]. The incidence should not be increased if laparoscopic appendectomy is performed properly [1].

A review of 61 cases by A. Subramanian and M.K. Lang showed mean stump length of 3.3 cm and appendiceal stumps of less than 0.5 cm are unlikely to result in future stump appendicitis [10]. Mangi and Berger [10] have suggested that the incidence of stump appendicitis can be decreased by proper identification of the base of the appendix and by leaving an appendiceal stump of <3 mm long. Dissecting the recurrent

branch of the appendiceal artery and following the tenia coli on the caecum helps in identifying the true appendiceal base.

High index of clinical suspicion supported by investigations such as abdominal ultrasound scan or CT scan aid in the diagnosis of Stump Appendix [11–15]. CT scan excludes other etiologies of the acute abdomen and it should be able to identify pericecal inflammatory changes, abscess formation, fluid in the right paracolic gutter, cecal wall thickening, ileocecal mass and, in some cases, a prompt visualization of the appendiceal stump can be made, hence it is preferred over ultrasound scan [15]. Diagnostic laparoscopy is useful in some doubtful cases with persistent abdominal symptoms after ruling out other pathologies by doing extensive imaging and It may allow safe completion appendectomy if diagnosis of stump appendicitis is made. Colonoscopy and barium enema are other modalities of diagnosis described in the literature [16].

The completion appendectomy is the treatment of choice for stump appendicitis, most commonly done as an open operation (72%) [15] but a successful laparoscopic approach has also been reported. Only 10% of stump appendicitis which are perforated have been treated with laparoscopic procedure, the rest requiring open surgery [11]. Extensive procedures like ileocectomy may be required in the setting of extensive inflammation and peritonitis [1]. Perforated stump appendicitis requiring partial cecectomy and right hemicolectomy have also been reported [11]. Non-surgical treatments have also been described for stump appendicitis, which include colonoscopic removal of appendicolith [15–17] and medical management using antibiotics, analgesics and clear liquid diet. Such patients may undergo interval stump appendectomy after 6 weeks, following resolution of inflammation. This is said to decrease the potential morbidity of wound and surgical site infections and eliminate repeated bouts of stump appendicitis in the future [16, 17].

## 5. Conclusion

Stump appendicitis can represent a diagnostic dilemma if the treating physician is unfamiliar with this uncommon clinical entity. The timely use of CT scan allows the prompt diagnosis in cases with perforated sump appendicitis. Completion appendectomy either open or laparoscopic method is the definitive modality of treatment.

The primary takeaway lesson from this case report is that the treating physician/surgeon should have a high index of suspicion for this rare entity while dealing with a patient having abdominal pain and a past surgical history of appendectomy, in order to establish a timely diagnosis and avoid potential complications that might follow.

## Ethical approval

The case report is exempt from ethical approval in our institution.

## Sources of funding

This research did not receive any specific grant or funding from funding agencies in the public, commercial, or not-for-profit sectors.

## Author contribution

Sunil Basukala (SB) = Conceptualization, Supervision.

Sunil Basukala (SB), Bishnu deep Pathak (BDP), Soumya Pahari (SP) = Writing - original draft.

Sunil Basukala (SB), Bikash Bahadur Rayamajhi (BBR), Bikram Basukala (BB), Suman Gurung (SG) = Writing - review & editing.

All the authors read and approved the final manuscript.

## Consent

Written informed consent was obtained from the patient for

publication of this case report and accompanying images. A copy of the written consent is available for review by the Editor-in-Chief of this journal on request.

#### Research Registration Number

Not applicable.

#### Guarantor

Sunil Basukala (SB).

#### Provenance and peer review

Not commissioned, externally peer-reviewed.

#### Declaration of competing interest

All authors declare that they have no conflict of interest.

#### Acknowledgments

The authors wish to acknowledge the patient included in this report. We would also like to thank our head of department of surgery for the guidance.

#### Appendix A. Supplementary data

Supplementary data to this article can be found online at <https://doi.org/10.1016/j.amsu.2022.103447>.

#### References

- [1] T. MJ, S. JM, U. PA, S. JJ, D. AC, Appendicitis after appendectomy, *Arch. Surg.* 143 (4) (2008) [cited 2021 Nov 6], <https://pubmed.ncbi.nlm.nih.gov/18427031/>, 413–5. Available from.
- [2] R. Hendaheewa, A. Shekhar, S. Ratnayake, The dilemma of stump appendicitis — a case report and literature review, *Int. J. Surg. Case Rep.* 14 (2015 Aug 11) 101, <https://doi.org/10.1016/j.ijscr.2015.07.017> [cited 2021 Nov 6].
- [3] Appendicitis S, Essenmacher A, Nash AC, Walker E, Essenmacher AC, Nash E, et al. UC irvine clinical practice and cases in emergency medicine title permalink publication date license stump appendicitis. 2018 [cited 2021 Nov 6]; Available from: [http://escholarship.org/uc/uciem\\_cpem](http://escholarship.org/uc/uciem_cpem).
- [4] MK Liang, HG Lo, JL Marks, Stump appendicitis: a comprehensive review of literature, *Am Surg* 72 (2) (2006) 162–166, <https://doi.org/10.1177/000313480607200214>. PMID: 16536249.
- [5] L.K. Shin, D. Halpern, S.R. Weston, E.M. Meiner, D.S. Katz, Prospective CT diagnosis of stump appendicitis, Nov 23 [cited 2021 Nov 6], <https://doi.org/10.2214/ajr1843.supplement01840s62>, 2012, [www.ajronline.org](http://www.ajronline.org), 184(3 Suppl).
- [6] G G, A L, B D, B C, S R, G M, A rare clinical entity: stump appendicitis. Case report and complete review of literature, *Clin. Ter.* 170 (6) (2019). Nov 1 [cited 2021 Nov 6], <https://pubmed.ncbi.nlm.nih.gov/31696901/>. e409–17. Available from.
- [7] I.A. Kooij, S. Sahami, S.L. Meijer, C.J. Buskens, A.A. Te Velde, The immunology of the vermiform appendix: a review of the literature, *Clin. Exp. Immunol.* 186 (1) (2016 Oct) 1–9.
- [8] R.A. Agha, T. Franchi, C. Sohrabi, G. Mathew, A. Kerwan, The SCARE 2020 guideline: updating consensus surgical CAse REport (SCARE) guidelines, *Int. J. Surg.* 84 (2020) 226–230, <https://doi.org/10.1016/j.ijssu.2020.10.034>.
- [9] R. Parthasarathi, S.V. Jankar, B. Chittawadgi, S.C. Sabnis, S.S. Kumar, S. Rajapandian, P. Senthilnathan, P.P. Raj, C. Palanivelu, Laparoscopic management of symptomatic residual appendicular tip: a rare case report, *J. Min. Access Surg.* 13 (2017) 154–156 [cited 2021 Dec 30].
- [10] A.A. Mangi, D.L. Berger, Stump appendicitis, *Am. Surg.* 66 (8) (2000 Aug 1) 739.
- [11] A. Subramanian, M.K. Liang, A 60-year literature review of stump appendicitis: the need for a critical view, *Am. J. Surg.* 203 (4) (2012 Apr 1) 503–507.
- [12] J.A. Awe, A.M. Soliman, R.W. Gourdie, Stump appendicitis: an uncompleted surgery, a rare but important entity with potential problems, *Case Rep. Surg.* (2013), 2013 Jan 1.
- [13] T. Shah, R.K. Gupta, R.J. Karkee, C.S. Agarwal, Recurrent pain abdomen following appendectomy: stump Appendicitis, a surgeon's dilemma, *Clin. Case Rep.* 5 (3) (2017 Mar) 215.
- [14] C. Van Paesschen, F. Haenen, R. Bestman, M. Van Cleemput, Stump appendicitis 10 years after appendectomy, a rare, but serious complication of appendectomy, a case report, *Acta Chir. Belg.* 117 (1) (2017 Jan 2) 49–51.
- [15] G. Geraci, A. Lena, B. D'Orazio, B. Cudia, S. Rizzuto, G. Modica, A rare clinical entity: stump appendicitis. Case report and complete review of literature, *La Clin. Ter.* 170 (6) (2019 Nov 10) e409–e417.
- [16] R.E. Rios, K.M. Villanueva, J.J. Stirparo, K.E. Kane, Recurrent (stump) appendicitis: a case series, *Am. J. Emerg. Med.* 33 (3) (2015 Mar 1), 480–e1.
- [17] H. Kanona, A. Al Samaraee, C. Nice, V. Bhattacharya, Stump appendicitis: a review, *Int. J. Surg.* 10 (9) (2012 Jan 1) 425–428.