

Letter to the Editor**The Outcome of Six Patients with COVID-19 Infection and Multiple Myeloma.**

Keywords: COVID-19; Multiple myeloma (MM); ARDS (acute respiratory distress syndrome); Interleukin6 (IL-6); Tocilizumab.

Published: November 1, 2020

Received: August 28, 2020

Accepted: October 22, 2020

Citation: Elsabah H., Aldapt M.B., Taha R., Soliman D.S., Elomri H., Ibrahim F. The outcome of six patients with COVID-19 infection and Multiple Myeloma. *Mediterr J Hematol Infect Dis* 2020, 12(1): e2020082, DOI: <http://dx.doi.org/10.4084/MJHID.2020.082>

This is an Open Access article distributed under the terms of the Creative Commons Attribution License (<https://creativecommons.org/licenses/by-nc/4.0>), which permits unrestricted use, distribution, and reproduction in any medium, provided the original work is properly cited.

To the editor.

In December 2019, coronavirus disease 2019 (COVID-19) emerged in the Chinese city Wuhan, caused by severe acute respiratory syndrome coronavirus 2 (SARS-CoV-2), later spread to become a worldwide pandemic.¹ It was shown that severe COVID-19 infection risk factors included older age, hypertension, respiratory disease, and cardiovascular disease.² In general, patients with cancer are at an increased risk of SARS-CoV-2 infection compared with the community; however, different tumor types have different susceptibility to COVID infection.³ Additionally, there is suggested evidence that patients with hematological malignancies are at higher risk of death from severe COVID-19 than the general population and patients with hematological malignancies without COVID.⁴ Multiple myeloma (MM) patients are highly susceptible to infections due to humoral and cellular immune dysfunction.

In contrast, COVID -19 infection is often associated with uncontrolled inflammatory response and cytokine release syndrome. There are limited data describing the impact of COVID-19 on MM patients. Herein, we report the outcome of six patients with MM and concomitant COVID-19 infection diagnosed between April 15, 2020, and June 30, 2020, admitted to tertiary care hospital in the state of Qatar. Two patients have newly diagnosed MM, and four were known myeloma cases who acquired the infection during the disease course. Four patients had a mild infection, and two patients had a severe and critical infection that required intensive care unit (ICU) admission; both cases were treated with Tocilizumab with variable response and outcome.

The first patient is a 42-year-old who presented with fever, cough, and sore throat for five days. Polymerase chain reaction (PCR) nasopharyngeal swab came positive for SARS-CoV-2. Laboratory workup revealed moderate anemia with Hemoglobin at 9.8 gm/dL (13.0-17.0 gm/dl) and increase in serum creatinine at 360 umol/L (62-124 umol/L) and total protein at 96 gm/L

(66-87 gm/L) with low albumin of 27 gm/L (35-52 gm/L) and normal calcium level. Further workup including serum protein electrophoresis (SPEP) showed monoclonal band typed as IgG lambda (28 g/L), light chain analysis revealed free light chain lambda at 14,170 mg/L (5.7-26.3 mg/L), with kappa/lambda ratio of <0.01 (0.26-1.65). Bence-Jones protein (BJP) was detected at 3.9 g/L and high Beta-2 microglobulin (B2M) at 20 mg/L (0.8-2.2 mg/L). The patient was treated with Hydroxychloroquine, Azithromycin and Dexamethasone 40 mg for four days (for 2 cycles) to treat MM. He was hospitalized for 21 days with an uneventful course. Bone marrow (BM) aspiration and biopsy were done and showed a 70% plasma cell infiltrate consistent with MM. Subsequently, the patient was started on Bortezomib 1.3 mg/m² on days 1, 4, 8, and 11, Cyclophosphamide 500 mg, and Dexamethasone 40mg weekly every 21 days cycle.

The second patient was a 41-year-old female with no chronic illness presented with fever, cough, and shortness of breath. A chest x-ray showed diffuse bilateral lung infiltrates (**Figure 1**).

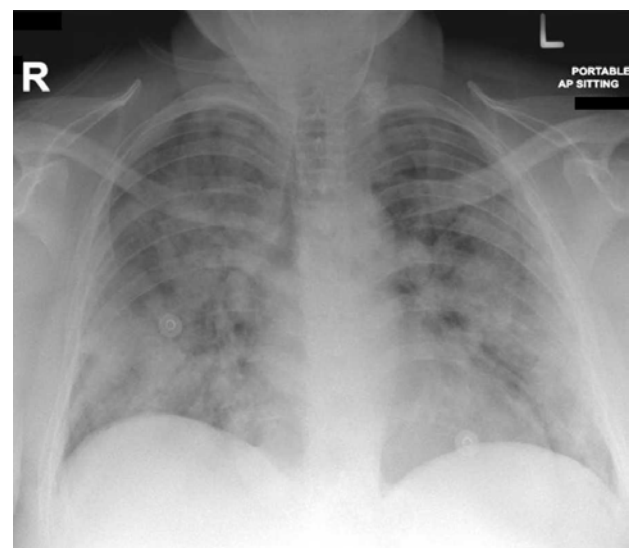


Figure 1. Chest x-ray for case (2) showing diffuse bilateral lung infiltrates.

COVID-19 infection was suspected and confirmed by PCR from a nasopharyngeal swab. Laboratory workup revealed severe anemia with Hgb of 6 g/dL (12-15 g/dL) and impaired renal function with a serum creatinine of 322 $\mu\text{mol/L}$ (62-124 $\mu\text{mol/L}$). SPEP revealed a small monoclonal band, while light chain analysis showed high free light chain kappa at 10,291 mg/L (3.3-19.4 mg/L), with a kappa/lambda ratio of 910 (0.26-1.65). The patient was started on Hydroxychloroquine and Azithromycin. On day 3 of admission, she was transferred to ICU due to an increase in her oxygen requirement. Serum IL-6 was found to be as high as 3,611 pg/mL (≤ 7 pg/mL). Tocilizumab, 400 mg, was started. Subsequently, her IL-6 dropped to 330 pg/mL.

Ten days later, the IL-6 level was increased to 4,800 pg/mL. Another dose of Tocilizumab 400 mg was given, resulting in a drop of IL-6 level to 211 pg/mL. Dexamethasone 40mg (2 cycles for four days) was started on which the patient showed significant improvement in her clinical situation and biochemical parameters with a significant reduction in free light chain kappa from 10,291 mg/L to 1,1470 mg/L (**Figure 2**). BM aspiration and biopsy were performed subsequently and revealed 20% plasma cell infiltration consistent with MM diagnosis. The patient was started on Bortezomib 1.5 mg/m² (day 1, 8, 15, 22) with Cyclophosphamide 500 mg and Dexamethasone 20mg weekly) every 28 days cycle.

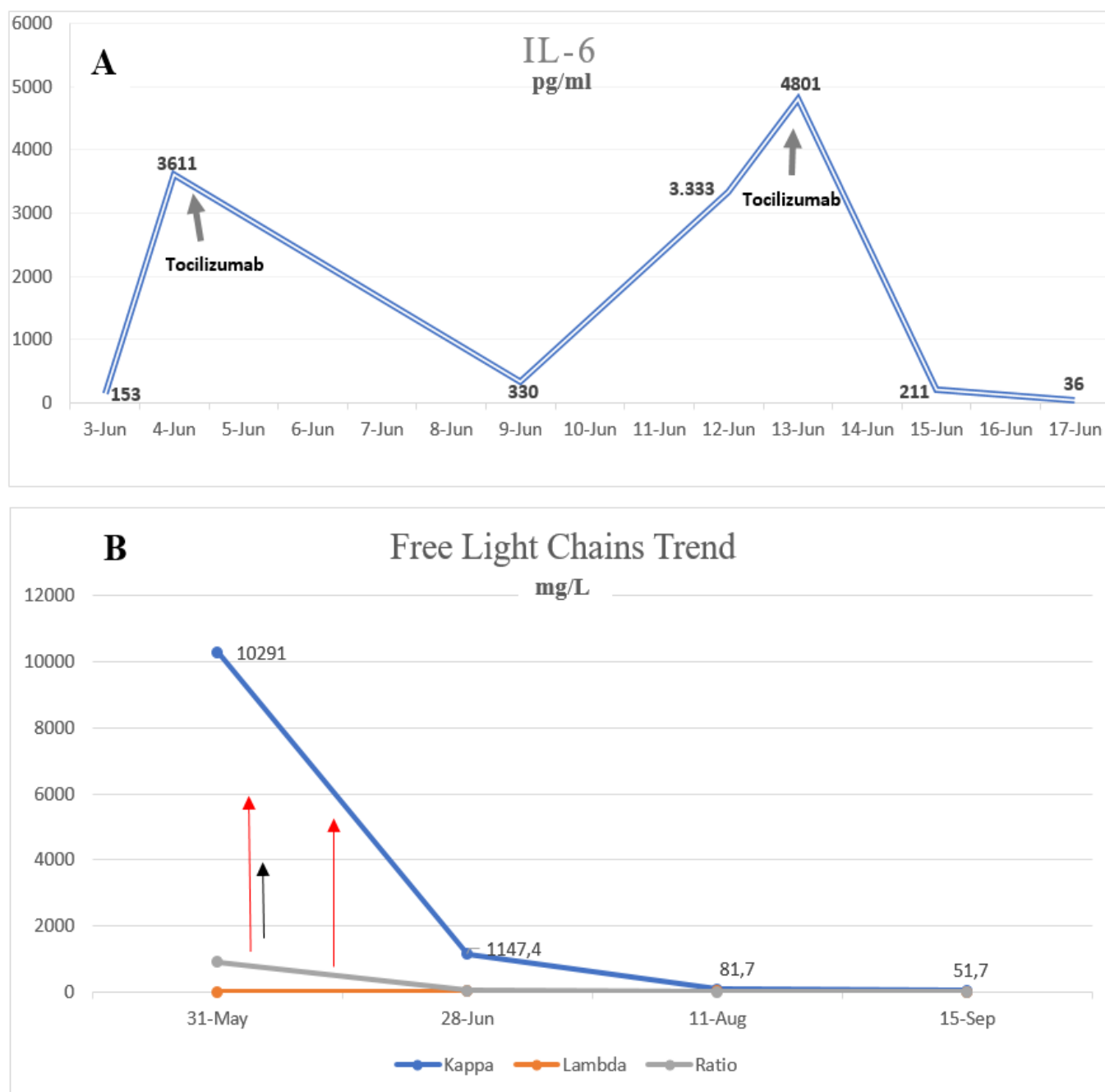


Figure 2. A graph showing base line serum level of Interleukin 6 and the effect of Tocilizumab (A) and the effect of Tocilizumab and Dexamethazone on Free light chain level (B).

The third patient is a 56-year-old male, known case of diabetes mellitus type 2 (DM2), and was diagnosed with IgG Kappa MM in 2015 and was treated previously with VCD protocol and autologous stem cell transplant (ASCT), followed by lenalidomide maintenance. He presented with mild COVID-19 pneumonia, which required hospitalization for ten days; he was treated with Hydroxychloroquine and Azithromycin and recovered completely from COVID-19 with an uneventful hospital course.

The fourth patient is a 70-year-old male with a background of DM2, dyslipidemia, and morbid obesity. He was diagnosed in 2005 with IgA Kappa MM and heavily pretreated previously with multiple lines of therapy, including Bortezomib, Immunomodulatory drugs (IMiDs), Daratumumab, Carfilzomib based therapy, and two autologous stem cell transplant. He presented with severe pneumonia secondary to COVID-19 infection, which required mechanical ventilation at day seven. COVID-19 treatment included Hydroxychloroquine, Azithromycin, Lopinavir/Ritonavir, and convalescent plasma. Tocilizumab at 8mg/kg was given for 3 doses for elevated IL6 level with rapid resolution of inflammatory markers but without significant clinical impact or response. The patient had a complicated ICU course with prolonged intubation, renal failure requiring hemodialysis, secondary bacterial infection, and encephalopathy. He died after 80 days after admission as result of COVID-19 related ARDS and significant comorbidities.

The fifth case is a 64-year-old male diagnosed in 2018 with smoldering myeloma. He presented with mild upper respiratory tract symptoms secondary to COVID-19 infection; his symptoms resolved after five days of Hydroxychloroquine and Azithromycin.

The sixth patient was a 55-year-old male diagnosed with MM IgG Kappa three months before presentation while receiving ongoing induction chemotherapy, consisting of Bortezomib, Lenalidomide, and Dexamethasone (VRD). He presented with mild upper respiratory tract symptoms secondary to COVID-19 that did not require hospitalization, and the patient resumed his chemotherapy 14 days after full recovery.

Herein, we report a heterogeneous group of multiple myeloma patients (in different phases) who had a concomitant COVID-19 with different severity. Out of the six patients with COVID-19 infection, two were newly diagnosed as MM at their initial hospital admission, and four patients were already known myeloma patients who acquired the infection during the disease course.

The latter group (four patients) includes one patient who got COVID-19 infection post ASCT while on

maintenance therapy; a second was on induction Bortezomib, Lenalidomide, and Dexamethasone (VRD) therapy. The third patient was a case of relapsed/refractory myeloma, who failed multiple previous lines of therapy. The fourth case was smoldering myeloma under observation. Detailed patients' and disease characteristics and laboratory findings were listed in **tables 1 and 2**.

Our cohort included four patients who had mild COVID-19 infection and two patients with severe critical disease. Only one patient died secondary to COVID-19 after a prolonged ICU course (80 days). These findings are contrary to those reported by Dhakal et al. in a recently published case series, which included seven patients with MM and COVID-19 infection, where all patients had an unfavorable disease course, three of the reported patients died, and four-needed ICU admission.⁵

Interleukin6 (IL-6) has an essential role in MM pathogenesis by interaction with adhesion molecules, tumor suppressor genes, oncogenes, and apoptosis inhibition in myeloma cells.⁶ The studies addressing Tocilizumab use, an interleukin-6 (IL-6) receptor antagonist, are still rather controversial. While some centers reported a significant effect in patients with COVID-19 infection,⁷ preliminary data from phase III clinical trials did not show any significant benefit.⁸

Two of our patients (case 2 and case 4) had received Tocilizumab; one of them had a dramatic response both in a clinical situation and biochemical parameters. The successful use of Tocilizumab in MM patients with COVID-19 was reported by Chandos et al.⁹ It is noteworthy that the high mortality rate in COVID-19 was suggested to be secondary to cytokine storm and inflammatory response, and it was noted that levels of IL-6 were associated with the severe COVID-19 pneumonia.¹⁰ These cases may emphasize the importance of using IL-6 antagonists in treating patients with COVID-19, especially in those diagnosed with MM.

There is no specific treatment for COVID-19 infection right now; however, many approaches have been tried, including a combination of antiviral, hydroxychloroquine, dexamethasone, and convalescent plasma with varying success rates. In this report, we present our experience in the management of MM in the era COVID-19 pandemic. The current data are still insufficient and rather contradictory. Further multicenter studies on a larger number of patients are needed to draw a definite conclusion regarding the role of using Tocilizumab in patients with COVID-19, generally and in Multiple Myeloma patients with associated COVID-19 infection.

Table 1. Clinicopathological characteristics, treatment and disease course for six patients with Multiple Myeloma and COVID-19 infection.

#	Gender	Age	Co-morbidities	MM subtype	COVID Symptoms	COVID category	COVID Treatment	MM phase	Hospital Stay, In days	ICU	Intubation	Outcome
1	M	42	None	IgG Lambda	Fever, Cough, Sore throat	Mild	Hydroxychloroquine, Azithromycin, Dexamethasone	New	21	No	No	Recovered
2	F	41	None	FLC Kappa	Fever, Cough, shortness of breath	Severe	Hydroxychloroquine, Azithromycin, Methylprednisolone, Tocilizumab	New	17	Yes	No	Recovered
3	M	56	Diabetes	IgG Kappa	Fever	Mild	Hydroxychloroquine, Azithromycin	Post-ASCT on maintenance Lenalidomide	10	No	No	Recovered
4	M	70	Diabetes, Morbid obesity	IgA kappa	Fever	Critical	Hydroxychloroquine, Azithromycin, Oseltamivir, Convalescent Plasma, Tocilizumab, Lopinovir/ritonavir	RR, post multiple lines of treatment and two times ASCT on carfilzomib-dexamethasone	80	Yes	Yes	Died
5	M	64	Radical nephrectomy	IgG kappa (smoldering)	Fever, Cough	Mild	Hydroxychloroquine, Azithromycin	Watch and Wait	5	No	No	Recovered
6	M	55	Diabetes, hypertension	IgG Kappa	asymptomatic	Mild	None	induction VRD	None	No	No	Recovered

FLC: Free light chain, ASCT: Autologous stem cell transplant, RR: Relapsed/refractory, VRD: Bortezomib, Lenalidomide, and Dexamethasone.

Table 2. Hematologic and biochemical characteristics of six patients with Multiple Myeloma and COVID-19 infection.

#	Baseline Blood Tests											
	WBCs x10 ³ /uL	Hgb gm/dL	PLT x10 ³ /uL	ANC x10 ³ /uL	ALC x10 ³ /uL	Creatinine umol/L	Calcium mmol/L	TP gm/L	Albumin 30 gm/L	LDH U/L	CRP mg/L	Ferritin ug/L
1	4.6	9.8	256	1.5	2.2	360	2.2	96	24	190	77	1071
2	5.0	6.0	215	2.0	2.4	322	2.2	71	37	380	35	646
3	3.1	12.0	122	2.0	0.8	83	2.3	85	39	NA	21	319
4	7.9	12.0	151	5.8	0.9	101	2.39	69	34	NA	59	330
5	4.9	13.0	109	2.0	2.0	118	2.1	84	34	NA	7	NA
6	6.2	12.2	256	2.9	1.9	62	2.34	66	34	NA	NA	NA

WBC: White blood cells, Hgb: Hemoglobin, ANC: Absolute neutrophil count, ALC: Absolute lymphocyte count, TP: Total protein, LDH: Lactate dehydrogenase, CRP: C-reactive protein, NA: Not available
Normal reference range: WBC: 4-10, Hgb:12-15, ANC:2-7, ALC: 1-3, Creatinin:44-80, Calcium: 2.1-2.5, TP:66-87, LDH:135-214, CRP:0-5, Ferritin: 12-114.

¹ Division of Hematology, Department of Medical Oncology, National Center for Cancer Care & Research (NCCCR), Hamad Medical Corporation (HMC), Doha, Qatar.

² Department of Laboratory Medicine and Pathology, National Centre for Cancer Care & Research (NCCCR), Hamad Medical Corporation (HMC), Doha, Qatar.

³ Department of Laboratory Medicine and Pathology, Weill Cornell Medical College (WCMC-Q), Doha, Qatar.

⁴ Clinical pathology department, National Cancer Institute, Cairo-Egypt

Competing interests: The authors declare no conflict of Interest.

Correspondence to: Prof Dina Soliman. E-mail: DSoliman@hamad.qa

References:

1. World Health Organization. Director-General's remarks at the media briefing on 2019-nCoV on February 11 2020. <https://www.who.int/dg/speeches/detail/who-director-general-s-remarks-at-the-media-briefing-on-2019-ncov-on-11-february-2020> (Accessed on February 12, 2020).
2. Yang J, Zheng Y, Gou X, et al. Prevalence of comorbidities and its effects in patients infected with SARS-CoV-2: a systematic review and meta-analysis. *Int J Infect Dis.* 2020;94:91-95. <https://doi.org/10.1016/j.ijid.2020.03.017> PMID:32173574 PMCID:PMC7194638
3. Lennard Y W Lee. COVID-19 prevalence and mortality in patients with cancer and the effect of primary tumour subtype and patient demographics: a prospective cohort study *Lancet Oncol* 2020; 21: 1309-16
4. Francesco Passamonti. Clinical characteristics and risk factors associated with COVID-19 severity in patients with haematological malignancies in Italy: a retrospective, multicentre, cohort study. *Lancet Haematol* 2020; 7: e737-45 Published Online August 13, 2020
5. Dhakal, B., D'Souza, A., Chhabra, S. et al. Multiple myeloma and COVID-19 Leukemia. (2020) 34:1961-1963 <https://doi.org/10.1038/s41375-020-0879-9> PMID:32475990
6. K Gadó, G Domján, H Hegyesi. Role of interleukin-6 in the pathogenesis of multiple myelom. *Cell Biology International* Volume 24, Issue 4, April 2000, Pages 195-209 <https://doi.org/10.1006/cbir.2000.0497> PMID:10816321
7. Pan Luo, Yi Liu, Lin Qiu, Xiulan Liu, Dong Liu, Juan Li. Tocilizumab treatment in COVID - 19: A single center experience *J Med Virol.* 2020,92:814-818. <https://doi.org/10.1002/jmv.25801> PMID:32253759 PMCID:PMC7262125
8. A Study to Evaluate the Safety and Efficacy of Tocilizumab in Patients With Severe COVID-19 Pneumonia (COVACTA) *ClinicalTrials.gov* Identifier: NCT04320615
9. Aristeidis Chaidos et al Interleukin 6 - blockade treatment for severe COVID - 19 in two patients with multiple myeloma *British Journal of Hematology.* May 2020 <https://doi.org/10.1111/bjh.16787> PMID:32369612
10. McGonagle D, Sharif K, O'Regan A, Bridgewood C. The Role of Cytokines including Interleukin-6 in COVID-19 induced Pneumonia and Macrophage Activation Syndrome-Like Disease. *Autoimmun Rev.* 2020;19(6):102537. <https://doi.org/10.1016/j.autrev.2020.102537> PMID:32251717 PMCID:PMC7195002