

Available online at www.sciencedirect.com

ScienceDirect

journal homepage: www.elsevier.com/locate/radcr

Case Report

Atypical presentation of a locally advanced hepatocellular carcinoma: Extensive workup of an incidental finding on computed tomography performed for planning of transcatheter aortic valve implantation[☆]

Julia Lueg, MD^a, Fabian Knebel, MD^a, Ibrahim Awwad, MD^b, Markus H. Lerchbaumer, MD^c, Ute Fahlenkamp, MD^c, Alexander Lembcke, MD^c, Julian Pohlan, MD^{c,d,*}

^a Department of Cardiology, Charité - Universitaetsmedizin Berlin, corporate member of Freie Universität Berlin and Humboldt Universität zu Berlin, Berlin, Germany

^b Department of Gastroenterology, Charité - Universitaetsmedizin Berlin, corporate member of Freie Universität Berlin and Humboldt Universität zu Berlin, Berlin, Germany

^c Department of Radiology, Charité - Universitaetsmedizin Berlin, corporate member of Freie Universität Berlin and Humboldt Universität zu Berlin, Berlin, Germany

^d Berlin Institute of Health at Charité – Universitätsmedizin Berlin, Charitéplatz 1, 10117 Berlin, Germany

ARTICLE INFO

Article history:

Received 22 January 2021

Revised 6 May 2021

Accepted 7 May 2021

Keywords:

TAVI

HCC

CTA

CEUS

MRI

ABSTRACT

This case report presents the diagnostic workup of liver malignancy incidentally detected in a 72-year-old male patient on routine body computed tomography angiography (CTA) performed for planning transcatheter aortic valve implantation (TAVI).

The patient initially presented to an outside hospital with chest discomfort, where routine diagnostic procedures in the emergency room revealed grade III aortic valve stenosis.

Routine CTA for TAVI planning in our department then revealed tumor thrombosis of the portal vein suspicious for hepatic malignancy.

In contrast-enhanced ultrasound (CEUS) only the left hepatic lobe was inhomogeneously transformed with early arterial contrast enhancement. Magnetic resonance imaging (MRI) confirmed a primary hepatic malignancy involving the left liver. Transcutaneous biopsy with ultrasound guidance established the diagnosis of hepatocellular carcinoma (HCC).

[☆] Competing interest: The authors declare no conflict of interest relevant to this work.

* Corresponding author.

E-mail address: julian.pohlan@charite.de (J. Pohlan).

<https://doi.org/10.1016/j.radcr.2021.05.021>

1930-0433/© 2021 The Authors. Published by Elsevier Inc. on behalf of University of Washington. This is an open access article under the CC BY-NC-ND license (<http://creativecommons.org/licenses/by-nc-nd/4.0/>)

Incidental findings may be of prognostic relevance for the patient and in a number of cases, TAVI can be a prerequisite for the appropriate therapy.

© 2021 The Authors. Published by Elsevier Inc. on behalf of University of Washington.

This is an open access article under the CC BY-NC-ND license (<http://creativecommons.org/licenses/by-nc-nd/4.0/>)

Introduction

Background

Aortic stenosis is the most common clinically relevant valvular disease in adults. Around 5% of people older than 65 years suffer from aortic stenosis [1]. Common symptoms are angina pectoris, dyspnea, and syncope; and the diagnosis is routinely made by transthoracic (TTE) and transoesophageal echocardiography (TEE). Current treatment options include surgical aortic valve replacement and transcatheter aortic valve implantation (TAVI).

To define the optimal therapeutic strategy for each patient individually, a “heart team” including surgeons and cardiologists discusses each case, deciding between surgery and minimally invasive treatment on the basis of the findings of diagnostic workup and individual risk factors, age, and comorbidities [2]. Pretherapeutic workup in our hospital includes computed tomography angiography (CTA) of the neck, chest, abdomen, and pelvis in order to both assess arterial access routes and rule out a malignant disease or other condition relevant for patient management.

A retrospective analysis has shown that up to 60% of incidental findings (IFs) on pre-TAVI CT scans are accounted for by potentially malignant lesions of abdominal [3]. Nevertheless, there is an ongoing discussion regarding the exact incidence of clinically significant IFs and their impact on further patient management and mortality [4–6]. Current guidelines require a life expectancy of >1 year to justify TAVI or surgical valve replacement [1].

Case presentation

We report the case of a 72-year-old male patient with severe aortic stenosis who was transferred to the Department of Cardiology of our hospital from an external hospital to undergo pretherapeutic assessment of suitability for TAVI or valve replacement.

Initially, the patient presented to the emergency room of an external hospital with a three day-history of persistent chest discomfort triggered by pressure and motion. The pain did not radiate or worsen with physical activity. The patient's comorbidities and medications on admission are summarized in Tables 1 and 2. Vital signs in the external emergency room were stable and within normal limits, and the ECG did not show any signs of acute coronary syndrome. Blood analysis revealed slightly elevated troponin T (22 ng/l) and only a nonsignificant further increase upon repeat measurement (26 ng/l), see Table 3. Liver function blood testing showed isolated elevation of gamma-GT (170 U/l), while bilirubin and GPT/ALT were within the normal range. With this presentation and a high cardiovascular risk profile, the

Table 1 – Comorbidities. The comorbidities of the patient include two risk factors for hepatocellular carcinoma (HCC).

Comorbidities
Diabetes mellitus type II
Hypertension
Dyslipidemia
Chronic obstructive pulmonary disease (COPD)
Hepatitis C (diagnosed in 2001, treated with interferon until 2002)
Current smoker (50 PY)
History of alcohol abuse (7 glasses of beer/day for 20 years, discontinued 30 years ago)

Table 2 – Medication. Medication includes antihypertensive medication as well as diuretics, as relevant for this patient's aortic valve stenosis.

Medications on admission
Metformin, 1000mg, and sitagliptin, 100mg
ACE-inhibitor (Ramipril 5mg)
Beta-blocker (bisoprolol 10mg)
Diuretic (furosemide 40mg)
Statin (Atorvastatin 20mg)
Inhaled parasympatholytic agent (aclidinium bromide/formoterol fumarate dihydrate 340µg)

patient was admitted to the cardiology unit of the external hospital. Coronary angiography performed to evaluate for non-ST elevation myocardial infarction (NSTEMI) as a cause of the patient's symptoms ruled out clinically significant coronary heart disease. TTE revealed a severe aortic stenosis (AVA VTI: 0.8 cm², AV p_{mean}: 30 mmHg), confirmed by TEE. The patient was discharged from the external hospital and electively readmitted to the Department of Cardiology of our hospital for further diagnostic workup and to decide about the appropriate treatment strategy.

On admission to our hospital, the patient denied epigastric pain, typical angina pectoris, syncope or dizziness. Upon further questioning, however, the patient reported night sweats and an unplanned weight loss of six kilograms over the last three months.

For planning of valve replacement, the patient underwent routine whole-body CTA on a 320-row CT scanner (Canon Medical Systems, Ottawa, Japan). Automated exposure calculation was used for dose calculation. Images were acquired at 100 kV. The scanned regions included the neck, chest, and abdomen/pelvis for planning TAVI according to our department's standard protocol. CTA was performed with

Table 3 – Laboratory findings. Laboratory findings included a elevation of GGT initially with no other signs of liver damage. Extensive laboratory evaluation also showed elevation of GOT, AP and AFP.

Value	Reference	External Hospital	This institution	
Date		15.10.20	29.11.20	16.12.20
Bilirubin, total	< 1.2 mg/dl	0.4 mg/dl	0.51 mg/dl	0.32 mg/dl
GPT/ALT	< 41 U/l	23 U/l	20 U/l	30 U/l
GOT/AST	< 50 U/l		59 U/l	59 U/l
GGT	8-61 U/l	170 U/l	197 U/l	247 U/l
AP	40-130 U/l		157 U/l	208 U/l
LDH	135-250 U/l	240 U/l	218 U/l	226 U/l
Lipase	13-60 U/l	14 U/l	12 U/l	16 U/l
Albumin	35- 52 g/l		38.2 g/l	
Quick	70 - 130 %	97%	103%	
INR	0.9 – 1.25	1.02	1.0	
PTT	26.0-40.0 s	32 s	23.6 s	
AFP	<7 µg/l		23.9 µg/l	

ALT – alanine aminotransferase; AST – aspartate aminotransferase; GGT - gamma glutamyl transferase; GPT – glutamate pyruvate transaminase; LDH - lactatdehydrogenase; INR – international normalized ratio; PTT – partial thromboplastin time; s – seconds; U – units; l – liters; g - grams.

intravenous administration of contrast agent (iopromide, Ultravist 370, Bayer, Leverkusen, Germany; body-weight adapted dosage). Reconstructions included axial, coronal, and sagittal reformations at 1 mm and 5 mm slice thickness.

CTA revealed a central portal venous thrombosis with morphologically altered liver parenchyma of the left lobe but no evidence of a demarked focal liver lesion (Fig. 1).

For further characterization of the liver parenchyma and in search of a focal mass, contrast-enhanced ultrasound (CEUS) was performed. There was no evidence of cirrhosis or of a nodular mass on B-mode. CEUS confirmed tumor thrombosis of the portal vein and showed a reduced echogenicity of the entire left liver lobe, strictly respecting the segmental borders. In the venous phase (3 min after contrast injection), only a subtle washout in the superficial area of the left liver lobe (subcapsular) was appreciated, while the transformed left liver lobe showed incomplete washout. The superficial washout could also be interpreted as bubble destruction in the nearfield due to continuous scanning over three minutes (Fig. 2).

Additionally, the patient underwent abdominal magnetic resonance imaging (MRI) at 3.0 T using phased-array body coils. The MRI protocol included T2-weighted (w) standard 2D sequences with and without fat saturation (FS) and T1-w unenhanced 2D sequences with and without FS (including in-/opposed phase technique). T1-w 3D sequences with FS were acquired during breath-holds before and after intravenous administration of gadoxetic acid (Primovist; Bayer Pharma, Leverkusen, Germany; automatic injection at 1 mL/s flow rate followed by a 40 mL saline flush; body-weight-adapted dose). Postcontrast images were acquired during the arterial, portal venous, and venous phase. To image the hepatobiliary phase, the T1-w 3D sequence was acquired 20 minutes after

contrast agent administration in both axial and coronal orientation. MR images showed a diffusely increased T2 signal throughout the left liver lobe with diffusion restriction on diffusion-weighted imaging, a slight arterial hyperenhancement followed by washout on portal venous and venous phases. The left liver lobe showed no hepatocyte uptake on hepatobiliary T1-w sequences (Fig. 3). A diffusely growing primary hepatic malignancy was suspected.

Next, the patient was scheduled for percutaneous ultrasound-guided biopsy for histopathological evaluation in the Department of Gastroenterology and Hepatology. The procedure was performed under sterile conditions after local anesthesia. Histology confirmed poorly to moderately differentiated hepatocellular carcinoma (HCC) with Hepar 1 staining indicating cytoplasmic expression, and a proliferation rate of 50% as determined with Ki 67.

Repeat laboratory testing of liver function confirmed elevated gamma-GT while all other parameters including bilirubin, Liver enzymes, coagulation, and albumin were normal. Of note, there was a small but significant increase in alpha-fetoprotein (AFP).

An interdisciplinary tumor board planned further patient management, opting for treatment with atezolizumab and bevacizumab due to advanced disease with HCC invasion of the portal vein, corresponding to Barcelona Clinic Liver Cancer Classification (BCLC) stage C. Cardiological management has been postponed and depends on the response to HCC treatment.

Discussion

This case illustrates the multifaceted diagnostic workup of an incidental liver tumor in a 72-year-old male patient with severe aortic stenosis.

Incidental findings are common in patients undergoing pretherapeutic diagnostic workup before surgical aortic valve replacement or interventional TAVI [3]. It is a daily challenge for the medical specialties involved to decide about the relevance of such an incidental finding for the patient's further treatment. The detection of possible malignancy is an important concern since TAVI is only recommended for patients with a life expectancy of at least one year. Therefore, pretherapeutic planning and diagnostic workup in these patients require close cooperation of several specialties.

Diagnostic workup of suspected hepatic malignancy with vascular invasion in our patient was necessary because the initial CTA findings did not allow to narrow down the differential diagnosis. The CEUS examination distinguished a normal right hepatic lobe and diffusely infiltrated left liver lobe based on early enhancement. Still, two highly experienced ultrasound examiners were not able to identify a focal lesion within the transformed left liver lobe. According to the current European Federation of Ultrasound in Medicine and Biology (EFSUMB) guidelines, CEUS is validated for the characterization of focal liver lesions already detected on B-mode US [7]. Thus, CEUS should be seen only as an alternative imaging modality in the evaluation of diffuse tumor infiltration of the liver. Moreover, the short duration of the arterial phase of 10-

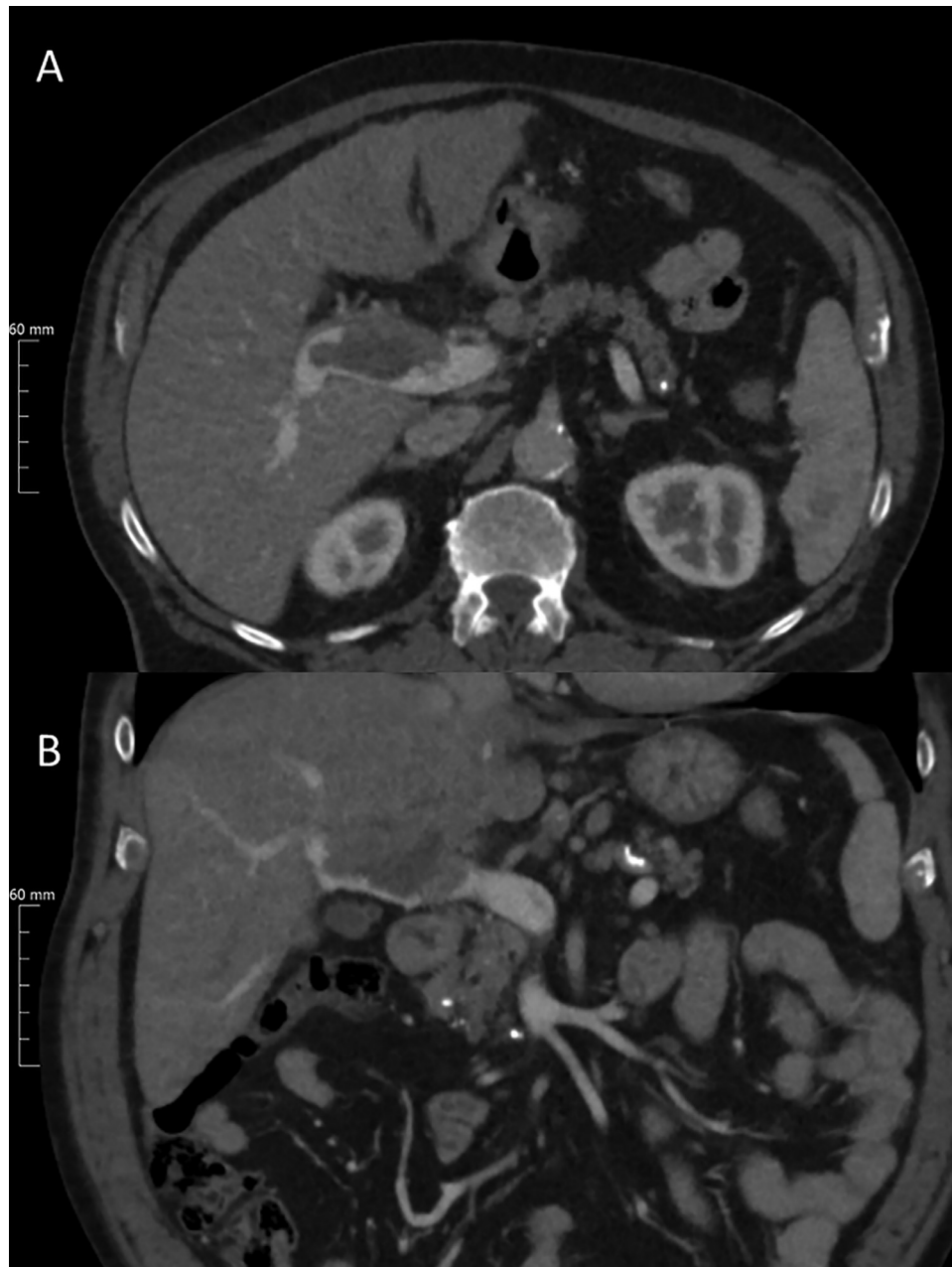


Fig. 1 – Incidental hepatocellular carcinoma (HCC) in a 72-year-old patient. Tumor thrombosis of the portal vein and altered tissue structure on CTA in axial (A) and coronal 4 mm reformation (B). Diagnosis of a diffusely growing primary liver tumor with portal vein thrombosis, subsequently confirmed upon biopsy.

20 sec in CEUS makes adequate assessment of the whole liver impracticable and challenging, and HCC lesions, which have been reported to show arterial-phase hyperenhancement [7], may be missed.

Additional MRI revealed diffuse tumor growth confined to the left liver lobe. A preliminary diagnosis of primary hepatic malignancy was made with no signs of cirrhosis. Histopathology of a percutaneous biopsy specimen confirmed this diffusely infiltrative malignancy to be due to HCC. Diffuse HCC is a rare subtype, and intrahepatic nodules are the typical imaging finding [8].

Another noteworthy finding in our patient was that HCC occurred without any signs of liver cirrhosis. However, the patient had two well-established risk factors for HCC [9]. First, the patient had a history of hepatitis C, treated with interferon for one year in 2001. Regular routine outpatient controls had been carried out but were uneventful prior to his hospitalization. Second, the patient had a history of alcohol abuse. HCC is the most common primary liver malignancy in a cirrhotic patient [10]. The patient did not have cirrhosis on imaging.

Given this complex situation in our patient, the chest discomfort that led him to present to an emergency room

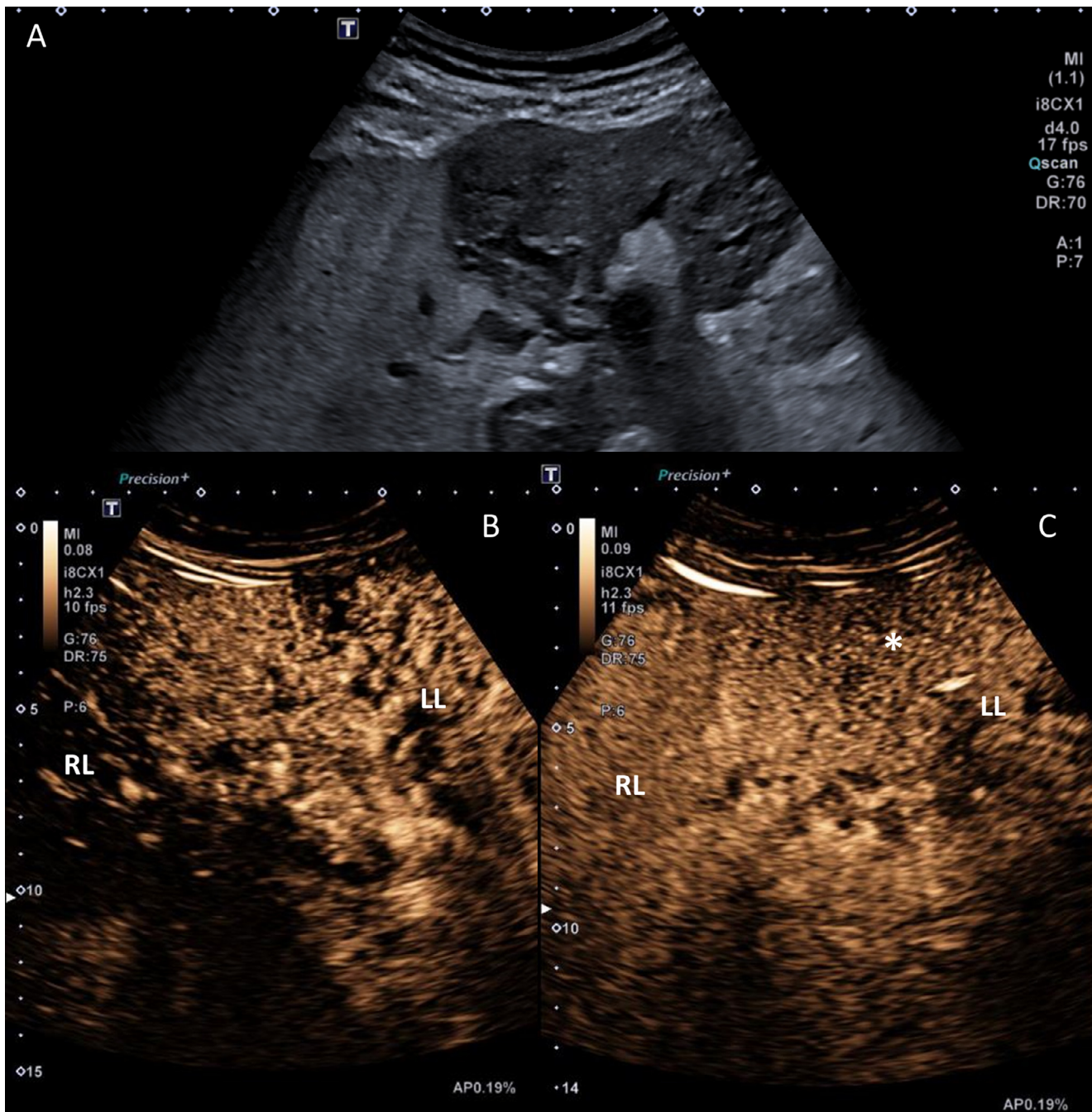


Fig. 2 – Ultrasound with B-mode indicating a diffusely altered echogenicity of the left liver lobe (A). Contrast-enhanced ultrasound (CEUS) images acquired in arterial phase (after 33 seconds, B) and late venous phase (after 3 min, C) show early arterial inflow in the left liver lobe (LL) compared to the right liver lobe (RL). Washout in the left lobe (asterisk) was only present in superficial area, while the dynamic examinations cannot differentiate real lesion washout from bubble destruction in the near field, as the left lobe showed inhomogeneous washout in the late contrast phase.

might also have been caused by advanced stage HCC with tumor thrombosis of the portal vein rather than severe aortic stenosis. This stresses the importance of a holistic analysis of the patient's symptoms in the emergency room. An abdominal ultrasound examination at the time of initial presentation would have led to earlier detection of hepatic malignancy.

In the meantime, the patient showed tumor response in an outside follow-up study and successfully received TAVI.

Finally, our patient had two advanced and possibly life-threatening diseases, giving rise to the question of priority and extent of treatment. Such cases nicely illustrate the importance of interdisciplinary conferences such as tumor boards and “heart teams”, which can find an optimal treatment strat-

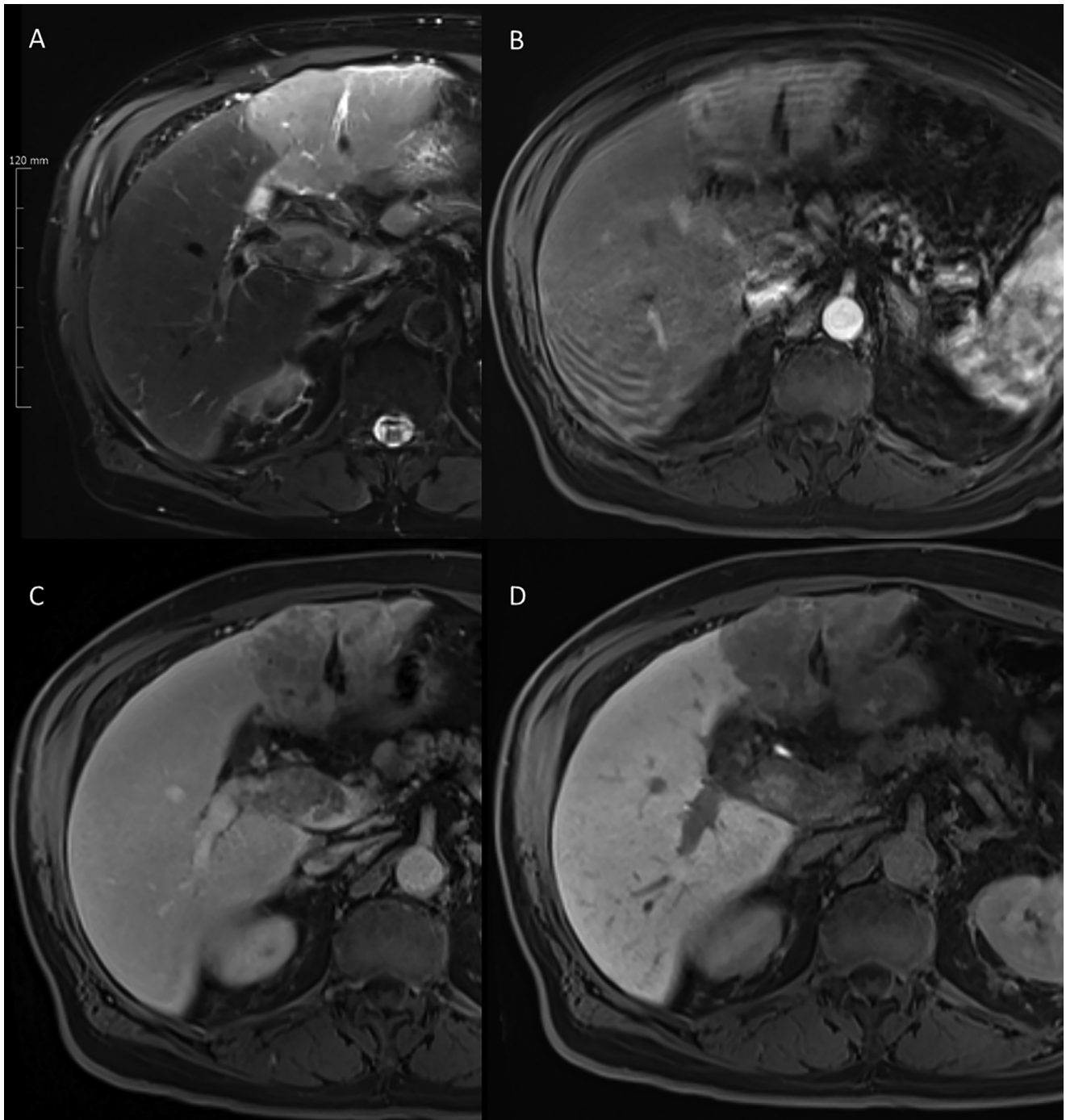


Fig. 3 – MRI showed a T2 hyperintense left lobe (A) with early enhancement on arterial phase (B). Washout of the altered left liver lobe can be appreciated on portal venous and venous phase (C). The left liver lobe showed no hepatocyte uptake during the hepatobiliary phase (D).

egy for the individual patient that takes duly takes individual needs into account.

Conclusion

This case illustrates the extensive diagnostic workup of an incidental HCC with portal vein thrombosis on CTA conducted

for TAVI planning. The requirement of a 12-month life expectancy in candidates for aortic valve replacement makes it necessary to carefully search for malignancy, as demonstrated by the patient presented here. Incidental findings may be of prognostic relevance for the patient and in a number of cases, TAVI can be a prerequisite for the appropriate therapy. A routine body CT, the standard in our hospital, allows planning of the intervention or surgery while at

the same time ruling out therapeutically relevant incidental findings.

Patient consent

The patient provided written consent for the anonymous publication of this case report.

REFERENCES

- [1] Nkomo VT, Gardin JM, Skelton TN, Gottdiener JS, Scott CG, et al. Burden of valvular heart diseases: a population-based study. *Lancet* 2006;368(9540):1005–11.
- [2] Kuck HE K-H, Figulla HR, Haude M, Katus H, Möllmann H, Naber CK, et al. Qualitätskriterien zur Durchführung der transkathetären Aortenklappenimplantation (TAVI). *Der Kardiologe*; 2014.
- [3] Patel A, Mahendran K, Collins M, Abdelaziz M, Khogali S, Luckraz H. Incidental abnormal CT scan findings during transcatheter aortic valve implantation assessment: incidence and implications. *Open Heart* 2018;5(2): e000855.
- [4] Hinton J, Gough S, Ahmed H, Gabara L, Rawlins J, Calver A, et al. Frequency and impact of incidental findings on computed tomography during work-up for transcatheter aortic valve implantation: single centre experience and review of the literature. *Br J Radiol* 2019;92(1102):20190344.
- [5] Trenkwalder T, Lahmann AL, Nowicka M, Pellegrini C, Rheude T, Mayr NP, et al. Incidental findings in multislice computed tomography prior to transcatheter aortic valve implantation: frequency, clinical relevance and outcome. *Int J Cardiovasc Imaging* 2018;34(6):985–92.
- [6] Feyz L, El Faquir N, Lemmert ME, Misier KR, van Zandvoort LJC, Budde RPJ, et al. Prevalence and consequences of noncardiac incidental findings on preprocedural imaging in the workup for transcatheter aortic valve implantation, renal sympathetic denervation, or MitraClip implantation. *Am Heart J* 2018;204:83–91.
- [7] Dietrich CF, Nolsøe CP, Barr RG, Berzigotti A, Burns PN, Cantisani V, et al. Guidelines and good clinical practice recommendations for contrast-enhanced ultrasound (ceus) in the liver-update 2020 WFUMB in cooperation with efumb, afumb, aium, and flaus. *Ultrasound Med Biol* 2020;46(10):2579–604.
- [8] Kanematsu M, Semelka RC, Leonardou P, Mastropasqua M, Lee JK. Hepatocellular carcinoma of diffuse type: MR imaging findings and clinical manifestations. *J Magn Reson Imaging: JMRI* 2003;18(2):189–95.
- [9] Trichopoulos D, Bamia C, Lagiou P, Fedirko V, Trepo E, Jenab M, et al. Hepatocellular carcinoma risk factors and disease burden in a european cohort: a nested case-control study. *JNCI* 2011;103(22):1686–95.
- [10] Tang A, Bashir MR, Corwin MT, Cruite I, Dietrich CF, Do RKG, et al. Evidence supporting li-rads major features for ct- and mr imaging-based diagnosis of hepatocellular carcinoma: a systematic review. *Radiology* 2018;286(1):29–48.