



Case Report

## Cervical C7 ganglion cyst causing compressive myelopathy: A rare case report

Charandeep Singh Gandhoke<sup>1</sup>, Siu Kei David Mak<sup>1</sup>, Nishal Kishinchand Primalani<sup>1</sup>, Eng Tah Goh<sup>1</sup>, Hwei Yee Lee<sup>2</sup>, Colum Patrick Nolan<sup>1</sup>

Departments of <sup>1</sup>Neurosurgery, National Neuroscience Institute, <sup>2</sup>Pathology, Tan Tock Seng Hospital (TTSH), Singapore.

E-mail: \*Charandeep Singh Gandhoke - charandeepsingh2008@gmail.com; Siu Kei David Mak - david.mak@mohh.com.sg; Nishal Kishinchand Primalani - nishal.primalani@mohh.com.sg; Eng Tah Goh - get032002@hotmail.com; Hwei Yee Lee - hwei\_yee\_lee@ttsh.com.sg; Colum Patrick Nolan - colum.nolan@singhealth.com.sg



**\*Corresponding author:**

Charandeep Singh Gandhoke,  
9B, (2nd Floor), Cycle  
Merchant Society, Rasta Peth,  
Near YMCA, Near Hotel  
Shantai, Pune – 411011,  
Maharashtra, India.

charandeepsingh2008@gmail.com

### ABSTRACT

**Background:** Juxtafacet cysts, synovial and ganglion cysts, emanate from the facet joints. Patients with these cysts are typically asymptomatic but may rarely present with radiculopathy and/or myelopathy.

**Case Description:** A 72-year-old female presented with a 1-month history of progressive lower extremity weakness (left more than right), numbness, and urinary incontinence. Notably, she also had a C7 sensory level to pin appreciation of 1-month duration. The magnetic resonance imaging showed an extradural C7 cystic lesion whose capsule enhanced with gadolinium, causing severe cord compression. The patient underwent a left C7 hemilaminectomy for complete excision of the cyst; postoperatively in 2-weeks duration, she regained full neurological function. The final histopathology was consistent with a ganglion cyst.

**Conclusion:** Cervical juxtafacet cysts rarely cause compressive myelopathy. They may be readily diagnosed and resected with excellent postoperative outcomes.

**Keywords:** Cervical, Compressive, Ganglion cyst, Juxtafacet cyst, Myelopathy.

### INTRODUCTION

Juxtafacet cysts (ganglion and synovial) emanate from the facet joints. They are mostly asymptomatic but can occasionally contribute to radiculopathy and/or myelopathy.

### CASE REPORT

A 72-year-old female presented with a 1-month history of a C7 sensory level to pin appreciation accompanied by progressive lower extremity weakness (left more than right), numbness, and urinary incontinence. The T1-weighted magnetic resonance (MR) study showed an iso/hypointense extradural lesion on the left side of the spinal canal at the C7 level contributing to marked cord compression. It was hyperintense on the T2-weighted MR study, and the cyst wall enhanced with the administration of gadolinium [Figure 1].

Received : 25 February 19  
Accepted : 19 March 19  
Published : 24 April 19

DOI  
10.25259/SNI-153-2019

Quick Response Code:



This is an open-access article distributed under the terms of the Creative Commons Attribution-Non Commercial-Share Alike 4.0 License, which allows others to remix, tweak, and build upon the work non-commercially, as long as the author is credited and the new creations are licensed under the identical terms.

©2019 Published by Scientific Scholar on behalf of Surgical Neurology International

©2019 Published by Scientific Scholar on behalf of Surgical Neurology International

### Left C7 hemilaminectomy/operative findings

The patient underwent a left C7 hemilaminectomy for complete excision of the cyst. At surgery, the juxtafacet cyst wall was fibrous and densely adherent to the dura; the cyst itself contained gelatinous material. Notably, there was no obvious communication with the left C7-T1 facet joint cavity [Figure 2].

### Histopathology

On histopathological examination, portions of the fibrous cyst wall showed no discernible internal lining. However, mucoid and basophilic calcified material was seen in the lumen of the cyst. This, accompanied by myxoid degeneration within the cyst wall, was consistent with a diagnosis of a ganglion cyst [Figure 3]. Postoperatively, the patient fully recovered in 2 weeks.

## DISCUSSION

### Location and frequency of juxtafacet cysts

Juxtafacet cysts are intraspinal, extradural, and benign cysts located near/contiguous with the facet joints. They are most common in the lumbar spine (95%) followed by the cervical spine (3.5%) and thoracic regions (1.5%).

### Etiopathogenesis of juxtafacet cysts

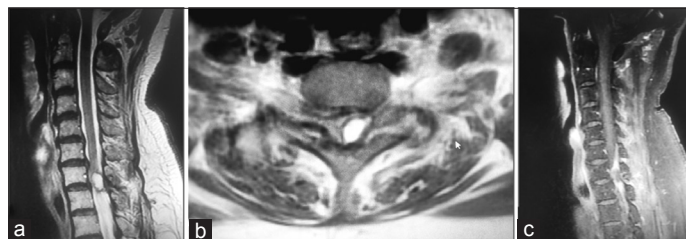
These lesions are attributed to facet joint degeneration, for example, erosion through the wall of the facet joint capsule due to microinstability and repetitive microtrauma.<sup>[5]</sup> The synovium then extrudes through the joint capsule, yielding an intracanalicular synovial cyst. Upregulation of inflammatory factors (e.g., angiopoietin-1, basic fibroblast growth factor, substance P, platelet-derived growth factor, and interleukins) at the site of the mechanically stressed facet joint, further contribute to synovial hyperplasia and cyst formation.<sup>[5]</sup> In a few cases, communication with the facet capsule is lost, and with further myxoid degeneration, this leads to the formation of a ganglion cyst.<sup>[1,2,4,8,9]</sup>

### Comparison between synovial versus ganglion cysts

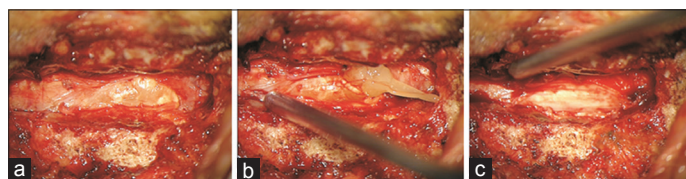Both synovial and ganglion cysts have an external layer covered by connective tissue. However, synovial cysts communicate with the facet joint, and the internal lining is made up of pseudostratified columnar cells, accompanied by a clear serous content.<sup>[1-4,8,9]</sup>

### Location and diagnosis of juxtafacet cysts

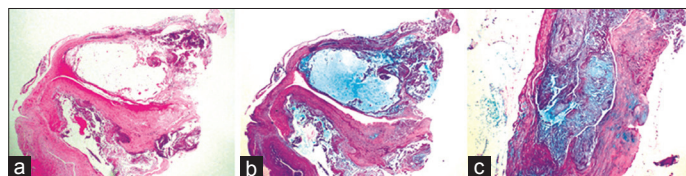
Cervical juxtafacet cysts are most commonly located at the cervicothoracic junction (e.g., C7-T1: a transitional level).<sup>[5]</sup> Contrast-enhanced MR imaging is the optimal study for diagnosing juxtafacet cysts, as the capsule typically uniformly



**Figure 1:** Magnetic resonance imaging of the cervical spine suggestive of (a and b) T2 hyperintense extradural C7 cystic lesion causing severe cord compression with a displacement of the spinal cord to the right. (c) The cyst wall enhanced with the administration of gadolinium.



**Figure 2:** (a) Intraoperative photograph showing a cervical extradural ganglion cyst with severe cord compression. (b) The cyst contains gelatinous material. (c) After complete excision of the cyst, the spinal cord is well decompressed.



**Figure 3:** (a) Hematoxylin and eosin  $\times 40$  magnification: a low power view showing a part of the fibrous cyst wall without a discernible internal lining. Mucoid and basophilic calcified material is seen. (b) Alcian blue - Periodic Acid Schiff (PAS)  $\times 40$  magnification: highlights the mucoid material in the lumen of the cyst. (c) Alcian blue - PAS  $\times 100$  magnification: another area showing myxoid degeneration in the cyst wall, consistent with a ganglion cyst.

enhances with gadolinium.<sup>[7]</sup> Those containing serous fluids are usually hypointense on T1 and hyperintense on T2-weighted MR studies. Gelatinous cysts may alternatively appear isointense on both T1- and T2-weighted MR images.<sup>[7]</sup>

### Treatment of cervical juxtafacet cysts

Most symptomatic juxtafacet cysts should be surgically excised. Extensive laminectomy may be required if there is attendant multilevel stenosis/spondylosis. Fusion may only be warranted in the few cases where frank documented instability is present and/or when lesions are located at the cervicothoracic junction.<sup>[1,6]</sup> Early diagnosis and complete surgical excision of these cysts usually leads to full neurological recovery as documented in this case study.

## CONCLUSION

Cervical juxtafacet cysts rarely cause compressive myelopathy. They may be readily diagnosed and resected with excellent postoperative outcomes.

## Declaration of patient consent

The authors certify that they have obtained all appropriate patient consent forms. In the form, the patient has given her consent for her images and other clinical information to be reported in the journal. The patient understands that her name and initials will not be published and due efforts will be made to conceal her identity, but anonymity cannot be guaranteed.

## Financial support and sponsorship

Nil.

## Conflicts of interest

There are no conflicts of interest.

## REFERENCES

1. Bydon M, Lin JA, de la Garza-Ramos R, Sciubba DM, Wolinsky JP, Witham TF, *et al.* The role of spinal fusion in the treatment of cervical synovial cysts: A series of 17 cases and meta-analysis. *J Neurosurg*

- Spine 2014;21:919-28.
2. Epstein NE, Hollingsworth R. Synovial cyst of the cervical spine. *J Spinal Disord* 1993;6:182-5.
3. Kao CC, Winkler SS, Turner JH. Synovial cyst of spinal facet. Case report. *J Neurosurg* 1974;41:372-6.
4. Lunardi P, Acqui M, Ricci G, Agrillo A, Ferrante L. Cervical synovial cysts: Case report and review of the literature. *Eur Spine J* 1999;8:232-7.
5. Lyons MK, Birch BD, Krauss WE, Patel NP, Nottmeier EW, Bo K, *et al.* Subaxial cervical synovial cysts: Report of 35 histologically confirmed surgically treated cases and review of the literature. *Spine (Phila Pa 1976)* 2011;36:E1285-9.
6. Rahimizadeh A, Soufiani H, Hassani V, Agari N, Amirzadeh M, Ava R. Cervical subaxial synovial cyst with progressive myelopathy: Report of a case and review of the literature. *World Spinal Column J* 2016;7: 189-94.
7. Sasamori T, Hida K, Anzai K, Yano S, Kato Y, Tanaka S, *et al.* A case of cervical juxtafacet cyst with extensive rim enhancement on Gd-DTPA MRI. *Clin Imaging* 2014;38:199-201.
8. Shima Y, Rothman SL, Yasura K, Takahashi S. Degenerative intraspinal cyst of the cervical spine: Case report and literature review. *Spine (Phila Pa 1976)* 2002;27:E18-22.
9. Song JK, Musleh W, Christie SD, Fessler RG. Cervical juxtafacet cysts: Case report and literature review. *Spine J* 2006;6:279-81.

**How to cite this article:** Gandhoke CS, Mak SK, Primalani NK, Goh ET, Lee HY, Nolan CP. Cervical C7 ganglion cyst causing compressive myelopathy: A rare case report. *Surg Neurol Int* 2019;10:61.