


Disseminated Nontuberculous Mycobacterium Presenting as Chronic Diarrhea and Wasting

Journal of Investigative Medicine High Impact Case Reports
Volume 10: 1–4
© 2022 American Federation for Medical Research
DOI: 10.1177/23247096221101860
journals.sagepub.com/home/hic


Manasi Singh, MD¹  and Marc Heincelman, MD, MPH¹

Abstract

Infections due to nontuberculous mycobacterium (NTM) are important in chronically immunosuppressed populations and are a particular threat to solid organ transplant recipients (SOT). However, they are not a common occurrence and have protean manifestations, making it important that clinicians maintain a high degree of suspicion in the correct patient population. *Mycobacterium avium* complex (MAC) usually presents with pulmonary involvement in immunocompetent population and disseminated disease in SOT patients with fever of unknown origin, lymphadenopathy, and cutaneous lesions being part of the well-known presentation. It is not commonly described as causing severe diarrhea. Here, we present an interesting case of a patient with a kidney and pancreas transplant who presented with debilitating wasting and chronic diarrhea. Biopsies and cultures confirmed MAC. To our knowledge, this is the first case report of MAC causing severe wasting diarrhea in renal transplant patients. The patient was treated with a multidrug regimen. Given the rare presentation of MAC presenting as chronic diarrhea, the treatment regimen is not standardized and infectious disease specialists should be involved early on. Up to 30% of renal transplant patients infected with NTM lose graft function and 20% die. Unfortunately, our patient suffered both these outcomes.

Keywords

solid organ transplant, nontuberculous mycobacteria, *Mycobacterium avium* complex, diarrhea

Case Presentation

A 61-year-old woman with a kidney-pancreas transplant in 2004 followed by a second kidney transplant in 2017 presented to the emergency department with recurrent falls in the setting of several weeks of diarrhea with generalized weakness and progressive bilateral lower extremity swelling. Prior to admission, the patient was having 6 to 7 loose bowel movements per day for 2 weeks. The number of episodes and volume were not affected by food intake. The large-volume, high-frequency diarrhea was debilitating and subsequently led to decreased oral intake and a decline in her overall nutritional status. Additional medical history was pertinent for type 2 diabetes. For her transplantation, she had been induced with anti-thymocyte globulin, and maintenance immunosuppression at the time of admission consisted of tacrolimus, mycophenolate mofetil, and prednisone. Social history was unremarkable. She lived alone, denied sick contacts, did not smoke or drink, and had not traveled in or outside the country.

On admission to our institution, vital signs demonstrated a temperature of 36.4°C, blood pressure of 131/68 mm Hg, heart rate of 64 beats per minute, respiratory rate of 16

breaths per minute, and oxygen saturation of 97% on room air. Her weight was 47.2 kg and body mass index was 17.32 kg/m². Physical examination revealed a pale, frail, ill-appearing lady with generalized muscle wasting in her extremities, bilateral temporal wasting, and loss of her buccal pad of fat. She had 2 plus pitting lower extremity edema up to the hips. There was no fluid wave on abdominal examination.

Renal function tests demonstrated a creatinine of 4.5 mg/dL (increased from baseline 3.5 mg/dL), blood urea nitrogen of 65 mg/dL, and bicarbonate of 16 mmol/L. Serum albumin was 1.7 g/dL. Complete blood count demonstrated hemoglobin of 6.8 g/dL (baseline, 7.5–9 g/dL), mean corpuscular volume of 91.5 fL, and white blood cell

¹Medical University of South Carolina, Charleston, USA

Received March 19, 2022. Revised April 18, 2022. Accepted May 1, 2022.

Corresponding Author:

Manasi Singh, MD, Department of Internal Medicine, Medical University of South Carolina, 135 Rutledge Avenue, Rm 1224, Charleston, SC 29425, USA.

Email: singhma@musc.edu



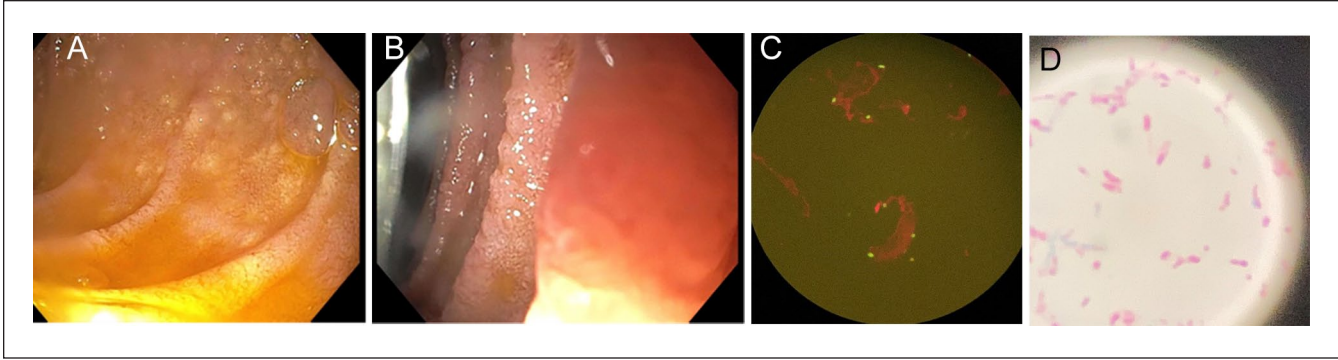


Figure 1. (A) Enteroscopy showing duodenal mucosal nodularity, seen more clearly on (B). (C) Fluorescent acid fast bacilli (AFB) seen on dark background, auramine-rhodamine stain, 40 \times . (D) Numerous AFB seen on Ziehl-Neelsen stain, oil immersion 100 \times .

count of 6.37K/cumm. Gastrointestinal (GI) polymerase chain reaction was tested and was negative on 2 occasions. Fecal calprotectin and fecal leucocytes were also negative. The stool was negative for cyclospora.

Due to her severe diarrhea and cytomegalovirus (CMV) plasma viral load of 1823 IU/mL, intravenous ganciclovir was started for a presumed diagnosis of CMV colitis. Colonoscopy showed a few sessile polyps with a few diverticula but was overall unremarkable. Colonic biopsies were negative for CMV on histopathological examination. Given her persistent symptoms despite ganciclovir therapy, an upper endoscopy was performed, which demonstrated erosive gastropathy and mucosal changes with nodularity in the first and second parts of the duodenum. (Figure 1A, B)

On hospital day 7, ova and parasite stool study returned 3+ positive for acid fast bacteria (AFB). Around the same time, blood cultures also turned AFB-positive. Histopathologic results from the duodenal biopsy demonstrated abundant AFB organisms present within lamina propria macrophages and acid fast organisms consistent with mycobacteria seen on Kinyoun stain (auramine-rhodamine-positive, periodic acid-Schiff with diastase-positive) (Figure 1C and D).

Transplant infectious disease team was consulted and she was started on a multidrug regimen to cover both NTM and mycobacterium tuberculosis, adjusting for renal function, with ethambutol, azithromycin, rifabutin, amikacin, isoniazid, and moxifloxacin.

Unfortunately, despite appropriate treatment and supportive measures, our patient continued to deteriorate. She developed respiratory distress and acute hypoxic respiratory failure requiring transfer to the intensive care where she was intubated. Chest imaging demonstrated bilateral multifocal pneumonia with bilateral pleural effusions. Bronchoalveolar lavage and pleural fluid analysis returned AFB-positive, confirming a diagnosis of disseminated NTM. The organism was later identified as *Mycobacterium avium* complex (MAC).

Over the next few days, her kidney function continued to deteriorate and she ultimately lost renal graft function all together. Her tenuous hemodynamics did not permit intermittent hemodialysis and she needed to be on continuous renal replacement therapy. After spending 2 months in the hospital with repeated trips to intensive care, she succumbed to the disseminated infection.

Discussion

Nontuberculous mycobacterium is ubiquitous, and a diverse group of organisms having more than 140 species are described, but only about 25 cause diseases in humans.¹ The prevalence of NTM disease is rising.² Infections tend to involve the lungs in immunocompetent hosts. In immunosuppressed transplant recipients, they present with protean manifestations ranging from cutaneous lesions, nodules in organs, and tenosynovitis, to disseminated disease.³ As solid organ transplant (SOT) recipients live longer thanks to advances in surgical techniques and better postoperative care, they are exposed to more risk from these organisms from longer periods of immunosuppression. Of the SOT patient population, those with lung transplants seem to be at the most risk of NTM, especially pulmonary compared with heart, renal, and liver recipients.^{4,5} Interestingly, NTM infection is still uncommon in transplant recipients and prophylaxis is not routinely recommended.^{6,7} No specific risk factors have been identified for NTM infections in SOT patients and it is unknown whether multiple transplants increase the risk.⁵ Song et al⁸ did a systematic review of NTM infection in 115 renal transplant recipients. In their study, only 13 of the 115 patients had 2 renal transplants like our patient.

Although almost any organ can be involved in renal transplant patients, disseminated disease is most commonly seen and can take 1 of the 2 forms.⁹ The more common clinical presentation is disseminated skin lesions, caused by rapid growers. The other clinical presentation is that of fever of

unknown origin with generalized or abdominal lymphadenopathy and positive blood cultures, usually caused by MAC and *Mycobacterium simiae*. Our patient's presentation was atypical, presenting with relentless high-volume wasting diarrhea. In the setting of her decades-long immunosuppression, it made us consider parasites like *Cystoisospora belli*, cryptosporidia, and microsporidia once CMV was ruled out.^{10,11} The fecal AFB stain was performed with the intention of looking for cryptosporidia and cystoisospora oocyte. We were quite surprised when it showed up 3+ acid fast organisms. Same-day biopsies taken during upper endoscopy showing AFB-positive organisms, later determined to be MAC, confirmed the diagnosis.

Intestinal MAC is a rare infection in renal transplant patients.¹² Our literature search did not find any reports of MAC causing severe wasting diarrhea in renal transplant patients. We found 2 reports, one of NTM causing diarrhea from jejunal infection in an allogenic bone marrow transplant patient¹³ and one of atypical mycobacterium causing colitis in a renal transplant patient.¹⁴ A slow growing NTM, *Mycobacterium genavense*, has been described as having an affinity for the GI tract in immunocompromised patients, particularly HIV patients.¹⁵ The most common macroscopic finding in intestinal MAC in HIV patients is raised nodularity of stomach and duodenum. In retrospect, our patient had duodenal nodularity and it has been suggested that the presence of mucosal nodularity on endoscopy should prompt consideration of MAC in the right clinical setting.¹²

Culture remains the gold standard for diagnosis. Most cases are diagnosed by a combination of culture and histopathological examination. Collection of gastric aspirate for AFB where biopsy cultures are not available has been described with success.¹²

Treatment of MAC in patients with solid organ transplants is long and difficult. Most recommendations are taken from MAC treatment in HIV patients and from pulmonary MAC. The guidelines for treatment are mostly expert opinion, as there are not many randomized trials.¹⁶ A combination of antimicrobials and reduction of immunosuppression is usually tried.¹⁷ Given treatment options vary according to the species identified, speciation of NTM is the first step.⁹ The utility of in vitro resistance testing is controversial and dependent on species. It is generally useful only for rapid growing mycobacteria. In other cases, it can be misleading and recommended only for specific "drug-bug" combinations.¹⁸ Anti-TB meds have significant side effects on their own and interact with anti-rejection medications, complicating the issue further. The exact duration of treatment is unknown and varies from 12 months after culture conversion for pulmonary NTM to life or for the duration of the immunosuppressed state for disseminated MAC.

In conclusion, we present a rare case of disseminated NTM presenting as chronic diarrhea and wasting in a renal transplant patient.

Author Contributions

Manasi Singh—Drafting of the manuscript; Critical revision of the manuscript for important intellectual content.

Marc Heincelman—Drafting of the manuscript; Critical revision of the manuscript for important intellectual content, supervisory.

Declaration of Conflicting Interests

The author(s) declared no potential conflicts of interest with respect to the research, authorship, and/or publication of this article.

Ethical Approval

Our institution does not require ethical approval for reporting individual cases or case series.

Funding

The author(s) received no financial support for the research, authorship, and/or publication of this article.

Informed Consent

Verbal informed consent was obtained from the patient for their anonymized information to be published in this article.

ORCID iD

Manasi Singh  <https://orcid.org/0000-0001-6175-0858>

References

1. Tortoli E. Impact of genotypic studies on mycobacterial taxonomy: the new mycobacteria of the 1990s. *Clin Microbiol Rev.* 2003;16(2):319-354.
2. Lake MA, Ambrose LR, Lipman MC, et al. "Why me, why now?" Using clinical immunology and epidemiology to explain who gets nontuberculous mycobacterial infection. *BMC Med.* 2016;14:54.
3. Patel R, Roberts GD, Keating MR, Paya CV. Infections due to nontuberculous mycobacteria in kidney, heart, and liver transplant recipients. *Clin Infect Dis.* 1994;19(2):263-273.
4. George IA, Santos CA, Olsen MA, Bailey TC. Epidemiology and outcomes of nontuberculous mycobacterial infections in solid organ transplant recipients at a midwestern center. *Transplantation.* 2016;100(5):1073-1078.
5. Longworth SA, Vinnard C, Lee I, Sims KD, Barton TD, Blumberg EA. Risk factors for nontuberculous mycobacterial infections in solid organ transplant recipients: a case-control study. *Transpl Infect Dis.* 2014;16(1):76-83.
6. Doucette K, Fishman JA. Nontuberculous mycobacterial infection in hematopoietic stem cell and solid organ transplant recipients. *Clin Infect Dis.* 2004;38(10):1428-1439.
7. Rawla MS, Kozak A, Hadley S, LeCates WW. Mycobacterium avium-intracellulare-associated acute interstitial nephritis: a rare cause of renal allograft dysfunction. *Transpl Infect Dis.* 2009;11(6):529-533.
8. Song Y, Zhang L, Yang H, Liu G, Huang H, Wu J, et al. Nontuberculous mycobacterium infection in renal transplant recipients: a systematic review. *Infect Dis (Lond).* 2018;50(6):409-416.

9. van Ingen J. Diagnosis of nontuberculous mycobacterial infections. *Semin Respir Crit Care Med.* 2013;34(1):103-109.
10. Atambay M, Bayraktar MR, Kayabas U, et al. A rare diarrheic parasite in a liver transplant patient: *Isospora belli*. *Transplant Proc.* 2007;39(5):1693-1695.
11. Marques J, Menezes M, Mendes F, Dutra E, Saiote J, Santos S, et al. A rare diarrheic parasite in a kidney transplant patient: *cystoisospora belli*. *Transpl Infect Dis.* 2020;22(1):e13237.
12. Parr JB, Lachiewicz AM, van Duin D, Chong PP. Successful diagnosis of intestinal mycobacterium avium complex infection in a kidney transplant recipient using nasogastric aspirate culture: a case report. *Transplant Proc.* 2017;49(10):2362-2364.
13. Yamazaki R, Mori T, Nakazato T, Aisa Y, Imaeda H, Hisamatsu T, et al. Non-tuberculous mycobacterial infection localized in small intestine developing after allogeneic bone marrow transplantation. *Intern Med.* 2010;49(12):1191-1193.
14. Kochhar R, Indudhara R, Nagi B, Yadav RV, Mehta SK. Colonic tuberculosis due to atypical mycobacteria in a renal transplant recipient. *Am J Gastroenterol.* 1988;83(12):1435-1436.
15. Wetzstein N, Kessel J, Bingold TM, Carney J, Graf C, Koch BF, et al. High overall mortality of Mycobacterium genavense infections and impact of antimycobacterial therapy: systematic review and individual patient data meta-analysis. *J Infect.* 2022;84(1):8-16.
16. Griffith DE, Aksamit T, Brown-Elliott BA, et al. An official ATS/IDSA statement: diagnosis, treatment, and prevention of nontuberculous mycobacterial diseases. *Am J Respir Crit Care Med.* 2007;175(4):367-416.
17. Haas S, Scully B, Cohen D, Radhakrishnan J. Mycobacterium avium complex infection in kidney transplant patients. *Transpl Infect Dis.* 2005;7(2):75-79.
18. Keating MR, Daly JS, AST Infectious Diseases Community of Practice. Nontuberculous mycobacterial infections in solid organ transplantation. *Am J Transplant.* 2013;13(Suppl. 4):77-82.