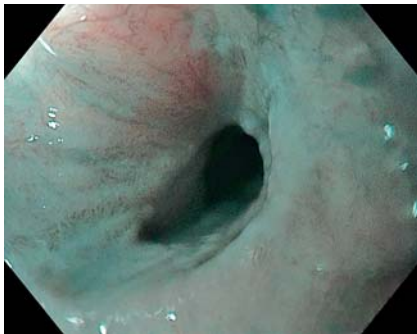
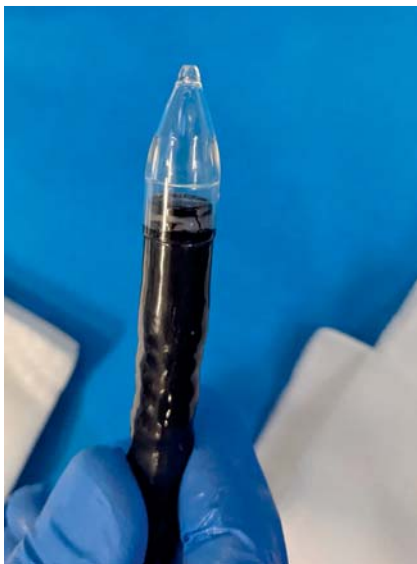
Use of a bougie-shaped cap for dilation with direct visual control for an esophageal stricture induced by radiation therapy

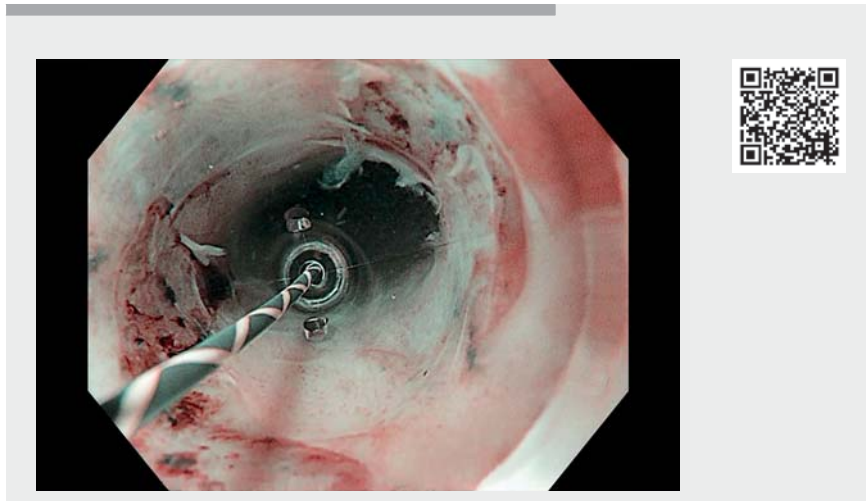


► **Fig. 1** Endoscopic view of the stricture in the lower third of the esophagus (narrow-band imaging).



► **Fig. 2** The 12 mm BougieCap device (Ovesco, Tübingen, Germany) attached to a GIF-HQ190 gastroscopie tip (outer diameter 9.9 mm; Olympus, Tokyo, Japan).

Bougies and balloons are two instruments commonly used for endoscopic dilation of benign strictures in the upper gastrointestinal tract, with similar efficacy [1]. However, these invasive strategies do not allow visual control of the operation during dilation of the stricture, and bleeding caused by the treat-



► **Video 1** Use of a bougie-shaped cap for dilation with direct visual control for an esophageal stricture induced by radiation therapy.

ment itself prevents proper examination of the esophageal mucosa after the procedure. The BougieCap (Ovesco, Tübingen, Germany) is a recently developed dilation device that allows successful and safe endoscopic treatment of benign strictures [2].

We herein report the case of a 64-year-old patient admitted for treatment of an esophageal stricture induced by radiation therapy following treatment for squamous cell carcinoma, with the need for repeated dilations. After visualization of the stricture in the lower third of the esophagus, which could not be crossed by the gastroscopie, a 12 mm BougieCap was attached to the GIF-HQ190 gastroscopie tip (outer diameter 9.9 mm; Olympus, Tokyo, Japan) and positioned proximally to the stricture (► **Fig. 1**, ► **Fig. 2**). A guidewire was pushed through the cap beyond the stricture. The stricture was then carefully passed with the transparent cap by advancing the scope, allowing visualization of the tension on the tissue and avoiding overstretching. A careful ex-

amination of the esophageal mucosa using chromoendoscopy (narrow-band imaging, Lugol) did not reveal any squamous lesions. No immediate or delayed severe adverse events were reported (► **Video 1**).


The BougieCap dilation device allows direct visual control during the procedure. Mucosal examination is further improved by the compression of the vessels by the device, resulting in less mucosal bleeding. Furthermore, from an ecological perspective, the use of this technique significantly reduces plastic waste by over 99% (3 g of plastic waste vs. 480 g for single-use balloon dilation) [3].

Endoscopy_UCTN_Code_TTT_1AO_2AH

Competing interests

The authors declare that they have no conflict of interest.

The authors

Pierre Lafeuille , **Clara Yzet**, **Paul Bonniaud**,
Florian Rostain, **Thierry Ponchon**, **Jérôme**
Rivory, **Mathieu Pioche**

Department of Endoscopy and
Hepatogastroenterology, Pavillon L, Edouard
Herriot Hospital, Lyon, France

Corresponding author

Pierre Lafeuille, MD

Endoscopy Unit – Digestive Disease
Department, Pavillon L – Edouard Herriot
Hospital, 5 place d'Arsonval, 69437 Lyon
Cedex, France
pierre.lafeuille@chu-lyon.fr

References

- [1] Josino IR, Madruga-Neto AC, Ribeiro IB et al. Endoscopic dilation with bougies versus balloon dilation in esophageal benign strictures: systematic review and meta-analysis. *Gastroenterol Res Pract* 2018; 2018: 5874870
- [2] Schoepfer AM, Henchoz S, Biedermann L et al. Technical feasibility, clinical effectiveness, and safety of esophageal stricture dilation using a novel endoscopic attachment cap in adults with eosinophilic esophagitis. *Gastrointest Endosc* 2021; 94: 912–919
- [3] Yzet C, Figueiredo M, Michoud C et al. Ecological impact of endoscopic dilatation using the bougie cap device: a low-tech innovation to reduce waste by 99. *Endoscopy* 2022. doi:10.1055/a-1838-3860

Bibliography

Endoscopy 2023; 55: E18–E19
DOI 10.1055/a-1929-9317
ISSN 0013-726X
published online 16.9.2022
© 2022. The Author(s).

This is an open access article published by Thieme under the terms of the Creative Commons Attribution-NonDerivative-NonCommercial License, permitting copying and reproduction so long as the original work is given appropriate credit. Contents may not be used for commercial purposes, or adapted, remixed, transformed or built upon. (<https://creativecommons.org/licenses/by-nc-nd/4.0/>)

Georg Thieme Verlag KG, Rüdigerstraße 14,
70469 Stuttgart, Germany



ENDOSCOPY E-VIDEOS

<https://eref.thieme.de/e-videos>



Endoscopy E-Videos is an open access online section, reporting on interesting cases and new techniques in gastroenterological endoscopy. All papers include a high quality video and all contributions are freely accessible online. Processing charges apply (currently EUR 375), discounts and waivers acc. to HINARI are available.

This section has its own submission website at
<https://mc.manuscriptcentral.com/e-videos>