

[Orthopaedic Surgery]

Intramuscular Hemangiomas

Joseph M. Wierzbicki, MD,*[†] Jeffrey H. Henderson, MD,[†] Mark T. Scarborough, MD,[‡] Charles H. Bush, MD,[§] John D. Reith, MD,^{||} and James R. Clugston, MD[†]

Context: Intramuscular hemangiomas are common in the general population and often present at medical and surgical clinics. Unfortunately, unfamiliarity with these lesions has led to a high percentage of misdiagnoses, inappropriate workup, and unnecessary referrals.

Evidence Acquisition: A literature search was performed using Medline, Embase, PubMed, and Cochrane. The relevant articles and referenced sources were reviewed for additional articles that discussed the epidemiology, pathophysiology, investigation, and management of intramuscular hemangiomas. Clinical experience from experts in orthopaedics, musculoskeletal pathology, and musculoskeletal radiology was compared. The selected case studies are shared cases of the authors.

Results and Conclusion: The pathophysiology of these lesions is not completely understood, but much can be implied from their underlying vascular nature. Isolated lesions are benign tumors that never metastasize but tend to enlarge and then involute over time. Magnetic resonance imaging is the imaging modality of choice. If a systemic disorder or malignancy is not suspected or has been ruled out, conservative management is the treatment of choice for most intramuscular hemangiomas.

Keywords: hemangioma; intramuscular hemangioma; vascular malformation; muscle lesions

Hemangiomas are abnormal proliferations of blood vessels, making up 7% of all benign soft tissue tumors. Their true incidence and prevalence are difficult to calculate, as the majority of lesions are small and asymptomatic.^{9,13,22} These lesions are largely congenital, but approximately 20% can be linked to trauma.^{2,9,22} The established course is growth, fibroadipose replacement, intravascular clotting, atrophy, and involution, supported by 90% occurring before the age of 30 years, as well as low incidence in older adults.^{1,2,9,13,19} They occur most commonly in subcutaneous adipose tissue but may also be found in muscle.^{9,28} Intramuscular hemangiomas account for approximately 0.8% of all benign soft tissue tumors.^{7,24} The malformations are most frequently located in the thigh (36%), followed by the calf (17%).²²

CLINICAL EXAMINATION

Intramuscular hemangiomas are rarely considered in the differential diagnosis for musculoskeletal pain. With an average duration of symptoms at initial presentation being 13 months, chronic extremity pain should increase suspicion for an

intramuscular hemangioma.²⁵ Chronic pain and a new mass are the most common presenting symptoms.^{10,14,25} Pain is present in 60% of cases and is most frequent in muscles that are long and narrow.^{1,9,25} Pain is often exacerbated with exercise of the involved muscle due to the vascular dilation and increased regional blood flow, leading to swelling and compressive pain. Clinical findings that support the diagnosis of hemangioma include isolated pulsations, extremity enlargement when dependent (and regression when elevated), compressibility, increased temperature, muscle contracture, tenderness to palpation, and muscle weakness.¹³ Larger and/or superficial hemangiomas may be associated with lower extremity deformities, skin discoloration, bruit, or pulsation. Rarely, they may shunt blood flow and cause heart murmurs and congestive heart failure.^{9,13}

INVESTIGATION

X-ray followed by magnetic resonance imaging (MRI) is the typical imaging sequence for exploration of extremity complaints and will most often make the diagnosis. MRI is the diagnostic procedure of choice, as it reliably differentiates

From the [†]Primary Care Sports Medicine Fellowship, Department of Community Health and Family Medicine, University of Florida, Gainesville, Florida, the [‡]Department of Orthopaedic Oncology, Orthopaedic and Sports Medicine Institute, University of Florida, Gainesville, Florida, the [§]Department of Radiology, University of Florida, Gainesville, Florida, and the ^{||}Department of Pathology, Immunology, and Laboratory Medicine and the Department of Orthopaedics and Rehabilitation, University of Florida, Gainesville, Florida

*Address correspondence to Joseph M. Wierzbicki, MD, Primary Care Sports Medicine Fellowship, University of South Florida and Morton Plant Mease, 807 North Myrtle Avenue, Clearwater, FL 33755 (e-mail: wierzbicki@ufl.edu)

The authors report no potential conflicts of interest in the development and publication of this manuscript.

DOI: 10.1177/1941738112470910

© 2012 The Author(s)

Table 1. Imaging modalities utilized in the workup of intramuscular hemangiomas.

Study	Possible Findings
X-ray	Without abnormalities ^{1,11,22}
	Abnormal soft tissue shadows and/or mass lesion ^{11,13}
	Calcified phleboliths (Figure 1; 25% of cases) ^{13,25}
	Benign-appearing periosteal reaction, bone erosion, chronic cortical thickening, and remodeling (Figure 3a) ^{11,13}
Ultrasound	Hyperechogenic region (most common finding) ^{8,11}
	Acoustic shadowing of calcified phlebolith ¹¹
	Abnormal resistance in color flow arterial Doppler pattern ¹¹
Magnetic resonance imaging ^a	
T1-weighted images	High signal intensity reflecting fat content of lesion (Figures 2a and 2b) ^{5,11}
	Indistinct lesion borders and areas of signal void indicate muscle atrophy ^{5,11,21}
	Low signal intensity represents fibrous tissue, thrombi, or phleboliths ⁵
	Signal voids can show phase encoding artifact and allow recognition of high flow vascular lesions (Figure 4) ^{13,21}
T2-weighted images	High signal intensity relative to muscle (Figure 2b) ^{5,11}
	Multilobulated, “bag of worms,” or tubular appearance (Figure 2a)
	Central area of low intensity is highly specific, “dot sign” ^{21,23}
	Phleboliths not commonly seen ⁵
Angiography and computed tomography angiography ^b	Pooling in dilated vascular spaces ^{11,21}
	Lesions may be high or low flow (high-flow lesions have greater success with embolization) ^{13,18}
Computed tomography	Superior definition of associated bone involvement or osseous hemangiomas ^{5,11}
	Exclude other soft tissue masses (lipomas are well demarcated and show low density attenuation; hemangiomas are poorly defined with tissue attenuation similar to skeletal muscle with areas of fat attenuation) ^{5,11}
	Greater sensitivity for bony erosions and phleboliths (up to 50% of cases) ^{5,11}

^aDiagnostic procedure of choice.

^bRarely used.

hemangiomas from malignant tumors without the need for a biopsy (Table 1).^{5,11,23} Rounded soft tissue calcifications in some hemangiomas may be seen on X-ray, termed phleboliths or “venous stones” (Figure 1). Musculoskeletal ultrasound may confirm a mass and is effective in the workup of intramuscular hemangiomas. Ultrasound does not reliably identify pathognomonic features of hemangiomas, but it can

identify abnormal Doppler flow patterns or features consistent with phleboliths.¹¹ With the increased use of in-office ultrasound, this modality may play a larger role in diagnostic investigations in the future. Computed tomography has been helpful in excluding other types of masses but is not always reliable in defining hemangiomas.⁵ Occasionally, angiography is necessary to demonstrate the fine vascular details of a hemangioma. This may

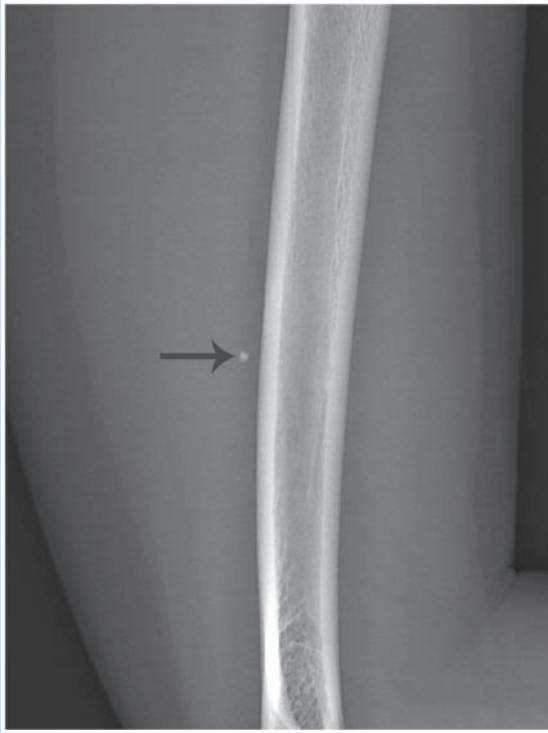


Figure 1. Lateral radiograph demonstrates a phlebolith (arrow) in a 31-year-old woman with an intramuscular hemangioma of the lateral triceps.

be helpful when embolization or surgical resection of complex lesions is contemplated.^{5,11,13,15} The majority of imaging studies identify features suggestive of an intramuscular hemangioma (and, thus, a benign tumor); as such, biopsy is rarely needed to rule out a malignant process.⁵ However, if uncertainty remains regarding the diagnosis following clinical examination and imaging, open or needle biopsy is recommended.¹⁴

TREATMENT

Multiple treatments are available for symptomatic intramuscular hemangiomas.^{13,20,24} Options include conservative management, systemic corticosteroids, embolization, radiation, sclerotherapy, and surgical excision.^{13,20,24} Each case requires thorough consideration of the unique characteristics of this lesion and the patient's degree of functional impairment. Although true intramuscular hemangiomas have no malignant potential, all management strategies should include regular follow-up.^{9,10}

Conservative management is the first line of treatment for nearly all isolated intramuscular hemangiomas.^{3,12-14} Monitoring alone with regular follow-up is appropriate for minimally bothersome lesions. Of these minimally bothersome intramuscular hemangiomas, approximately 75% and 60% had not elected to undergo surgery when followed up at 2 and 10 years, respectively.³ When the degree of pain or

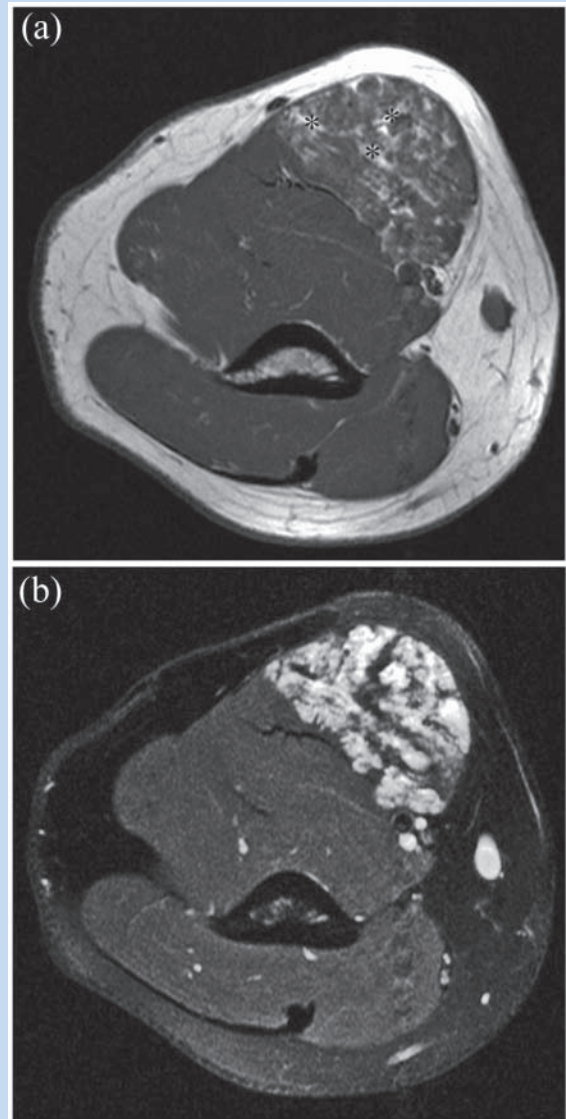


Figure 2. Forty-five-year-old man with a hemangioma of the right biceps brachii. (a) A T1-weighted axial magnetic resonance image through the hemangioma is very slightly hyperintense to muscle and shows multiple interlacing vascular channels of the lesion, giving a “bag of worms” appearance. High-signal intralesional fat is abundant in many hemangiomas (asterisks). (b) A STIR axial image through the hemangioma at the same level shows the vascular component of the lesion to be markedly hyperintense to muscle.

functional impairment warrants more intervention than just monitoring, nonoperative measures may decrease symptoms as the malformation involutes, including activity modification, compression garments, elevation of the extremity, nonsteroidal anti-inflammatory drugs, and physical therapy. The greatest relief is found by avoiding excessive use of the muscles that house the malformation, thus altering the vasodilation-

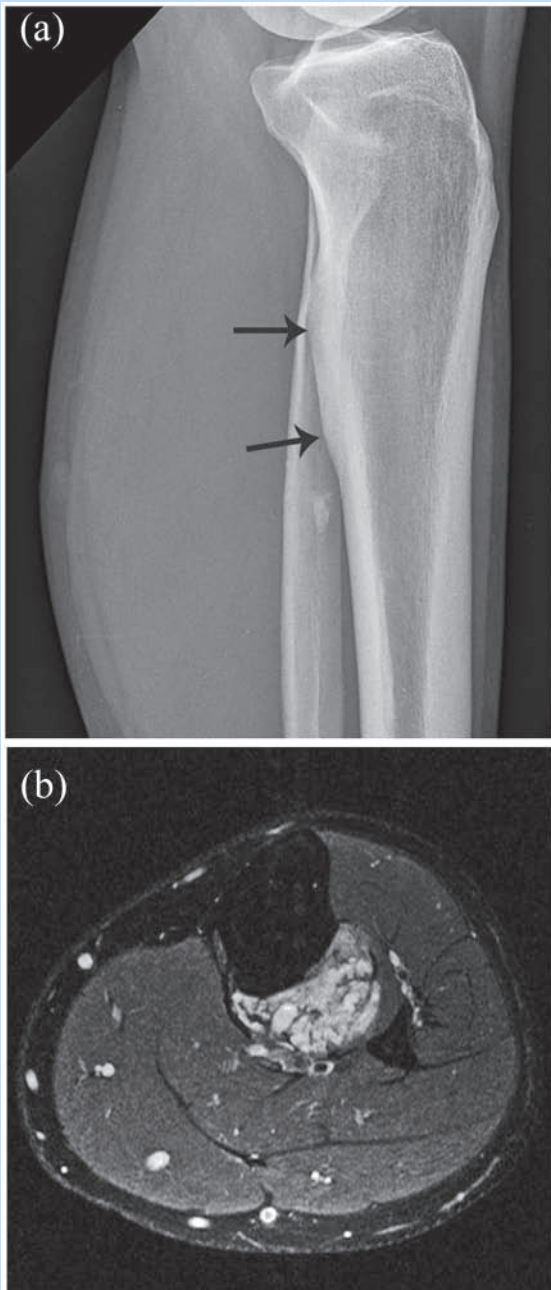


Figure 3. The 31-year-old man with a left proximal calf mass described in Case 1.¹² (a) The lateral radiograph shows bony hyperostosis of the posterior cortex of the left proximal tibia (arrows) and an incidental enchondroma in the fibular shaft. (b) Axial T1 image shows a juxtacortical hemangioma of the left proximal calf.

dependent edema and pain.^{13,14} In most cases, prolonged nonoperative management leads to gradual symptom resolution.^{14,22} With complicated hemangiomas, systemic hemangiomatous disease, or unsuccessful conservative treatment, referral should be made to an oncology service.

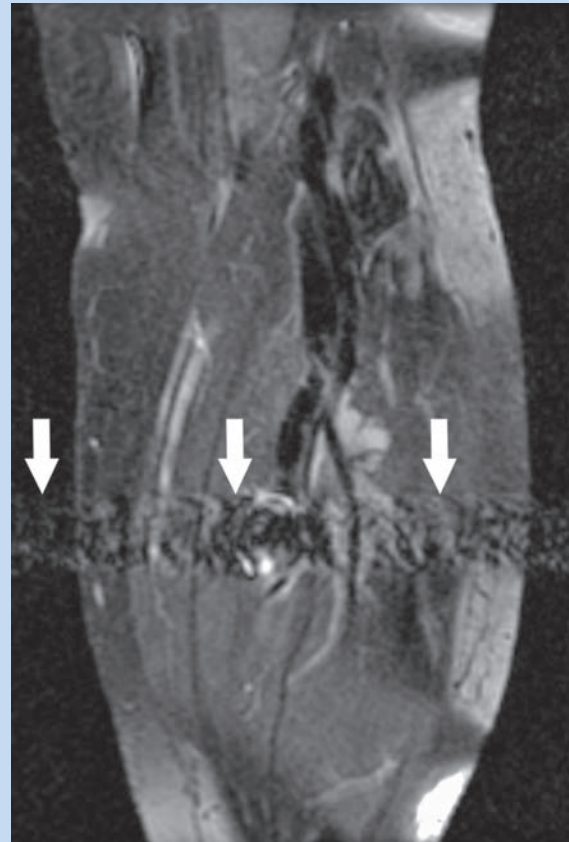


Figure 4. MRI of the calf demonstrating a region of high flow as signal voids with phase encoding artifact (arrows).

Because of the self-limited nature of most intramuscular hemangiomas and variable outcomes with invasive therapies, surgical intervention is not needed unless indications are compelling. Rapid tumor growth, intractable pain, risk of local skin necrosis, thrombocytopenia, cosmetic or functional impairment, or suspicion of malignancy may necessitate surgical intervention.^{3,17,22} Characteristics that make lesions better surgical candidates are highly localized, well-circumscribed single-muscle, and minimal loculations.^{2,3,22} Because hemangiomas have a complex and infiltrative nature, normal tissue must be removed well beyond the gross edges of the lesion to prevent recurrence.^{2,3,6} Incomplete surgical excision is the greatest risk factor for recurrence, and adequate excision can result in debilitating complications.^{3,7} The risk of tumor recurrence after excision is variable, ranging from 18% to 61%, although hemorrhage remains the most common complication.^{3,22}

Additional treatments for vascular malformations are available but rarely used secondary to side effects and less successful long-term outcomes. Surgical excision is sometimes impractical; not all patients are agreeable to surgery, and complex high-risk infiltrating lesions exist. In

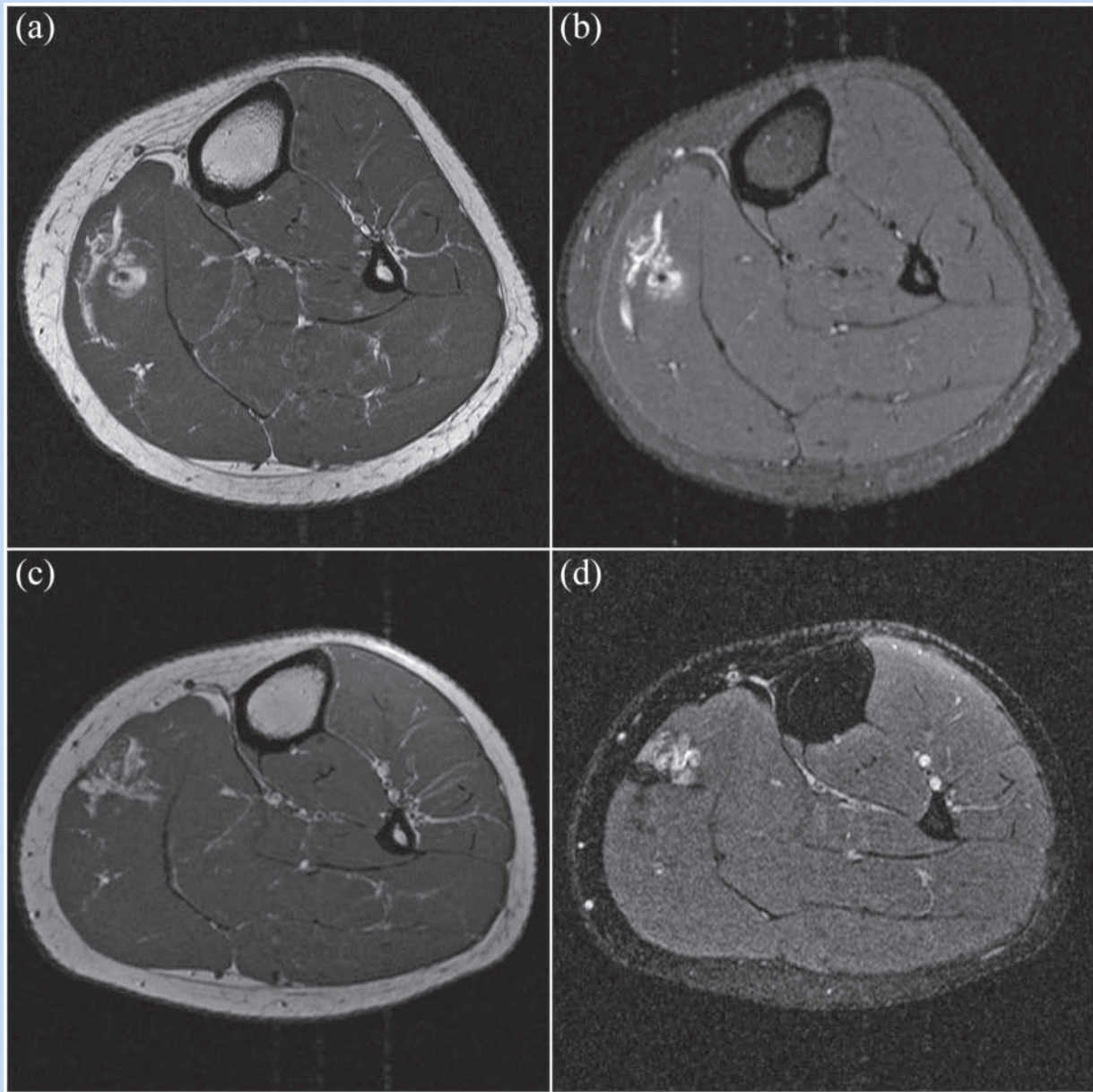


Figure 5. The 17-year-old girl in Case 2. (a) Axial T1 postcontrast image showing increased signal throughout, with a small, round low-signal-intensity focus within the lesion. (b) Axial STIR image at the same level. (c) Axial T1 postcontrast image showing recurrence of the intramuscular hemangioma within the medial head of the gastrocnemius. (d) An axial STIR image at the same level again showing recurrence of the intramuscular hemangioma.

these cases, sclerotherapy, corticosteroids, radiation therapy, or embolization may be beneficial.^{10,18,25} Embolization can control pain in unresectable lesions and in combination with surgical excision to decrease blood loss and postoperative recurrence.^{7,13,18} There have been favorable outcomes with multiple intralesional sclerotherapies, and these may be considered in select cases.^{4,6,17,22,24} Indications for radiation therapy and systemic corticosteroids are few, as they are utilized primarily in the setting of systemic disease.¹⁶

CASE 1

A 22-year-old active man presented with persistent proximal “pressure-like” pain in the posterior calf while cycling and running.¹² The pain worsened with vigorous dorsiflexion and plantar flexion. There was minimal tenderness over the left posterior lateral aspect of the proximal calf, but no swelling or mass was appreciated. Lateral gastrocnemius strain and chronic exertional compartment syndrome were considered. He

improved with 4 weeks of physical therapy and did not follow up at that time. Nine years later at age 31 years, he complained of similar left lower extremity pain during prolonged exercise. X-rays showed a possible enchondroma in the fibular shaft near the painful area (Figure 3a). MRI revealed a multiloculated soft tissue mass (3.5 × 2.2 × 8.8 cm) of increased T2 signal within the tibialis posterior muscle, abutting the posterior tibial artery and tibial nerve (Figure 3b). There was uniform contrast enhancement of the mass with small areas of calcification and chronic cortical thickening of the adjacent tibia and fibula and mildly increased T1 signal similar to fatty tissue, consistent with an intramuscular hemangioma. He was treated conservatively with activity modification, home exercise program, and occasional ibuprofen. Follow-up MRI showed no changes.

CASE 2

A 17-year-old high school girl with 3 months of intermittent left calf pain and swelling during activity had near complete resolution of both with rest and elevation. Physical examination was unremarkable except for a proximal mass over her medial calf in a dependent position. X-ray revealed no abnormalities. MRI showed an ill-defined enhancing lesion (3.6 × 3.1 × 1.8 cm) within the left medial gastrocnemius with increased T1-weighted signal throughout and a small, round low-

signal-intensity focus within the lesion, consistent with an intramuscular hemangioma (Figures 5a and 5b). A needle biopsy was nondiagnostic. After 3 months of conservative management failed, she elected a surgical excision. In combination with physical therapy, she was able to return to full activity. Four years later (age 21 years), her symptoms returned with the same severity, location, and mass effect. Repeat MRI (Figures 5c and 5d) showed recurrence of the intramuscular hemangioma within the medial head of the gastrocnemius at the site of the previous hemangioma (3.3 × 1.3 × 1.5 cm). She again elected surgical removal because of the severity of the symptoms and impact on her activity. At 6 months postoperative, she was asymptomatic and tolerating full activity.

DISCUSSION

When chronic extremity pain fails to respond to conservative management, intramuscular soft tissue tumors should be included in the differential diagnosis. The diagnosis is usually made by history, clinical examination, and a combination of imaging studies. With the rise of in-office ultrasound, expect a higher incidence of vascular malformations. Conservative management remains the most successful treatment, as the majority of these lesions involute with time, and advanced therapies may be considered on a case-by-case basis.



Clinical Recommendations

SORT: Strength of Recommendation Taxonomy

A: consistent, good-quality patient-oriented evidence

B: inconsistent or limited-quality patient-oriented evidence

C: consensus, disease-oriented evidence, usual practice, expert opinion, or case series

Clinical Recommendation	Evidence Rating	References	Comments
When an intramuscular hemangioma is suspected, workup begins with X-ray or ultrasound, followed by magnetic resonance imaging (MRI).	C	4, 5, 8, 11-13	Expert opinion
MRI is the diagnostic procedure of choice for intramuscular hemangiomas.	B	5, 11-13	Expert opinion, retrospective cohort studies
MRI findings consistent with an intramuscular hemangioma do not require additional workup. If the diagnosis is not clear after MRI, biopsy or surgical removal should be performed.	B	5, 10-13, 21, 23	Expert opinion, case series, retrospective cohort studies
Noninvasive management is first-line management for intramuscular hemangiomas, as it yields equally successful results that are without complications.	B	3, 12-14, 17, 22	Expert opinion, case series, retrospective cohort studies
Invasive management of uncomplicated intramuscular hemangiomas should be reserved for cases that have failed nonoperative management.	B	3, 12-14, 17, 22	Expert opinion, case series, retrospective cohort studies

REFERENCES

1. Allen PW, Enzinger FM. Hemangioma of skeletal muscle: an analysis of 89 cases. *Cancer*. 1972;29:8-22.
2. Beham A, Fletcher CD. Intramuscular angioma: a clinicopathological analysis of 74 cases. *Histopathology*. 1991;18(1):53-59.
3. Bella G, Manivel J, Thompson R, Clohisy D, Cheng E. Intramuscular hemangioma: recurrence risk related to surgical margins. *Clin Orthop Relat Res*. 2007;459:186-191.
4. Brown RA, Crichton K, Malouf GM. Intramuscular haemangioma of the thigh in a basketball player. *Br J Sports Med*. 2004;38:346-348.
5. Buetow PC, Kransdorf MJ, Moser RP Jr, Jelinek JS, Berrey BH. Radiologic appearance of intramuscular hemangioma with emphasis on MR imaging. *AJR*. 1990;154:563-567.
6. Chaudhary N, Jain A, Gudwani S, Kapoor R, Motwani G. Intramuscular haemangioma of head and neck region. *J Laryngol Otol*. 1998;112:1199-1201.
7. Cohen AJ, Youkey JR, Clagett GP, Huggins M, Nadalo L, d'Avis JC. Intramuscular hemangioma. *JAMA*. 1983;249(19):2680-2682.
8. Derchi LE, Balconi G, Flaviis LD, Oliva A, Rosso F. Sonographic appearance of hemangiomas of skeletal muscle. *J Ultra Med*. 1989;8:263-267.
9. Enzinger FM, Weiss SW. Benign tumors and tumorlike lesions of blood vessels. In: *Soft Tissue Tumors*. 2nd ed. St Louis, MO: Mosby; 1988:512.
10. Fergusson ILC. Haemangiomas of skeletal muscle. *Br J Surg*. 1972;59:634-637.
11. Greenspan A, McGahan JP, Vogelsang P, Szabo RM. Imaging strategies in the evaluation of soft-tissue hemangiomas of the extremities: correlation of the findings of plain radiography, angiography, CT, MRI, and ultrasonography in 12 histologically proven cases. *Skel Radiol*. 1992;21:11-18.
12. Henderson J, Wierzbicki J, Clugston J, Patel N. Ten years of lower leg pain: intramuscular hemangioma. *Med Sci Sports Exerc*. 2010;42:5.
13. Katz D, Damron T. Orthopedic surgery for hemangioma. <http://emedicine.medscape.com/article/1255694-overview>. Updated September 18, 2012.
14. Kryzak TJ Jr, DeGroot H 3rd. Adult onset flatfoot associated with an intramuscular hemangioma of the posterior tibialis muscle. *Orthopedics*. 2008;31(3):280.
15. McNeill TW, Chan GE, Chapek V, Ray RD. The value of angiography in the surgical management of deep hemangiomas. *Clin Orthop Relat Res*. 1974;101:176-181.
16. Mencke HJ, Zilkens J, Bigalke KH, Ammon J. The problem of intramuscular haemangioma. *Arch Orthop Trauma Surg*. 1982;100:243-247.
17. Mitsionis G, Pakos E, Kosta P, Batistatou A, Beris A. Intramuscular hemangioma of the foot: a case report and review of the literature. *Foot Ankle Surg*. 2010;16:e27-e29.
18. Mitty HA, Kleiger B. Partial embolization of large peripheral hemangioma for pain controls. *Radiology*. 1978;127:671-672.
19. Mulliken JB, Glowacki J. Hemangiomas and vascular malformations in infants and children: a classification based on endothelial characteristics. *Plas Reconstr Surg*. 1982;69(3):412-422.
20. Scott JE. Haemangiomas in skeletal muscle. *Br J Surg*. 1957;44:496-501.
21. Suh JS, Hwang G, Hahn SB. Soft tissue hemangiomas: MR manifestations in 23 patients. *Skel Radiol*. 1994;23:621-625.
22. Tang P, Hornicek FJ, Gebhardt MC, Cates J, Mankin HJ. Surgical treatment of hemangiomas of soft tissue. *Clin Orthop Relat Res*. 2002;399:205-210.
23. Teo EL, Strouse PJ, Hernandez RJ. MR imaging differentiation of soft-tissue hemangiomas from malignant soft-tissue masses. *AJR*. 2000;174: 1623-1628.
24. Watson WL, McCarthy WD. Blood and lymph vessel tumors. *Surg Gynecol Obstet*. 1940;71:569.
25. Wild AT, Raab P, Krauspe R. Hemangioma of skeletal muscle. *Arch Orthop Trauma Surg*. 2000;120(3-4):139-143.

For reprints and permission queries, please visit SAGE's Web site at <http://www.sagepub.com/journalsPermissions.nav>.