

## CASE REPORT

# A case report of spontaneous rupture of the quadriceps tendon

Xiuming Gao, Zhen Shao, Suwei Liu & Jie Xiang

Department of Rehabilitation, The Affiliated Hospital of Xuzhou Medical College, Xuzhou, Jiangsu 221002, China

### Correspondence

Jie Xiang, Department of Rehabilitation, The Affiliated Hospital of Xuzhou Medical College, Xuzhou, Jiangsu 221002, China. Tel: 86-0516-85726027; Fax: 86-0516-85726027; E-mail: xj1111@163.com

### Key Clinical Message

Spontaneous quadriceps tendon rupture is a rare occurrence in patients with primary hyperparathyroidism (PHPT), which is less common in adolescents. We first reported a spontaneous unilateral rupture in a young patient with PHPT.

### Funding Information

No sources of funding were declared for this study.

### Keywords

Primary hyperparathyroidism, quadriceps tendon rupture, spontaneous.

Received: 25 May 2016; Revised: 9

November 2016; Accepted: 13 November 2016

*Clinical Case Reports* 2017; 5(9): 1477–1481

doi: 10.1002/ccr3.786

## Introduction

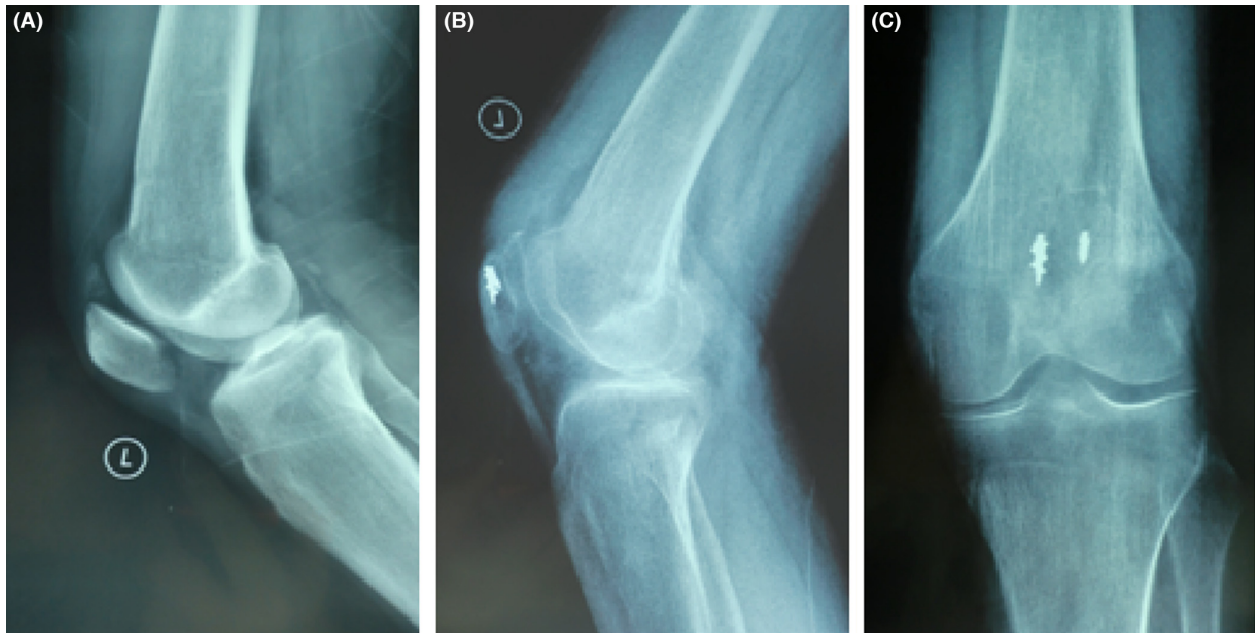
Spontaneous quadriceps tendon rupture (QTR) is a very rare injury. Since the first description by Steiner and Plamer [1], only a little over 100 cases have been documented. QTR mostly occurs in patients with chronic diseases, including chronic renal failure, gout, systemic lupus erythematosus, and long-term corticosteroid use [2–4]. Primary hyperparathyroidism (PHPT) is a common endocrine disorder in adults, which typically manifests as asymptomatic hypercalcemia. This effect describes local and systemic complications, such as kidney stones, abdominal pain, and skeletal fragility. However, adverse effects resulting in quadriceps tendon rupture following PHPT, which is rare in adolescents, have not yet been found. We first reported a spontaneous unilateral rupture in a young patient with PHPT and then introduced the pathogenesis of quadriceps tendon rupture, its treatment course, and outcome.

## Case Report

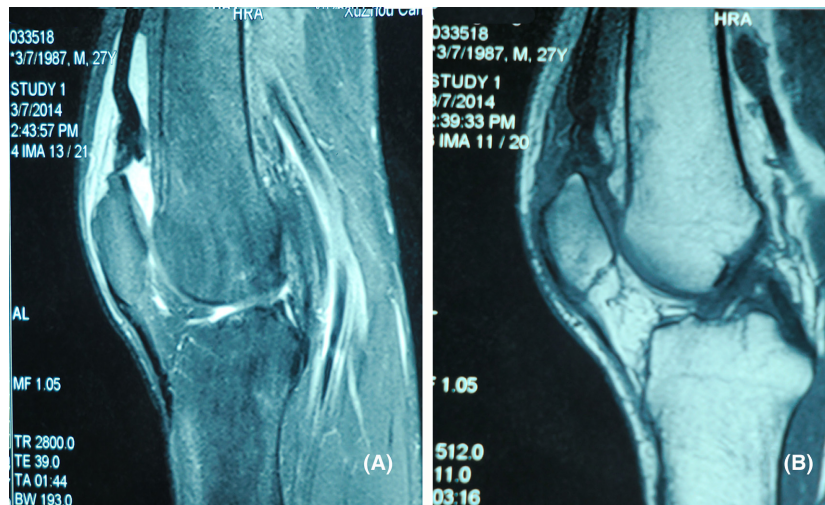
A 27-year-old man was admitted to a hospital emergency department because of the detection of low cracks upon

descending stairs 2 months ago. Immediately after the trauma, he was unable to bear weight and collapsed because of the giving way of the left knee. Plain radiography showed low riding, downward shift of left patella, and signs of left suprapatellar swelling, thereby indicating pretraumatic degeneration (Fig. 1A). MRI revealed complete disruption of the quadriceps tendon at patellar insertion sites (Fig. 2). A diagnosis of quadriceps tendon rupture was made, and surgical intervention was recommended. The patient was operated 1 day after injury. Two anchors were implanted into the patella after drilling, and two pairs of heavy and nonabsorbable sutures were placed through the quadriceps tendon via the same technique used for Bunnell suture. Postoperative radiography showed regular positioning of the patella (Fig. 1B and C).

He was transferred to the Rehabilitation Department of our hospital after a two-month immobilization period with knee extension and continuous passive active movement to exercise the extensor mechanism and improve flexion range. During this time, the patient experienced mild muscle weakness and early fatigability in training. The patient also presented with neuropsychiatric symptoms, such as depression, confusion, and sleep disorder.



**Figure 1.** Lateral X-ray examination of a 27-year-old man. Downward displacement of the left patella and calcification in the quadriceps tendon are shown in A. B and C shows postoperative radiography, revealing regular positioning of the patella.



**Figure 2.** Lateral T1- and T2-weighted magnetic resonance images of the left knee. A and B shows a complete disruption of the quadriceps tendon at the patellar insertion sites.

Moreover, the patient suffered from polydipsia, polyuria, and back pain. Further examination brought unexpected results.

Laboratory test data were as follows: serum calcium, 3.47 mmol/L; serum phosphorus, 0.65 mmol/L; parathyroid hormone (iPTH), 2011 pg/mL; serum alkaline phosphatase (ALP), 2943 IU/L; bone mineral density (BMD) indicated severe osteoporosis (Table 1). SPECT-PET (Tc-99 m-MIBI 15 mCi) imaging scan demonstrated

increased radioactive pharmaceutical uptake in the left lower neck, which suggested a pathological parathyroid gland (Fig. 3). Renal ultrasound showed nephrolithiasis, and small stones were noted in bilateral renal sinuses. Fibrous gastroscopy revealed chronic superficial gastritis. A new diagnosis was made: (i) primary hyperparathyroidism, with possible parathyroid adenoma; (ii) unilateral spontaneous quadriceps tendon rupture; and (iii) secondary osteoporosis. Primary hyperparathyroidism is a

common condition; standard treatment is surgical excision. The patient was operated on 1 week after preoperative preparation. A single tumor in the left lower neck suggested a pathological parathyroid gland, which was confirmed via hematoxylin–eosin staining (Fig. 4) and immunohistochemistry findings of a 2.5-cm pathological parathyroid adenoma. Postoperative treatment was predominantly medical, with calcium carbonate and vitamin D analogs. Most laboratory indexes declined and BMD improved. However, clinical manifestations did not completely disappear 6 months after the operation. Permanent hypocalcemia, which was defined as a serum calcium value of <2.25 mmol/L (normal range is 2.25–2.75 mmol/L), persisted beyond the first 3 months after surgery and required substitution with calcium and an active form of vitamin D. Postoperative periodic review of indicators revealed that many of the indicators were still unusual, especially PTH. Biochemical markers of bone formation, such as TP1NP, and markers of bone resorption and CROSSL remained high, as shown in Table 1. PTH will also be high if insufficient disease-causing tissues are removed; this situation may soon be excluded as the second SPECT-PET (Tc-99 m-MIBI 20 mCi) scan can be accurately performed. A new diagnosis of secondary hyperparathyroidism was made. We shall continue observing the patient closely through routine biochemical screenings.

We were pleased that the patient began to actively extend his knee and received flexion exercise after surgical excision. In 2 months, knee functions gradually returned to normal and no pain was reported. The patient regained full active mobility of the left knee 4 months after surgery and then returned to work 6 months after surgery.

## Discussion

Quadriceps tendon rupture is an uncommon injury, but spontaneous unilateral rupture is rarer. Weakening of the quadriceps tendon may predispose the patient to rupture,

as can uremia, rheumatoid arthritis, diabetes mellitus, nephritis, gout, autoimmune inflammatory diseases, tumors, and prolonged use of systemic steroid therapy [5–8]. However, no patient with PHPT has yet been found currently, which is much less common in adolescents. We reported the case of a 27-year-old healthy man who sustained QTR after a minor trauma, as well as the subsequent depression treatment course and outcome.

Primary hyperparathyroidism is common in patients aged 50–60 years, but uncommon in infants and children, with an incidence estimated at only two to five in 100,000. Remarkably, PHPT is clinically symptomatic in most young patients, who typically present with signs and symptoms of hypercalcemia, skeletal complications, and nephrolithiasis [9]. The younger the patients are, the more serious the myopathy and skeletal complications appear. Biochemically, these patients manifest with hypercalcemia and elevated concentrations of iPTH.

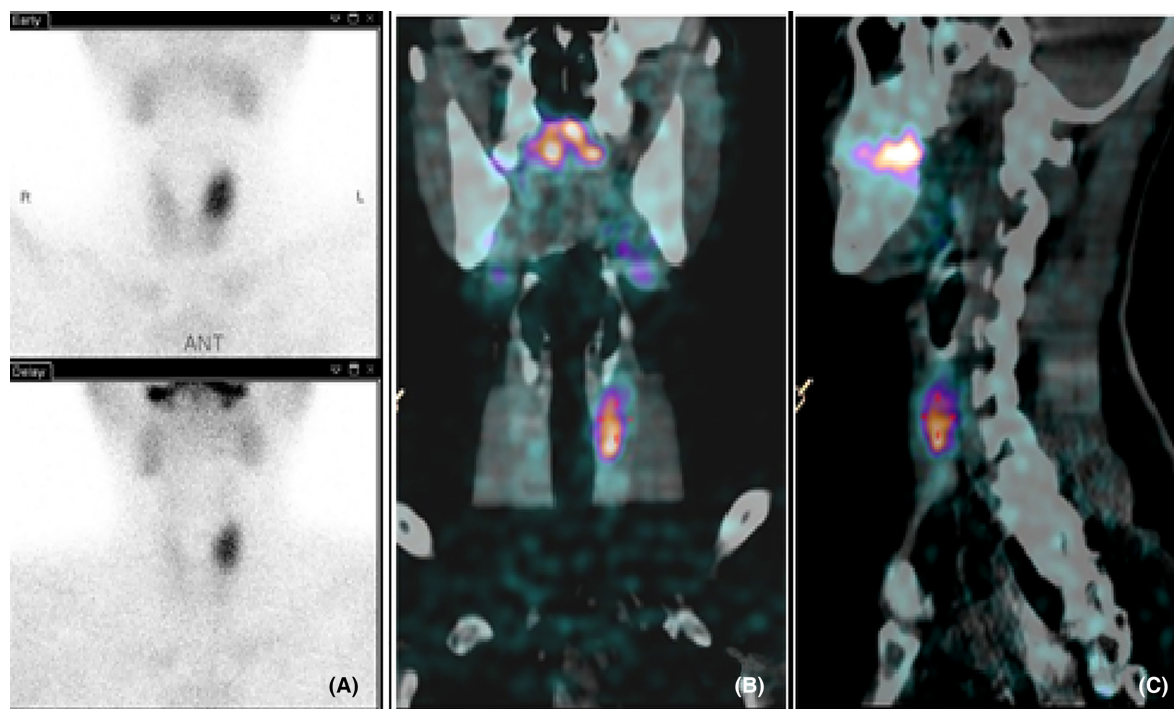
The effects of PTH in bone can be either catabolic or anabolic. Prevalence of one action will determine the net effect of PTH on bone mass and its microarchitecture. In co-culture experiments [10], osteoblasts are continuously exposed to PTH and sustain osteoclastogenesis, mimicking the effect of continuous exposure to high levels of PTH, as it occurs to PHPT patients. Under these conditions, PTH will lead to an increased osteoblast expression of the receptor activator of nuclear factor  $\kappa$ B ligand (RANKL). RANKL will bind to its receptor (RANK), which is expressed in osteoclast precursors, thereby stimulating osteoclastogenesis and osteoclast activity. In parallel, PTH induces a decrease in osteoprotegerin (OPG), a decoy receptor for RANKL, which prevents RANKL interaction with RANK. Increased RANKL/OPG ratio is thought to be the main mechanism by which a high level of PTH that elicits bone resorption is maintained [11]. In PHPT, osteoblasts and osteoclasts are increased, but the resorption depth is overtaken and the bone formation period is long. These ultrastructural events account for

**Table 1.** Clinical and laboratory data of the PHPT patient before and after surgery.

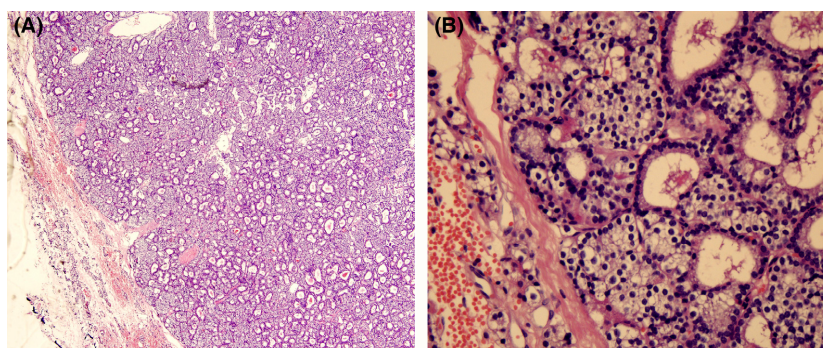
Indicator range	Pre op.	Post op. 1 week	1 month	3 month	6 month	Reference range
Serum calcium (mmol/L)	3.47	1.06	1.97	2.13	2.29	2.25–2.75
Serum phosphorus (mmol/L)	0.65	0.70	0.84	1.59	1.34	0.82–1.60
Serum PTH (pg/mL)	2011	405	350	569	490	11–87
TP1NP (ng/mL)	1200	789	721	726	731	9.1–76.2
CROSSL (ng/mL)	4.08	4.01	3.18	3.21	3.84	0.04–0.78
Vit D (ng/mL)	<3.0	8.4	13.19	6.7	4.44	>20
BMD <i>t</i> score						
Lumbar spine	–1.5		–1.1		0.1	≥–1.0
Femoral neck	–3.1		–2.5		–1.9	≥–1.0

TP1NP, I collagen amino-terminal extension peptide; CROSSL, b-collagen-specific sequences; Vit D, 25-hydroxyvitamin D; BMD, bone mineral density; pre-op., preoperative; post-op., postoperative.





**Figure 3.** Positive Tc-99 m-MIBI-SPECT imaging scan demonstrating increased radioactive pharmaceutical uptake in the left lower pole of the thyroid gland in the early and delayed images (A). SPECT/CT images localize this focus to the left thyroid region (B and C).



**Figure 4.** Hematoxylin and eosin (HE) staining of the excised parathyroid lesion with primary hyperthyroidism shows predominantly cystic follicular adenoma. Low power ( $\times 4$ , A) and high power ( $\times 40$ , B).

the increase in markers of bone turnover and changes in bone mineral density (BMD) [12]. This finding was in agreement with our case, in which markers of bone formation activity (TP1NP) and bone resorption activity (CROSSL) are increased in patients with severe osteoporosis (Table 1). Eventually, high levels of PTH lead to patellar subperiosteal bone resorption, thereby reducing the firmness of the quadriceps tendon, which attaches to the upper pole of the patella; these factors led to complete disruption of the quadriceps tendon [13, 14]. Another important factor of QTR occurrence is the sustained high

level of PTH caused by a long-term and chronic injury on the quadriceps tendon as toxins. These toxins cause negative feedback of tendon organization, leading to a reduction in protein-polysaccharide aggregate, enzyme secretion, maturity of actuate collagen fiber, and immaturity of quadriceps collagen [15, 16]. These pathologic changes led to significant tendon abnormalities that tendon mechanical stresses may further damage and exceed their tensile strength to the point of rupture. Therefore, a small trauma can lead to complete disruption of the quadriceps tendon.

Traditionally, the surgical approach to PHPT is bilateral exploration of the parathyroid glands and excision of abnormal glands. PHPT is generally more severe in this age group; therefore, young people are at a significant risk of postoperative hungry bone syndrome (approximately 50%) and acute hypocalcemia (approximately 50%) [17]. In addition, some patients will develop persistent hypocalcemia (2%) [18]. In the present case, the complications arising from surgery for parathyroidectomy include seizures from hypocalcemia, long-term postoperative hypocalcemia, and persistent hyperparathyroidism. A new diagnosis, especially for secondary hyperparathyroidism, was made. However, we are apprehensive about tertiary hyperparathyroidism that occurs if long-standing secondary hyperparathyroidism leads to autonomous PTH production with hypercalcemia. We shall continue observing the patient closely through routine biochemical screenings.

In conclusion, quadriceps tendon ruptures are uncommon injuries that require early surgical treatment and subsequent functional exercise to maximize the functional outcome of the patient. For young patients with tendon ruptures, especially in spontaneous or minimally traumatic ruptures, pathogenesis is considered multifactorial, especially PHTH. Systematic treatment for PHTH is effective in correcting tendon damage and metabolic disturbances.

## Conflict of Interest

None declared.

## Authorship

JX and XG: supervised and wrote the clinical case report; XG and ZS: analyzed clinical and laboratory data; SL: contributed to the revision of the manuscript. All authors reviewed the manuscript.

## References

- Steiner, C. A., and L. H. Palmer. 1949. Simultaneous bilateral rupture of the quadriceps tendon. *Am. J. Surg.* 78:752–755.
- Mousa, A., S. Jones, and A. Toft. 1999. Spontaneous rupture of achilles tendon: missed presentation of Cushing's syndrome. *BMJ* 319:560–561.
- de Ávila Fernandes, E., G. B. Sandim, S. A. Mitraud, et al. 2010. Sonographic description and classification of tendinous involvement in relation to tophi in chronic tophaceous gout. *Insights Imaging* 1:143–148.
- Alves, E. M., J. C. Macieira, E. Borba, F. A. Chiuchetta, and M. B. Santiago. 2010. Spontaneous tendon rupture in systemic lupus erythematosus: association with Jaccoud's arthropathy. *Lupus* 19:247–254.
- Soo, I., J. Christiansen, D. Marion, M. Courtney, and V. A. Luyckx. 2011. Sequential rupture of triceps and quadriceps tendons in a dialysis patient using hormone supplements. *Clin. Nephrol.* 75:20–23.
- Park, J. H., S. B. Kim, H. S. Shin, G. H. Jung, Y. S. Jung, and H. Rim. 2013. Spontaneous and serial rupture of both achilles tendons associated with secondary hyperparathyroidism in a patient receiving long-term hemodialysis. *Int. Urol. Nephrol.* 45:587–590.
- Omar, M., P. Haas, M. Ettinger, C. Krettek, and M. Petri. 2013. Simultaneous bilateral quadriceps Tendon Rupture following Long-Term Low-Dose Nasal Corticosteroid Application. *Case Rep. Orthop.* 2013:657845.
- Senthilkumaran, S., S. Shah, N. Balamurugan, P. Thirumalaikolundusubramanian. 2012. Levofloxacin, tendon rupture and acute kidney injury: thinking outside the box. *Indian J. Nephrol.* 22:65.
- George, J., S. V. Acharya, T. R. Bandgar, P. S. Menon, and N. S. Shah. 2010. Primary hyperparathyroidism in children and adolescents. *Indian J. Pediatr.* 77:175–178.
- Huang, J. C., T. Sakata, L. L. Pflieger, M. Bencsik, B. P. Halloran, D. D. Bikle, et al. 2004. PTH differentially regulates expression of RANKL and OPG. *J. Bone Miner. Res.* 19:235–244.
- Nakchbandi, I. A., R. Lang, B. Kinder, K. L. Insogna. 2008. The role of the receptor activator of nuclear factor-kappaB ligand/osteoprotegerin cytokine system in primary hyperparathyroidism. *J. Clin. Endocrinol. Metab.* 93:967–973.
- Schnoke, M., S. B. Midura, and R. J. Midura. 2009. Parathyroid hormone suppresses osteoblast apoptosis by augmenting DNA repair. *Bone* 45:590–602.
- Bhole, R., J. C. Flynn, and T. C. Marbury. 1985. Quadriceps tendon ruptures in uremia. *Clin. Orthop. Relat. Res.* (195):200–206.
- Ohishi, M., and E. Schipani. 2011. PTH and stem cells. *J. Endocrinol. Invest.* 34:552–556.
- Jones, N., and C. M. Kjellstrand. 1996. Spontaneous tendon ruptures in patients on chronic dialysis. *Am. J. Kidney Dis.* 28:861–866.
- Basic-Jukic, N., I. Juric, S. Racki, and P. Kes. 2009. Spontaneous tendon ruptures in Patients with end-stage renal disease. *Kidney Blood Press. Res.* 32:32–36.
- Paunovic, I., V. Zivaljevic, R. Stojanic, N. Kalezic, M. Kazic, and A. Diklic. 2013. Primary hyperparathyroidism in children and young adults:—a single institution experience. *Acta Chir. Belg.* 113:35–39.
- Dutta, D., M. Kumar, R. N. Das, S. Datta, D. Biswas, S. Ghosh, et al. 2013. Primary hyperparathyroidism masquerading as rickets: diagnostic challenge and treatment outcomes. *J. Clin. Res. Pediatr. Endocrinol.* 5:266–269.