

# Arthroscopically Assisted Tape Augmentation for Anterior Talofibular Ligament Repair



Madeleine Willegger, M.D., F.E.B.O.T., and Reinhard Schuh, M.D., Ph.D.

**Abstract:** In this Technical Note, we describe arthroscopically assisted tape augmentation of a modified Broström repair for chronic lateral ankle instability. Specifically, this technique involves talar anchor placement under direct arthroscopic visualization combined with a minimally invasive approach for anatomic anterior talofibular ligament repair and Fiber-Tape (Arthrex, Naples, FL) augmentation. The primary advantage of our technique compared with open InternalBrace (Arthrex) techniques is that only a 2-cm incision is made and no subcutaneous suture passing and knot tying are required, which bear the danger of superficial peroneal nerve damage. In addition, the risk of nonanatomic anchor placement is diminished owing to direct arthroscopic visualization and preparation of the anterior talofibular ligament remnants.

Recently, the concept of arthroscopic ankle ligament surgery has gained increasing attention because it is minimally invasive and intra-articular pathologies can be diagnosed and addressed simultaneously. Multiple so-called arthroscopic or arthroscopically assisted techniques for anterior talofibular ligament (ATFL) repair and reconstruction have been described.<sup>1,2</sup> Nevertheless, arthroscopically assisted percutaneous ATFL reinforcement with the inferior extensor retinaculum must be distinguished from arthroscopic repair techniques. Percutaneous techniques bear the potential danger of irritation or iatrogenic damage to the superficial peroneal nerve (SPN).<sup>1,2</sup>

Open augmentation of the Broström procedure with the InternalBrace (Arthrex, Naples, FL) is

biomechanically superior to traditional Broström repair.<sup>3-6</sup> To advance ankle ligament surgery, we propose an arthroscopically assisted augmentation of the ATFL with the InternalBrace. This technique enables precise anatomic repair and augmentation under direct arthroscopic visualization and preparation of the ATFL footprint. Only a minimal incision in addition to a 3-portal arthroscopic technique is needed, which reduces soft-tissue damage during surgery. This technique reinforces the ATFL repair as a secondary stabilizer and safety belt, encouraging natural healing of the ligament by protecting it during the healing phase and supporting early mobilization.

## Surgical Technique

### Patient Selection

The described technique is indicated in patients presenting with symptomatic chronic lateral ankle instability (Table 1).

### Patient Positioning and Instruments

The patient is placed in a supine position, with slight elevation of the ipsilateral buttock with a wedge. The heel of the affected limb rests on the very end of the operating table, enabling the surgeon to dorsiflex the ankle. Surgery can be performed with the patient under general or spinal anesthesia. A single-shot antibiotic prophylaxis is administered intravenously approximately 30 minutes before incision. A thigh tourniquet is applied and inflated to 300 to 350 mm Hg after surgical washing and draping of the foot and

From the Department of Orthopedics and Trauma Surgery, Medical University of Vienna, Vienna, Austria (M.W.); and Department of Pediatric Orthopedics and Foot and Ankle Surgery, Orthopedic Hospital Speising, Vienna, Austria (R.S.).

The authors report the following potential conflicts of interest or sources of funding: R.S. is a consultant for Arthrex, Zimmer Biomet, and ImplanTec, outside the submitted work. Full ICMJE author disclosure forms are available for this article online, as [supplementary material](#).

Received December 29, 2019; accepted February 14, 2020.

Address correspondence to Reinhard Schuh, M.D., Ph.D., Department of Pediatric Orthopedics and Foot and Ankle Surgery, Orthopedic Hospital Speising, Speisinger Straße 109, 1130 Vienna, Austria. E-mail: [reinhard.schuh@me.com](mailto:reinhard.schuh@me.com)

© 2020 by the Arthroscopy Association of North America. Published by Elsevier. This is an open access article under the CC BY-NC-ND license (<http://creativecommons.org/licenses/by-nc-nd/4.0/>).

2212-6287/2016

<https://doi.org/10.1016/j.eats.2020.02.017>

**Table 1.** Indications and Contraindications of Arthroscopically Assisted Internal Brace Augmentation for ATFL Repair

## Indications

- Chronic lateral ankle instability refractory to nonoperative treatment for 3-6 mo
- High-demand patient (participant in recreational or professional sports)
- Moderate to poor ligament remnant tissue
- Generalized ligamentous laxity
- Recurrent ankle ligament instability after surgical repair (in presence of good remnant tissue quality)

## Contraindications

- Pathologic hindfoot alignment (i.e., varus or valgus)
- Absence of sufficient soft-tissue remnants for Broström-Gould repair

ATFL, anterior talofibular ligament.

ankle. We prefer to use a 4-mm 30° scope for ankle arthroscopy,<sup>7</sup> as well as an arthroscopic motorized 3.5-mm shaver, a standard radiofrequency ablation device, and other small-joint arthroscopic instruments (probe, arthroscopic grasper, and so on). Joint distension is achieved using an irrigation pump at 40 to 50 mm Hg. All implants used for the technique are outlined in [Figure 1](#).

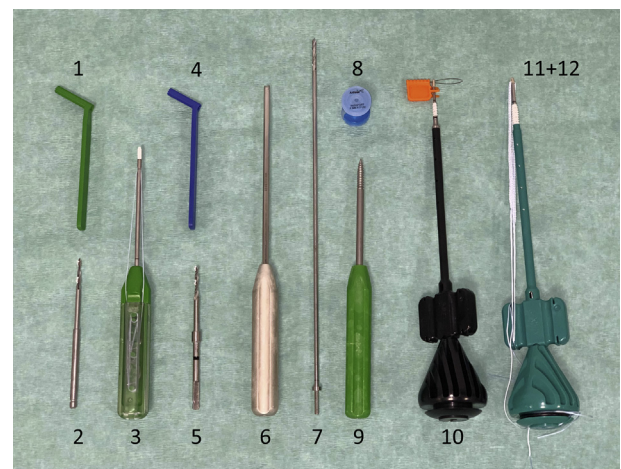
### Portal Placement

Anatomic landmarks are identified and marked prior to surgery ([Fig 2](#)). A step-by-step guide for proper portal placement is outlined in [Table 2](#). The ankle joint is inflated with 15 mL of sodium chloride at the location of the anteromedial portal ([Fig 2](#), [Table 2](#)). A 0.5-mm longitudinal incision is made in the skin, followed by blunt dissection with a mosquito clamp into the joint. The trocar is then inserted and gently pushed into the anterior working space inside the ankle joint. Now, the 4 mm 30° scope can be inserted, and diagnostic ankle arthroscopy can be performed. An anterolateral portal is created as a working portal under direct arthroscopic vision. After anteromedial and anterolateral portal placement, the next step is to debride and dissect the ATFL remnants and to clearly visualize the ATFL footprint at the distal tip of the fibula and at the inferior aspect of the anterolateral corner of the talar trochlea at the talar neck, respectively.<sup>8</sup> The lateral gutter should be cleaned by removing any soft tissue or synovitis with the shaver or radiofrequency ablation device. After preparation of the ATFL remnants, an accessory lateral working portal (accessory anterolateral [AAL] portal) is created ([Table 2](#), [Fig 3](#)).

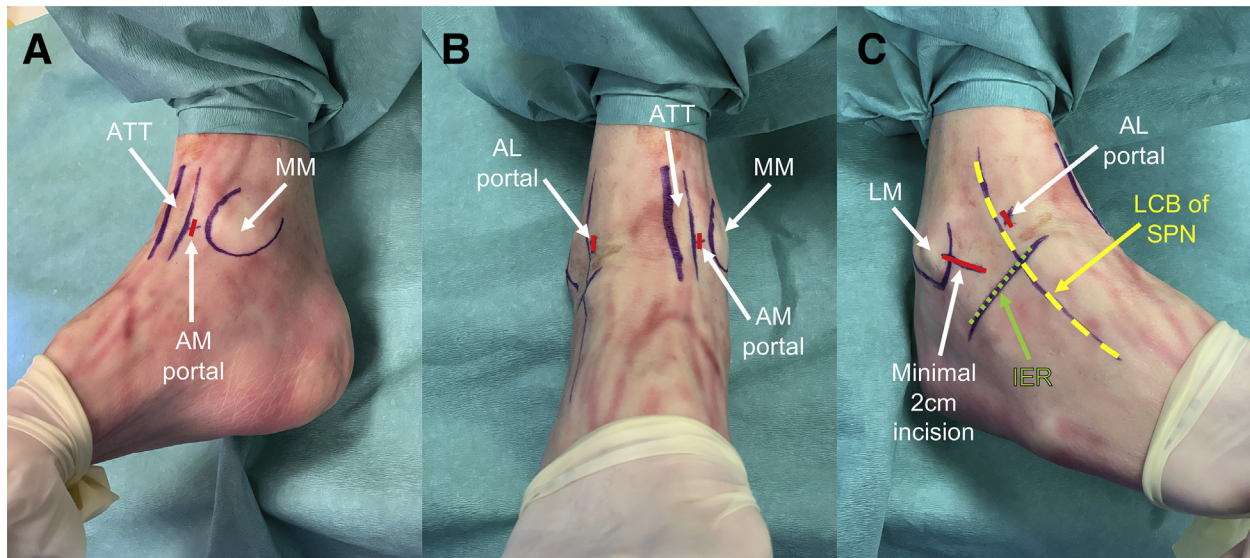
### Arthroscopic Talar Internal Brace Insertion

A PassPort Button cannula (6-mm internal diameter, 2-cm length; Arthrex) is inserted with a mosquito clamp through the AAL portal ([Table 3](#), [Fig 3](#), [Video 1](#)). The surgeon should insert the drill guide through the PassPort Button cannula and hold it just at the anatomic insertion of the talar ATFL footprint. The footprint is located anterior to the joint surface articulating with the lateral malleolus.<sup>8</sup> A 3.4-mm drill is

introduced and is oriented to the talar body from distal to proximal, pointing to the medial malleolus, to avoid penetration of the subtalar joint. The assistant drills with a cannulated 3.4-mm drill and a 20-mm drill stop, followed by tapping with a 4.75-mm tap. A 4.75-mm bone anchor (SwiveLock; Arthrex) loaded with an ultrahigh-strength tape (FiberTape; Arthrex) is placed and inserted. The green paddle on the screwdriver is held stationary while the driver is turned clockwise. The laser line on the driver is buried in the bone. The handle is removed, and a pullout test should be performed to check for adequate anchor engagement ([Fig 4](#)). The PassPort Button cannula is removed, and the FiberTape is temporarily fixed with a mosquito clamp. The scope is also removed.



**Fig 1.** Implants and instruments used for described technique (all implants are from Arthrex): drill guide and 2.4-mm drill for SutureTak preparation (1 and 2); BioComposite-SutureTak, 3 mm × 14 mm, loaded with FiberWire (3); drill guide and 2.7-mm drill for fibular SwiveLock preparation (4 and 5); cannulated drill guide and 3.4-mm cannulated drill for talar SwiveLock preparation (6 and 7); PassPort Button cannula (6-mm internal diameter, 2-cm length) (8); 4.75-mm tap for SwiveLock tapping (9); 3.5-mm × 15.8-mm BioComposite-SwiveLock (10); and 4.75-mm × 19.1-mm BioComposite-SwiveLock loaded with No. 2 FiberTape (11 and 12).



**Fig 2.** Anatomic landmarks: preoperative marking prior to surgery. A right ankle specimen is draped in supine position, and the major landmarks for arthroscopically assisted anterior talofibular ligament (ATFL) repair and InternalBrace augmentation are identified and marked as outlined. (A) Medial view. The red line indicates the anteromedial (AM) portal. (ATT, anterior tibial tendon; MM, medial malleolus.) (B) Anterior view. The red lines indicate the anteromedial (AM) and anterolateral (AL) portals. (ATT, anterior tibial tendon; MM, medial malleolus.) (C) Lateral view with the foot and ankle in a position of supination and hyper–plantar flexion including flexion of the fourth toe. The short red line indicates the anterolateral (AL) portal; long red line, a 2-cm incision in line with the anatomic course of the ATFL, starting just proximal to the palpable tip of the distal fibula; yellow line, lateral cutaneous branch (LCB) of the superficial peroneal nerve (SPN); and green line, inferior extensor retinaculum (IER). (LM, lateral malleolus.)

**ATFL Repair and Fibular Anchor Preparation**

A small, approximately 2-cm incision is made at the anteroinferior aspect of the distal fibula oriented just along the trajectory of the ATFL. Dissection is carried out deeper until the fibular footprint of the ATFL is seen. Right at the central cranial aspect of the fibular

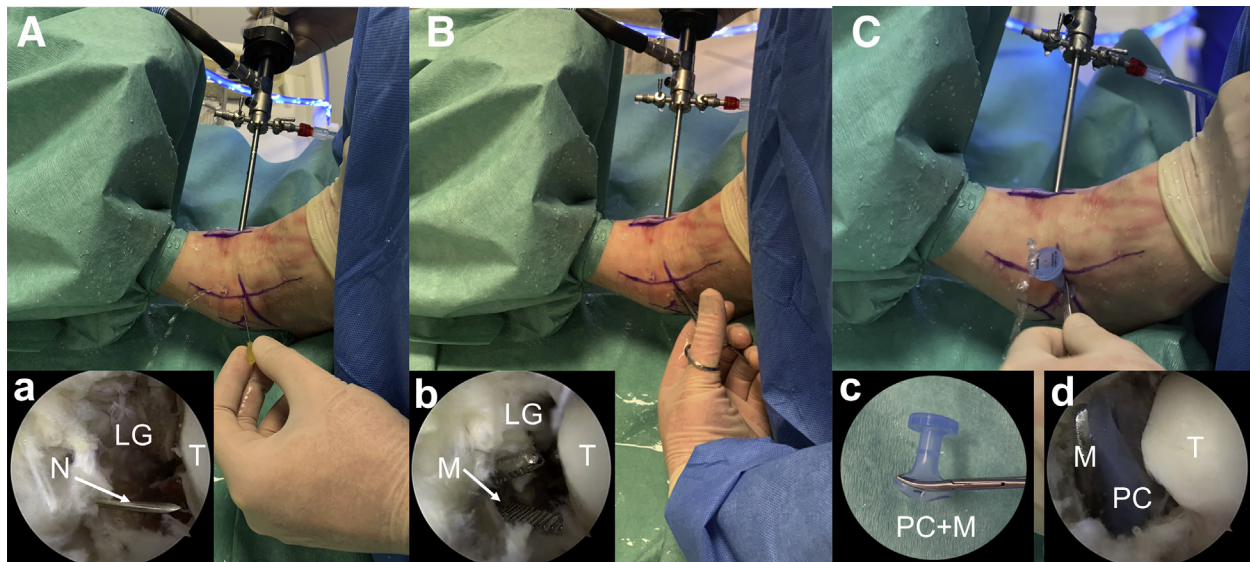
footprint, the cortex is roughened with a chisel (Fig 5). A 3.0-mm SutureTak anchor (Arthrex) loaded with a FiberWire (Arthrex) is inserted after drilling with a 2.4-mm drill. At the lateral aspect of the footprint, the drill guide for the SwiveLock should be placed and drilled with a 2.7-mm drill and 20-mm drill stop. Anchor

**Table 2.** Step-by-Step Portal Placement

Step	Portal	Location	Tips and Tricks
First step	Anteromedial portal	Medial to anterior tibial tendon at level of joint line	<ul style="list-style-type: none"> <li>In a dorsiflexed position, a soft spot and/or depression can be palpated.</li> <li>Dorsiflexion of the ankle translates the excursion of the anterior tibial tendon toward the center of the joint, which enables portal placement as central in the sagittal ankle axis as possible (still medial to the anterior tibial tendon). This will facilitate visualization of the lateral gutter.</li> </ul>
Second step	Anterolateral portal	Lateral to peroneus tertius and/or extensor tendons and medial to lateral cutaneous branch of SPN at joint level	<ul style="list-style-type: none"> <li>Care must be taken to avoid injury to the lateral dorsal cutaneous branch of the SPN, which runs just subcutaneously and can be visualized by holding the foot in a position of forced supination and hyper–plantar flexion and flexing the fourth toe.<sup>2</sup></li> <li>Correct placement of the portal is confirmed when the introduced spinal needle can easily reach the ATFL remnant and the fibular footprint.</li> </ul>
Third step	Accessory lateral working portal (AAL portal)	At level of talar ATFL footprint (Fig 3)	<ul style="list-style-type: none"> <li>A spinal needle should be introduced aiming to the talar insertion of the ATFL to find the right spot for accessory lateral portal placement.</li> <li>The direction of the needle should follow a 90° inclination to the talar ATFL footprint.</li> </ul>

AAL, accessory anterolateral; ATFL, anterior talofibular ligament; SPN, superficial peroneal nerve.





**Fig 3.** Creation of accessory anterolateral portal and technique of PassPort Button cannula introduction. (A) The 30° 4.0-mm scope is placed in the anteromedial viewing portal looking into the lateral gutter, which has previously been cleaned with a shaver and radiofrequency ablation device. A needle is introduced into the ankle joint, starting just lateral to the lateral cutaneous branch of the superficial peroneal nerve and approximately 1 cm distal to the anterolateral portal. The inset (a) is an arthroscopic view looking in the lateral gutter (LG), showing the needle (N) aiming at the talar footprint of the anterior talofibular ligament. The direction of the needle should follow a 90° inclination to the talar body. (T, talus.) (B) After removal of the needle, a small incision, approximately 5 mm long, is made and a mosquito clamp is inserted to perforate and spread the joint capsule. The inset (b) shows an arthroscopic view of the mosquito clamp (M) that spreads the capsule. (LG, lateral gutter; T, talus.) (C) After spreading of the capsule, the PassPort Button cannula (6-mm internal diameter, 2-cm length; Arthrex) can be clamped in the mosquito clamp, as outlined in the left inset (c), and gently introduced into the ankle joint. The right inset (d) shows an arthroscopic view of the talus (T) and the PassPort Button cannula (PC) with the mosquito clamp (M).

drilling is performed in a 30° cranially oriented direction to a neutral foot position and 90° oriented to the fibular cortex. Care must be taken to avoid angulation of the drill toward the ankle joint, but to maintain just

20° to 30° of inclination to the joint. Tapping should be performed with the 4.5-mm tap down to the laser line.

A modified Broström-Gould procedure is carried out by use of FiberWire (Fig 6). During the anatomic ATFL

### Table 3. Pearls and Pitfalls of Technique

#### Pearls

The surgeon should always use a mosquito clamp to penetrate the ankle joint capsule (“nick and spread”). The incision and capsule opening should be kept as small as possible to avoid excessive water leakage.

Cartilage damage is avoided if the ankle is held in a dorsiflexed position throughout portal creation and insertion of sharp instruments. The direction of instrument introduction is always toward the anterior working space.

Insertion of the PassPort Button cannula can be tricky. We offer the following advice: (1) fold the articular-sided lid and use the mosquito clamp to grasp it; (2) once a part of the intra-articular lid is seen on the screen, gently remove the mosquito clamp and turn the PassPort Button cannula clockwise to detangle soft-tissue bridges until the whole lid can be placed in the lateral gutter; and (3) open up the incision for some additional millimeters if you are struggling to pass the cannula inside the joint.

Attention should be paid during talar anchor preparation to avoid penetration into the tibiotalar or subtalar articular space. The drill is oriented to the talar body from distal to proximal, pointing to the medial malleolus.

Only a small, 2-cm incision is needed compared with open techniques, in which an extensive approach is still carried out to dissect the ligaments.

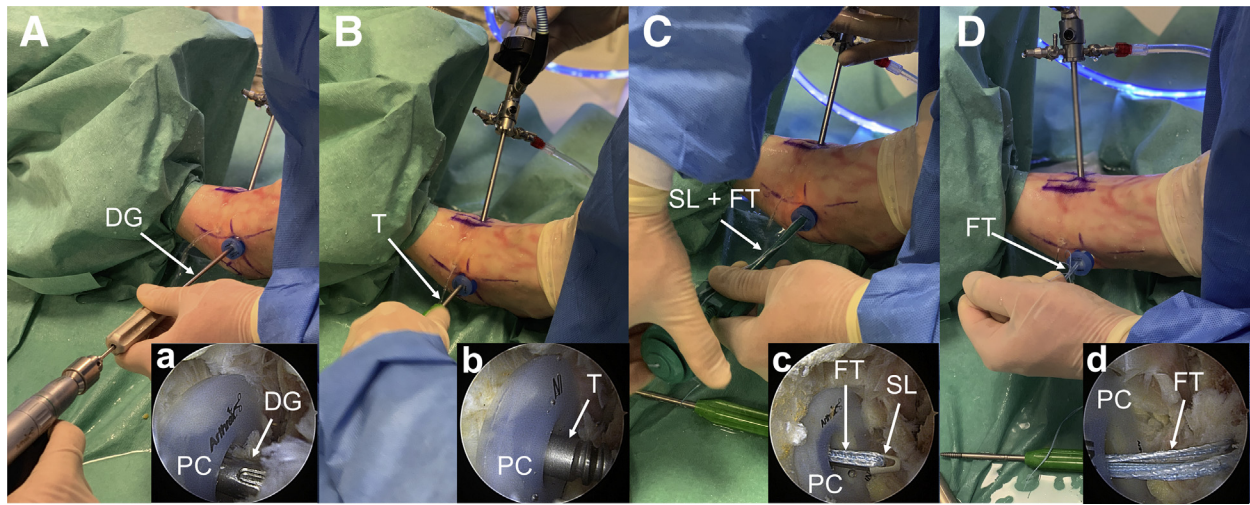
In the fibula, even though a 3.5-mm SwiveLock anchor is inserted, a 4.75-mm tap is used to accommodate the additional FiberTape passing through the drill hole.

#### Pitfalls

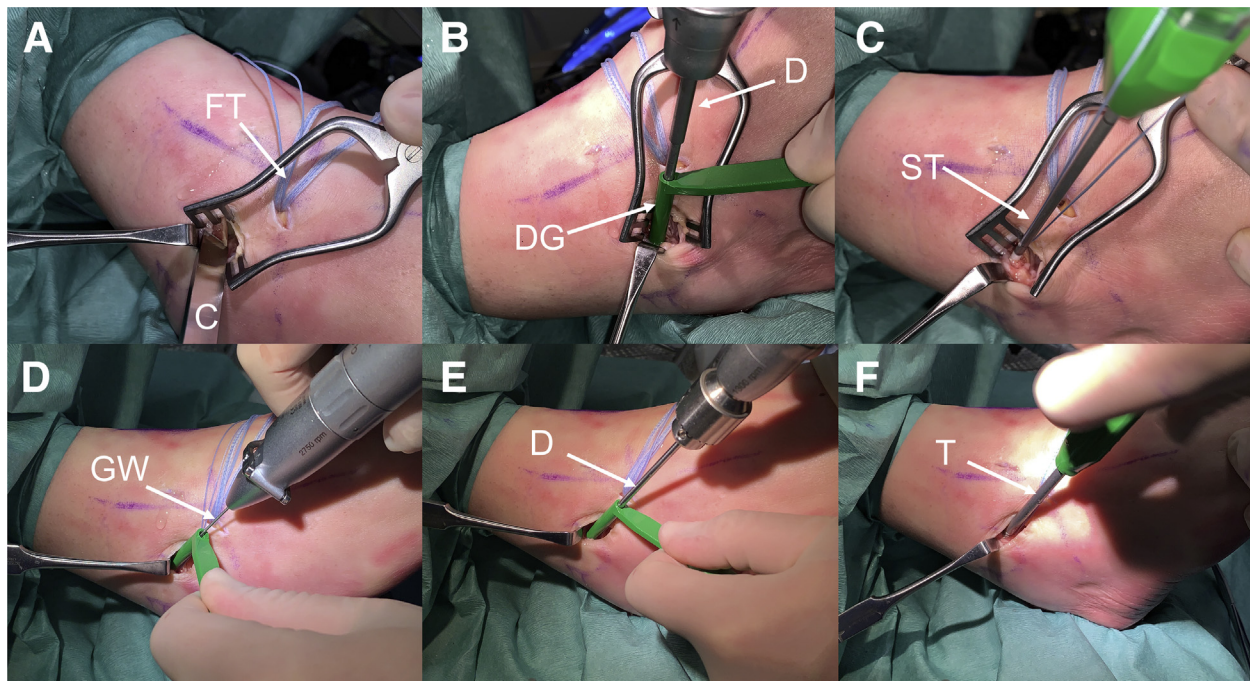
The surgeon should avoid damage to the dorsal cutaneous branch of the SPN—the course of the nerve can be visualized and marked prior to surgery by supination and hyper-plantar flexion of the foot and ankle including flexion of the fourth toe. This is a compulsory step prior to ankle arthroscopy.

The surgeon should avoid aggressive soft-tissue debridement of the lateral gutter that may injure the joint capsule or the ATFL or its remnant. The surgeon must be careful while suturing the anterolateral portal because the SPN can be in the vicinity of the portal and there is a potential for entrapment of the nerve with the sutures.<sup>2</sup>

Over-tightening of the InternalBrace may limit ankle range of motion. The proper amount of tension is at the surgeon’s discretion because there is no way to quantify the ideal amount.

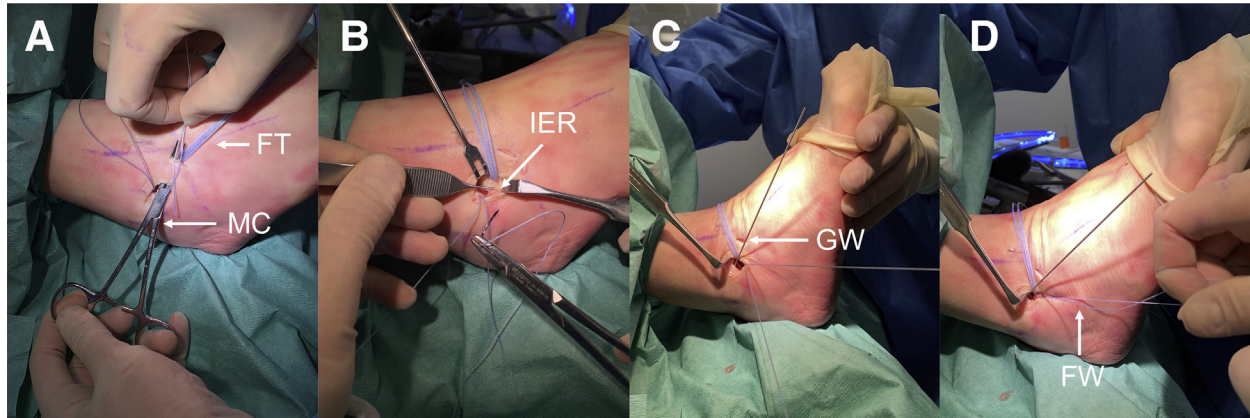


**Fig 4.** Arthroscopic talar anchor placement and InternalBrace insertion: arthroscopic drilling and placement of talar 4.75-mm SwiveLock loaded with No. 2 FiberTape. (A) The drill guide (DG) is inserted through the PassPort Button cannula (PC) in the accessory anterolateral portal. The cannula is used to reduce soft-tissue damage, especially to protect the lateral cutaneous branch of the superficial peroneal nerve. The drill is oriented to the talar body from distal to proximal, pointing to the medial malleolus. The inset (a) shows an arthroscopic view from the anteromedial portal. Drilling is performed at the anatomic talar footprint of the anterior talofibular ligament remnant, angulated 90° to the bony surface. (B) After drilling, a 4.75-mm tap (T) is inserted and tapped down to the black laser line. The inset (b) shows an arthroscopic view during tapping. (PC, PassPort Button cannula.) (C) After tapping, a 4.75-mm SwiveLock (SL) loaded with a No. 2 FiberTape (FT) is inserted in the prepared drill hole. The green paddle on the screwdriver is held stationary while the driver is turned clockwise until the anchor is completely buried in the talus. The inset (c) shows an arthroscopic view during anchor introduction. (PC, PassPort Button cannula.) (D) The driver is removed, and a manual pullout test is performed to check the stability of the SwiveLock. The inset (d) shows an arthroscopic view looking at the tensioned FiberTape (FT) during the manual pullout test. (PC, PassPort Button cannula.)

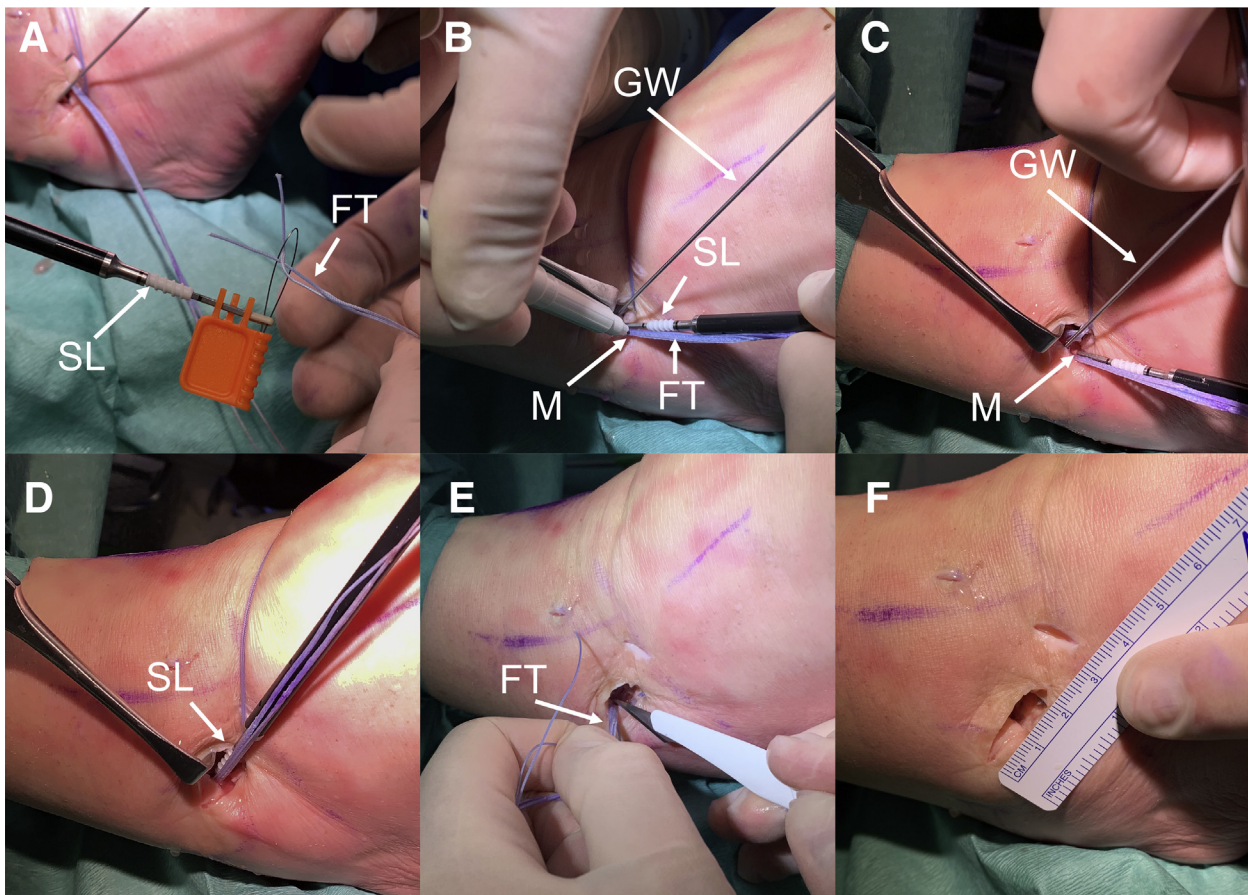


**Fig 5.** Fibular anchor preparation. (A) Preparation of fibular anterior talofibular ligament (ATFL) footprint. The FiberTape (FT) is coming out of the accessory anterolateral portal. A chisel (C) is used to roughen the bony surface to enhance soft tissue-to-bone healing. (B) Drilling with a 2.4-mm drill (D) and a drill guide (DG) at the central cranial aspect of the footprint. (C) Introduction of a 3.0-mm SutureTak (ST) anchor loaded with FiberWire. This anchor is later used for the modified Broström-Gould procedure. (D) Guidewire (GW) drilling at the lateral aspect of the ATFL footprint. (E) Cannulated drilling with a 2.7-mm drill (D) for SwiveLock preparation. After removal of the guidewire and drill, a 4.75-mm tap is used for fibular InternalBrace preparation. (F) To accommodate both lids of the FiberTape, the fibular anchor is prepared with a 4.75-mm tap (T) even though a 3.5-mm SwiveLock is used.





**Fig 6.** Minimally invasive modified Broström-Gould anterior talofibular ligament (ATFL) repair. (A) A mosquito clamp (MC) is inserted from the minimal incision and passed to the accessory anterolateral portal to grasp both ends of the FiberTape (FT) and shuttle it to the incision. The FiberTape will be needed in a later step for InternalBrace augmentation. (B) In this specimen, a modified Broström-Gould repair was indicated. The inferior extensor retinaculum (IER) is identified and held with a pincer. (C) Both ends of the FiberWire are passed through the IER, which is then sutured to the fibular footprint of the ATFL. During this procedure, the foot is held in a neutral position with slight eversion. Before the IER is tied to the fibular footprint, a guidewire (GW) is temporarily placed in the already prepared drill tunnel for the SwiveLock. (D) The modified Broström-Gould ATFL repair is completed by tying both ends of the FiberWire (FW).



**Fig 7.** InternalBrace augmentation. (A) The ends of the FiberTape (FT) are passed through the eyelet of the 3.5-mm SwiveLock (SL). (B) The eyelet of the 3.5-mm SwiveLock anchor (SL) is advanced to the edge of the fibular drill tunnel. The FiberTape suture (FT) should be pulled to the desired tension and marked at the level of the black laser line (M) on the anchor. To avoid over-tensioning, the foot should be placed in a neutral position. The guidewire (GW) is kept in place in the drill tunnel for SwiveLock insertion. (C) The SwiveLock anchor eyelet is moved back to the marked point (M) on the FiberTape suture. The temporarily placed guidewire (GW) is removed. (D) The SwiveLock (SL) is introduced into the drill tunnel. A mallet can be used to gently hit the handle of the anchor. The handle is turned clockwise until the anchor is buried in the bone. (E) The rest of the FiberTape (FT) is cut. (F) Only a small, 2-cm incision is used for arthroscopically assisted anterior talofibular ligament repair with InternalBrace augmentation.

**Table 4.** Advantages, Disadvantages, and Limitations of Technique**Advantages**

- Direct arthroscopic visualization and preparation of the ATFL footprint enable a more anatomic repair.
- No subcutaneous suture passing and knot tying are required, reducing the risk of SPN injury, glove perforation, bulky knots, and knot migration.
- Less surgical dissection (small, 2-cm incision) is required, with more esthetic results.
- Less perioperative morbidity occurs.
- The technique allows early protected range of motion with a faster recovery and return to sports.
- Arthroscopy enables evaluation of the ankle joint and diagnosis and treatment of associated intra-articular pathology.

**Disadvantages and limitations**

- The use of nonabsorbable suture tape can lead to chronic inflammation followed by a foreign body reaction.
- The InternalBrace should not be used as a standalone construct; therefore, the technique is limited by the available remnant tissue. Anatomic reconstruction of the ATFL with allograft or autograft is indicated in severe cases in which there are no ATFL remnants.
- Arthroscopically assisted ATFL repair and augmentation require previous experience in ankle arthroscopy.
- The use of suture anchors and implants increases the cost compared with some traditional open techniques.

ATFL, anterior talofibular ligament; SPN, superficial peroneal nerve.

repair, the foot is held in slight eversion and neutral dorsiflexion.

**InternalBrace Augmentation**

A mosquito clamp is used to pass the FiberTape from the AAL portal through the incision (Video 1). A detailed step-by-step explanation of InternalBrace augmentation is outlined in Figure 7. Skin closure is performed with No. 4-0 nonresorbable atraumatic sutures. No suction drain is used.

**Postoperative Mobilization and Rehabilitation**

The patient is placed in an ankle brace for 4 weeks. Weight bearing is allowed immediately as tolerated. Antithrombotic prophylaxis is used until full weight bearing is achieved. Physical therapy begins after 2 weeks, with range-of-motion exercises and gait training; no forced eversion and inversion of the foot should be performed. In addition, strengthening and balance exercises are initiated. Swimming and bicycling are allowed at 2 months postoperatively, and unrestricted sports, including contact sports, are allowed at 3 months postoperatively depending on the preoperative sports activity level.

**Discussion**

We have described an arthroscopically assisted augmentation of an ATFL repair with the InternalBrace. It is a simple, minimally invasive, and quick procedure that provides additional initial stability to and protection of an anatomic ATFL repair. Adding the InternalBrace as an augmentation to a modified Broström-Gould procedure makes early active rehabilitation possible.<sup>9</sup>

During arthroscopic preparation, the individual anatomy and pathology of the patient can be addressed more precisely and, therefore, repair and augmentation can be performed at the exact fibular and talar footprint (Table 4). Most so-called arthroscopic Broström procedures include a subcutaneous technique in which sutures are passed through the inferior extensor

retinaculum to reinforce the ATFL repair. The disadvantage of these techniques is the high rate of SPN entrapment with subsequent pain and discomfort for the patient.<sup>1</sup> Even though there is a certain risk of lateral cutaneous branch damage in every ankle arthroscopy owing to the proximity of the SPN to the lateral portal, we have not seen any nerve entrapment or damage in our patients treated with this technique.

Indications and contraindications are shown in Table 1, and pearls and pitfalls are shown in Table 3. One risk of this technique is excessive tensioning of the ultrahigh-strength tape. This can lead to stiffness and a postoperative limitation in ankle joint range of motion.

Augmenting the ATFL repair with the InternalBrace allows early active rehabilitation without the need for extended protection.<sup>5,6</sup> We see this technique as a tool for the highly active patient with chronic lateral ankle instability.

**References**

1. Matsui K, Burgesson B, Takao M, et al. Minimally invasive surgical treatment for chronic ankle instability: A systematic review. *Knee Surg Sports Traumatol Arthrosc* 2016;24:1040-1048.
2. Vega J, Dalmau-Pastor M, Malagelada F, Fargues-Polo B, Pena F. Ankle arthroscopy: An update. *J Bone Joint Surg Am* 2017;99:1395-1407.
3. Schuh R, Benca E, Willegger M, et al. Comparison of Brostrom technique, suture anchor repair, and tape augmentation for reconstruction of the anterior talofibular ligament. *Knee Surg Sports Traumatol Arthrosc* 2016;24:1101-1107.
4. Willegger M, Benca E, Hirtler L, et al. Biomechanical stability of tape augmentation for anterior talofibular ligament (ATFL) repair compared to the native ATFL. *Knee Surg Sports Traumatol Arthrosc* 2016;24:1015-1021.
5. Yoo JS, Yang EA. Clinical results of an arthroscopic modified Brostrom operation with and without an internal brace. *J Orthop Traumatol* 2016;17:353-360.
6. Coetzee JC, Ellington JK, Ronan JA, Stone RM. Functional results of open Brostrom ankle ligament repair augmented with a suture tape. *Foot Ankle Int* 2018;39:304-310.

7. Hirtler L, Schuh R. Accessibility of the talar dome-anatomic comparison of plantarflexion versus noninvasive distraction in arthroscopy. *Arthroscopy* 2018;34:573-580.
8. Matsui K, Takao M, Tochigi Y, Ozeki S, Glazebrook M. Anatomy of anterior talofibular ligament and calcaneofibular ligament for minimally invasive surgery: A systematic review. *Knee Surg Sports Traumatol Arthrosc* 2017;25:1892-1902.
9. Ulku TK, Kocaoglu B, Tok O, Irgit K, Nalbantoglu U. Arthroscopic suture-tape internal bracing is safe as arthroscopic modified Brostrom repair in the treatment of chronic ankle instability. *Knee Surg Sports Traumatol Arthrosc* 2020;28:227-232.