

Teaching Case

Case report of tracheobronchial squamous cell carcinoma treated with radiation therapy and concurrent chemotherapy

Vishesh Agrawal BA ^{a,b}, J. Paul Marcoux MD ^{b,c},
Michael S. Rabin MD ^{b,c}, Inna Vernovsky MD ^d, Jon O. Wee MD ^{b,e},
Raymond H. Mak MD ^{a,b,*}

^a Department of Radiation Oncology, Dana-Farber Cancer Institute, Brigham and Women's Hospital, Boston, Massachusetts

^b Harvard Medical School, Boston, Massachusetts

^c Department of Medical Oncology, Dana-Farber Cancer Institute, Brigham and Women's Hospital, Boston, Massachusetts

^d Department of Pulmonary Medicine, Newton-Wellesley Hospital, Newton, Massachusetts

^e Division of Thoracic Surgery, Brigham and Women's Hospital, Boston, Massachusetts

Received 1 January 2016; received in revised form 10 March 2016; accepted 18 March 2016

Introduction

Tracheobronchial tumors include primary malignant tumors, secondary malignant tumors, and benign tumors. Primary malignant tumors of the trachea are rare, representing only 0.1% to 0.4% of all malignant disease. Squamous cell carcinoma (SCC) and adenoid cystic carcinoma are the most common histological subtypes, making up approximately two-thirds of primary tracheal neoplasms.¹ Such tumors have typically been treated with surgical resection and adjuvant radiation therapy (RT; Table 1). Medically inoperable tumors are usually treated with definitive RT, but because of the rarity of these tumors, there are no randomized trials to determine the optimal treatment regimen.^{8,14}

A radiation dose of ~60 Gy has been most commonly reported for external beam RT, with higher doses having

significant toxicity of the tracheal and esophageal tissue using historical techniques.¹⁵⁻¹⁷ In contrast to definitive RT, the use of definitive RT with concurrent chemotherapy for tracheal SCC has been sparingly described in the literature.^{2,3,5,18} In this report, we describe our experience with 2 patients at our institution who received definitive RT using modern techniques with concurrent chemotherapy for tracheobronchial SCC.

Case presentation

Patient 1, a 72-year-old female, initially presented with recurrent pneumonia, thrombocytosis, and leukocytosis. She had a 30 pack-year smoking history, but had quit for >25 years before the presentation. The patient underwent bronchoscopy, which revealed an infiltrating, granular, endobronchial mass extending from the carina into the left mainstem and right upper lobe bronchus (Fig 1A). The right mainstem bronchus was 80% occluded. There was no evidence of primary lung tumor or infiltration. Tracheal biopsies were consistent with SCC. Positron

Conflicts of interest: None.

* Corresponding author. Department of Radiation Oncology, Brigham and Women's Hospital, 75 Francis Street, ASB1-L2, Boston, MA 02115.

E-mail address: rmak@partners.org (R.H. Mak)

<http://dx.doi.org/10.1016/j.adro.2016.03.003>

2452-1094/Copyright © 2016 the Authors. Published by Elsevier Inc. on behalf of the American Society for Radiation Oncology. This is an open access article under the CC BY-NC-ND license (<http://creativecommons.org/licenses/by-nc-nd/4.0/>).

Table 1 Treatment and outcomes of case reports and series describing tracheobronchial cancer

Study	No. of patients (SCC/total)	Treatment (no. of patients)	Radiation dose	Median survival	5-y OS (%)	Pattern of failure
Joshi et al (2014) ²	9 total	Chemo RT	60-64 Gy	NR	NR	NR
Xie et al (2012) ³	66 SCC/156 total	RT (33) No RT (33)	NR NA	73 mo 7 mo	51.0 7.6	NR NR
Abbate et al (2010) ⁴	1 SCC	RT	50.4 Gy Boost to 61.2 Gy	1 y	NA	NR
Hetnał et al (2010) ⁵	24 SCC/50 total	Surgery + RT (3)* RT (39)* Chemo-RT (4)*	64 Gy (definitive), 35 Gy (palliative)	NR NR NR	66* 16* 0*	5-y LRRFS 18%, 5-y DFS 15%
Ly et al (2010) ⁶	1 SCC	Endotracheal ablation and XRT (1)	66.6 Gy	> 16 mo	NA	NR
Ahn et al (2009) ⁷	11 SCC/23 total	Surgery (6) EBRT (2) Surgery + EBRT (3)	NA NR NR	NR NR NR	50 0 50	NR NR NR
Gaissert et al (2004) ⁸	135 SCC/270 total	Surgical resection ± adjuvant EBRT (90) Definitive RT (45) EBRT (3) or EBRT + ILRT (1)	54 Gy adjuvant 60 Gy EBRT 10-56 Gy ILRT 15 Gy (LDR)	38 mo 8.8 mo 38 mo*	39 7.3 37*	NR NR Local failure: 2/9 Distant failure 4/9
Videtic et al (2003) ¹⁰	1 SCC	No treatment (2) Chemo RT	NA 60 Gy	>2 y	NR	NR
Chao et al (1998) ¹¹	28 SCC/42 total	Definitive RT ≥50 Gy (6) Definitive RT <50 Gy (22)	50-64 Gy* 36 Gy (median)*	12.4 mo* 4.5 mo*	NR	NR
Makarewicz et al (1998) ¹²	13 SCC/23 total	RT	60 Gy (primary therapy) 20 Gy ILRT + 30 Gy EBRT (palliative)	17 mo	NR	NR
Schraube et al (1994) ¹³	11 SCC	RT (10)	54-60 or 46-50 Gy + 3-4 x5 Gy High-dose endotracheal afterloading	31 mo	NR	Local failure 5/10 Distant failure 3/10
Chow et al (1993) ²⁴	7 SCC/22 total	Surgery + RT (1) Surgery (4) Surgery + EBRT (1) EBRT (7)	60 Gy NA 50-60 Gy* 30-68 Gy*	NR 16 mo* 146 mo 26 mo*	NR NR NR NR	NR LRR 40%* LRR 20%* LRR 67%*
Fields et al (1989) ¹⁶	13 SCC/24 total	RT Surgery + RT	<40-70 Gy	10 mo*	25*	Locoregional failure 14/24* Distant failure 12/24*
Cheung (1989) ¹⁷	20 SCC/24 total	EBRT (2 orthovoltage, 17 megavoltage)	13-70 Gy	5 mo	NR	NR

DFS, disease-free survival; EBRT, external beam radiation therapy; ILRT, intraluminal radiation therapy; LRRFS, locoregional recurrence-free survival; NA, not applicable; NR, not reported; RT, radiation therapy; SCC, squamous cell cancer.

* No subgroup analysis by squamous histology reported.

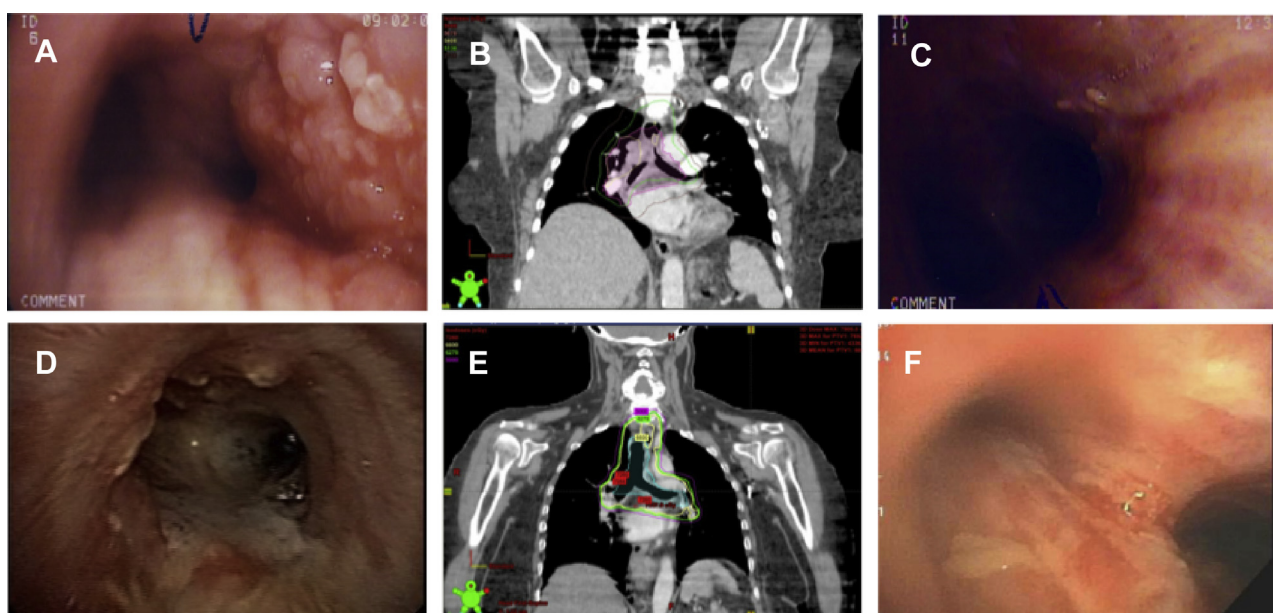


Figure 1 Patient 1 (A) Pretreatment bronchoscopy photograph of distal trachea with granular mass, (B) Radiation treatment plan with 56 Gy isodose line indicated in purple; (C) posttreatment bronchoscopy of distal trachea. Patient 2 (D) pretreatment bronchoscopy photograph with nodularity of distal trachea; (E) radiation treatment plan with 62 Gy isodose line indicated in green. (F) Patient posttreatment bronchoscopy of distal trachea.

emission tomography (PET) computed tomography (CT) further revealed a fludeoxyglucose (FDG) avid right paratracheal node and was thus consistent with stage IV disease under the Bhattacharyya staging system.¹⁹ Given the extensive tracheal involvement, the patient was not considered a surgical candidate. The patient was treated with 60 Gy external beam RT in 30 fractions using 3-dimensional conformal techniques (Fig 1C) with concurrent weekly carboplatin and Taxol. The internal target volume included the trachea, right mainstem bronchus, right paratracheal node, and right hilum with a clinical target volume (CTV) margin of 3 to 5 mm axially and 7 to 10 mm superiorly and inferiorly. There was no elective nodal irradiation. The mean lung dose delivered was 17.9 Gy with a V20 (percentage of lung receiving 20 Gy) of 35.7% and V5 of 67.0%. The mean dose delivered to the esophagus was 32.3 Gy with a V55 of 46%.

She experienced side effects of mild odynophagia and dysphagia (Radiation Therapy Oncology Group [RTOG] grade 2) treated by hydrocodone and acetaminophen. She also experienced significant fatigue requiring intravenous hydration. At 3 months' posttreatment, she developed grade 2 radiation pneumonitis that resolved with prednisone. She developed distant recurrence at 12 months with renal metastasis. PET scan showed an FDG uptake in the left kidney with no abnormal uptake in the thorax. Bronchoscopy showed no evidence of endobronchial lesions (Fig 1B). The patient died of progressive disease at 15 months. She had no evidence of local recurrence.

Patient 2, a 63-year-old female, initially presented with a productive cough. She had a 60 pack-year history of

smoking but had quit 5 years before presentation. Bronchoscopy revealed multiple endotracheal and endobronchial nodules beginning 1 cm below the vocal cords extending to the carina and along the left mainstem bronchus (Fig 1D; Appendix E1; available as supplementary material online only at www.practicalradonc.org). There was no evidence of disease in the right airway. Biopsy revealed SCC in situ with suspected focal invasion. PET CT showed slight FDG uptake in the trachea from the sternal notch to the carina, left mainstem bronchus, and left hilum, consistent with Bhattacharyya stage III. There was no evidence of primary lung tumor or infiltration into bronchus. Given the extensive involvement of the airway, the patient was treated with 66 Gy in 33 fractions using IMRT (Fig 1F) with 2 cycles of concurrent cisplatin and etoposide. Given the difficulty of visualizing disease extent, we used PET CT, bronchoscopy videos, and discussions with the thoracic surgeon and pulmonologist who performed the bronchoscopy to identify anatomic landmarks to demarcate the extent of disease. The internal target volume included the trachea and left mainstem bronchus with a 3 mm CTV margin axially and a 7 mm CTV margin superiorly and inferiorly. There was no elective nodal irradiation. The mean lung dose was 14.2 Gy with a V20 of 27.3% and a V5 of 50.3%. The mean dose to the esophagus was 36.9 Gy with a V55 of 51%.

During treatment, the patient developed moderate dysphagia and esophagitis (RTOG grade 1) and subsequent difficulty with oral intake requiring multiple administrations of intravenous fluids, but able to eat a

regular diet throughout therapy. She had grade 3 dermatitis with moist desquamation of the anterior neck. Surveillance bronchoscopies at 4 and 9 months showed no residual or recurrent disease. However, the patient developed hemoptysis at 11 months after chemo-RT. Bronchoscopy at 14 months showed no evidence of disease; however, biopsies of the left mainstem bronchus revealed SCC in situ. Chest CT at this time also revealed multiple bilateral pulmonary nodules suspicious for metastatic disease. The patient was hospitalized multiple times with hypoxia, and a chest CT at 16 months revealed an increase in bilateral pulmonary nodules consistent with metastatic disease. The patient died at 17 months.

Discussion

Given the rarity of tracheobronchial tumors, there have been no randomized controlled trials to determine the optimal therapy. The preferred form of therapy is surgical resection with adjuvant RT because of its favorable outcomes over RT alone. The reported 5-year survival rate for surgically treated patients is 41% to 57% compared with 6% to 11% for patients treated with definitive radiation.^{7,8,20} Yet, up to one-third of patients with tracheal cancer may not be surgical candidates, most often because of the extent of locoregional disease.⁸ For patients who are not surgical candidates, the choice of treatment has generally been RT, with few studies describing the use of chemotherapy for tracheal SCC.^{5,10} This report expands on the existing literature by describing the treatment of 2 patients with definitive RT and concurrent chemotherapy.

As a result of advances in surgical techniques, the majority of patients with tracheobronchial disease are candidates for surgery. Resection of up to one-half of the length of the adult trachea is feasible with modern mobilization techniques.²¹ Adjuvant radiation is generally recommended for resectable SCC and adenoid cystic carcinoma.^{3,14} Because of the narrow margins of resection achieved in tracheal surgery, Grillo and Mathisen recommended the use of postoperative radiation in all cases, including those with negative margins and lymph nodes.¹⁴ Contraindications to surgery include metastatic disease, invasion of adjacent organs, involvement of airway greater than could be safely resected (>50% of trachea), involvement of airway that would leave grossly positive margins after resection, spinal kyphosis, or poor medical condition of the patient.^{8,22,23}

There remains a high mortality for patients with unresectable tracheal cancer and thus prompts an examination of the reported treatments for these patients, which has generally been limited to external beam RT,^{4,11-13,16} with some reports of brachytherapy^{9,12} and endotracheal ablation.⁶ Review of the literature indicates that local recurrence is the most common pattern of failure for

tracheobronchial SCC with rates between 19% and 73%.^{5,8,13} However, distant failure is also substantial, reported between 13% and 46%, supporting the potential inclusion of chemotherapeutic regimens for the treatment of this disease.

Although concurrent chemoradiation is used in non-small cell carcinoma and head and neck cancer, there are few reports describing its use in tracheobronchial tumors. Videtic et al reported 1 patient with tracheal SCC who received 2 cycles of induction cisplatin, etoposide, leucovorin, and 5-fluorouracil followed by 2 cycles of cisplatin, etoposide, leucovorin, and 5-fluorouracil concurrent with 60 Gy RT (30 fractions), resulting in survival greater than 2 years.¹⁰ Hetnal et al demonstrated the use of etoposide and cisplatin after RT (median, 64 Gy) in 4 patients with tracheal cancer, but did not report a median survival rate for these patients.⁵ Joshi et al expanded on these results with a recent series of 9 patients treated with radiation (CTV 90, 62.5 Gy) and concurrent chemotherapy (paclitaxel 50 mg/m² and carboplatin area under the curve = 2 weekly).² Although target volumes are not clearly described in many reports, several case series of definitive RT have included hilar nodes, subcarinal nodes, and mediastinal nodes within their target volumes.^{5,12,13} Further details regarding the radiation dose delivery (such as CTV margin) have not been clearly described in historical reports.

The patients in this report were treated with RT and concurrent chemotherapy. We report an overall survival of 15 and 17 months. This appears to be comparable or better than prior reports of SCC treated with definitive RT. However, reported rates of overall survival with definitive RT are difficult to compare because of heterogeneous presentations and a lack of consistent staging in prior reports. Chao et al report a median survival of only 5.7 months in their cohort (42 patients, 67% SCC) treated with RT alone. Median survival was poorer for patients with lymph node involvement at 4.6 months.¹¹ Gaissert et al similarly described median overall survival of 8.8 months for patients with unresectable SCC.⁸ Two series have reported higher rates of survival for definitive radiation. Makarewicz et al describe a median survival of 17 months in 13 patients treated with 60 Gy RT.¹² However, only 3 of these patients had nodal involvement, and only 1 patient had mainstem bronchus involvement. Similarly, Schraube et al¹³ report a median survival of 31 months for 11 SCC patients treated with definitive RT, which appears to be higher than other reports.¹⁴ The authors of this study acknowledge that their reported higher rate of survival may be attributed to lack of mediastinal lymph node involvement in 7 of 11 patients. Chow et al also report a median overall survival of 26 months; however, this analysis was not limited to patients with SCC.²⁴ Thus, it is not clear whether the patients in these studies represent earlier stage or less aggressive disease compared with patients in our report

who presented with extensive locoregional or nodal involvement.

Notably, patients in this report tolerated therapy well with the use of modern RT techniques and dose delivery to 60 to 66 Gy to large extents of the central airways. The most significant adverse effect was RTOG grade 2 esophagitis and grade 2 radiation pneumonitis. Neither of the patients required nutritional support via feeding tube during or after therapy. Of note, the grade 2 pneumonitis was observed in the patient with 3-dimensional conformal planning with lung metrics of V20 = 35.7% and V5 = 67.0%, whereas pneumonitis did not occur with the use of IMRT for patient 2.

This report provides evidence for the use of concurrent chemotherapy and RT using modern techniques with no significant severe toxicity for SCC of the trachea. This supports the few reports that have been published documenting the use of concurrent chemoradiation for this tumor^{2,5,18} as well as other tracheobronchial tumors.²⁵ Because of the limited number of patients treated, additional data will be required to validate the efficacy of chemoradiation in comparison to primary RT alone for unresectable cases and subsequently identify improved systemic therapies. Given the high rate of distal recurrence in other reports and in our 2 patients, further investigation into the potential role of additional therapies, such as adjuvant chemotherapy or immunotherapy, may be worth exploring. Notably, these patients did not have metastatic tracheal disease or direct extension of bronchogenic carcinoma. Thus, the applicability of this report to such disease presentations is unclear. However, our initial findings suggest the use of concurrent chemotherapy may be considered in addition to RT in patients with locally advanced or late stage tracheal SCC.

Supplementary data

Supplementary material for this article (<http://dx.doi.org/10.1016/j.adro.2016.03.003>) can be found at www.practicalradonc.org.

References

- Macchiarini P. Primary tracheal tumours. *Lancet Oncol*. 2006;7:83-91.
- Joshi N, Mallick S, Haresh KP, et al. Modern chemoradiation practices for malignant tumors of the trachea: An institutional experience. *Indian J Cancer*. 2014;51:241-244.
- Xie L, Fan M, Sheets NC, et al. The use of radiation therapy appears to improve outcome in patients with malignant primary tracheal tumors: A SEER-based analysis. *Int J Radiat Oncol Biol Phys*. 2012;84:464-470.
- Abbate G, Lancellata A, Contini R, Scotti A. A primary squamous cell carcinoma of the trachea: Case report and review of the literature. *Acta Otorhinolaryngol Ital*. 2010;30:209.
- Hetnał M, Kielaszek-Ćmiel A, Wolanin M, et al. Tracheal cancer: Role of radiation therapy. *Rep Pract Oncol Radiother*. 2010;15:113-118.
- Ly V, Gupta S, Desoto F, Cutaia M. Tracheal squamous cell carcinoma treated endoscopically. *J Bronchol Interv Pulmonol*. 2010;17:353-355.
- Ahn Y, Chang H, Lim YS, et al. Primary tracheal tumors: Review of 37 cases. *J Thorac Oncol*. 2009;4:635-638.
- Gaissert HA, Grillo HC, Shadmehr MB, et al. Long-term survival after resection of primary adenoid cystic and squamous cell carcinoma of the trachea and carina. *Ann Thorac Surg*. 2004;78:1889-1897.
- Thotathil ZS, Agarwal JP, Shrivastava SK, Dinshaw KA. Primary malignant tumors of the trachea - the Tata Memorial Hospital experience. *Med Princ Pract*. 2004;13:69-73.
- Videtic GMM, Campbell C, Vincent MD. Primary chemoradiation as definitive treatment for unresectable cancer of the trachea. *Can Respir J*. 2003;10:143-144.
- Chao MW, Smith JG, Laidlaw C, Joon DL, Ball D. Results of treating primary tumors of the trachea with radiotherapy. *Int J Radiat Oncol Biol Phys*. 1998;41:779-785.
- Makarewicz R, Mross M. Radiation therapy alone in the treatment of tumours of the trachea. *Lung Cancer Amst Neth*. 1998;20:169-174.
- Schraube P, Latz D, Wannenmacher M. Treatment of primary squamous cell carcinoma of the trachea: The role of radiation therapy. *Radiother Oncol J*. 1994;33:254-258.
- Grillo HC, Mathisen DJ. Primary tracheal tumors: Treatment and results. *Ann Thorac Surg*. 1990;49:69-77.
- Green N, Kulber H, Landman M, Pierce M. The experience with definitive irradiation of clinically limited squamous cell cancer of the trachea. *Int J Radiat Oncol Biol Phys*. 1985;11:1401-1405.
- Fields JN, Rigaud G, Emami BN. Primary tumors of the trachea. Results of radiation therapy. *Cancer*. 1989;63:2429-2433.
- Cheung AY. Radiotherapy for primary carcinoma of the trachea. *Radiother Oncol J Eur Soc Ther Radiol Oncol*. 1989;14:279-285.
- Joshi NP, Haresh KP, Das P, et al. Unresectable basaloid squamous cell carcinoma of the trachea treated with concurrent chemoradiotherapy: A case report with review of literature. *J Cancer Res Ther*. 2010;6:321-323.
- Bhattacharyya N. Contemporary staging and prognosis for primary tracheal malignancies: A population-based analysis. *Otolaryngol-Head Neck Surg*. 2004;131:639-642.
- Honings J, van Dijk JAAM, Verhagen AFTM, van der Heijden HFM, Marres HAM. Incidence and treatment of tracheal cancer: A nationwide study in the Netherlands. *Ann Surg Oncol*. 2007;14:968-976.
- Compeau CG, Keshavjee S. Management of tracheal neoplasms. *Oncologist*. 1996;1:347-353.
- Meyers BF, Mathisen DJ. Management of tracheal neoplasms. *Oncologist*. 1997;2:245-253.
- Grillo HC. *Surgery of the Trachea and Bronchi*. Hamilton, Ontario, Canada: BC Decker; 2004.
- Chow DC, Komaki R, Libshitz HI, Mountain CF, Ellersbroek N. Treatment of primary neoplasms of the trachea. The role of radiation therapy. *Cancer*. 1993;71:2946-2952.
- Allen AM, Rabin MS, Reilly JJ, Mentzer SJ. Unresectable adenoid cystic carcinoma of the trachea treated with chemoradiation. *J Clin Oncol*. 2007;25:5521-5523.